

## Tuberculid of the Glans Penis

Nádia Barbosa Aires, Claudia G. Santi and Marcello M. S. Nico

Department of Dermatology, University of São Paulo, São Paulo, Avenida Rebouças 1101, Ap 92, São Paulo 05401-150, SP, Brazil.

E-mail: [nadiaaires@yahoo.com.br](mailto:nadiaaires@yahoo.com.br)

Accepted May 30, 2006

Sir,

The incidence of tuberculosis in industrialized countries has decreased in recent years, although it is significant in developing ones (1, 2). Tuberculosis has re-emerged recently, largely due to the HIV/AIDS epidemic (3).

Cutaneous tuberculosis in its different manifestations is relatively rare and its diagnosis is often challenging (3–5). There are two general categories of cutaneous tuberculosis. The first is true cutaneous tuberculosis, which involves the proliferation of the tubercle bacilli in the skin and includes primary tuberculous chancre, lupus vulgaris, scrofuloderma, tuberculosis verrucosa cutis, orificial tuberculosis and miliary tuberculosis (1, 2). The second category comprises the tuberculids, which consist of a group of clinical entities representative of hypersensitivity reactions to haematogenous lodging of small numbers of tubercle bacilli or bacilli antigens in cutaneous vessels of a tuberculin highly sensitive individual (1–4, 6, 7). Clinical forms of tuberculids include erythema induratum, papulo-necrotic tuberculid (PNT) and lichen scrofulosorum (1–4, 7). PNT occurs as multiple ulcerated papules and affects more commonly pilo-sebaceous follicle bearing areas of the skin, but, on rare occasions, palmoplantar and penile lesions have been reported.

The term “penile tuberculid” refers to a characteristic picture limited mainly to the glans penis. This has been considered a distinctive type of tuberculid by some authors, mainly in Japan (3, 7). In rare additional reports, lesions described include papules and nodules with ulcerations and scarring (3, 5, 8, 9). Prolonged course, spontaneous healing of individual lesions, recurrence and the occasional presence of an internal tuberculous focus in the organism are factors to consider in establishing the diagnosis (9).

We present here two Brazilian patients diagnosed with penile tuberculid.

### CASE REPORTS

#### Case 1

A 24-year-old Afro-Brazilian man presented with a 3-month history of painless lesions on the glans penis. Clinical examination revealed multiple infiltrated, erythematous, 2 mm papules; several of these lesions showed a tiny central scab; in some areas these coalesced into crater-shaped ulcerations with a sloughing base. Along with the aforementioned lesions, several depressed scars with irregular borders and pock-marked surface were present (Fig. 1 a). There was no palpable adenopathy and no other significant physical findings were present. There was

no previous history of tuberculosis, either in the patient or in his close family. Histopathology of a biopsied papule revealed a wedge-shaped area of dermo-epidermal necrosis surrounded by a poorly formed granulomatous infiltrate composed of lymphocytes and macrophages. Fibrinoid necrosis of some dermal vessels was present. Stains for acid-fast bacilli and fungi were negative. Biopsy culture for mycobacteriosis was negative. The tuberculin test was strikingly positive, showing a 30×30 mm nodule with blisters and lymphangitis. Red and white cell count did not reveal significant abnormalities. Thoracic X-ray was normal, urinalyses with studies for mycobacteria were normal/negative.

A diagnosis of penile tuberculid was made and treatment with rifampicin, isoniazid and pyrazinamide was initiated. After 2 months there were no active lesions; only the depressed scars remained.

#### Case 2

A 61-year-old Afro-Brazilian man had a 20-year history of relapsing penile lesions that had been diagnosed previously by dermatologists as dermatitis artefacta. Clinical examination showed several infiltrated nodulo-ulcerative lesions and many irregular pock-mark depressed scars on the glans penis. No other detectable changes were present on cutaneous or general examinations. Histopathology of a papule revealed an area of dermal necrosis evolved by a lympho-histiocytic infiltrate in a loose granulomatous array; occasional degenerated neutrophils were present (Fig. 2). Stains acid-fast bacilli and fungi were negative. Biopsy culture for mycobacteriosis was negative. The tuberculin test was intensely positive (25×25 mm nodule and 35×35 mm erythema). Blood count and biochemistry and chest X-ray were normal. Urine studies for mycobacteria and blood tests for syphilis were negative.

A diagnosis of penile tuberculid was made, and after one month of chemotherapy (rifampicin, isoniazid and pyrazinamide) the ulcers healed, leaving only the depressed scars (Fig. 1b).

### DISCUSSION

The formation of tuberculids is explained by the haematogenous dissemination to the skin of mycobacterial antigens from an internal tuberculous focus in a hypersensitive patient, as measured by PPD (1, 2, 6–8). The clinical variety of presentations may be explained by variations in the skin temperature, stasis and size of vessels involved by the hypersensitivity vasculitic process (8, 10); at times several patterns may coexist in the same patient (11). The tuberculous focus is frequently not detected at the time of the eruption, it may be non-active at this time (8). Mycobacteria cannot be cultured from lesions (10); nevertheless, some recent authors have found mycobacterial DNA in erythema induratum and PNT lesions using polymerase chain reaction (PCR) (3, 4, 10); and lesions show a good response to anti-tuberculous therapy (3, 7, 11, 12).

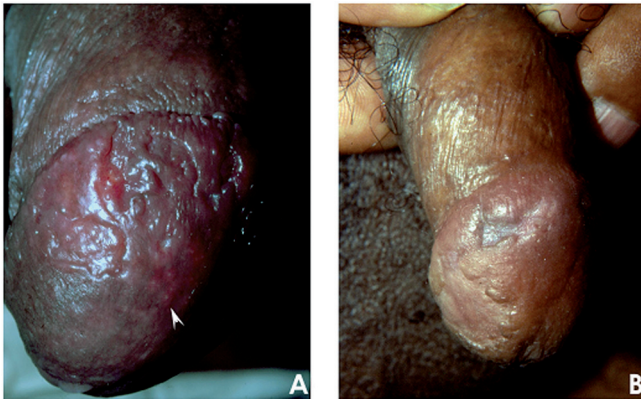

Fig. 1. (a) Case 1: multiple scabbed papules (arrow); proximally, presence of ulcers and scars. (b) Case 2: after treatment, showing typical irregular depressed scars.

The occurrence of penile tuberculids is a very rare but well-documented event (3, 5, 7–9). Most reports come from Japanese and South African authors (3, 5, 7, 13), suggesting a racial or environmental predisposition, but occasional patients have been seen in other countries (8, 9). To our knowledge, South American patients have not been reported so far.

Previous reports of penile PNT include cases with exclusive penile lesions and cases with classic papulonecrotic lesions elsewhere (9, 12). This latter situation indicates that cases of exclusive genital lesions may represent a localized form of the same pathological process, but in our opinion it is a quite characteristic one, since most reported cases remain confined to the glans penis and most cases of PNT do not present with genital lesions. Genital ulcerative diseases usually considered as differential diagnosis with genital tuberculid include syphilis, recurrent herpes simplex, erythroplasia, drug eruption, balanitis, Behçet's disease and squamous cell carcinoma (7–9), and one of our patients had been pre-

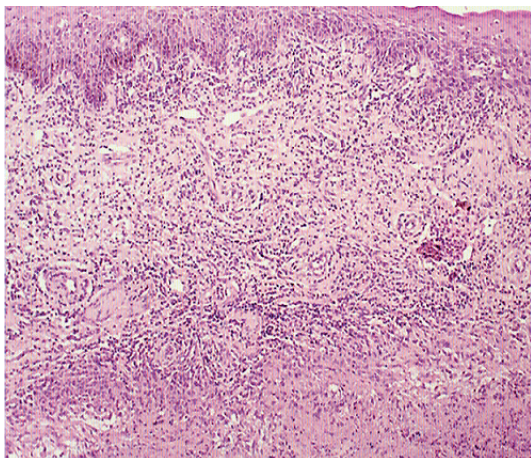


Fig. 2. Case 2: area of necrosis in the dermis surrounded by a palisade of inflammatory cells (haematoxylin-eosin (H&E)).

viously diagnosed with artifact balanitis for 20 years. To our knowledge no other disease, however, evolves into such a scar on the glans penis, and the cases presented herein are identical to the photographs presented in previous reports (8, 9, 13).

Histopathological findings in PNT include a wedge-shaped area of dermo-epidermal necrosis, fibrinoid changes in the superficial vessels and a superficial and deep inflammatory infiltrate with neutrophils, lymphocytes and macrophages with variable degree of granuloma formation (11). Occasional palisade disposition of the mononuclear infiltrate around the area of dermal necrosis, resembling granuloma annulare, is seen (11), as in the case of our patient no. 2. Stains for mycobacteria are consistently negative.

As seen here, correct diagnosis of penile tuberculid is frequently delayed, at times for years, but its clinical, histopathological and immunological presentations are typical enough for a precise diagnosis. Conventional anti-tuberculous treatment has been uniformly effective in the described cases (3, 7, 9, 12).

## REFERENCES

1. Hamada M, Urabe K, Moroi Y, Miyazaki M, Furue M. Epidemiology of cutaneous tuberculosis in Japan: a retrospective study from 1906 to 2002. *Int J Dermatol* 2004; 43: 727–731.
2. Barbagallo J, Tager P, Ingleton R, Hirsch RJ, Weinberg JM. Cutaneous tuberculosis: diagnosis and treatment. *Am J Clin Dermatol* 2002; 3: 319–328.
3. Yonemura S, Fujikawa S, Su JS, Ohnishi T, Arima K, Sugimura Y. Tuberculid on the penis with a scab on the nodule. *Int J Urol* 2004; 11: 931–933.
4. Calonje E. The spectrum of cutaneous tuberculosis and the tuberculids. *J Eur Acad Dermatol Venereol Suppl* 2003; 17: 85.
5. Kashima M, Mori K, Kadono T, Nakabayashi Y, Shibayama E, Mizoguchi M. Tuberculide of the penis without ulceration. *Br J Dermatol* 1999; 140: 757–759.
6. Baselga E, Margall N, Barnadas MA, de Moragas JM. Mycobacterium tuberculosis DNA in Papulonecrotic Tuberculid. *Arch Dermatol* 1996; 132: 92–94.
7. Nishigori C, Taniguchi S, Hayakawa M, Imamura S. Penis tuberculides: papulonecrotic tuberculides on the glans penis. *Dermatologica* 1986; 172: 93–97.
8. Vijaikumar M, Thappa DM, Kaviarasan PK. Papulonecrotic tuberculide of the glans penis. *Sexually Transmitted Infections* 2002; 77: 147.
9. Stevanovic DV. Papulonecrotic tuberculids of glans penis. *Arch Dermatol* 1958; 78: 760–761.
10. Degitz K, Steidl M, Thomas P, Plewig G, Volkenandt M. Aetiology of tuberculids. *Lancet* 1993; 341: 239–240.
11. Jordaan HF, van Niekerk DJT, Louw M. Papulonecrotic Tuberculid: a clinical, histopathological and immunohistochemical study of 15 patients. *Am J Dermatopathol* 1994; 16: 474–485.
12. Israelewicz S, Dharan M, Rosenman D, Steinfeld M, Zuckerman F. Papulonecrotic tuberculid of the glans penis. *J Am Acad Dermatol* 1985; 12: 1104–1106.
13. Findlay GH. *The dermatology of bacterial infections*. Oxford: Blackwell, 1987: p. 81–83.