

Mucinous Eccrine Naevus Presenting with Hyperhidrosis: A Case Report

Xiao-Yong Man¹, Sui-Qing Cai¹, Ai-Hua Zhang² and Min Zheng^{1*}

Departments of Dermatology, ¹Second Affiliated Hospital, Zhejiang University School of Medicine, Hangzhou, Zhejiang, and ²Affiliated Hospital of Taishan Medical College, Taian, Shandong, China. *E-mail: minz@zju.edu.cn

Accepted May 17, 2006.

Sir,

Eccrine naevus is a very rare cause of local hyperhidrosis, fewer than 20 cases have been reported (1, 2), with widely varying clinical presentations appearing as solitary pore, papule, nodule, tumour plaques and naevus sudoriferous type (3). Histopathological characteristics include increase in the number and/or size of the normal eccrine coils, without vascular changes (3). Mucinous eccrine naevus (MEN) is a variant of eccrine naevus, characterized by a proliferation of normally structured eccrine surrounded by abundant mucin deposits (4, 5). Only four cases have been reported in the literature to date (4–7). We report here a case of MEN with onset at about one year of age.

CASE REPORT

An 18-year-old girl was referred to the dermatology department with a 17-year history of hyperhidrosis and hypertrophy on the distal end of her left foot. This was initially noted by her parents at the age of one year. During childhood, her left four toes, except for the big toe, became pigmented, rough, swollen and deformed. Sweat usually secreted from the area on her left foot and saturated her sock and shoe. One year earlier, this lesion was diagnosed as pigmented naevus in another hospital by biopsy from the dorsum of the foot, but no special findings were observed. She was otherwise healthy, and there was no personal or family history of similar lesions.

Physical examination revealed a 4×3 cm, triangle-shaped, well-circumscribed lesion on the distal end of the dorsum of the left foot, with slightly brown hyperpigmentation. The big toe was normal, while the other four toes were deformed, hypertrophic and hyperpigmented, especially the middle toe (Fig. 1), which was firm and tender on palpation. Dewdrop-like sweat was fully distributed on the lesion surface. Sensation was intact over both affected and unaffected skin areas. Her right foot was completely normal.

Informed consent was obtained from the patient prior to biopsy. A cutaneous lesion was excised deeply from the dorsum of the left second toe, rather than from the dorsum of the left foot. The tissue was fixed in formalin and embedded in paraffin, and 4 µm sections for light microscopy were stained with haematoxylin and eosin (H&E) and Alcian blue separately. The epidermis demonstrated hyperkeratosis, acanthosis and focal pigment granule of the basal layer. The tissue showed an unremarkable superficial dermis. In the deep dermis, however, proliferation of lobulated eccrine glands, an increase in the number of intradermal eccrine ducts and eccrine coils composed of normal secretory and ductal portion were revealed (Fig. 2A). The nature of this lesion can be fully appreciated at higher magnification (Fig. 2B). The Alcian blue stain performed at pH 2.5 strongly highlighted a deposit of abundant mucinous

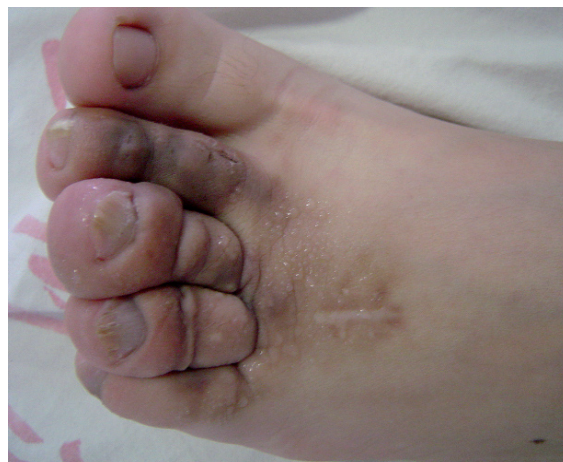

Fig. 1. A well-defined half 4×3 cm, triangle lesion on the dorsum of the foot. Except for the hallux, the other four toes are all deformed. The hyperhidrotic plaque is pigmented, tender and hypertrophic. The colourless, diaphanous, dewdrop-like sweat fully distributes on the surfaces of the lesion.

material, in the stroma surrounding the eccrine gland and diffusely present in the dermis (Fig. 2C).

Laboratory and radiological investigations, including total blood count, renal and liver function tests, X-ray of the feet, and abdominal and pelvic ultrasonography revealed no abnormal findings.

According to the clinical and histopathological findings, the girl was diagnosed as MEN.

Plastic surgery was applied to deal with the hypertrophy. At two subsequent follow-up visits, the patient presented improved shape of her left toes, but the sweating was not remarkably reduced.

DISCUSSION

Excessive sweating is a common complaint and in most patients the cause is benign (8). The aetiologies of localized hyperhidrosis associated with cutaneous abnormalities include eccrine angiomatous hamartoma, sudoriparous angioma, eccrine naevus and idiopathic unilateral hyperhidrosis (1). Eccrine naevus, a term first coined by Pippione et al. in 1976 (9), is a very rare lesion which presents at birth or at an early age, with no gender predilection. A biopsy reveals an increase in the number and/or size of the eccrine glands (1, 10, 11). Some cases of eccrine naevus lack hyperhidrosis despite an increased eccrine component (11).

MEN is an extremely rare variant of eccrine naevus. Only four cases have been described in the literature. In

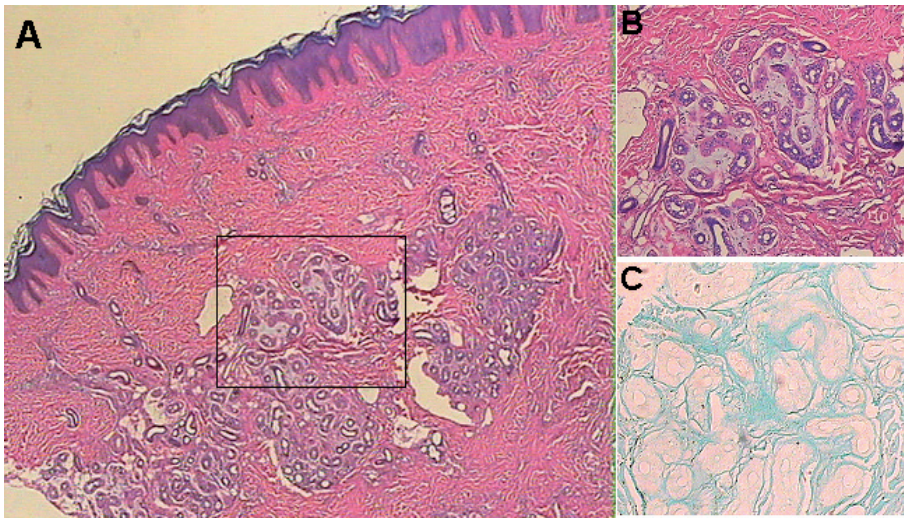


Fig. 2. Hyperkeratosis and acanthosis in the epidermis. (A) Increased number of lobulated eccrine structures in the deep dermis (haematoxylin and eosin (H&E) $\times 20$). (B) Higher magnification of the rectangle area. Proliferation of normally structured eccrine glands and ducts surrounded with abundant mucinous material in the deep dermis (H&E $\times 200$). (C) Alcian blue-specific staining of mucinous material (Alcian blue $\times 400$).

1994, Romer & Taira (4) reported a 47-year-old woman with an erythematous nodule, 1 cm in diameter, on the right lower extremity, of 2-years duration. The clinical diagnosis was erythema nodosum, but in histopathological findings, the tissue contained both eccrine and mucinous elements, thus they termed it MEN (4). In 2003, the second case was reported by Llombart et al. (6). This case was a 2-year-old girl who had two 1-cm, asymptomatic, brownish nodules. Histological analysis revealed a dermal lobulated proliferation of eccrine structures surrounded by a prominent mucinous stroma (6). Another case of MEN, which was late in onset and presented as a swollen patch, was described by Park et al. in 2004 (5). Interestingly, hyperhidrosis of the lesion was not present in these three cases. Very recently, the fourth case contributed additional information, in that the MEN lesions showed a distribution following the lines of Blaschko, with an extensive pattern along the lower left limb with multiple nodular lesions, and associated with focal hyperhidrosis (7). In our case, however, dewdrop-like sweat was fully distributed on the surfaces of the lesion (Fig. 1). The biopsied tissue showed a proliferation of normally structured lobulated eccrine glands and ducts surrounded with abundant materials confirmed as mucin by Alcian blue stain.

The aetiology of MEN is unknown. Llombart et al. (6), have hypothesized a defect during embryogenesis to be involved in the pathogenesis, but the fact that some of the cases developed in adulthood seems to argue against this hypothesis.

As the deformations of the toes and the hyperhidrosis were bothersome to our patient, she underwent plastic surgery. The hypertrophy was improved, but the sweat was not remarkably reduced. As the next step, we plan to apply other therapies of localized hyperhidrosis,

such as a 20% alcohol solution of aluminium chloride hexahydrate, iontophoresis, botulinum toxin (12, 13) and systemic anticholinergics (8).

REFERENCES

1. Kawaoka JC, Gray J, Schappell D, Robinson-Bostom L. Eccrine nevus. *J Am Acad Dermatol* 2004; 51: 301–304.
2. Morris ES, Scheel MM, Lundquist KF, Raimer SS. Grouped papules on the arm of an infant. Eccrine nevus. *Arch Dermatol* 2000; 136: 549–552.
3. Hong CE, Lee SH. Multiple eccrine nevus with depressed patches. *Yon Med J* 1997; 38: 60–62.
4. Romer JC, Taira JW. Mucinous eccrine nevus. *Cutis* 1994; 53: 259–261.
5. Park HS, Lee UH, Choi JC, Chun DK. Mucinous eccrine nevus. *J Dermatol* 2004; 31: 687–689.
6. Llombart B, Molina I, Montegudo C, Ramon D, Martin JM, Sanchez R, et al. Mucinous eccrine nevus: an unusual lesion in a child. *Pediatr Dermatol* 2003; 20: 137–139.
7. Espana A, Marquina M, Idoate MA. Extensive mucinous eccrine naevus following the lines of Blaschko: a new type of eccrine naevus. *Br J Dermatol* 2006; 154: 1004–1006.
8. Leung AKC, Chan PYH, Choi MCK. Hyperhidrosis. *Intern J Dermatol* 1999; 38: 561–567.
9. Pippione M, Depaoli MA, Sartoris S. Eccrine-nevus. *Dermatologica* 1976; 152: 40–46.
10. Morris ES, Scheel MM, Lundquist KF, Raimer SS. Grouped papules on the arm of an infant. *Arch Dermatol* 2000; 136: 547–552.
11. Vazquez MR, Gomez de la Fuente E, Fernandez JG, Martin FJ, Estebananz JL, Moraleda FP. Eccrine naevus: case report and literature review. *Acta Derm Venereol* 2002; 82: 154–156.
12. Kreyden OP, Schmid-Grendelmeier P, Burg G. Idiopathic localized unilateral hyperhidrosis: case report of successful treatment with botulinum toxin type A and review of the literature. *Arch Dermatol* 2001; 137: 1622–1625.
13. Sonntag M, Rauch L, Ruzicka T, Bruch-Gerharz D. Botulinum toxin treatment of eccrine sweat gland nevus. *Hautarzt* 2005; 56: 364–366.