

INVESTIGATIVE REPORT

Effect of UV Irradiation on Cutaneous Cicatrices: A Randomized, Controlled Trial with Clinical, Skin Reflectance, Histological, Immunohistochemical and Biochemical Evaluations

Eva DUE¹, Kristian ROSSEN², Lars Tue SORENSEN³, Anette KLIEM⁴, Tonny KARLSMARK¹ and Merete HAEDERSDAL¹
Departments of ¹Dermatology, ²Pathology and ³Surgery, Bispebjerg Hospital, University of Copenhagen, and ⁴Department of Immunology and Microbiology, University of Southern Denmark, Odense, Denmark

The aim of this study was to examine the effect of ultraviolet (UV) irradiation on human cutaneous cicatrices. In this randomized, controlled study, dermal punch biopsy wounds served as a wound healing model. Wounds healed by primary or second intention and were randomized to postoperative solar UV irradiation or to no UV exposure. Evaluations after 5 and 12 weeks included blinded clinical assessments, skin reflectance measurements, histology, immunohistochemistry, and biochemical analyses of the N-terminal propeptide from procollagen-1, hydroxyproline, hydroxylysine, and proline. Twelve weeks postoperatively, UV-irradiated cicatrices healing by second intention: (i) were significantly pointed out as the most disfiguring; (ii) obtained significantly higher scores of colour, infiltration and cicatrix area; and (iii) showed significantly higher increase in skin-reflectance measurements of skin-pigmentation vs. non-irradiated cicatrices. No histological, immunohistochemical or biochemical differences were found. In conclusion, postoperative UV exposure aggravates the clinical appearance of cicatrices in humans. Key words: cicatrix; hydroxyproline; PINP; skin reflectance; ultraviolet radiation, wound healing.

(Accepted June 13, 2006.)

Acta Derm Venereol 2007; 87: 27–32.

Eva Due, MD, Department of Dermatology, Bispebjerg Hospital, University of Copenhagen, Bispebjerg Bakke 23, DK-2400 Copenhagen, Denmark. E-mail: dueeva@yahoo.dk

Dermatological and plastic surgery are often performed on ultraviolet (UV)-exposed skin areas. It is thought that UV exposure has a clinically negative effect on wound healing and the cosmetic appearance of cicatrices. Postoperative instructions recommend patients to protect healing wounds from exposure to sunlight. However, the evidence for this recommendation is actually sparse since there are very few studies investigating the effect of UV irradiation on human wound healing. These studies deal with pressure sores, suction blisters and skin grafts (1–3). The effect of UV irradiation on the cosmetic appearance of scar tissue after dermatological surgery in humans has not been investigated previously.

Cutaneous wound healing is a complex process involving four major overlapping phases: inflammation, cell proliferation, matrix deposition and remodelling (4). The wound healing process may be influenced by UV irradiation in different ways, for example by the immediate UV-induced inflammation, which presents as erythema and is followed by increased skin pigmentation (5). Moreover, the metabolism of type I collagen is affected within hours of UV exposure (6, 7). Collagen I is the most abundant structural protein of the extracellular matrix in mature scar tissue, being responsible for the skin resiliency and determining the cosmetic appearance of the cicatrix (8, 9).

The aims of this study were to evaluate the effect of solar UV irradiation on the cosmetic appearance of human cicatrices, and to study histological, immunohistochemical and biochemical aspects of collagen metabolism.

MATERIALS AND METHODS

Study population

Fourteen healthy non-smoking male volunteers, mean age 29.4 years (range 21–44 years), with skin types II and III (10) and with homogeneous skin pigmentation on their buttocks were enrolled in the study after giving informed consent. Exclusion criteria were atopic dermatitis, previous keloids or hypertrophic scars, exposure to UV light during the last 3 months and medical treatment including anti-inflammatory drugs. During the study the subjects were not allowed to expose their buttocks to sunlight or other types of UV light. The study was approved by the Regional Scientific Ethical Committee according to the Declaration of Helsinki.

Experimental set-up

Full-thickness dermal punch biopsy wounds healed by either primary closure (PC-cicatrices, 5 mm) or by second intention (SI-cicatrices, 6 mm) and served as wound healing model (Table I). Eight biopsies from each volunteer were taken symmetrically, laterally on the upper gluteal regions. The buttocks were randomized to post-operative UV irradiation or to no UV exposure by tossing a coin. Response evaluations and re-biopsies (6 mm) from SI-cicatrices took place 5 and 12 weeks after wounding (Table I). Dermal punch biopsies were carried out after surgical disinfection with 0.5% ethanol-chlorhexidine liniment and under local anaesthesia with Carbocain (20 mg/ml) with adrenalin (5 µg/ml), 1–2 ml per biopsy. PC-wounds were sutured with one stitch of Ethilon 4-0 non-absorbable sutures. The sutures were

Table I. *Experimental set-up. Eight full-thickness dermal punch biopsies (5 and 6 mm) were performed at week 0 on the buttocks of each volunteer. Buttocks were randomized to UV irradiation or no irradiation. Five and 12 weeks postoperatively clinical evaluations were performed and re-biopsies were carried out from second intention (SI)-cicatrices* for biochemical, histological and immunohistochemical evaluations*

Test wound	Healing by second intention (5 mm)	Healing by primary closure (6 mm)	UV-exposure Week 2–4	Response evaluation	
				Week 5	Week 12
1	X		X	X*	
2	X			X*	
3	X		X		X*
4	X				X*
5		X	X	X	
6		X		X	
7		X	X		X
8		X			X

removed at day 14. Biopsies were divided into two halves and prepared for histological, immunohistochemical and biochemical analyses. UV irradiation was provided by a solar simulator with a filtered xenon lamp (Multiport Solar Ultraviolet Simulator, Model 601, Solar Light Co., USA) emitting a UV spectrum close to natural sunlight: 297–400 nm, thus including UVA and UVB. The emitted spectrum was determined by a UV spectroradiometer (Sola-Hazard, Solatell, Redruth, Cornwall, UK). The measurements are expressed in standard erythema doses (SED), where 1 SED = 100 J/m² normalized to 298 nm according to the International Commission on Illumination (11). The radiation was conducted to the skin through a light guide that irradiated a circular skin area of approximately 1 cm². A template ensured precise repetitive irradiations of the wound areas. Irradiations were performed with single doses of 2.7 SED = 0.027 J/cm². A single dose corresponds to spending 30 min on the beach on a cloudless midsummer day in Denmark. Irradiations started 2 weeks after wounding and were carried out every second day, 11 times in total. The accumulated dose was 29.4 SED.

Clinical evaluation

A trained dermatologist carried out blinded evaluations of the clinical appearance of the cicatrices at week 5 (photo evaluation) and week 12 (on-site evaluation) after wounding. The observer was asked to evaluate the overall clinical impression by answering: (i) if there was any difference between the corresponding UV-irradiated and non-irradiated cicatrices; (ii) was the difference mild (= 1), moderate (= 2) or pronounced (= 3); and (iii) which of the cicatrices was the most disfiguring. Moreover, the observer performed a semi-quantitative 4-point evaluation of colour, atrophy, infiltration and contraction of the cicatrices. Five weeks after wounding the observer evaluated whether the wound closure was complete. The on-site clinical evaluations 12 weeks after wounding included visual and palpable examinations of the cicatrices. Quantification of the surface area of the SI-cicatrices was accomplished by drawing the outlines of the scars on millimetre-grid paper. Photographs were taken with a Canon Digital Camera (EOS D30) equipped with a lens mounted ring flash (Canon Macro Lens EF 100 mm 1:2.8 USM). All photographs were taken under identical conditions and camera settings. All photographs were taken in raw format and converted to JPG format. A single laboratory processed all photographs. The clinical evaluations took place under identical, standardized conditions.

Skin reflectance

Skin reflectance measurements quantified skin redness and pigmentation (UV-Optimize, Matic, Herlev, Denmark). The equipment uses 555 and 660 nm wavebands of light, where the discrimination

between light absorption in melanin and haemoglobin is maximal. Skin pigmentation and redness are quantified independently and continuously on relative scales from 0 to 100%, where 0% pigment corresponds to an extremely white person with no melanization and 100% pigment corresponds to the pigmentation in extremely black skin with no light reflection. 0% skin redness is found in skin where blood has been temporarily drained from the area, whereas 100% redness is found in highly vascular tissue (12, 13). Measurements were standardized by means of a template.

Biochemical analyses

The amino acids hydroxyproline (HYP) and hydroxylysine (HYL) are nearly 100% specific for collagen and can therefore serve as indicators of the total amount of collagen. Proline (PRO) is correlated with the total amount of protein. Identification and quantification of amino acids were carried out by derivatization with phenylisothiocyanate and subsequent high-performance liquid chromatography (14). PINP is the N-terminal propeptide from procollagen 1 (15, 16) that reflects the ongoing collagen synthesis of skin *in vivo*. Quantification of PINP was carried out by enzyme-linked immunosorbent assay (ELISA) utilizing purified 1-chain specific rabbit antibodies (15–17).

Histological and immunohistochemical evaluations

Samples were fixed in 4% buffered neutral formalin solution, embedded in paraffin and 4 µm thick sections were made perpendicular to the skin surface. Staining procedures for histology included haematoxylin-eosin and Alcianblue-vanGieson. For immunohistochemistry the sections were deparaffinized with 99% ethanol, demasked with protease and incubated with affinity purified polyclonal rabbit antibody against PINP (kindly provided by Dr Børge Teisner, Department of Immunology and Microbiology, University of Southern Denmark, Odense, Denmark) (15–17). Thereafter the sections were incubated with EnVision anti-rabbit (DAKO K4003 (Glostrup, Denmark)) and colour development was performed with 3-amino,9-ethyl-carbazol, counterstaining with Mayers haematoxylin. An experienced histopathologist carried out blinded evaluations of epidermal thickness and semi-quantitative evaluations on four-point scales (0–3) of inflammatory response, eosinophilic infiltration, collagen deposition, keloid fibrosis, fibroblast cellularity, vascularity, extravasation of erythrocytes and PINP immunoreactivity.

Statistics

Data were analysed and presented non-parametrically. The overall clinical differences between corresponding cicatrices were tested by the sign test. Fisher's exact test was used for comparing healed and not-healed wounds. The Wilcoxon signed rank test was used

for paired comparisons of clinical parameters, cicatrix areas, skin pigmentation and redness, histological and immunohistochemical wound healing parameters, HYP, HYL, PRO and PINP. Differences between groups were considered significant when $p \leq 0.05$.

RESULTS

Clinical evaluation

The *SI-cicatrices* were, in general, homogenous and characterized by a red-brownish discolouration with a light-brown periphery and some infiltration. No contraction was seen in any cicatrices. Five weeks after wounding no significant differences were seen between UV-irradiated and non-irradiated cicatrices. Twelve weeks after wounding (Fig. 1) a significant overall clinical difference was seen between UV-irradiated and non-irradiated cicatrices (14/14, $p = 0.0001$) and the UV-irradiated cicatrices were significantly pointed out as the most disfiguring cicatrices (14/14, $p = 0.0001$). The observed differences were graded as mild ($n = 12$) and moderate ($n = 2$). Significantly higher scores of colour and infiltration were obtained for UV-irradiated

vs. non-irradiated cicatrices. The UV-irradiated cicatrices were significant, but only slightly larger than the non-irradiated cicatrices (Table II).

The *PC-cicatrices* were, in general, irregular and characterized by stitch marks from sutures, resulting in a cross-shaped appearance. The scars were red-brownish discoloured with a light brown periphery and some infiltration. No contraction was seen in any cicatrices. UV-irradiated cicatrices were not by overall clinical evaluation pointed out as more disfiguring than non-irradiated cicatrices (week 5 $p = 0.79$; week 12 $p = 0.18$). However, significant higher scores of infiltration (week 5) and colour (week 12) were obtained for UV-irradiated cicatrices vs. non-irradiated cicatrices (Table II).

Skin reflectance

Skin pigmentation was significantly more increased in UV-irradiated cicatrices vs. corresponding non-irradiated cicatrices. The increased skin pigmentation remained constant from weeks 5 to 12 postoperatively in UV-irradiated *SI-cicatrices*, in non-irradiated *SI-cicatrices* and in UV-irradiated *PC-cicatrices*. No significant differences were seen in skin redness between UV-irradiated and non-irradiated cicatrices (Table II). The increased skin redness declined significantly from weeks 5 to 12 postoperatively in irradiated *SI-cicatrices* ($p=0.0134$), in non-irradiated *SI-cicatrices* ($p=0.0166$) and in non-irradiated *PC-cicatrices* ($p=0.0295$).

Biochemical results

The amounts of HYP and PRO were significantly reduced in UV-irradiated and non-irradiated cicatrices at

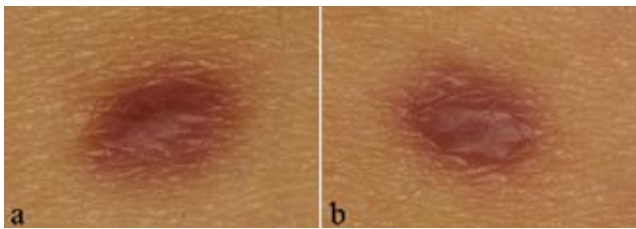


Fig. 1. (a) UV-irradiated and (b) non-irradiated second intention-cicatrice 12 weeks after wounding.

Table II. Blinded clinical evaluations of cicatrices at weeks 5 (photo-evaluation) and 12 (on-site evaluation) and reflectance measurements of pigment% and redness%. Values are presented as median (range)

	Week 5				<i>p</i>	Week 12				<i>p</i>
	Non UV		UV			Non UV		UV		
<i>SI-cicatrices</i>										
Complete wound closure	12		9		$p=0.385$					
Infiltration ^a	1	(1-2)	1.75	(1-2)	$p=0.13$	1	(0.5-2.0)	1.5	(0.5-2.0)	$p=0.042$
Atrophy ^a	0	(0-0)	0	(0-0)	$p=1$	0	(0.0-1.0)	0.25	(0.0-1.0)	$p=1.000$
Colour ^a	2	(0.5-2)	2	(1-2)	$p=0.88$	1.5	(1.0-2.0)	2	(2.0-2.0)	$p=0.008$
Size of cicatrix, mm ²	18	(11-34)	18	(13-25)	$p=0.88$	22	(17-34)	24	(18-34)	$p=0.017$
Pigmentation% ^b	8.9	(-3.1-13.2)	11.2	(-3.7-25.9)	$p=0.002$	7.9	(-5.2-15.3)	12.2	(-3.5-18.5)	$p=0.000$
Redness% ^b	30.2	(11.4-46.0)	24.2	(8.0-40.6)	$p=0.14$	23.7	(4.6-30.4)	18.4	(4.0-29.1)	$p=0.153$
<i>PC-cicatrices</i>										
Complete wound closure	14	(0.5-1.5)	10		$p=0.098$					
Infiltration ^a	1	(0-0)	1.5	(1-2)	$p=0.02$	1	(0.5-2.0)	1	(0.5-2.0)	$p=0.063$
Atrophy ^a	0	(1-2)	0	(0-0)	$p=1$	0.5	(0.0-2.0)	0.5	(0.0-1.0)	$p=0.375$
Colour ^a	2		2	(2-2)	$p=0.18$	1.5	(1.0-2.0)	2	(1.5-2.0)	$p=0.02$
Pigmentation% ^b	3.8	(-4.0-14.9)	12.5	(-8.9-32.3)	$p=0.003$	8.9	(-8.6-20.1)	13.0	(-7.9-23.7)	$p=0.007$
Redness% ^b	31.3	(19.6-45.0)	28.3	(-3.0-43.5)	$p=0.12$	23.5	(11.1-35.2)	24.0	(10-34.8)	$p=0.952$

^aFour-point semiquantitative scales: (0, 1, 2, 3). Intermediary grades were accepted.

^bReflectance measurements of skin pigmentation% and redness% are expressed as changes from the value in normal skin.

SI, second intention; PC, primary closure.

weeks 5 and 12 postoperatively vs. normal skin at week 0 ($p < 0.01$). There were no significant differences in the amounts of HYL from irradiated and non-irradiated cicatrices at weeks 5 and 12 postoperatively vs. normal skin at week 0. The amounts of PINP were significantly increased in UV-irradiated and non-irradiated cicatrices at weeks 5 and 12 postoperatively vs. normal skin at week 0 ($p < 0.01$). There were no significant differences in the amounts of HYP, HYL, PRO or PINP between UV-irradiated vs. non-irradiated SI-cicatrices (Table III).

Histological and immunohistochemical results

The initial biopsies showed normal skin without pathological changes. The biopsies from weeks 5 and 12 were characteristic for recent and later scar tissue, respectively. The scar tissue was slightly inflamed and a little more pronounced in the biopsies from week 5. Fibroblast cellularity and collagen deposition showed a reverse relation in the biopsies at week 5 and 12. Thus the fibroblast cellularity was more pronounced at week 5 and the collagen deposition was more pronounced at week 12; yet the differences were limited. There were no significant differences between UV-irradiated and non-irradiated SI-cicatrices for epidermal thickness, inflammatory response, eosinophilic infiltration, collagen deposition, keloid fibrosis, fibroblast cellularity, vascularity, extravasation of erythrocytes or PINP immunoreactivity.

DISCUSSION

In this study we used clinically relevant UV doses corresponding with the UV exposure of 5–6 h in the middle of the day in the summertime, in Denmark. The results at the 12-week follow-up indicate that postoperative UV-irradiation aggravates the clinical appearance of cicatrices healed by second intention in regard to overall cosmetic impression, colour, infiltration and size, and tends to aggravate the clinical appearance of cicatrices healed by primary closure. Skin reflectance measurements of pigmentation confirmed the clinical observations of colour, while the histological, immunohistochemical and biochemical analyses could not

explain the clinical assessments of infiltration. In the clinical evaluations the assessor was blinded to whether cicatrices were UV-irradiated. However, some bias may be introduced to the evaluations due to a slight solar-induced hyper-pigmentation in the cicatrices. This was, nevertheless, an inevitable confounder in the present human study. The PC-cicatrices were in general irregular due to the stitching and, therefore, difficult to compare, which may explain why we found only limited differences between UV-irradiated and non-irradiated PC-cicatrices. Photo-evaluations (5-week follow-up) were less optimal than on-site evaluations (12-week follow-up), which allow for visual, three-dimensional and palpable examinations. This may give an explanation for the non-significant findings 5 weeks after wounding.

Evaluation of completion of wound closure 5 weeks after wounding did not show any differences between UV-irradiated and non-irradiated cicatrices. Previous animal studies examining the effect of postoperative UV exposure (UVA or UVA plus UVB) on the wound-healing process show delayed healing (18), faster healing (19) as well as no effect on wound healing rate (20, 21). In our study the sizes of the UV-irradiated SI-cicatrices were significantly though only slightly larger than the non-irradiated SI-cicatrices at week 12. In relation to this animal studies of the effect of pre-operative UV exposure (UVA or UVA plus UVB) on wound healing showed slower wound contraction (22, 23) in UV-irradiated vs. non-irradiated skin, while one animal study demonstrated a diminution of wound size when irradiated postoperatively compared with non-irradiated wounds (250–400 nm) (20).

Human studies on the UV effect on collagen metabolism document that UV irradiation has a negative effect on collagen synthesis and a stimulating effect on collagen breakdown, resulting in reduction of the total amount of collagen (24, 25). Likewise, we would expect smaller concentrations of PINP in the irradiated wounds, compared with the non-irradiated wounds, reflecting the negative UV effect on collagen synthesis (25, 26). However, neither the histological or immunohistochemical evaluations of collagen, nor the biochemical analyses of HYP, HYL, PRO and PINP

Table III. Effect of UV-irradiation on hydroxyproline (HYP), hydroxylysine (HYL), proline (PRO) and N-terminal propeptide (PINP) from procollagen-1 in cicatrices healed by second intention. Values are presented as median (range)

Week 0	Week 5				Week 12							
	Non-UV		UV		Non-UV		UV					
HYP ^a	57.53	(44.20–63.93)	41.75 ^d	(34.52–53.18)	45.99 ^d	(36.91–56.29)	$p=0.194$	46.47 ^d	(41.80–59.22)	46.53 ^{c,d}	(41.31–58.75)	$p=0.391$
HYL ^a	3.43	(1.12–4.72)	3.67	(2.62–7.81)	3.29	(2.77–8.54)	$p=0.463$	3.80	(2.96–4.75)	3.72	(3.13–5.00)	$p=0.715$
PRO ^a	83.58	(62.44–88.78)	64.59 ^d	(59.37–79.38)	67.38 ^d	(62.41–79.90)	$p=9.296$	68.94 ^d	(64.58–88.35)	70.88 ^d	(62.98–82.97)	$p=0.502$
PINP ^b	0.14	(0.02–1.68)	42.94 ^d	(15.28–150.53)	64.38 ^d	(17.97–147.64)	$p=0.358$	63.29 ^d	(22.57–188.97)	57.64 ^d	(33.38–102.74)	$p=0.194$

^aµg/mg dry, delipidized tissue, ^bµg/g biopsy wet weight.

^cDifferent from corresponding value at week 5, $p = 0.042$.

^dDifferent from corresponding values at week 0, $p < 0.01$.

supported our clinical demonstration of a difference of infiltration between UV-irradiated and non-irradiated cicatrices. This indicates that these chosen collagen parameters are not correlated with the clinical results of cicatrices. Another explanation may be uncertainty of the biopsy-dividing method and artefacts arising during the dehydration- or formalin fixation-processes of the tissue. A previous wound healing study on rats showed significantly reduced HYP content in implant capsules in pre-operatively UVA-exposed wounds compared with controls (22), while a study on healing wounds in rabbits showed increased collagen fibre deposition and fibroblast formation in the UV-irradiated group vs. the non-irradiated group (19). However, the wound healing process in animals cannot be considered to develop as in man, and therefore results from the above animal studies cannot be applied directly to humans.

The mechanisms by which postoperative UV exposure interferes with the complex wound-healing process are far from clear; additional studies are needed for further elucidation. Microdissection could serve as a more precise way of obtaining pure scar tissue from the biopsies for the biochemical analyses. Furthermore, parameters other than the collagen amount and quality might influence the cosmetic result of the cicatrices and should be investigated. Finally, wound tensile strength could be added as another important clinical end-point.

In conclusion, this is the first human study to examine the effects of UV exposure on cicatrices after dermatological surgery. This randomized controlled study shows that postoperative sun exposure aggravates the clinical appearance of young cicatrices in humans. We recommend that wounds and cicatrices should not be exposed to sunlight during the postoperative wound-healing period.

ACKNOWLEDGEMENTS

We thank Peter Philipsen for his valuable help with statistical analyses and Rikke Roll for her excellent laboratory help. This work was supported by Bispebjerg Hospitals Forskningsudvalg, The Danish Foundation for Medical Research, Region of Copenhagen, The Faroe Islands and Greenland, Fonden Aksel Meyer Nielsen og Vetsera Meyer Nielsens Mindelegat, Hans og Noras Buchards Fond, and Aage Bangs Fond.

REFERENCES

1. Wiemer DR, Spira M. Ultraviolet light and hyperpigmentation in healing wounds. *Ann Plast Surg* 1983; 11: 328–330.
2. Wills EE, Anderson TW, Beattie BL, Scott A. A randomised placebo-controlled trial of ultraviolet light in the treatment of superficial pressure sores. *J Am Geriatr Soc* 1983; 31: 131–133.
3. Svedman C, Hammarlund C, Kutlu N, Svedman P. Skin suction blister wound exposed to u.v. irradiation: a burn wound model for use in humans. *Burns* 1991; 17: 41–46.
4. Wang JF, Olson ME, Reno CR, Kulyk W, Wright JB, Hart DA. Molecular and cell biology of skin wound healing in a pig model. *Connect Tissue Res* 2000; 41: 195–211.
5. Soter NA. Acute effects of ultraviolet radiation on the skin. *Semin Dermatol* 1990; 9: 11–15.
6. Fisher GJ, Datta SC, Talwar HS, Wang ZO, Varani J, Kang S, et al. Molecular basis of sun-induced premature skin ageing and retinoid antagonism. *Nature* 1996; 379: 335–339.
7. Fisher GJ, Datta S, Wang Z, Li XY, Quan T, Chung JH, et al. c-Jun-dependent inhibition of cutaneous procollagen transcription following ultraviolet irradiation is reversed by all-trans retinoic acid. *J Clin Invest* 2000; 106: 663–670.
8. Thomas DW, O'Neill ID, Harding KG, Sheperd JP. Cutaneous wound healing: a current perspective. *J Oral Maxillofac Surg* 1995; 53: 442–447.
9. Witte MB, Barbul A. General principles of wound healing. *Surg Clin North Am* 1997; 77: 509–528.
10. Fitzpatrick TB. Editorial: The validity and practicality of sun-reactive skin types I through IV. *Arch Dermatol* 1988; 124: 869–871.
11. McKinlay AF, Diffey BL. A reference action spectrum for ultraviolet induced erythema in human skin. *CIE J* 1987; 6: 17–22.
12. Wulf HC. Method and apparatus for determining an individual's ability to stand exposure to UV, US patent 1989; 4: 882, 598: 1–38.
13. Lock-Andersen J, Gniadecka M, De Fine Olivarius F, Dahlstrom K, Wulf HC. UV induced erythema evaluated 24 h post-exposure by skin reflectance and laser Doppler flowmetry is identical in healthy persons and patients with cutaneous malignant melanoma and basal cell cancer. *J Photochem Photobiol B*. 1997; 41: 30–35.
14. Jorgensen LN, Madsen SM, Gottrup F. Implantable wound healing models and the determination of subcutaneous collagen deposition in expanded polytetrafluoroethylene implants. In: DiPietro LA, Burns AL, eds. *Methods in molecular medicine. Wound healing: methods and protocols*. Vol. 78. Totowa, NJ: Humana Press Inc., 2002: p. 263–273.
15. Teisner B, Rasmussen HB, Hojrup P, Yde-Andersen E, Skjodt K. Fetal antigen 2: an amniotic protein identified as the aminopeptide of the alpha 1 chain of human procollagen type I. *APMIS* 1992; 100: 1106–1114.
16. Orum O, Hansen M, Jensen CH, Sorensen HA, Jensen LB, Horslev-Petersen K, et al. Procollagen type I N-terminal propeptide (PINP) as an indicator of type I collagen metabolism: ELISA development, reference interval, and hypovitaminosis D induced hyperparathyroidism. *Bone* 1996; 19: 157–163.
17. Brandt J, Krogh TN, Jensen CH, Frederiksen JK, Teisner B. Thermal instability of the trimeric structure of the N-terminal propeptide of human procollagen type I in relation to assay technology. *Clin Chem* 1999; 45: 47–53.
18. Brockis JG, Elliott M, Lissiman M. The rate of healing wounds treated with ultra-violet light. *Aust NZ J Surg* 1965; 35: 108–114.
19. El-Batouty MF, el-Gindy M, el-Shawaf L, Bassioni N, el-Ghaweet A, el-Emam A. Comparative evaluation of the effects of ultrasonic and ultraviolet irradiation on tissue regeneration. *Scand J Rheumatol* 1986; 15: 381–386.
20. Nordback I, Kulmala R, Jarvinen M. Effect of ultraviolet therapy on rat skin wound healing. *J Surg Res* 1990; 48: 68–71.
21. Basford JR, Hallman HO, Sheffield CG, Mackey GL. Comparison of cold-quartz ultraviolet, low-energy laser, and occlusion in wound healing in a swine model. *Arch Phys Med Rehabil* 1986; 67: 151–154.
22. Özcan G, Shenaq S, Chahadeh H, Spira M. Ultraviolet-A induced delayed wound contraction and decreased collagen content in healing wounds and implant capsules. *Plast Reconstr Surg* 1993; 92: 480–484.
23. Davidson SF, Brantley SK, Johnson SG, Hsu HS, Das SK.

- The effects of ultraviolet irradiation on wound contraction in the hairless guinea pig. *Br J Plast Surg* 1992; 45: 508–511.
24. Fagot D, Asselineau D, Bernerd F. Matrix metalloproteinase-1 production observed after solar-simulated radiation exposure is assumed by dermal fibroblasts but involves a paracrine activation through epidermal keratinocytes. *Photochem Photobiol* 2004; 79: 499–505.
 25. Quan T, He T, Kang S, Voorhees JJ, Fisher GJ. Solar ultraviolet irradiation reduces collagen in photoaged human skin by blocking transforming growth factor-beta type II receptor/Smad signaling. *Am J Pathol* 2004; 165: 741–751.
 26. Knuutinen A, Kokkonen N, Risteli J. Smoking affects collagen synthesis and extracellular matrix turnover in human skin. *Br J Dermatol* 2002; 146: 588–594.