

LETTERS TO THE EDITOR

Treatment of Ocular Cicatricial Pemphigoid with the Tumour Necrosis Factor Alpha Antagonist Etanercept

Sorilla Prey¹, Pierre-Yves Robert², Mireille Drouet³, Agnès Sparsa¹, Cyril Roux¹, Jean-Marie Bonnetblanc¹ and Christophe Bédane¹

Departments of ¹Dermatology, ²Ophthalmology, and ³Immunology, Hôpital Dupuytren, CHRU, FR-87042 Limoges, France

Accepted April 20, 2006.

Sir,

Cicatricial pemphigoid (CP) is a rare autoimmune sub-epithelial blistering disease that predominantly affects the mucous membranes with scarring (1). The disease is characterized by the involvement of muco-cutaneous sites, among them ocular involvement, which can lead to blindness. Mild forms of the disease may be controlled by anti-inflammatory drugs, such as dapsone, whereas severe forms, and particularly ocular involvement, usually require the use of immunosuppressive therapies (2). As tumour necrosis factor (TNF)- α plays a role in the fibrosing process, its targeting strategies are promising in the management of ocular CP. Here we report a case of ocular CP treated successfully with the TNF- α antagonist etanercept.

CASE REPORT

An 86-year-old woman presented with CP limited to her eyes. The onset of the disease was 20 years before it progressed to scarring conjunctivitis. Diagnosis was made by a conjunctival biopsy with direct immunofluorescence, showing linear deposits of IgG and C3 along the basement membrane zone. Circulating antibody was not found by indirect immunofluorescence analysis of the serum or by immunoblotting.

Her medical history included high blood pressure, dyslipidaemia, cataract, atopic dermatitis and chronic idiopathic purpura.

She was treated initially with local eyewash with vitamin A, cyclosporine and corticosteroid. She underwent several surgical interventions for entropion-trichiasis and a transplant of amniotic membrane on the left eye in 2000.

The patient was admitted to our department in 2001 because of an aggravation of her ocular CP. At the first examination both eyes showed a painful conjunctival hyperaemia (stage 4) and symblepharon stage IIIb of Foster's classification. Treatment with dapsone, 50 mg/day, was initiated, associated with monthly intravenous (i.v.) cyclophosphamide (750 mg/m²) followed by 50 mg/day oral cyclophosphamide. After two i.v. administrations, the patient described improvement in her sight, and the local inflammation decreased (stage 2). However, cyclophosphamide had side-effects, with asthenia, headache, nausea and vomiting after each bolus and for that reason the patient was lost to follow-up during 2 years. During this period, she was treated only with dapsone, and her visual status worsened.

On second referral she was almost blind. The conjunctivitis was more severe and painful (stage 4). Dapsone was therefore increased to 100 mg/day with i.v. cyclophosphamide (500, then 750 mg/m²), followed by 50 mg/day per os. After five more treatments, the tolerance remained poor, with permanent ocular pain and conjunctival fibrosis leading to stage IIIId symblepharon with trichiasis and corneal neovascularization (Fig. 1A).

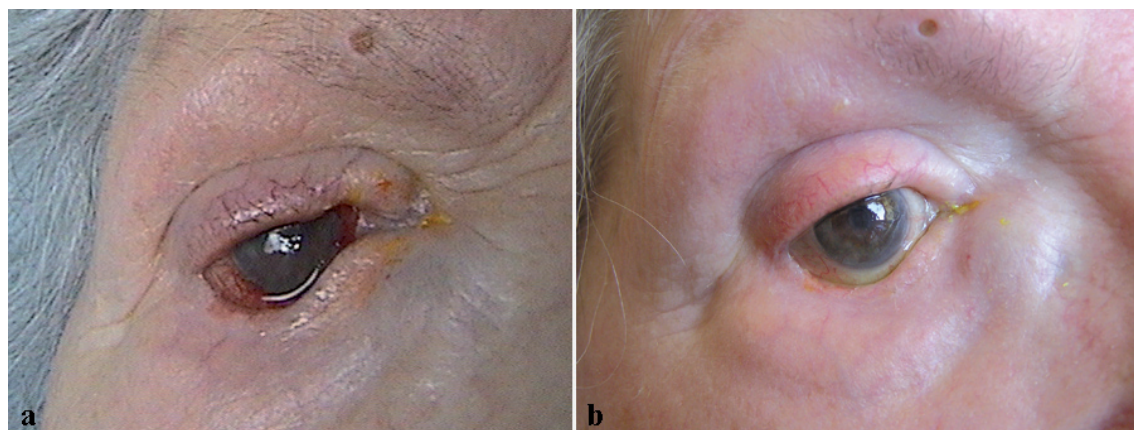


Fig. 1. (A) Conjunctival fibrosis leading to stage IIIId symblepharon with trichiasis and corneal neovascularization. (B) Improvement in both eyes after 6 months: conjunctival hyperaemia has disappeared and symblepharon of the right eye has decreased from stage IIIId to IIIa.

Etanercept (Wyeth, Aventis, Paris, France) was initiated in a regimen of 25 mg subcutaneous injections twice a week. Dapsone 100 mg/day was continued. Conjunctivitis and corneal neovascularization began to decrease after one month of treatment.

Six months later, both eyes had improved with disappearance of conjunctival hyperaemia, an improvement in vision, and even a decrease of symblepharon of her right eye from stage III_d to III_a (Fig. 1B). Tolerance and observance of the treatment was good, and neither side-effects (infection, tuberculosis or autoimmune manifestation) nor relapse were noticed during a 1-year follow-up during continued etanercept therapy.

DISCUSSION

The blistering process in CP is determined by the production of auto-antibodies directed against various basement membrane zone components (e.g. BP180 protein, laminin 5, laminin 6, type VII collagen, beta 4 integrin, 45kD protein, uncein, 168 kDa and 120 kDa epithelial protein) which are clearly pathogenic, as demonstrated on newborn mice (3–4). CP has a genetic predisposition with an association to HLA-DQ7 (DQB1*0301). The inflammatory response with the activation of the cytokine network, especially TNF- α , determines the outcome of scarring. Some studies have shown a high level of TNF- α and IL-6 in the serum of patients affected by CP (5). These abnormalities have also been reported in pemphigus and bullous pemphigoid (6–8), where anti-TNF- α therapy has been tried (9). The key role of TNF- α in fibrosis is well demonstrated in many organs (liver, kidney, etc.) and TNF- α as well as TGF- β also plays a pre-eminent role in the pathogenesis of various skin disorders (10).

To date there are very few treatments that are efficient at controlling the evolution of CP and particularly the fibrosing process. Due to the rarity of CP, no large comparative study can be set up. The published data is based largely on case reports or small retrospective series of patients. For the milder forms of the disease (affecting only the oral mucosa and/or the skin), local treatment and dapsone are usually sufficient to control the course of the disease. Patients with severe forms may need systemic corticosteroids and usually immunosuppressive drugs. Oral cyclophosphamide remains the drug of choice. Many other treatments have been proposed and evaluated in small series, e.g. salazopyrine, mycophenolate mofetil, azathioprine, cyclins or polyvalent immunoglobulins (11–12). Systemic corticosteroids can help to treat exacerbation of CP, but cannot be considered as a baseline treatment in CP. Most of these drugs have adverse effects that can be severe (13). Moreover, no therapy has been able to show anti-fibrotic activity, which is an essential requirement to prevent scar formation. In our patient etanercept showed a good

efficiency on isolated ocular CP. A similar patient has been reported by Sacher (14): a 72-year-old woman with an isolated oral involvement, who had contraindication or failure of conventional therapeutics. The treatment with etanercept together with oral methylprednisolone, 60 mg/day, allowed a complete recovery 2 months later, and a decrease in corticotherapy to 1 mg/day. There was no relapse after 8 months of detachment. This confirms the immunosuppressive effect and steroid-sparing effect of anti-TNF- α in the management of CP.

Conflict of interest: No conflicts of interest is reported.

REFERENCES

1. Chan LS. The first international consensus on mucous membrane pemphigoid: definition, diagnostic criteria, pathogenic factors, medical treatment, and prognosis indicator. *Arch Dermatol* 2002; 138: 370–379.
2. Ahmed M, Zein G, Khawaja F, Foster CS. Ocular cicatricial pemphigoid: pathogenesis, diagnosis and treatment. *Prog Retin Eye Res.* 2004; 23: 579–592.
3. Liu Z. A passive transfer model of the organ-specific autoimmune disease, bullous pemphigoid, using antibodies generated against the hemidesmosomal antigen, BP180. *J Clin Invest* 1993; 92: 2480–2488.
4. Lazarova L. Passive transfer of anti-laminin-5 antibodies induces subepidermal blisters in neonatal mice. *J Clin Invest* 1996; 98: 1509–1518.
5. Lee SJ. Serum levels of tumor necrosis factor-alpha and interleukin-6 in ocular cicatricial pemphigoid. *Invest Ophthalmol Vis Sci* 1993; 34: 3522–3525.
6. D'Auria L, Mussi A, Bonifati C, Mastroianni A, Giacalone B, Ameglio F. Increased serum IL-6, TNF-alpha and IL-10 levels in patient with bullous pemphigoid: relationships with disease activity. *J Eur Acad Dermatol Venereol* 1999; 12: 11–15.
7. D'Auria L, Bonifati C, Mussi A, D'Agosto G, De Simone C, Giacalone B, et al. Cytokines in the sera of patients with pemphigus vulgaris: interleukin-6 and tumour necrosis factor-alpha levels are significantly increased as compared to healthy subjects and correlate with disease activity. *Eur Cytokine Netw* 1997; 8: 383–387.
8. Lopez-Robles E. TNF alpha and IL6 are mediators in the blistering process of pemphigus. *Int J Dermatol* 2001; 40: 185–188.
9. Berookhim B. Treatment of recalcitrant pemphigus vulgaris with the tumor necrosis factor antagonist etanercept. *Cutis* 2004; 74: 245–247.
10. Diya F. Management of autoimmune bullous disease. *Pharmacology and therapeutics.* *J Am Acad Dermatol* 2004; 51: 859–877.
11. Kirtschig G. Interventions for mucous membrane pemphigoid / mucous membrane pemphigoid and epidermolysis bullosa acquisita: a systematic literature review. *Arch Dermatol* 2002; 138: 380–384.
12. Banno T. Effects of tumour necrosis factor-alpha (TNF alpha) in epidermal keratinocytes revealed using global transcriptional profiling. *J Biol Chem.* 2004; 279: 32633–32642.
13. Miserocchi E. The effect of treatment and its related side effects in patients with severe ocular cicatricial pemphigoid. *Ophthalmology* 2002; 109: 111–118.
14. Sacher C. Treatment of recalcitrant cicatricial pemphigoid with the tumor necrosis factor alpha antagonist etanercept. *J Am Acad Dermatol* 2002; 46: 113–115.