

Psoriasiform Drug Eruptions Under Anti-TNF Treatment of Arthritis are Not True Psoriasis

Julien Seneschal¹, Sebastian Lepreux², Marie-Laure Bouyssou-Gauthier¹, Isabelle Heliot-Hosten¹, Andra Economu³, Joel Dehais³, Thierry Schaevebeke³ and Alain Taïeb^{1*}

¹Departments of Dermatology, Saint André Hospital, University Hospitals of Bordeaux, Departments of ²Pathology and ³Rheumatology, Pellegrin Hospital, University Hospitals of Bordeaux, FR-33075 Bordeaux Cedex, France. *E-mail: alain.taieb@chu-bordeaux.fr
Accepted August 17, 2006.

Sir,

Anti-tumour necrosis factor (TNF) agents are attractive approaches to the treatment of auto-inflammatory disorders including psoriasis. Cutaneous side-effects resembling psoriasis or eczema have been reported, with various interpretations concerning a link with a true dermatological disorder, especially psoriasis (1–10). To clarify this issue, we report the detailed investigation of 8 patients with psoriasiform eruptions occurring during the administration of anti-TNF agents, including histopathological and immunohistochemical patch-test studies.

PATIENTS AND METHODS

Between July 2004 and September 2005, 8 patients (3 women, 5 men, mean age 45 years, age range 25–61 years) were enrolled in a prospective study. All patients were referred to the Department of Rheumatology from a cohort of 266 patients treated with TNF- α inhibitors. They were followed for rheumatoid arthritis (4 patients), ankylosing spondylitis (3 patients) and psoriatic arthritis (1 patient).

Anti-TNF- α agents were administered at the dosages recommended by their respective manufacturers. Other concomitant long-term medications included methotrexate and folic acid in 5 patients and low-dose corticosteroids in 2 patients. All patients responded well to anti-TNF- α agents.

All patients were patch-tested using Finn chambers with the European standard series and 2 anti-TNF agents (etanercept and infliximab) diluted 30% in water, following the recommendations of the European Society of Contact Dermatitis (11). A 0.2 ml volume of etanercept or infliximab was applied on a filter paper at the respective final concentrations of 7.5 mg/ml and 5 mg/ml, respectively. Etanercept and concomitant immunosuppressant medications had been stopped 15 days before tests and infliximab 4 weeks before. Tests were read at 48 h and at day 8 by the same doctor. No prick or intradermal tests were performed. When patch tests were positive, lesions

were photographed and histological samples were taken. Punch biopsy specimens were processed for standard and immunohistochemical analyses.

Biopsy specimen (eruption and tests) were stained with anti-CD3 (T cells), anti-CD4 (helper T cells), anti-CD8 (cytotoxic T cells), anti-CD20 (B cells) and anti-HLA-DR monoclonal antibodies.

RESULTS

Four patients had been treated with etanercept, 3 with infliximab and one with adalimumab. None had a personal history of eczema or cutaneous drug reaction. Only one had a personal history of psoriasis and another one a family history of psoriasis. Three patients had a family history of atopic or contact dermatitis (Table I). The time elapsed from initiation of therapy to appearance of skin lesions was variable: 8–26 months for infliximab therapy, 2–24 months for etanercept and 7 months for adalimumab. All patients developed eruptions that resembled small plaque psoriasis (Fig. 1a). The lesions did not develop at injection sites. A recurrence of skin lesions was observed after new injections of the same anti-TNF agent in 4 patients. Due to the highly beneficial effect on joint inflammation, psoriasiform eruptions did not justify discontinuation of anti-TNF- α treatment. In 3 cases (patients 1, 3 and 4), treatment was stopped because of another adverse reaction, namely immune keratitis. In one of these patients (no. 4), skin lesions persisted in spite of infliximab being stopped for one year. Antinuclear antibody titres were evaluated before TNF- α inhibitor treatment and during psoriasiform eruption. Three patients (nos. 1, 5 and 6) had a significant increase in titre (Table I).

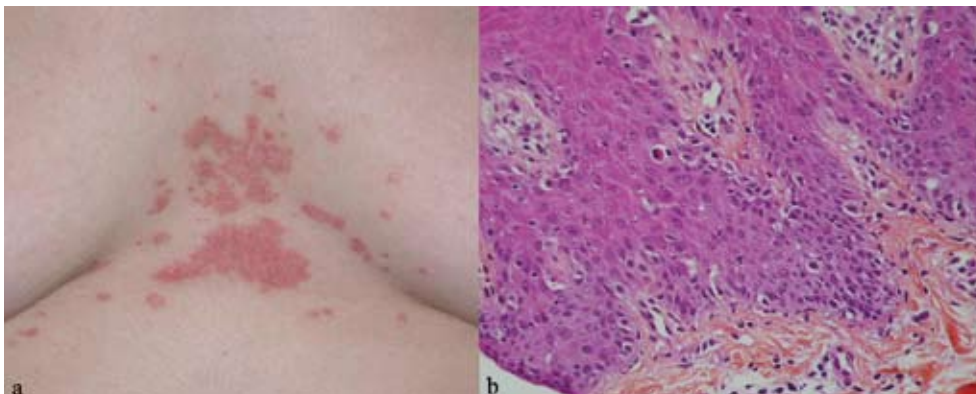


Fig. 1. Patient 4: (a) psoriasiform eruption induced by anti-tumour necrosis factor (TNF) agents on the chest. (b) Histological features: parakeratosis, acanthosis, lichenoid and spongiotic pattern, necrotic keratinocytes.

Table I. Descriptions of the 8 patients and patch test results

| Patient No/ Diagnosis/ age/sex | Personal/family history | Anti-TNF agent | Months ¹ | Type of eruption | Patch tests | | Findings at patch test | ANA | | | |
|-----------------------------------|----------------------------|-------------------|---------------------|------------------|-------------|---|---------------------------|--------------------------------|---|--------|--------|
| | | | | | 48-h | Day 8 | | Start of anti-TNF- α | At time of eruption | | |
| | duration (years) | Psoriasis Eczema | | | | | | | | | |
| 1/35/F | RA/3 | -/- | -/- | ETA | 2 | Psoriasiform plaques legs, trunk, scalp | - | + | Erythematous limited plaques on shoulder area | 1/100 | 1/500 |
| 2/59/M | AS/17 (HLA B 27+) | -/- | -/- | INF | 18 | Guttate scalp, legs, trunk, and PPP | - | + | Pustulosis on arms and extremities | 1/50 | 1/100 |
| 3/45/M | RA/4 | -/- | -/- | ADA | 7 | Psoriasiform plaques scalp PPP | + ² | - | Edema and vesicles on patch test site | - | - |
| 4/26/F | AS/5 (HLA B 27-) | -/+ ³ | -/- | INF | 8 | Plaques and widespread guttate psoriasis-like eruptions | - | + | Erythematous and limited plaques on shoulder area | - | 1/50 |
| 5/48/M | PA/25 (HLA B 27+) | +/- | -/- | INF | 26 | Psoriasis elbows and legs | - | - | - | - | 1/500 |
| 6/61/M | AS/30 (HLA B 27+) | -/- | -/+ | INF | 26 | Extensive plaques PPP hyperkeratosis skin folds lesions | - | - | - | 1/100 | 1/250 |
| 7/30/F | RA/13 | -/- | -/+ | ETA | 18 | Plaques, psoriasiform lesions elbows, knees, fingers | - | + | Erythematous limited plaques on shoulder area | 1/1000 | 1/1000 |
| 8/59/M | RA/6 | -/- | -/- | ETA | 24 | Erythematous plaques arms trunk | - | - | - | 1/50 | 1/50 |

Patients numbers 1–4 and 7 have received methotrexate as concomitant medication.

¹Months after treatment initiation; ²etanercept; ³2nd degree.

Anti-TNF, anti-tumour necrosis factor; RA, rheumatoid arthritis; AS, ankylosing spondylitis; PA, psoriatic arthritis; INF, infliximab; ETA, etanercept; ADA: adalimumab; ANA: anti-nuclear antibodies; PPP: palmoplantar pustulosis.

No positive reactions were observed with standard patch-test series in 6 cases. One patient reacted to nickel and another to balsam of Peru at 48 h. Patient 3 only reacted to etanercept patch tests at 48 h and presented oedema and vesicles. He had no reaction with infliximab. Readings at day 8 showed positive results in 4/8 cases (Table I).

Two patients declined a skin biopsy of the eruption. All biopsy specimens showed epidermal hyperplasia, parakeratosis and spongiosis. A lichenoid pattern (Fig. 1b) was observed in 3 patients (nos. 1, 4 and 7). These changes were less marked in other biopsy specimens. A total of 5/6 biopsy specimens showed a predominantly lymphomononuclear cell infiltrate with a perivascular pattern without eosinophils. In patient 5 a psoriasiform eruption on the legs showed a lichenoid and spongiotic pattern, whereas that of the elbow showed a psoriatic pattern.

Skin biopsy samples from distant reactions after patch testing showed comparable histological features made of acanthosis and parakeratosis, spongiosis, necrotic keratinocytes and a lymphocytic infiltrate in the upper dermis with predominantly perivascular pattern and exocytosis within the epidermis. The biopsy sample of the patch test positive to etanercept in patient 7 at day 8 contained a moderate number of eosinophils. Patient 3 declined the biopsy.

In eruption and test biopsies, most of the cells of the perivascular or lichenoid infiltrates had an HLA-DR+/CD3+

phenotype. The cells of the lichenoid infiltrates were also CD8+, indicating an activated mature cytotoxic T lymphocytes lineage. Fifty percent of the dermal cells expressed CD4 consistent with a mature helper T-lymphocyte lineage while the other half of the infiltrate expressed CD8. In most of the biopsy specimens, only a few keratinocytes expressed HLA DR (between 5% and 15%).

DISCUSSION

Several cases of psoriasiform eruptions induced by anti-TNF- α agents have been reported (1–10). In some reports, clinical and histological findings were compatible with psoriasis, where others describe lichenoid drug reaction. In our series, we have arguments for a drug reaction including chronology of events, delayed-type patch-test positivity, the recurrent eruption after new injections (in 4/8 cases), and the remission obtained once treatment was curtailed. Histopathology was consistent with a mostly lichenoid/spongiotic drug reaction. Positive patch-test findings in 4/8 cases reproducing the clinical and histological features, are a strong argument in favour of this hypothesis. The strong inhibitory effect of anti-TNF- α on local patch-test responses could be compared with the effect of topical corticosteroid to explain the predominant delayed-type positivity at distant sites (12). Vergara & Silvestre (13) suggested

the systemic uptake of anti-TNF- α agents applied cutaneously. However, the cross-reaction to etanercept noted in the patient treated with adalimumab suggests that the observed side-effects could be due also to a class effect of the drugs/antibodies/proteins.

Antibodies against anti-TNF- α agents have already been detected (14), although no correlation between these antibodies and the development of complications has been established to date. Anti-DNA auto-antibodies formed during TNF- α blockade are frequent (15). However, the development of drug-induced lupus-like syndrome is rare. In our study, psoriasiform eruptions did not correlate with an increased titre of anti-nuclear antibodies.

ACKNOWLEDGEMENT

The follow-up of the patients was supported by a regional PHRC grant to Thierry Schaeveerbeke.

REFERENCES

1. Dereure O, Guillot B, Jorgensen C, Cohen JD, Combes B, Guilhou JJ. Psoriatic lesions induced by antitumour necrosis factor-alpha treatment: two cases. *Br J Dermatol*. 2004; 150: 506–507.
2. Vereza MM, Del Pozo J, Yebra-Pimentel MT, Porta A, Fonseca E. Psoriasiform eruption induced by infliximab. *Ann Pharmacother* 2004; 38: 54–57.
3. Thurber M, Feasel A, Stroehlein J, Hymes SR. Pustular psoriasis induced by infliximab. *J Drugs Dermatol* 2004; 3: 439–440.
4. Beuthien W, Mellinshoff HU, von Kempis J. Skin reaction to adalimumab. *Arthritis Rheum* 2004; 50: 1690–1692.
5. Grinblat B, Scheinberg M. Unexpected onset of psoriasis during infliximab treatment: comment on the article by Beuthien et al. *Arthritis Rheum* 2005; 52: 1333–1334.
6. Sfikakis PP, Iliopoulos A, Elezoglou A, Kittas C, Stratigos A. Psoriasis induced by anti-tumor necrosis factor therapy: a paradoxical adverse reaction. *Arthritis Rheum* 2005; 52: 2513–2518.
7. Dumont-Berset M, Laffite E, Gerber C, Dudler J, Panizzon RG. Eczematous drug eruption after infliximab. *Br J Dermatol* 2004; 151: 1272–1273.
8. Kary S, Worm M, Fritz J, Audring H, Scherer HU, Lee HH, et al. New onset or aggravating of psoriatic skin lesions in patients with definitive rheumatoid arthritis under treatment with TNF α antagonists: report of 8 cases [abstract]. *Ann Rheum Dis* 2004; suppl 63: 276.
9. Haibel H, Spiller I, Strasser C. Unexpected new onset or exacerbating of psoriasis treatment of active ankylosing spondylitis with TNF α blocking agents [abstract]. *Ann Rheum Dis* 2004; suppl 63: 405.
10. Baeten D, Kruithof E, Van den Bosch F, Van den Bossche N, Herssens A, Mielants H, et al. Systematic safety follow up in a cohort of 107 patients with spondyloarthritis treated with infliximab: a new perspective on the role of host defense in the pathogenesis of the disease? *Ann Rheum Dis* 2003; 62: 829–834.
11. Barbaud A, Goncalo M, Bruynzeel D, Bircher A. European Society of Contact Dermatitis. Guidelines for performing skin tests with drugs in the investigation of cutaneous adverse drug reactions. *Contact Dermatitis* 2001; 45: 321–328.
12. Reitamo S, Lauerma AI, Stubb S, Käyhkö K, Visa K, Förström L. Delayed hypersensitivity to topical corticosteroid. *J Am Acad Dermatol* 1986; 14: 582–589.
13. Vergara G, Silvestre JF. Cutaneous drug eruption to infliximab: report of 4 cases with an interface dermatitis pattern. *Arch Dermatol* 2002; 138: 1258–1259.
14. Cheifetz A, Mayer L. Monoclonal antibodies, immunogenicity, and associated infusion reactions. *Mt Sinai J Med* 2005; 72: 250–256.
15. Atzeni F, Turiel M, Capsoni F, Doria A, Meroni P, Sarzi-Puttini P. Autoimmunity and Anti-TNF alpha agents. *Ann NY Acad Sci* 2005; 1051: 559–569.