

Diagnosis and Treatment of Post-caesarean Scar Endometriosis

Iria Neri, Michela Tabanelli, Emi Dika, Gaspari Valeria and Annalisa Patrizi*

Department of Specialistic and Experimental Clinical Medicine, Division of Dermatology, University of Bologna, S. Orsola – Malpighi University Hospital, Via G. Massarenti 1, IT-40138 Bologna, Italy. *E-mail: annalisa.patrizi@unibo.it
Accepted February 5, 2007.

Sir,

Endometriosis is a common disease that involves approximately 10–15% of women of reproductive age. It is defined as an ectopic implantation of endometrial tissue (glands and stroma) outside the uterus, causing dyspareunia, dysmenorrhoea, menstrual irregularities and infertility. It is frequently detected in the pelvic organs, such as the peritoneum, the ovaries, the pouch of Douglas and the uterosacral ligaments (1).

Extra-pelvic endometriosis is a rare condition. It is reported most frequently in the gynaecological and surgical literature (2). The possible sites are, in order of frequency, the abdominal wall, the bowel, the peritoneum, the omentum, the umbilicus, the hernia sacs, the bladder, the kidney, the lungs, the pleura and the extremities (1, 3, 4). The most common locations of abdominal wall endometriomas are old surgical scars from obstetric or gynaecological procedures. Scar endometriosis presents clinically as a painful, palpable subcutaneous mass, associated with cramps and bloating during menses. It is easily confused with other conditions, such as keloids, haematoma, stitch granuloma, abscess, inguinal and incisional hernia (5). Caesarean scar endometriosis is the most frequently reported form of this disorder and is usually benign, although a malignant transformation has been reported (4).

CASE REPORT

We report here a case of a 47-year-old woman with a painful and sensitive nodular mass on a caesarean scar, present for the last 3 months. She reported that the nodule had begun with a small reddish spot and had gradually increased in volume. The patient stated that the nodule pain became more severe during the menstrual cycle and de-ambulation. Personal history revealed that a caesarean section had been performed 12 years previously, at the 32nd week of gestation due to early signs of gestosis. Previously she had had a spontaneous abortion. The patient had no history of other diseases and was otherwise healthy.

Physical examination revealed a 16×9×14 mm, red, tender, subcutaneous mass in the midline of the vertical caesarean scar. The overlying skin was normal (Fig. 1).

Echography and colour Doppler examinations of the soft tissue of the abdominal wall were performed. These showed a varied picture of hypoechoic mass with irregular morphology. In addition vascular satellite

arterial structures were reported. An incisional biopsy showed an endometriosis of the skin. Iron Prussian blue staining confirmed the presence of hemosiderin deposits. Consequently a complete local excision of the mass was performed and histological examination showed foci of endometrial glands surrounded by myxoid stroma with an abundant presence of mesenchymal cells and siderophages (Fig. 2). An immunohistological study was positive for cytokeratin 7 and for CD 10 in the surrounding cytotrogen stroma.

DISCUSSION

Extra-pelvic endometriosis, is most commonly seen after surgical procedures on the uterus and Fallopian tubes. Cutaneous scar endometriosis following caesarean section is the most frequent cutaneous form, with an incidence of 0.03–0.4% (6). The literature reports that the average time from surgery to clinical presentation may vary from 3 months to 12 years in different cases. The cause of endometriosis remains controversial, and gives rise to many theories, such as the role of the immune system with the drop in the regulatory capacity of natural killer cells and the mechanical transportation of the cells after gynaecological procedures (7). Another theory suggests that oestrogen stimulation of the scar plays an important role in the development of the endometriomas. The coexistence of pelvic endometriosis and scar endometriosis is rare, but can occur (6).

Recently, Francica et al. (8) reported that the use of sonographic and colour Doppler examinations, in

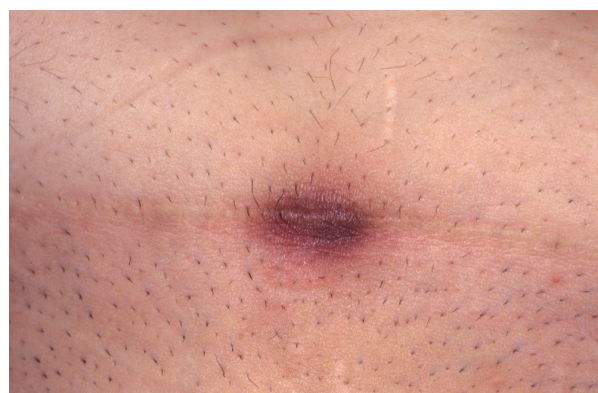

Fig. 1. A red, tender, subcutaneous mass in the midline of the vertical caesarean scar. The overlying skin was normal.

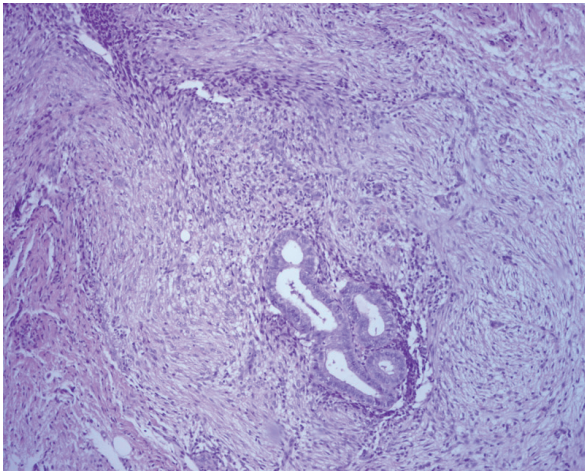


Fig. 2. Foci of endometrial glands surrounded by myxoid stroma with an abundant presence of mesenchymal cells and siderophages (H&E $\times 20$).

addition to the clinical data, may substantially help to reach a reliable pre-operative diagnosis.

Another recent study has underlined the usefulness of gray-scale ultrasonography combined with colour Doppler, which has a fine resolution in the diagnosis of scar endometriosis and usually shows an irregular shape, with non-homogeneous hypoechogenic density and alterations in peripheral vascularization (9).

The use of computed tomography (CT) scan and magnetic resonance imaging (MRI) may also contribute to the correct diagnosis. A solid, well-circumscribed lesion is the typical aspect seen in CT. MRI may be more useful for small lesions, because of its high spatial resolution; MRI allows a better distinction between the muscles and the subcutaneous tissue than CT (10).

A biopsy should, in any case, be performed after the ultrasonographic examination. The histological examination usually reveals endometrial glands with stroma in the excised lesion (11).

Management of scar endometriosis usually includes wide excision and hormonal suppression. When the complete excision of the endometriomas gives a total resolution, medical treatment is not significant. In fact, in the literature, the use of progesterone, contraceptive pills, and diazole has been reported as ineffective. Recently, the use of a gonadotrophin agonist has been proposed, with a prompt improvement in symptoms but with no change in the lesion size (12).

In our case the lesion appeared 12 years after the caesarean scar, a very long period. This leads us to the hypothesis that the mechanical migration theory played an important role in the development of the disease, since it appeared on the caesarean scar (a low-resistance point) after many years.

The diagnosis of scar endometriosis based solely on data from the medical history and clinical examination is difficult. In this patient the echography and colour Doppler of the lesion helped us to formulate the diagnosis by showing a hypoechoic mass with vascular abnormalities, such as the arterial satellite structures. These echographic findings are similar to those of other cases reported in the literature (8). We performed a complete excision of the lesion and a total resolution was obtained. No other treatment was necessary.

The patient should be informed of the high rate of recurrence of this disorder. Follow-up should be arranged for those patients who present multiple recurrences, in order to avoid any chance of malignant transformation (4).

REFERENCES

1. Goel P, Sood SS, Romilla Dalal A. Cesarean scar endometriosis. Report of two cases. *Indian J Med Sci* 2005; 59: 495–498.
2. Luisi S, Gabbanini M, Sollazzi S, Colataci F, Razzi S, Petraglia F. Surgical scar endometriosis after cesarean section: a case report. *Gynecol Endocrinol* 2006; 22: 284–285.
3. Gunes M, Kayikcioglu F, Ozturkoglu E, Haberal A. Incisional endometriosis after cesarean section, epistomy and other gynecologic procedures. *J Obstet Gynaecol Res* 2005; 31: 471–475.
4. Leng J, Lang J, Guo L, Li H, Liu Z. Carcinosarcoma arising from atypical endometriosis in a cesarean section scar. *Int J Gynecol Cancer* 2006; 16: 432–435.
5. Adamo V, Di Natale W, Meola C, Gilio M, Cavalli S, Ferrari L, et al. Endometriosis in an epistomy scar: a case report. *Chirurg Ital* 2004; 56: 735–738.
6. Chatterjee SK. Scar endometriosis: a clinicopathological study of 17 cases. *Obstet Gynecol* 1980; 56: 81–84.
7. Hernandez Valencia M, Zarate A, Hernandez Quijano T, Laniero Mtes de Oca ME, Escamilla Godinez G. Edometriosis in delayed scarring of postpartum eutocis episiorrhaphy. Integral aspect and a case report. *Rev Med Inst Mex Seguro Soc* 2005; 43: 237–242.
8. Francica G, Giardiello C, Angelone G, Cristaino S, Finelli R, Tramontano G. Abdominal wall endometriomas near cesarean delivery scars: sonographic and color Doppler findings in a series of 12 patients. *J Ultrasound Med* 2003; 22: 1041–1047.
9. Wu YC, Tsui KH, Hung JH, Yuan CC, Ng HT. High-frequency power Doppler angiographic appearance and microvascular flow velocity in recurrent scar endometriosis. *Ultrasound Obstet Gynecol* 2003; 21: 94–99.
10. Balleyguier C, Chapron C, Chopin N, Helenon O, Menu Y. Abdominal wall and surgical scar endometriosis. Results of magnetic resonance imaging. *Gynecol Obstet Invest* 2003; 55: 220–224.
11. Hussain M, Noorani K. Primary umbilical endometriosis. A rare variant of cutaneous endometriosis. *J Coll Physician Surg Pak*. 2003; 13: 164–165.
12. Rivlin ME, Das SK, Patel RB, Meeks GR. Leuprolide acetate in the management of cesarean scar endometriosis. *Obstet Gynecol* 1995; 85: 838–839.