

Median Raphe Cyst with Ciliated Cells of the Penis

Kaori Koga¹, Yuichi Yoshida², Monji Koga¹, Morishige Takeshita³ and Juichiro Nakayama¹

Departments of ¹Dermatology and ³Pathology, Fukuoka University School of Medicine, 7-45-1 Nanakuma, Jonan-ku, Fukuoka 814-0180, and ²Department of Dermatology, Faculty of Medicine, Tottori University, Yonago, Japan. E-mail: dermatol@fukuoka-u.ac.jp
Accepted February 5, 2007.

Sir,

Median raphe cysts of the penis are uncommon benign lesions that affect young men. The cysts are lined with pseudostratified columnar or stratified squamous cell epithelium, mimicking the epithelial lining of the male urethra. Immunohistochemical study also indicates a histogenetic relationship with the urothelium. To our knowledge, there have been only 2 reports of ciliated epithelium in this kind of cyst published previously (1, 2). We describe here a rare case of median raphe cyst of the penis with ciliated cells, and discuss the histopathological and immunohistochemical features.

CASE REPORT

A 27-year-old man was referred to our hospital for evaluation of an asymptomatic nodular lesion on the glans penis. He had been aware of a slow-growing lesion at puberty. There was no antecedent history of trauma or infection. Physical examination revealed a smooth, soft, painless cystic nodule, 3.0 cm in diameter on the ventral surface of the penis (Fig. 1). The lesion was excised surgically under local anaesthesia.

Histopathological examination showed an irregularly shaped empty cystic space in the middle dermis (Fig. 2a). No connection with the epidermis was evident. The cyst wall was lined with pseudostratified ciliated columnar epithelium (Fig. 2b). An immunohistochemical study was performed using a standard avidin-biotin peroxidase method. The luminal cells at the apical border were positive for CK7 (Fig. 3a), carcinoembryonic antigen (CEA) (Fig. 3b) and epithelial membrane antigen (EMA). No positive staining was obtained in the epithelium by CK20, α -smooth muscle actin (α -SMA), anti-S100 protein and

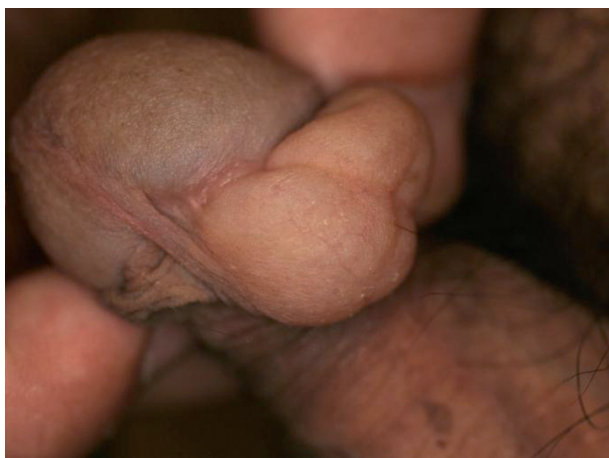

Fig. 1. A soft cystic nodule on the ventral aspect of the penis. The glans is seen to the left side and the rest of the penis is down to the right side. The nodule is cross at the frenulum.

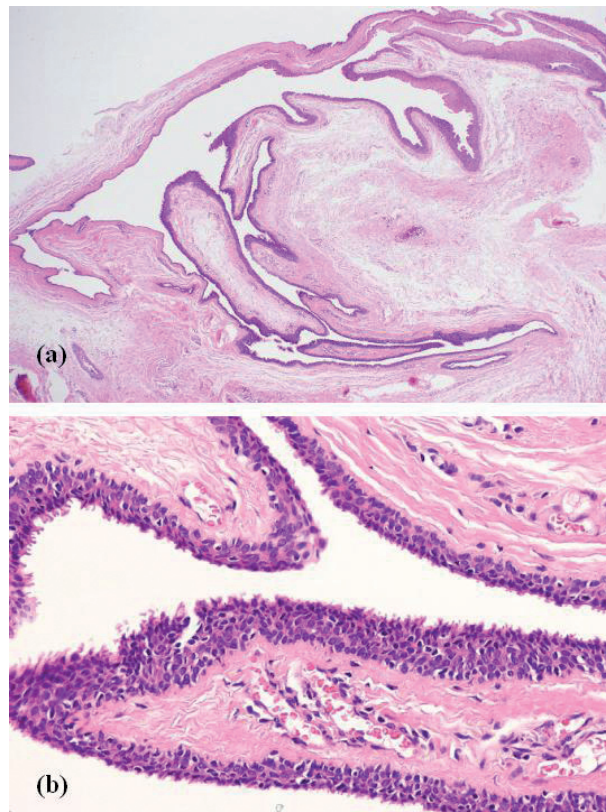


Fig. 2. (a) An irregularly shaped cystic space in the middle dermis (haematoxylin and eosin (H&E) $\times 20$). (b) Ciliated columnar cells in the inner lining of the cyst wall (H&E $\times 100$).

GCDFP-15 (not shown). A diagnosis of median raphe cyst with ciliated cells was made on the basis of these findings.

DISCUSSION

Median raphe cysts are relatively rare midline cysts of the male genitalia found at any point from the external urethral meatus to the anus and considered to be an embryological developmental abnormality (3). They develop mainly on the ventral aspect of the penis in young men (4). Histological study usually reveals the presence of irregular cystic cavity. Their epithelial lining cells consist of columnar stratified, pseudostratified or squamous cells, according to the urethral segment origin of the lesion (3). In the present case, we found CK7⁺, CEA⁺, and EMA⁺ ciliated columnar cells in the lining of the cyst wall.

Ciliated epithelial cells are present in the respiratory tract, middle ear, uterus and oviducts, ependymal epithel-

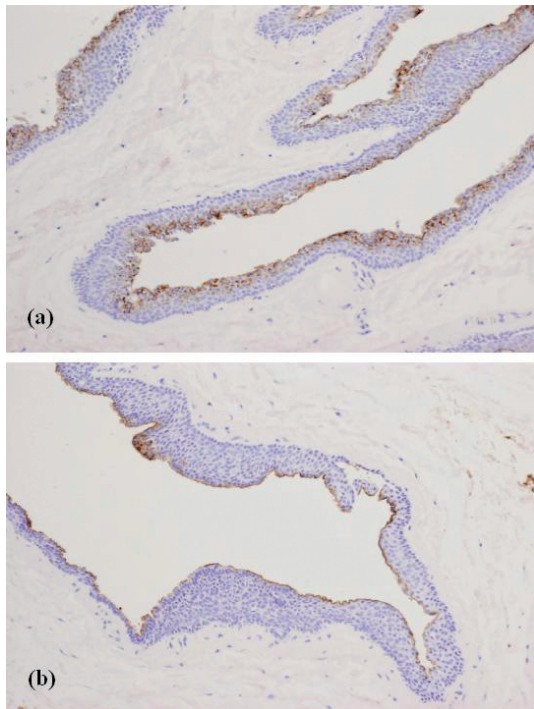


Fig. 3. Apical epithelial cells were diffusely stained by (a) CK7 and (b) carcinoembryonic antigen ($\times 100$).

lium of the central nervous system and ductulus efferens of the testis in human adults (5). Several developmental cutaneous cystic lesions in the skin, which have a ciliated columnar epithelium, have been reported (6–8). They have been given various names, such as bronchogenic cysts, vulvar cysts and cutaneous ciliated cysts according to their topographical location. Differential diagnosis of our case includes cutaneous ciliated cysts. However, cutaneous ciliated cysts typically affect the lower extremities or buttocks of women and have been regarded as Mullerian remnants (7). In men, the origin

is thought to be ciliated metaplasia of the eccrine sweat glands. In our case, immunostaining for CK7 confirmed a urothelial interpretation and immunostaining for CEA is probably related to the dysembryogenic cloacal nature, suggesting a median raphe cyst as well as the results found in other studies (9, 10). Ciliated cells of a median raphe cyst are considered to be derived from metaplastic changes in the urothelium, secondary to irritation or local stimulation (2, 5).

REFERENCES

1. Romani J, Barnadas MA, Miralles J, Curell R, Moragas JM. Median raphe cyst of the penis with ciliated cells. *J Cutan Pathol* 1995; 22: 378–381.
2. Acenero MJ, Garcia-Gonzalez J. Median raphe cyst with ciliated cells: report of a case. *Am J Dermatopathol* 2003; 25: 175–176.
3. Nagore E, Sanchez-Motilla JM, Febrer MI, Aliaga A. Median raphe cysts of the penis: a report of five cases. *Pediatr Dermatol* 1998; 15: 191–193.
4. Otsuka T, Ueda Y, Terauchi M, Kinoshita Y. Median raphe (parameatal) cysts of the penis. *J Urol* 1998; 159: 1918–1920.
5. Che M, Ro JY, Ordonez NG, Miller RW, Ayala AG. Ciliated epithelia in the urethra: case report and literature review. *Pathol Int* 2001; 51: 892–895.
6. Kural YB, Ergun S, Buyukbabani N, Durmusoglu R, Onsun N. Cutaneous bronchogenic cysts. *Int J Dermatol* 1998; 37: 137–140.
7. Fontaine DG, Lau H, Murray SK, Fraser RB, Wright JR. Cutaneous ciliated cyst of the abdominal wall: a case report with a review of the literature and discussion of pathogenesis. *Am J Dermatopathol* 2002; 24: 63–66.
8. Lee JS, Kim YC, Lee ES. Cutaneous ciliated cyst of the inguinal area in a man. *J Dermatol* 2006; 33: 146–149.
9. Dini M, Baroni G, Colafranceschi M. Median raphe cyst of the penis: a report of two cases with immunohistochemical investigation. *Am J Dermatopathol* 2001; 23: 320–324.
10. Cardoso R, Freitas JD, Reis JP, Tellechea O. Median raphe cyst of the penis. *Dermatol Online J* 2005; 11: 37.