

Acute Urticaria Associated with Amoeboid Forms of *Blastocystis* sp. Subtype 3

Alexandra Katsarou-Katsari¹, Constantine M. Vassalos^{3,4*}, Konstantina Tzanetou², Gregory Spanakos³, Chryssanthi Papadopoulou⁴ and Nicholas Vakalis³

¹Department of Dermatology, University of Athens, "A. Sygros" Hospital, ²General Hospital "G. Gennimatas", ³Department of Parasitology, Entomology and Tropical Diseases, National School of Public Health, Athens, and ⁴Department of Microbiology, Medical School, University of Ioannina, Dourouti University Campus, GR-45110 Ioannina, Greece. *E-mail: conniva@hotmail.com. The first two authors have contributed equally to this paper and should be considered as first authors.

Accepted June 5, 2007.

Sir,

Acute urticaria characterized by whealing lasting up to 6 weeks is a common condition, which can be caused by various factors. Although intestinal parasites are a possible cause, there is only one published report concerning the role of *Blastocystis* sp. in acute urticaria (1).

It is not known whether the common human intestinal protozoan *Blastocystis* should be regarded as a mere commensal organism or a potential pathogen (2, 3). *Blastocystis* has been found both in patients with gastrointestinal symptoms and in asymptomatic individuals (3, 4). However, extra-intestinal manifestations, such as chronic urticaria and other skin lesions, have been reported (1, 3, 5–9). We present here a patient infested with *Blastocystis* sp. identified as subtype 3 producing amoeboid forms throughout cultivation, who presented with acute urticarial lesions together with minor gastrointestinal symptoms.

CASE REPORT

A 19-year-old Caucasian male with hives of 3 weeks' duration presented with itchy wheals over his body and extremities. He had no trouble swallowing or breathing. His personal and family history was negative for nasal allergies, asthma, allergy and hypersensitivity to particular foods or drugs. He had not previously experienced urticaria and did not take any drugs during or prior to the episode of urticaria. There was no history of fever, arthralgia or insect bites prior to onset of symptoms. He had no pets and had not travelled recently. On further questioning, the patient noted that his stools were becoming softer. He also reported having experienced abdominal pain for approximately 2.5 months, but had tolerated this and therefore had not visited the doctor with the abdominal symptoms. The patient was otherwise healthy, with no hypotension. Dermatological examination revealed urticarial eruptions on his trunk and extremities. Dermographism was negative. As the diagnosis was compatible with acute urticaria, laboratory tests to identify an underlying cause were performed. An elimination diet was prescribed. The patient was commenced on oral desloratadine (5 mg, every morning) and oral levocetirizine (5 mg, every night). On review 4 days later, he was still taking antihistamine drugs with no relief of symptoms. Routine haematological and biochemical screening tests were within normal limits. There were no indications of hepatic, renal, autoimmune or endocrinological diseases. Total immunoglobulin E (IgE) levels were in the normal range. The elimination diet gave no positive result. A decrease in stool consistency was observed visually. Stool examination disclosed the presence of *Blastocystis* sp., but no other pathogen intestinal parasites. The patient had 5 *Blastocystis* per high power field. Oral metronidazole treatment

was started (750 mg 3 times a day). The parasite was isolated by *in vitro* cultivation using Robinson's medium. By day 2 parasite culture, up to 7% of the protozoa were present as amoeboid forms of *Blastocystis*. Genotype analysis identified *Blastocystis* sp. isolate as subtype 3. Following treatment day 3, oral metronidazole was continued for one more week. Although urticarial eruptions had not improved despite regular use of antihistamine drugs, one week after starting oral metronidazole treatment the patient experienced an amelioration of his symptoms. One week later, the patient reported that the urticaria had almost completely resolved since finishing the metronidazole. The minor gastrointestinal symptoms had also disappeared. His stools returned to normal. Results of subsequent stool examination were negative for *Blastocystis* sp. Oral desloratadine was discontinued one week after the end of metronidazole treatment, and 10 days after finishing the metronidazole, oral levocetirizine was also ceased. Despite stopping antihistamine drugs, no relapse has been observed.

DISCUSSION

Although *Blastocystis* sp. has been implicated in several specific intestinal disorders, including enteritis and colitis (3), non-specific symptoms, such as diarrhoea, abdominal cramps and nausea, have also been attributed to *Blastocystis* infection (4). In addition, *Blastocystis* has been associated with otherwise healthy individuals suffering from irritable bowel syndrome (IBS) (4). However, people with IBS rarely seek medical attention

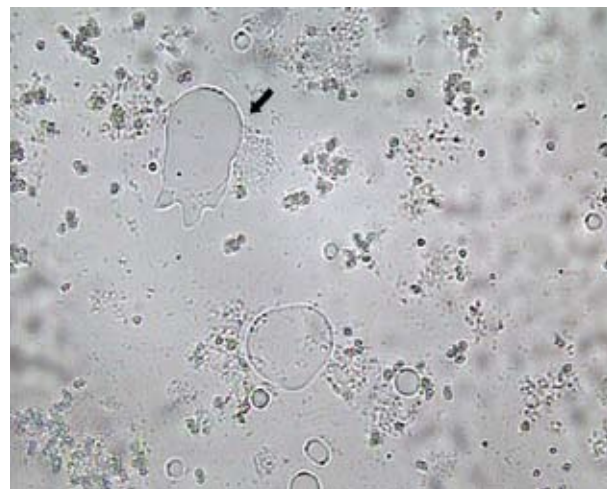


Fig. 1. Light micrograph of amoeboid forms of *Blastocystis* presented in culture using Robinson's medium (×400). The amoeboid form with prominent, extended pseudopodia is clearly visible (arrow).

(10). Since only a possible correlation has been found, it has been assumed that only some *Blastocystis* sp. genotypes might have relevant pathogenicity (11). In symptomatic patients, amoeboid forms of *Blastocystis* sp. might adhere to the epithelial cells lining the gut (4, 12). Amoeboid forms of *Blastocystis* have been detected both in patients with diarrhoea and in colonoscopy samples (12, 13). It can be speculated that amoeboid forms might affect gut immune homeostasis maintained by both enterocytes and different gastrointestinal immune cells (1). There may be an immune response (1) against carbohydrate antigens on the surface coat (4) that is thought to surround the amoeboid forms (12, 13). Furthermore, in active inflammation, inflammatory cell recruitment and accumulation might occur (1, 3). Urticaria could result from a variety of pathophysiological mechanisms. The activation of cutaneous mast cell degranulation is a complicated mechanism, which has not yet been elucidated. Histamine-releasing factors could be released by immigrant cells and activate mast cells and basophils (14). One case report concerning specific IgE-mediated chronic urticaria due to *Blastocystis* has been published (9). Furthermore, antigens might cause urticaria, and concomitant exposure could precipitate this reaction by increasing antigen absorption or by modulating the release of mediators (6, 8). Mast cell activation might involve membrane receptors for the complement molecules (14); this mechanism might explain toxic-allergic reactions possibly caused by *Blastocystis* (1, 3). Hence, histamine might be released, leading to short-lived urticaria.

The pathogenesis of acute urticaria in the case presented here was unclear. Both investigation and a thorough medical history failed (15) to reveal any IgE-mediated sensitivity (14); however, the patient was encouraged to reveal gastrointestinal symptoms (10, 14). He did not, however, report any exposure to *Blastocystis* (6, 8). The appearance of the amoeboid form of *Blastocystis* on culture day 2 concurred with the previously reported findings. It can be speculated that subtype 3 might contribute to *Blastocystis* sp. pathogenic potential only when the amoeboid form is present (11). It is of interest to note that, like in the case presented here, the successful eradication of *Blastocystis* producing amoeboid forms during the cultivation period resulted in complete resolution of urticarial lesions (1, 7, 8, 15). This is the first report of acute urticaria associated with *Blastocystis* sp. subtype 3 amoeboid forms seen in cul-

ture. It appears helpful examining amoeboid forms of *Blastocystis* sp. in parasite cultures from unresponsive patients who have acute urticaria of unknown aetiology and minor gastrointestinal symptoms, in order to administer appropriate anti-parasite treatment

REFERENCES

1. Valsecchi R, Leghissa P, Greco V. Cutaneous lesions in *Blastocystis hominis* infection. *Acta Derm Venereol* 2004; 84: 322–324.
2. Stensvold CR, Suresh GK, Tan KSW, Thompson RCA, Traub RJ, Viscogliosi E, et al. Terminology for *Blastocystis* subtypes – a consensus. *Trends Parasitol* 2007; 23: 93–96.
3. Stenzel DJ, Boreham PFL. *Blastocystis hominis* revisited. *Clin Microbiol Rev* 1996; 9: 563–584.
4. Tan KSW, Singh M, Yap EH. Recent advances in *Blastocystis hominis* research: hot spots in terra incognita. *Int J Parasitol* 2002; 32: 789–804.
5. Armentia A, Mendez J, Gomez A, Sanchis E, Fernandez A, de la Fuente R, Sanchez P. Urticaria by *Blastocystis hominis*. Successful treatment with paromomycin. *Allergol Immunopathol (Madr)* 1993; 21: 149–151.
6. Cassano N, Scoppio BM, Loviglio MC, Vena GA. Remission of delayed pressure urticaria after eradication of *Blastocystis hominis*. *Acta Derm Venereol* 2005; 85: 357–358.
7. Biedermann T, Hartmann K, Sing A, Przybilla B. Hypersensitivity to nonsteroidal anti-inflammatory drugs and chronic urticaria cured by treatment of *Blastocystis hominis* infection. *Br J Dermatol* 2002; 146: 1113–1114.
8. Gupta R, Parsi K. Chronic urticaria due to *Blastocystis hominis*. *Australas J Dermatol* 2006; 47: 117–119.
9. Pasqui AL, Savini E, Saletti M, Guzzo C, Pucetti L, Auteri A. Chronic urticaria and *Blastocystis hominis* infection: a case report. *Eur Rev Med Pharmacol* 2004; 8: 117–120.
10. Mearin F, Roset M, Badia X, Balboa A, Baró E, Ponce J, et al. Splitting irritable bowel syndrome: from original Rome to Rome II criteria. *Am J Gastroenterol* 2004; 99: 122–130.
11. Yan Y, Su S, Lai R, Liao H, Ye J, Li X, et al. Genetic variability of *Blastocystis hominis* isolates in China. *Parasitol Res* 2006; 99: 597–601.
12. Tan TC, Suresh KG. Amoeboid form of *Blastocystis hominis* – a detailed ultrastructural insight. *Parasitol Res* 2006b; 99: 737–742.
13. Tan TC, Suresh KG. Predominance of amoeboid forms of *Blastocystis hominis* in isolates from symptomatic patients. *Parasitol Res* 2006a; 98: 189–193.
14. Hennino A, Bérard F, Guillot I, Saad N, Rozières A, Nicolas J-F. Pathophysiology of urticaria. *Clin Rev Allergy Immunol* 2006; 30: 3–11.
15. Zuberbier T, Maurer M. Urticaria: Current opinions about etiology, diagnosis and therapy. *Acta Derm Venereol* 2007; 87: 196–205.