

Serum Cytokeratin 18 as a Metastatic and Therapeutic Marker for Extramammary Paget's Disease

Mariko URANO-TAKAOKA, Hayakazu SUMIDA*, Takuya MIYAGAWA*, Kentaro AWAJI, Kojiro NAGAI, Jun OMATSU, Tomomi MIYAKE and Shinichi SATO

Department of Dermatology, Faculty of Medicine, The University of Tokyo, Tokyo, Japan

Extramammary Paget's disease (EMPD) is a rare cutaneous adenocarcinoma with unfavourable prognosis once it becomes invasive. A tumour marker that reflects disease progression is required for adequate management of EMPD. Cytokeratin 18 is highly expressed in many types of cancer and its soluble forms are detected by M30 (for caspase-cleaved form) and M65 (for both caspase-cleaved and intact forms) assays. We report here that tumour cells of EMPD in both lesional skin and lymph node metastasis are immunohistochemically positive for CK18, and the baseline serum M30 and M65 levels in patients with metastatic EMPD are significantly higher than those in non-metastatic patients. In addition, serial serum M30 and M65 levels might reflect recurrence of EMPD and response to chemotherapy. These results suggest that serum CK18 levels may be a useful tumour marker for advanced EMPD.

Key words: extramammary Paget's disease; cytokeratin 18; tumour marker.

Accepted Dec 14, 2021; Epub ahead of print Dec 14, 2021

Acta Derm Venereol 2022; 102: adv00636.

Corr: Hayakazu Sumida and Takuya Miyagawa, Department of Dermatology, Faculty of Medicine, The University of Tokyo, 7-3-1, Hongo, Bunkyo-ku, Tokyo, 113-8655, Japan. E-mail: sumida-tky@umin.ac.jp; miyagawat-der@h.u-tokyo.ac.jp

Extramammary Paget's disease (EMPD) is a rare cutaneous adenocarcinoma that generally affects the genital and axillary regions in elderly patients. Although the pathogenesis of EMPD is unknown, it is reported to resemble breast cancer in immunohistochemical and molecular profiles (1). The prognosis is good in most cases, as the tumour cells often remain in situ. However, once EMPD invades the dermis the prognosis is poor, with lymph node metastasis or distant metastasis (2). Therefore, a tumour marker that reflects disease progression is required for better management of EMPD. There is currently no established chemotherapy for advanced EMPD, because of the rarity of this disease and the lack of clinical trials. Previously described regimens include docetaxel (DTX) monotherapy; low-dose 5-fluorouracil plus cisplatin; 5-fluorouracil, epirubicin, carboplatin, vincristine, and mitomycin; DTX plus S-1; S-1 monotherapy; and cisplatin, epirubicin, and paclitaxel combination therapy (3). Of these, DTX monotherapy has been studied in relatively large cohorts of patients, with a reported response rate of 31.8–58.3% (3).

SIGNIFICANCE

Cytokeratin 18 is expressed in adenocarcinoma and its soluble forms are detected by M30 (for caspase-cleaved form) and M65 (for both caspase-cleaved and intact forms) assays. Serum M30 and M65 levels are potential tumour markers in various types of cancer. Immunohistochemical analysis found that tumour cells in extramammary Paget's disease expressed cytokeratin 18. Furthermore, serum M30 and M65 levels in patients with metastatic extramammary Paget's disease were significantly higher than those in non-metastatic patients, and serial serum M30 and M65 levels might reflect recurrence and response to chemotherapy. Therefore, serum cytokeratin 18 levels may be a useful tumour marker for advanced extramammary Paget's disease.

Cytokeratins (CKs) are major structural proteins found in various types of epithelial cells (4). CK18 is expressed in many types of simple epithelial tissues and human carcinoma cells, such as those of the breast, prostate, lung, colon, and ovary (5). A recent report on CK18 expression in 115 different tumour types and subtypes, using immunohistochemistry, showed that CK18 is positive in all cases of adenocarcinomas of the lung, cervix uteri, small intestine, prostate and pancreas (6). Furthermore, CK18 is strongly positive in almost all cases of adenocarcinomas of the small intestine and prostate. On the other hand, CK 18 is negatively stained in all cases of skin tumours, such as malignant melanoma and basal cell carcinoma, and soft tissue tumours, such as dermatofibrosarcoma protuberans, Kaposi sarcoma, liposarcoma and leiomyosarcoma. The relationship between CK18 expression and clinical data has been analysed in some cancer types. For example, low levels of CK18 were associated with tumour-node-metastasis (TNM) stage, lymph node metastasis and unfavourable survival in patients with breast cancer (7). Likewise, downregulation of CK18 was related to paclitaxel-resistance and tumour aggressiveness in prostate cancer (8).

Although CK18 is insoluble at physiological salt concentrations, it is released from human carcinoma cells during cell death. CK18 has been reported to be a tumour marker for various types of carcinoma (9). Tumour cells of EMPD are also reported to be positive for CK18 in an immunohistochemical study (10). The soluble CK18 fragments from tumour cells are released into the extracellular compartment either by apoptosis or

necrosis (5). Therefore, the release of CK18 is a marker of epithelial cell death as well as apoptosis. M30 and M65, relatively new enzyme-linked immunoassay (ELISA) assays, can be used to detect different circulating forms of CK18 in serum (11). The M30 assay is postulated as a selective biomarker of apoptotic cell death, since it detects a neoepitope, which is revealed only after caspase cleavage of CK18 during the early stages of apoptosis. On the other hand, the M65 assay measures both caspase cleavage and cellular release of intact CK18, as it uses a different detection antibody from M30, which does not distinguish between the full-length protein and its fragments (5). Serum M30 and M65 levels are found to be elevated in patients with different types of carcinoma and are investigated as a non-invasive method of monitoring or predicting tumour progression, prognosis, and response to chemotherapy. In particular, serum M30 and M65 levels were significantly higher in patients with metastatic breast cancer than those with non-metastatic breast cancer (12). However, to date, the serum CK18 levels in patients with EMPD have not been studied. The aim of this study was to retrospectively measure the serum levels of CK18 and assess the significance of this protein as a tumour marker in EMPD.

MATERIALS AND METHODS

Patients

Serum samples were collected from 11 healthy controls and 24 patients with EMPD (19 patients before any type of treatment, 2 patients at recurrence after resection, and 3 patients after the initiation of chemotherapy) from October 2010 to April 2020 at the Department of Dermatology, The University of Tokyo Hospital, Tokyo, Japan. Diagnosis of EMPD was histologically proved with a skin biopsy, and clinical staging was performed according to the TNM staging system for EMPD (2). At the time of histological diagnosis of EMPD, we performed routine computed tomography and general physical examination to rule out any associated internal malignancy. In this study, 1 patient was diagnosed with breast cancer during such investigations. Four patients with EMPD had a past medical history of internal malignancy (three with breast cancer and one with colorectal cancer), all of whom had completed treatment for internal malignancy. The site affected by EMPD was external genitalia in all of these 5 patients. Furthermore, immunohistochemical staining with gross cystic disease fluid protein 15, cytokeratin 7 and cytokeratin 20 was performed to rule out secondary EMPD, which is represented by the epidermotropic spread of malignant cells from an underlying internal neoplasm (13). In cases in which the affected sites were near the anal or external urethral meatus, endoscopic investigations were also performed. Thus, patients with secondary EMPD were excluded in this study. For the analysis of serum M30 and M65 levels categorized by disease stage, serum samples from healthy controls, 19 patients with EMPD before any type of treatment, and 2 patients with EMPD at recurrence after resection were used. For analysis of the correlation between serum CK18 and carcinoembryonic antigen (CEA) levels, and of the serial serum levels in each patient, serum samples from all the patients with EMPD were used. The baseline patient characteristics are shown in **Table I**. Ten patients received chemotherapy; 8 patients received DTX only, one patient received S-1 only, and one patient received S-1 plus DTX. In these patients,

Table I. Patient characteristics

	Healthy controls (n = 11)	EMPD patients (n = 24)
Age, years (median)	62	71.5
Sex (F/M)	7/4	8/16
Serum haemoglobin level low/normal	0/11	3/21
Serum WBC count normal/high	10/1	23/1
C-reactive protein high/normal	6/5	6/18
Serum LDH level normal/high	9/0	2/20
Smoker	1	10
Aspartate aminotransferase (U/l) median	19	21
Alanine transaminase (U/l) median	17	18
Disease stage		
Stage 0		4
Stage I		2
Stage II		8
Stage III		1
Stage IV		9

WBC: white blood cell; LDH: lactate dehydrogenase.

response to treatment was evaluated according to the Response Evaluation Criteria in Solid Tumors version 1.1 guidelines. The evaluation results were recorded as complete response, partial response, stable disease, and progressive disease.

Serum M30 level has been reported to increase immediately after chemotherapy in breast cancer, reflecting apoptotic cell death induced by cytotoxic chemotherapy (14). Therefore, in this study, we included samples collected before each course of treatment to investigate the significance of these markers in terms of tumour volume instead of the cytotoxic effect of the chemotherapy. This study was performed according to the principles of the Declaration of Helsinki and approved by the ethics committee of the University of Tokyo Graduate School of Medicine. Written informed consent was obtained to use blood and skin samples from all patients and healthy controls.

Immunohistochemistry

For histological evaluation, tissue sections were deparaffinized and stained using mouse anti-CK18 antibodies (1:200, BioLegend, San Diego, CA, USA, Cat #628402). Since the eccrine sweat gland and the tumour cells of breast cancer are known to be positive for CK18 (4, 15, 16), samples of the eccrine sweat gland in normal skin and cutaneous metastasis from breast cancer were stained as positive controls. Normal epithelia and squamous cell carcinoma are stained as negative controls.

Enzyme-linked immunosorbent assay

The serum M30 and M65 levels were measured using M30 and M65 ELISA kits (PEVIVA, Bromma, Sweden) according to the manufacturer's instructions. These kits are solid-phase sandwich enzyme immunoassays, in which samples react with a solid-phase capture antibody M5 directed against CK18 and the horseradish peroxidase (HRP)-conjugated M30 antibody directed against the CK18Asp396 neo-epitope in soluble caspase-cleaved CK18 (for M30) or with a solid-phase capture antibody M6 directed against CK18 and the HRP-conjugated M5 antibody directed against a different epitope of CK18 (for M65). The absorbance was measured in a microplate reader at 450 nm. By plotting a standard curve from known concentrations of the samples provided as standards, M30 and M65 levels were calculated and expressed in U/l. The reference median values in the normal Swedish population of M30 and M65 are 94 U/l (95th percentile: 251) and 264 U/l (95th percentile: 413), respectively, according to the manufacturer's instructions. CEA levels of some patients with advanced stage were measured in the hospital laboratory at any time, and these data were compared with the M30 and M65 levels measured by ELISA.

Statistical analysis

Statistical analysis was performed using Prism Version 7 software (GraphPad, San Diego, CA, USA). Mann–Whitney *U* test was used for 2-group comparisons. Correlation coefficients were determined using Spearman's rank correlation test. *p*-values <0.05 were considered statistically significant.

RESULTS

Immunohistochemical staining for CK18 in lesional skin of patients with extramammary Paget's disease

Samples of EMPD lesional skin were immunolabelled for CK18. Tumour cells of EMPD in both lesional skin (Fig. 1A) and lymph node metastasis (Fig. 1B) were positive for CK18. As a positive control, skin samples of metastatic breast cancer were stained with CK18 (Fig. 1C). CK18 was negative in keratinocytes (Fig. 1C) and positive in sweat gland epithelial cells (Fig. 1D). Tumour cells of squamous cell carcinoma were negative for CK18 (Fig. 1E).

Serum M30 and M65 levels in patients with extramammary Paget's disease

Fig. 2A–D shows the serum M30 and M65 levels in healthy controls and patients with EMPD categorized by disease stage before initial treatment. Serum M30 and M65 levels in all examined patients with EMPD were not significantly different from those in healthy controls (Fig. 2A, B). However, serum M30 and M65 levels in patients with metastatic (stage IV) EMPD were higher than those in patients with non-metastatic (stage I–III) EMPD (Fig. 2C, D). No significant correlation was found between the ratio of M30 to M65 and disease stage.

Correlation between serum CK18 levels and serum carcinoembryonic antigen levels

CEA is one of the tumour markers reported to be useful in the management of EMPD, as well as other adenocarcinomas. Fig. 2E, F shows the correlation between serum CK18 and CEA levels. The data of serum CEA levels were obtained from clinical data at the hospital laboratory. A significant correlation was detected between the serum CEA levels and the serum M30 and M65 levels ($r=0.333$, $p=0.0207$ and $r=0.52$, $p<0.0001$, respectively).

Trend of serial carcinoembryonic antigen, M30, and M65 in each patient

We next focused on the serial levels of serum M30 and M65, in comparison with serum CEA levels in each patient. Here, we measured the CK18 levels in serum samples which were obtained before any type of treatment, at recurrence, just before each course of chemotherapy, or at the decision regarding best supportive care. Representative data are shown in Fig. 3. In patient 1 (Fig. 3A), M30 and M65 levels decreased drastically after the operation and did not increase, while maintaining complete response. CEA levels showed a similar trend. Patient 2 in Fig. 3B showed a decline in M30 and M65 levels after the initiation of DTX therapy and at the evaluation of stable disease (DTX1–DTX5). However, M30 and M65 levels increased in advance of the evaluation of progressive disease. In patient 3 (Fig. 3C), M65 levels increased in advance of the determination of progressive disease. In contrast, CEA did not show an increase at the same time as M65 (DTX24).

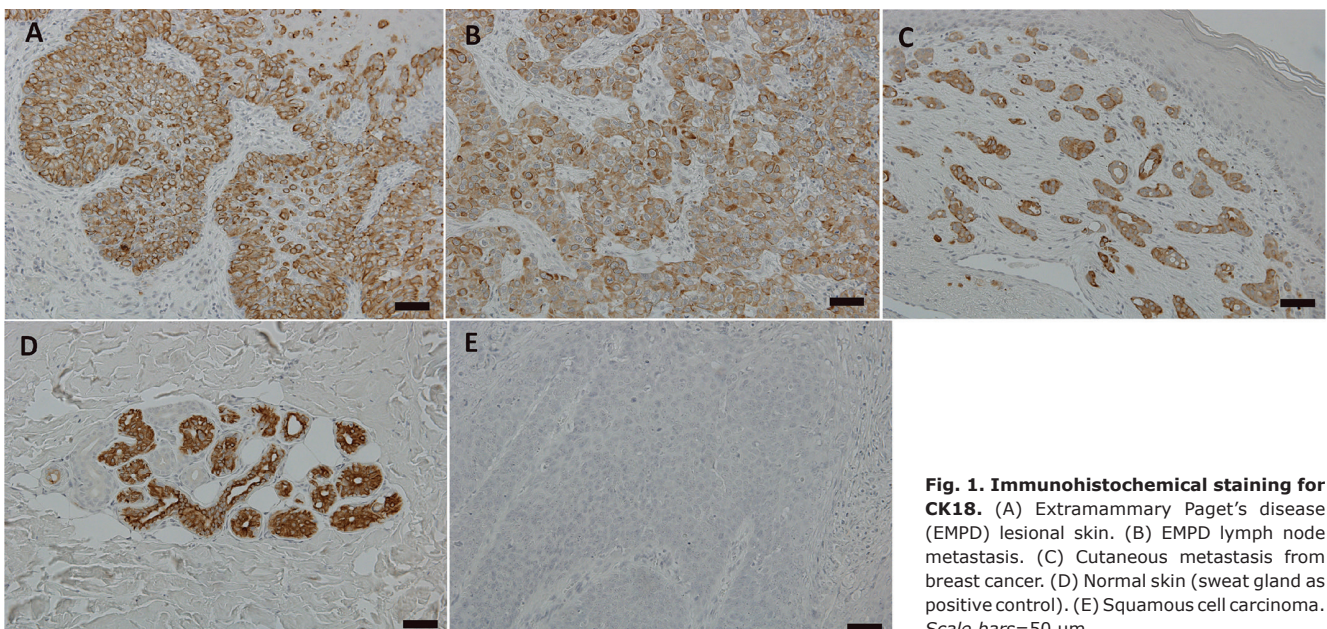


Fig. 1. Immunohistochemical staining for CK18. (A) Extramammary Paget's disease (EMPD) lesional skin. (B) EMPD lymph node metastasis. (C) Cutaneous metastasis from breast cancer. (D) Normal skin (sweat gland as positive control). (E) Squamous cell carcinoma. Scale bars=50 μ m.

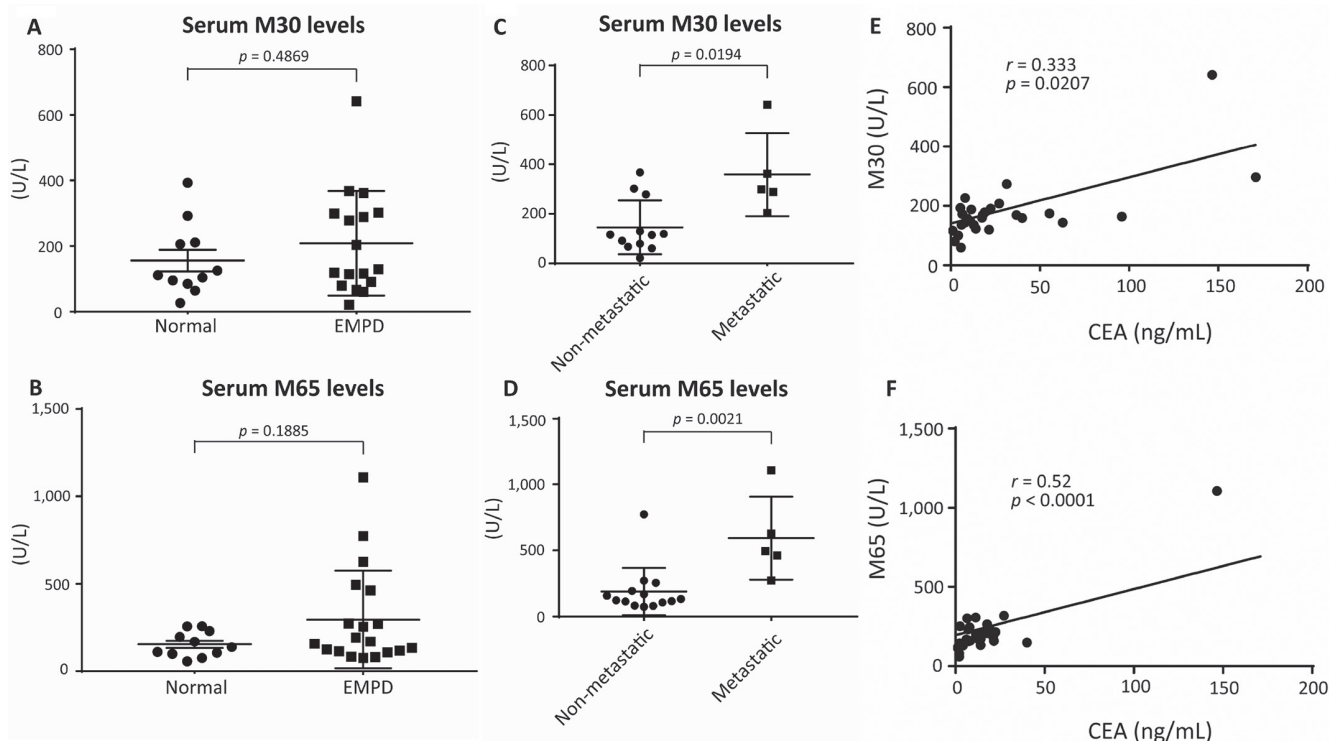


Fig. 2. Serum CK18 and carcinoembryonic antigen (CEA) levels in patients with extramammary Paget's disease (EMPD) and healthy controls. Horizontal line: mean. Error bars: standard error of the mean. (A) Serum M30 levels in patients with EMPD and healthy controls. (B) Serum M65 levels in patients with EMPD and healthy controls. (C) Serum M30 levels in non-metastatic vs metastatic patients. (D) Serum M65 levels in non-metastatic vs metastatic patients. (E) Correlation between serum CEA and serum M30 levels. (F) Correlation between serum CEA and serum M65 levels.

DISCUSSION

This study revealed that serum CK18 levels were significantly higher in patients with metastatic EMPD than in those with non-metastatic EMPD. The results also suggest that serum CK18 levels reflect the response to chemotherapy. This is in accordance with a previous study that showed that the serum levels of M30 and M65 in patients with metastatic breast cancer were significantly higher than those in non-metastatic patients (12). In another study that included repeated sampling through chemotherapy in patients with metastatic colorectal cancer, M30 and M65 levels increased progressively in

patients with progressive disease during chemotherapy (17). Interestingly, M30 and M65 levels increased in advance of the determination of progressive disease in this study. Therefore, serum CK18 levels might predict the response to chemotherapy. In particular, as shown in Fig. 3B and C, serum M65 levels increased more rapidly than serum M30 levels at the evaluation of disease progression. Thus, serum M65 levels might be a more sensitive and useful marker than serum M30 levels for the detection of disease progression.

Immunohistochemical staining show that tumour cells in both primary lesion and lymph node metastasis of

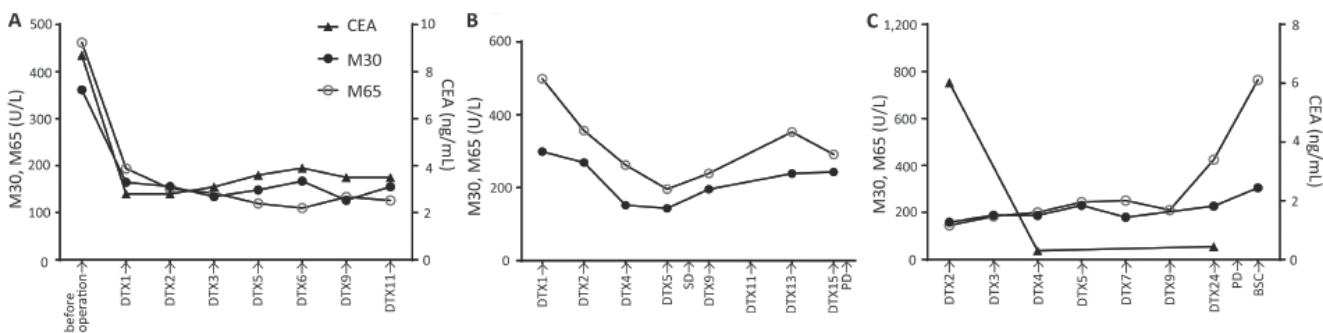


Fig. 3. Serial serum carcinoembryonic antigen (CEA), M30, and M65 levels in each patient. (A) Patient 1. M30 and M65 levels decreased drastically after operation and did not increase, while maintaining complete response. CEA levels showed a similar trend. (B) Patient 2 showed a decline in M30 and M65 levels after the initiation of docetaxel (DTX) therapy and at the evaluation of stable disease (SD). However, M30 and M65 levels increased in advance of the evaluation of progressive disease (PD). (C) Patient 3. M65 levels increased in advance of the determination of progressive disease. In contrast, CEA did not show an increase at the same time as M65. BSC: best supportive care.

EMPD are positive for CK18. Our results add to the existing knowledge that tumour cells of EMPD in primary lesion are positive for CK18 (10). The fact that tumour cells in metastatic lesions express CK18 supports our findings that serum CK18 levels are higher in patients with metastatic EMPD than in non-metastatic patients.

In terms of biological function, CK18 is important not only for maintaining the cytoplasmic network of intermediate filaments, but also for cellular processes, such as apoptosis, mitosis, cell cycle progression, and cell signalling (4). CK18 is involved in the signalling pathways, such as the phosphoinositide 3-kinase (PI3K)/Akt pathway. Inhibition of PI3K makes cells susceptible to Fas-induced apoptosis, whereas the constitutive expression of Akt protects cells from apoptosis (18). In addition, reduced apoptosis or its resistance plays a vital role in carcinogenesis (19). CK18 expression in breast cancer cell line is associated with reduced invasiveness *in vitro* and lack of tumourigenicity in nude mice. CK18 appears to restrict the motility of micrometastatic cells. Epithelial tumour cells need to undergo a fundamental phenotypical change called epithelial-to-mesenchymal transition to become more dedifferentiated and malignant, and reduced CK18 expression might contribute to this transition (20). Although the findings of the prognostic effect of CK18 *in vivo* and *in vitro* seem to be conflicting, it might be suggested that fragmented CK18 levels reflect the degradation of CK18, thereby inducing dedifferentiated conditions of tumour cells.

The current study showed that both serum M30 and M65 levels correlate with serum CEA levels. Previous studies have demonstrated the significance of CEA as a marker for advanced stage and chemotherapeutic response in EMPD (21, 22). In Fig. 3C, serum CEA levels remained within normal limits even when M65 levels showed an increase, suggesting that M30 and M65 levels might have a higher sensitivity than CEA levels.

Study limitations

This study has several limitations. First, the total sample size was relatively small, and especially, fewer samples were collected before any type of treatment, since many of the patients had already been treated elsewhere before the first presentation at our institute. Due to this small sample size, it was not reasonable to obtain a cut-off value of CK18 levels in terms of evaluating prognostic factors. In addition, analysis of the relationship between the serum levels of CK18 and survival was hardly possible due to the small sample size. Likewise, although it is widely accepted that distant lymph node metastases are associated with poor survival (2), we could not compare the prognosis in patients with distant lymph node metastases with that with regional lymph node metastases, as there was only one patient with regional lymph node metastasis.

Conclusion

In summary, this study showed that serum CK18 levels are elevated in metastatic EMPD and may predict chemotherapeutic response. Serum CK18 levels might be an adequate non-invasive marker to detect EMPD progression and recurrence. Further studies with a large sample size are required to clarify the usefulness of CK18 in patients with advanced-stage EMPD.

The authors have no conflicts of interest to declare.

REFERENCES

1. Tessier-Cloutier B, Asleh-Aburaya K, Shah V, McCluggage WG, Tinker A, Gilks CB. Molecular subtyping of mammary-like adenocarcinoma of the vulva shows molecular similarity to breast carcinomas. *Histopathology* 2017; 71: 446–452.
2. Ohara K, Fujisawa Y, Yoshino K, Kiyohara Y, Kadono T, Murata Y, et al. A proposal for a TNM staging system for extramammary Paget disease: retrospective analysis of 301 patients with invasive primary tumors. *J Dermatol Sci* 2016; 83: 234–239.
3. Hashimoto H, Kaku-Ito Y, Furue M, Ito T. The outcome of chemotherapy for metastatic extramammary Paget's disease. *J Clin Med* 2021; 10: 739.
4. Weng YR, Cui Y, Fang JY. Biological functions of cytokeratin 18 in cancer. *Mol Cancer Res* 2012; 10: 485–493.
5. Kramer G, Erdal H, Mertens HJMM, Nap M, Mauermann J, Steiner G, et al. Differentiation between cell death modes using measurements of different soluble forms of extracellular cytokeratin 18. *Cancer Res* 2004; 64: 1751–1756.
6. Menz A, Weitbrecht T, Gorbokon N, Büscheck F, Luebke AM, Kluth M, et al. Diagnostic and prognostic impact of cytokeratin 18 expression in human tumors: a tissue microarray study on 11,952 tumors. *Mol Med* 2021; 27: 16.
7. Shi R, Liu L, Wang F, He Y, Niu Y, Wang C, et al. Downregulation of cytokeratin 18 enhances BCRP-mediated multidrug resistance through induction of epithelial-mesenchymal transition and predicts poor prognosis in breast cancer. *Oncol Rep* 2019; 41: 3015–3026.
8. Yin B, Zhang M, Zeng Y, Li Y, Zhang C, Song Y. Downregulation of cytokeratin 18 is associated with paclitaxel resistance and tumor aggressiveness in prostate cancer. *Int J Oncol* 2016; 49: 848.
9. Oshima RG, Baribault H, Caulín C. Oncogenic regulation and function of keratins 8 and 18. *Cancer Metastasis Rev* 1996; 15: 445–471.
10. Liegl B, Leibl S, Gogg-Kamerer M, Tessaro B, Horn LC, Moirnar F. Mammary and extramammary Paget's disease: an immunohistochemical study of 83 cases. *Histopathology* 2007; 50: 439–447.
11. Cummings J, Hodgkinson C, Odedra R, Sini P, Heaton SP, Mundt KE, et al. Preclinical evaluation of M30 and M65 ELISAs as biomarkers of drug induced tumor cell death and antitumor activity. *Mol Cancer Ther* 2008; 7: 455–463.
12. Tas F, Karabulut S, Yildiz I, Duranyildiz D. Clinical significance of serum M30 and M65 levels in patients with breast cancer. *Biomed Pharmacother* 2014; 68: 1135–1140.
13. Lloyd J, Flanagan AM. Mammary and extramammary Paget's disease. *J Clin Pathol* 2000; 53: 742–749.
14. Olofsson MH, Ueno T, Pan Y, Xu R, Cai F, Van Der Kuip H, et al. Cytokeratin-18 is a useful serum biomarker for early determination of response of breast carcinomas to chemotherapy. *Clin Cancer Res* 2007; 13: 3198–3206.
15. Moll R, Franke WW, Schiller DL, Geiger B, Krepler R. The catalog of human cytokeratins: Patterns of expression in normal epithelia, tumors and cultured cells. *Cell* 1982; 31: 11–24.
16. Bártek J, Vojtěšek B, Stašková Z, Bártková J, Kerekés Z, Rejthar A, et al. A series of 14 new monoclonal antibodies to keratins: characterization and value in diagnostic histo-

- pathology. *J Pathol* 1991; 164: 215–224.
17. Greystoke A, Dean E, Saunders MP, Cummings J, Hughes A, Ranson M, et al. Multi-level evidence that circulating CK18 is a biomarker of tumour burden in colorectal cancer. *Br J Cancer* 2012; 107: 1518–1524.
 18. Abreu MT, Arnold ET, Chow JYC, Barrett KE. Phosphatidylinositol 3-kinase-dependent pathways oppose fas-induced apoptosis and limit chloride secretion in human intestinal epithelial cells: implications for inflammatory diarrheal states. *J Biol Chem* 2001; 276: 47563–47574.
 19. Wong RSY. Apoptosis in cancer: from pathogenesis to treatment. *J Exp Clin Cancer Res* 2011; 30: 87.
 20. Bühler H, Schaller G. Transfection of keratin 18 gene in human breast cancer cells causes induction of adhesion proteins and dramatic regression of malignancy in vitro and in vivo. *Mol Cancer Res* 2005; 3: 365–371.
 21. Umemura H, Yamasaki O, Kaji T, Otsuka M, Asagoe K, Iwatsuki K. Serum carcinoembryonic antigen level as a marker for advanced stage and chemotherapeutic response in extramammary paget's disease. *Acta Derm Venereol* 2018; 98: 706–707.
 22. Hatta N, Yamada M, Hirano T, Fujimoto A, Morita R. Extramammary Paget's disease: treatment, prognostic factors and outcome in 76 patients. *Br J Dermatol* 2008; 158: 313–318.