

CLINICAL REPORT

Cooling by Frozen Gel Pack as Pain Relief During Treatment of Axillary Hyperhidrosis with Botulinum Toxin A Injections

Jette SKIVEREN, Emmy KJAERBY and Heidi NORDAHL LARSEN

Department of Dermatology, Copenhagen University Hospital, Bispebjerg Hospital, Copenhagen, Denmark

Botulinum toxin A injection is a well-described efficacious treatment for axillary hyperhidrosis. Although considered a safe treatment, many patients experience pain during injections. The purpose of the present study was to examine whether cooling by frozen gel packs applied in the axilla for 5 min before treatment could reduce pain. Thirty-six patients with axillary hyperhidrosis were included in this randomized, open-label prospective study, in which patients were their own controls. Pain was assessed before, during (four times), and immediately after treatment, using a numeric rating scale. The patients experienced statistically significant pain reduction, of 14–19%, in areas cooled by frozen gel pack ($p < 0.01$). However, the clinical relevance of this relatively small pain reduction is questionable. Key words: botulinum toxin A; injection; skin cooling; ice; gel; pack.

(Accepted February 5, 2008.)

Acta Derm Venereol 2008; 88: 366–369.

Jette Skiveren, Department of Dermatology-D42, Copenhagen University Hospital, Bispebjerg Hospital, Bispebjerg Bakke 23, DK-2400 Copenhagen, Denmark. E-mail: js07@bbh.regionh.dk

Axillary hyperhidrosis is a common condition (with a self-reported prevalence of 1.4%) characterized by excessive secretion of the eccrine sweat glands (1). Several studies have described how psychological and social impairment associated with the condition leads to reduction in quality of life (2–8). Yet, only a minority of affected individuals seek professional advice for their sweating problems (1). Recent studies have shown that botulinum toxin A (BTX-A) significantly decreases axillary hyperhidrosis and has few side-effects. However, many patients experience pain during treatment.

Cooling by cold water, spray, air, ice cubes and frozen gel pack are often used to reduce discomfort and mild pain from a variety of sources, such as acute soft-tissue injury (9–10), injections (11–12), nerve blocks (13), insertion of intravenous catheters (14) and laser therapy. Only a few local, and no systemic, side-effects have been reported. However, despite the common use of cooling as anaesthesia for transient pain in the skin, only a few randomized controlled studies have been published (9, 12, 15).

In a randomized study of 24 patients treated with BTX-A in the face, ice was shown to provide significant pain relief (11). However, there are no reports of skin cooling by frozen gel pack for BTX-A in axillary hyperhidrosis. The aim of the present study was to investigate the efficacy of frozen gel pack as anaesthesia for pain relief during axillary BTX-A injections.

MATERIALS AND METHODS

Patients and ethics

Thirty-six patients (age range 20–41 years, mean 27.7 years) with bilateral axillary hyperhidrosis were included in the study. A dermatologist confirmed the diagnoses by clinical examination. Pregnant women, patients younger than 18 years, and patients with major psychiatric diseases, such as schizophrenia and affective disorders, were excluded. The study protocol was approved by the scientific ethics committee for Copenhagen County (KF01 308389) and conducted in accordance with the Declaration of Helsinki V. All patients gave their written informed consent.

Study design

The study design was a within-patient randomized, controlled trial, with patients acting as their own controls. Coin tossing and concealed envelopes were used for the randomization procedure.

Treatment

Patients who regularly shaved their armpits were recommended not to do so within 48 h prior to treatment. For patients with hairy armpits, the hair was cut to a length of 0.5 cm. Minor's iodine starch test (4) was used for identifying the hyperhidrotic area. The borders were marked and the area divided into 1 cm² squares. The frozen gel pack (3M Nexcare™ ColdHot, classic, 27 cm × 11 cm, Glostrup, Denmark), which was covered by a single layer of dry gauze, was applied 5 min before the injections. The control side was not given any anaesthesia. We used BTX-A 100 Units (Botox, Allergan, Irvine, CA, USA) diluted in 6 ml NaCl. The injections were administered with a 3-ml syringe, with a 27G needle (Microlance 27G×3/4" 0.4 × 19 mm), at an angle of 30–45°. The injections were given intradermally, and the injection volume was 0.1–0.2 ml/cm². The right axilla was always treated first and the left one immediately afterwards.

Outcome measures

Pain was assessed by a numeric rating scale (NRS), where 0 was no pain and 10 was the worst imaginable pain. The assessments were performed: (i) just before treatment and anaesthesia (0 min); (ii) at injection no. 10, 20, 30, and 40; and (iii) immediately after the last injection. NRS (verbal) was chosen

because immobilization of the arms of the patients during treatment impeded the use of a graphical visual analogue scale. In addition, verbal numerical rating scales correlate well with conventional visual analogue scales (16–18). After treatment, the patients were asked whether they preferred treatment with or without a frozen gel pack. The number of injections in each axilla was counted and the total time for injections, including pauses, was recorded.

Temperature measurements

To evaluate the effect of the frozen gel pack on skin temperature, consecutive temperatures were measured with a Raytek MX2 infrared thermometer (Santa Cruz, CA, USA) in the axilla of a healthy volunteer before and after application of the frozen gel pack.

Statistics

A reduction in pain score of 2 units on the analogue scale was considered the smallest detectable difference. Having a test power of 0.80 and a significance level of 0.05, 36 patients were needed to complete the study (Altman's nomogram). Null hypothesis was based on the assumption that there is no difference in efficacy (pain reduction) between anaesthesia with frozen gel pack and without anaesthesia.

A paired *t*-test was used to determine whether the change in pain score was statistically significant. *p*-values of less than 0.05 were considered significant. All analyses were performed using SPSS for Windows (SPSS version 11.51, SPSS Inc., Chicago, USA).

RESULTS

Thirty-six patients completed the study. Pain scores before, during and immediately after treatment are shown in Table I. The total numbers of injections (mean 51–54), as well as the total time used for the injections (mean 289–296 sec), were similar in the areas with or without anaesthesia ($p > 0.05$). Three patients needed pauses during treatment, which was counted as a part of the total time. There was no difference between the

Table I. Pain scores (numeric rating scale; NRS) and pain difference (NRS) between no anaesthesia and cooling with frozen gel pack (FGP) during injections (number 10, 20, 30 and 40) and immediately after botulinum toxin injections (inj.). Pain scores are shown as mean \pm standard deviation

Injection no.	Anaesthesia	Pain score		Pain difference (%)
		NRS	<i>p</i> -value	
Before inj.	Before anaesthesia	0.00	–	–
Before inj.	After anaesthesia	0.00	–	–
10	No anaesthesia	5.83 \pm 2.21	0.007	15
	Cooling with FGP	4.97 \pm 2.32		
20	No anaesthesia	6.17 \pm 2.14	0.008	14
	Cooling with FGP	5.31 \pm 2.19		
30	No anaesthesia	5.86 \pm 2.14	0.001	18
	Cooling with FGP	4.81 \pm 1.95		
40	No anaesthesia	5.86 \pm 2.14	0.005	19
	Cooling with FGP	4.50 \pm 2.26		
After inj.	No anaesthesia	4.86 \pm 2.47	0.009	15
	Cooling with FGP	3.97 \pm 1.93		

areas in these cases. There were significant differences in pain scores at all assessment points (10, 20, 30, 40 and immediately after treatment) between areas treated with frozen gel pack and areas without anaesthesia. In both patient groups, the highest pain scores were obtained after 20 injections, which in most patients were given in the central parts of the axilla.

None of the patients complained of pain before the start of the injections, either before or after anaesthesia with the frozen gel pack (Table I), but 3 patients (8%) complained of pain during application of the gel pack, and 2 complained of unspecified discomfort. Twenty-one patients (58%) said they would prefer anaesthesia with a frozen gel pack in the future. There were no differences in pain score between these patients and those who said they did not prefer future anaesthesia ($p > 0.05$). Two patients (6%) developed urticaria, probably acquired cold urticaria, which was related to the upper part of the gel pack, even though this was covered by gauze (19).

Skin temperatures before and after application of the frozen gel pack in the axilla of a healthy volunteer are shown in Fig. 1. As can be seen from this figure, the skin temperature increased to about 25°C 5 min after removal of the frozen gel pack.

DISCUSSION

Botulinum toxin A injection is an effective treatment for axillary hyperhidrosis. However, the intradermal injections are painful and, so far, no single effective treatment for this pain has been widely accepted. Topical anaesthesia with, for example, tetracaine, is among the most commonly applied method, but this is time-consuming, expensive and often difficult to apply in the axillae (20). By contrast, cooling of the skin has been suggested as a simple and cheap form of anaesthesia. The exact mechanism of action of anaesthesia by cooling is unknown, but several mechanisms, such as decreased nerve conduction, reduction in muscle spasms, prevention of oedema after injury and a de-

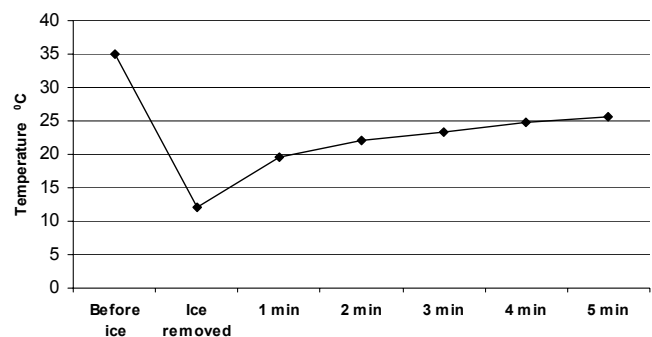


Fig. 1. Skin temperature (°C) before and after application of frozen gel pack in the axilla for 5 min in a healthy volunteer.

crease in the release of pain-production substances locally, have been proposed (10).

The present study shows that the application of a frozen gel pack for 5 min prior to injection results in a statistically significant pain reduction of 14–19%. However, the clinical relevance of a pain reduction of this magnitude is questionable; pain reductions of less than 30% have been described as “minimal” (21).

Others have achieved much greater pain reductions with similar cooling methods. Sarifakioglu & Sarifakioglu (11) achieved a pain reduction as high as 80% by applying an ice cube (5 × 5 cm) in a plastic bag to the skin for 5 min, although this was to treat the pain of only 4 injections in each side of the face (11). Bechara et al. (15) achieved an average pain reduction of around 66% in 10 patients by applying ice cubes in a glove to the skin 1 min before 25 axillary injections. A possible explanation for this difference might be that all the patients in our study were treated with at least 40 injections in each axilla. Hence, the treatment time may have been too long, so that the skin surface temperature may have risen beyond the point of analgesia. Indeed, while cold-induced analgesia have been shown to begin after the skin surface temperature lowers to approximately 13.6°C, and to cease when the temperature rises to more than 15.6°C (22), the temperature in our study increased beyond these limits within the first minute of the cooling procedure. On the other hand, after 10 injections, which in all cases took less than 1 min to give, the pain reduction achieved by the cooling procedure was still rather small. In addition, after 30 and 40 injections, the cooling-induced reduction in pain was actually more pronounced (18–19% vs. 15%).

The peak in pain score seen after 20 injections, with or without anaesthesia, probably reflects local differences in pain sensitivity in the axilla, as these injections were given to more central parts of the axilla, where the pain sensitivity seems to be higher (unpublished observations). Alternative explanations for the discrepancy in results compared with other studies might include differences in the size of the cooling modality's contact with the skin, the cooling modality's temperature, barriers between the cooling modality and the skin (e.g. gauze), the modality's size and weight, and the room temperature (23).

Finally, the size of the needle may be important. In our study a 27G needle with an outer diameter of 0.4 mm was used. Other studies have used needles ranging in size from 29G to 32G, corresponding to outer diameters of approximately 0.3 mm or less (8, 12).

Only those patients with major psychiatric disorders were excluded from the study, as such patients might not be able to co-operate fully. Hence, patients suffering from, for example, depression or mild anxiety were not excluded, because this could have introduced a bias in the assessment of pain scores (24). The present study could be criticized for not being blinded. However,

while other studies have claimed to be single-blind for the clinical investigator (11), we argue that blinding in this way is not possible, because the skin surface is colder and firmer than the surroundings.

In conclusion, the pain reduction achieved by applying a frozen gel pack as anaesthesia before BTA injections was quite small and does not support the use of cooling as pain relief for multiple skin injections. However, as this result is in contrast with previous studies showing encouraging effects of anaesthesia by cooling procedures, further studies on this topic are needed.

The authors declare no conflicts of interest.

REFERENCES

1. Strutton DR, Kowalski JW, Glaser DA, Stang PE. US prevalence of hyperhidrosis and impact on individuals with axillary hyperhidrosis: results from a national survey. *J Am Acad Dermatol* 2004; 51: 241–248.
2. Campanati A, Penna L, Guzzo T, Menotta L, Silvestri B, Lagalla G, et al. Quality-of-life assessment in patients with hyperhidrosis before and after treatment with botulinum toxin: results of an open-label study. *Clin Ther* 2003; 25: 298–308.
3. Connor KM, Cook JL, Davidson JR. Botulinum toxin treatment of social anxiety disorder with hyperhidrosis: a placebo-controlled double-blind trial. *J Clin Psychiatry* 2006; 67: 30–36.
4. Hornberger J, Grimes K, Naumann M, Glaser DA, Lowe NJ, Naver H, et al. Multi-specialty working group on the recognition, diagnosis, and treatment of primary focal hyperhidrosis. Recognition, diagnosis, and treatment of primary focal hyperhidrosis. *J Am Acad Dermatol* 2004; 51: 274–286.
5. Naumann MK, Hamm H, Lowe NJ. Botulinum toxin type A Hyperhidrosis Clinical Study Group. Effect of botulinum toxin type A on quality of life measures in patients with excessive axillary sweating: a randomized controlled trial. *Br J Dermatol* 2002; 147: 1218–1226.
6. Solish N, Benohanian A, Kowalski JW. Canadian dermatology study group on health-related quality of life in primary axillary hyperhidrosis. Prospective open-label study of botulinum toxin type A in patients with axillary hyperhidrosis: effects on functional impairment and quality of life. *Dermatol Surg* 2005; 31: 405–413.
7. Lowe NJ, Glaser DA, Eadie N, Daggett S, Kowalski JW, Lai PY. North American Botox in Primary Axillary Hyperhidrosis Clinical Study Group. Botulinum toxin type A in the treatment of primary axillary hyperhidrosis: a 52-week multicenter double-blind, randomized, placebo-controlled study of efficacy and safety. *J Am Acad Dermatol* 2007; 56: 604–611.
8. Talarico-Filho S, Mendonca DO, Nascimento M, Sperandio DE, Macedo F, DE Sanctis Pecora C. A double-blind, randomized, comparative study of two type A botulinum toxins in the treatment of primary axillary hyperhidrosis. *Dermatol Surg* 2007; 33: 44–50.
9. Bleakley C, McDonough S, MacAuley D. The use of ice in the treatment of acute soft-tissue injury: a systematic review of randomized controlled trials. *Am J Sports Med* 2004; 32: 251–261.
10. Ernst E, Fialka V J. Ice freezes pain? A review of the clinical effectiveness of analgesic cold therapy. *Pain Symptom Manage* 1994; 9: 56–59.

11. Sarifakioglu N, Sarifakioglu E. Evaluating the effects of ice application on the pain felt during botulinum toxin type-a injections: a prospective, randomized, single-blind controlled trial. *Ann Plast Surg* 2004; 53: 543–546.
12. Kuwahara RT, Skinner RB. Emla versus ice as a topical anesthetic. *Dermatol Surg* 2001; 27: 495–496.
13. Hayward SC, Landorf KB, Redmond AC. Ice reduces needle-stick pain associated with a digital nerve block of the hallux. *The Foot: International Journal of Clinical Foot Science (FOOT)*. 2006; 16: 145–148.
14. Richman PB, Singer AJ, Flanagan M, Thode HC Jr. The effectiveness of ice as a topical anesthetic for the insertion of intravenous catheters. *Am J Emerg Med* 1999; 17: 255–257.
15. Bechara F, Sand, M, Altmeyer P, Sand D, Hoffmann K. Skin cooling for botulinum toxin A injection in patients with focal axillary hyperhidrosis: a prospective, randomized, controlled study *Annals of plastic surgery*. *Ann Plast Surg* 2007; 58: 299–302.
16. Breivik EK, Bjornsson GA, Skovlund E. A comparison of pain rating scales by sampling from clinical trial data. *Clin J Pain* 2000; 16: 22–28.
17. Murphy DF, McDonald A, Power C, Unwin A, MacSullivan R. Measurement of pain: a comparison of the visual analogue with a nonvisual analogue scale. *Clin J Pain* 1988; 3: 197–199.
18. Williamson A, Hoggart B. Pain: a review of three commonly used pain rating scales. *J Clin Nurs* 2005; 14: 798–804.
19. Siebenhaar F, Weller K, Mlynek A, Magerl M, Altrichter S, Vieira Dos Santos R, et al. Acquired cold urticaria: clinical picture and update on diagnosis and treatment. *Clin Exp Dermatol* 2007; 32: 241–245.
20. O’Riordan JM, Fitzgerald E, Gowing C, O’Grady H, Feeley TM, Tierney S. Topical local anaesthetic (tetracaine) reduces pain from botulinum toxin injections for axillary hyperhidrosis. *Br J Surg* 2006; 93: 713–714.
21. Sloman R, Wruble AW, Rosen G, Rom M. Determination of clinically meaningful levels of pain reduction in patients experiencing acute postoperative pain. *Pain Manag Nurs* 2006; 7: 153–158.
22. Bugaj R. The cooling, analgesic, and rewarming effects of ice massage on localized skin. *Phys Ther* 1975; 55: 11–19.
23. Kanlayanaphotporn R, Janwantanakul P. Comparison of skin surface temperature during the application of various cryotherapy modalities. *Arch Phys Med Rehabil* 2005; 86: 1411–1415.
24. Weber A, Heger S, Sinkgraven R, Heckmann M, Elsner P, Rzany B. Psychosocial aspects of patients with focal hyperhidrosis. Marked reduction of social phobia, anxiety and depression and increased quality of life after treatment with botulinum toxin A. *Br J Dermatol* 2005; 152: 342–345.