

## INVESTIGATIVE REPORT

# Differential Expression of Pyloric Atresia in Junctional Epidermolysis Bullosa with *ITGB4* Mutations Suggests that Pyloric Atresia is due to Factors Other than the Mutations and Not Predictive of a Poor Outcome: Three Novel Mutations and a Review of the Literature

Ningning DANG<sup>1,9,10</sup>, Sandra KLINGBERG<sup>2</sup>, Adam I. RUBIN<sup>1</sup>, Matthew EDWARDS<sup>3</sup>, Siegfried BORELLI<sup>4</sup>, John RELIC<sup>5</sup>, Penelope MARR<sup>6</sup>, Kim TRAN<sup>6,10</sup>, Anne TURNER<sup>7</sup>, Nicholas SMITH<sup>8</sup> and Dédée F. MURRELL<sup>1,7,10</sup>

<sup>1</sup>Department of Dermatology, St George Hospital, Sydney, <sup>2</sup>Department of Chemical Pathology, Royal Brisbane Hospital, Brisbane, <sup>3</sup>Hunter Genetics & University of Newcastle, Newcastle, Australia, <sup>4</sup>Triemli Hospital, Zurich, Switzerland, <sup>5</sup>John Hunter Hospital, Newcastle, Australia, <sup>6</sup>Department of Anatomical Pathology, St George Hospital, <sup>7</sup>EB Clinic, Sydney Children's Hospital, Sydney, <sup>8</sup>Pathology Department, Queen Elizabeth II Hospital, Perth, Australia, <sup>9</sup>Department of Dermatology, Jinan Central Hospital, Shandong Province, China, and <sup>10</sup>University of New South Wales, Sydney, Australia

**Junctional epidermolysis bullosa with pyloric atresia (JEB-PA) is an autosomal recessive blistering disease including lethal and non-lethal variants due to mutations in *ITGB4* and *ITGA6*. It is unclear whether PA is caused directly by the mutations in these genes or by other factors. Skin biopsies from patients with JEB were processed for immunofluorescence mapping. When staining for integrin  $\beta 4$  or  $\alpha 6$  was absent or reduced, *ITGB4* was screened for mutations. A review of known mutations of *ITGB4* and the phenotypes of patients with JEB-PA was undertaken. Three novel *ITGB4* mutations were identified in 3 families with JEB-PA: 2 splice-site and one insertion mutation. Two families with lethal phenotypes (EB-050 and EB-049) were due to combinations of premature termination codons and missense mutations (658delC/R252C and 3903dupC/G273D, respectively). The third family EB-013 has 2 JEB affected siblings; a brother with PA and a sister without PA. Both were homozygous for *ITGB4* 264G>A/3111-1G>A. Two cases had no gastrointestinal symptoms or signs of PA. PA is an inconstant feature of the subtype of epidermolysis bullosa known as JEB-PA. It is most likely that multiple factors influence the development of PA and its presence is not predictive of a poor outcome. It is possible that institutions that do not routinely screen immunofluorescence mapping for integrin  $\alpha 6\beta 4$  staining in the absence of PA are missing this form of epidermolysis bullosa. **Key words:** *integrins; complications; phenotype; gastrointestinal; aplasia cutis; dysmorphic.***

(Accepted March 10, 2008.)

Acta Derm Venereol 2008; 88: 438–448.

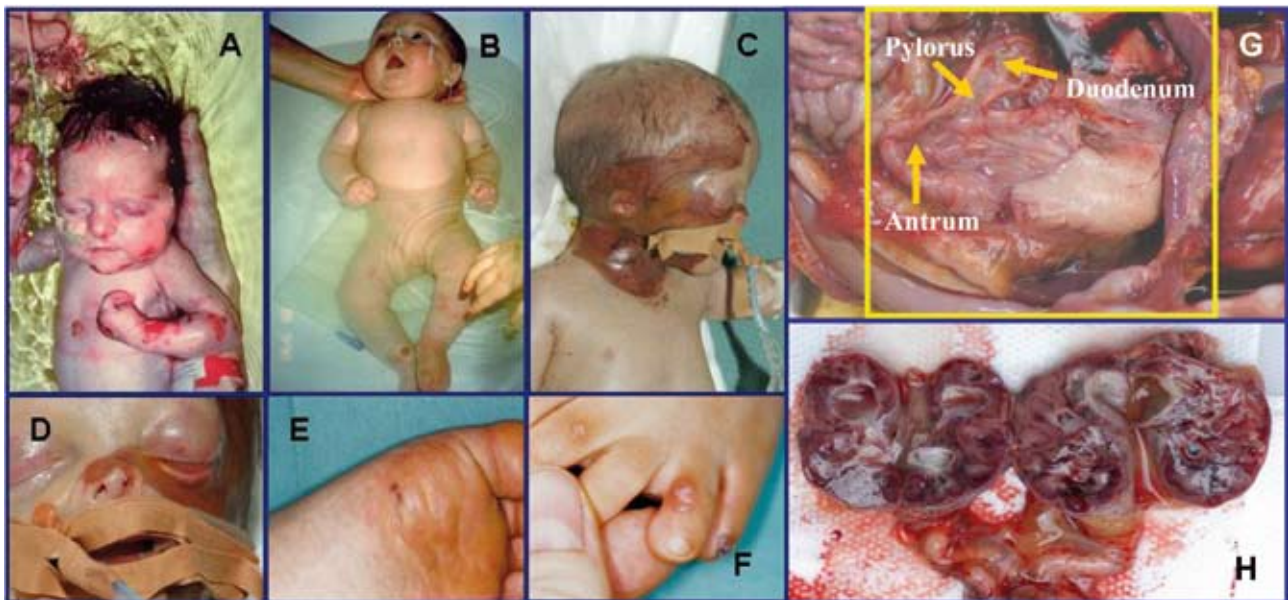
Dédée F. Murrell, Department of Dermatology, St George Hospital, University of New South Wales, Gray St, Kogarah, Sydney, NSW 2217, Australia. E-mail: d.murrell@unsw.edu.au

Junctional epidermolysis bullosa with pyloric atresia (JEB-PA) is a clinically and genetically heterogeneous autosomal recessive blistering disease, usually noted in the neonatal period, associated with congenital pyloric atresia (PA). This disease is frequently lethal in early infancy, despite surgical correction of PA (1), but non-lethal variants with diminishing blistering tendency with age have been noted previously (2–6). In addition to skin lesions, there are a variety of extracutaneous manifestations, including corneal erosions, dental, hair and nail abnormalities, as well as tracheal and urinary tract involvement (7). Ultrastructurally, the skin lesions are characterized by blister formation at the level of the lamina lucida with hypoplastic hemidesmosomes (HD) in reduced numbers and without distinct inner and outer plaques (8). Occasionally, a split in the HD in the lower basal layer occurs. Immunofluorescence antigen mapping (IFM) of the affected skin in lethal forms is usually associated with completely negative staining for integrin  $\beta 4$  and/or integrin  $\alpha 6$ , whereas non-lethal cases are usually associated with positive but attenuated staining (4). Mutations in the *ITGB4* gene were first demonstrated in JEB-PA by Vidal et al. (9). Like all integrin  $\beta$  subunits, the extracellular domain of integrin  $\beta 4$  contains 5 putative N-linked glycosylation sites and 4 homologously repeated cysteine-rich domains in which the presence of conserved residues at fixed positions allows protein-protein interactions (10, 11). Lam332 (laminin 5) and type XVII collagen bind to the extracellular domain of integrin  $\beta 4$  (12). Integrin  $\beta 4$  has an unusually large cytoplasmic tail of 1141 amino acids, which contains 2 pairs of fibronectin III-like (FNIII) domains separated by a connecting segment (CS) (10, 13). The second FNIII repeat and CS are essential for the assembly of  $\alpha 6\beta 4$  into HD (10, 13–15). This CS harbours a tyrosine activation motif in which residues 1422–1440 are critical for binding to lam332 and for HD assembly (16, 17). The first pair of FNIII repeats and the first 36

amino acids (1320–1355) of the CS are crucial for the recruitment of plectin into HD (14, 18). Sequences within the CS and the second pair of FNIII repeats of *ITGB4* are involved in targeting BP230 into HD-like structures (19). The main binding site for BP180 to integrin  $\beta 4$  resides in the segment comprising the carboxy-terminal half of the CS and the third FNIII repeat (19). As integrin  $\beta 4$  is also expressed in the epithelia of the gastrointestinal tract (20), one theory is that the absence of  $\alpha 6\beta 4$  integrin could explain the development of congenital PA. Integrin  $\beta 4$ -null mice have epithelial detachment in other epithelia, such as the tongue, oesophagus, stomach and bladder as well as the skin (21). In lethal JEB-PA, mutations usually consist of premature termination codons (PTC) affecting both *ITGB4* alleles, which result in the complete absence of  $\alpha 6\beta 4$  integrin; missense or splice site mutations are more prevalent in non-lethal forms (3, 4, 22). However, it is not only the nature, but also the position, of mutations reflected in the protein functional domains of  $\beta 4$  integrin that affect the phenotype of JEB-PA (23). To extend our knowledge of *ITGB4* mutations and to better understand the genotype-phenotype correlation in this form of EB, we studied 3 families, comprising 4 cases, and found 3 novel mutations in *ITGB4*. Interestingly, we discovered what we believe to be the first reported case of differential expression of PA in one family with 2 siblings bearing the same 2 *ITGB4* mutations. The latter suggests that unknown factors, such as epigenetic or environmental factors, may influence whether pyloric atresia occurs, as has been described in variability of pseudosyndactyly in recessive dystrophic EB with metalloproteinase 1 isoforms (24).

#### FOUR CASE REPORTS

**Family 1: EB-050.** This case was described briefly in an earlier report (4). A female infant was born at 30 weeks gestation complicated by polyhydramnios. She was the second child of a non-consanguineous union. Her mother presented in preterm labour and was given a course of betamethasone (Celestone) to suppress labour for foetal lung maturation and tocolytics. At birth, the infant had no blisters, but the first blisters appearing on her fingertips and toes when she was 2 days old. Subsequently blisters appeared at the sites of tape attachment or where she had been handled (Fig. 1A). At no stage did the infant have severe or widespread blistering. PA was noted shortly after birth and was surgically repaired. She developed respiratory distress, which was relatively mild but required mechanical ventilation. She was extubated at 6 days of age. She coughed up copious mucous secretions and had apnoeic attacks, requiring ongoing oxygen support from 28 days to 13 weeks of age. A chest radiograph showed widespread reticulonodular opacities consistent with “Northway & Rosen” stage-3 bronchopulmonary dysplasia. She developed anaemia, requiring 4 blood transfusions, neutropaenia and presumed sepsis, although no bacterial organisms were cultured. She was treated with multiple courses of i.v. antibiotics. Ultrasound detected a small subependymal intracranial haemorrhage. Other medical problems included jaundice, patent ductus arteriosus, gastro-oesophageal reflux and candida diaper dermatitis. She was discharged from hospital at post-conceptual age 46 weeks with most of the skin erosions having healed (Fig. 1B). A month later, she suddenly deteriorated and developed a new erosion



**Fig. 1.** Clinical presentation of the probands with junctional epidermolysis bullosa with pyloric atresia. (A) EB050 at 10 days showed erosions at sites where tape had been applied after birth. (B) EB050 at 4 months showing most of the erosions had healed. (C) EB049 showed loss of epidermis with exposure of reddened subcutaneous tissue and markedly atrophic ears but the external auditory meati were apparent. (D) EB049 showing a hypoplastic nasal tip, aplasia cutis congenita and patent nares. (E and F) EB013-1 and 013-2, respectively, showed mild blistering on the feet. (G) EB049 post-mortem of the stomach was normal with no pyloric atresia. (H) EB049: pelvicalyceal dilatation of the kidneys.

on her leg. She died after vomiting coffee-ground blood, suggestive of a gastro-intestinal bleed, at 147 days of age. No post-mortem was carried out, but the bleed was not thought to be related to the previous PA.

The infant's skin biopsy showed separated strips of epidermis, and a small fragment of dermis without overlying epidermis. Transmission electron microscopy (TEM) examination of another skin biopsy showed the basement membrane (BM) to be thin, with reduced numbers of HD along the dermo-epidermal junction (Fig. 2E). In addition, occasional breaks in the lamina densa were seen. IFM revealed type IV collagen monoclonal antibody below the blister, laminin V  $\beta 3$  chain monoclonal antibody K140 positive below the blister; anti-*ITGA6* and *ITGB4* were negative, although they were positive in normal human skin controls (Fig. 2A and B).

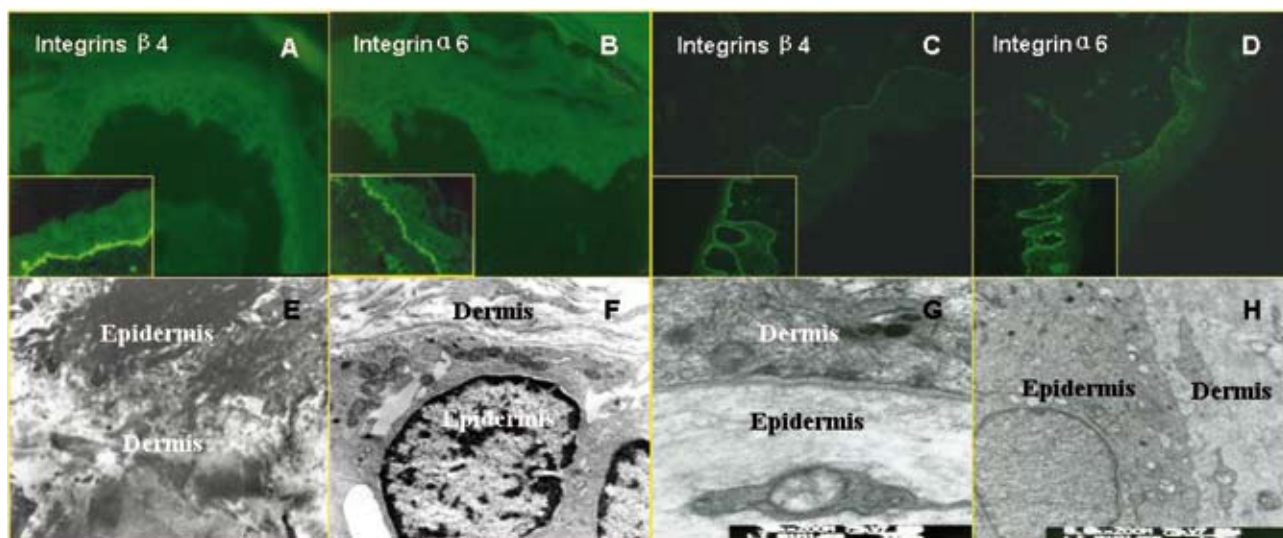
Mutation screening of *ITGB4* revealed a then-novel c.658delC mutation in exon 7 of maternal origin and p.R252C in exon 8 of paternal origin. The c.658delC is predicted to cause a downstream stop codon in exon 8. The p.R252C was confirmed by digestion with NarI. This mutation is located in the extracellular domain and has been described previously in association with PA (3, 4). As only one mutation is a PTC, it is unclear why the IFM was negative for both integrin  $\beta 4$  and  $\alpha 6$ . This family subsequently underwent prenatal diagnosis and an affected pregnancy was terminated. A third pregnancy resulted in a heterozygous carrier, but unfortunately this pregnancy was affected by an unrelated fatal condition, thanatophoric dwarfism, and was also terminated.

**Family 2: EB-049.** A female infant was born preterm at 33 weeks by caesarean section following spontaneous

pre-term labour, due to transverse lie and possible maternal sepsis. Her parents were non-consanguineous. She suffered severe respiratory distress syndrome and sepsis and was noted to have widespread erosions and fragile skin along with dysmorphic ears. As she was anuric, a renal ultrasound was performed which showed the ureters to be dilated. She died on day 2 from hyaline membrane disease due to prematurity and renal failure due to EB.

There was marked aplasia cutis in patches throughout the body, especially over the left and right lateral sides of face, the whole neck (Fig. 1C), the lateral aspect of the right upper limb, the left knee, the dorsal surface of both feet, the left and right shins, the dorsal surface of both hands, and the left upper arm. The head was abnormal with dysmorphic facies, the ears were markedly atrophic, but the external auditory meati were apparent (Fig. 1C), the nasal tip was hypoplastic with overlying aplasia cutis. The nares and choanae were patent (Fig. 1D), the eyes were asymmetrical with an ectropion affecting the left lower eyelid, the globes appeared normal and the palpebral fissures were down-slanting bilaterally, the alveolar plates and tongue appeared normal.

On post-mortem, the external appearance of the stomach was normal and internally, no evidence of pyloric stenosis or atresia was apparent externally; the mucosal surface appeared only slightly congested (Fig. 1G). The urinary bladder was very narrow between the umbilical arteries, but was present; the ureters showed marked tortuosity and dilatation; the kidneys were enlarged but reniform and on section there was marked pelvicalyceal dilatation (Fig. 1H). Histological examination of biopsies from involved skin revealed a small amount of dermis and subcutaneous tissue, the overlying epidermis



**Fig. 2.** Immunofluorescence mapping (IFM) and electron microscopy (EM) of the skin of probands with junctional epidermolysis bullosa with pyloric atresia. The epidermis and dermis were indicated and labelled. (A and B) IFM in EB050 showing negative staining for integrins  $\alpha 6$  and  $\beta 4$ . (C and D) IFM in EB013 showing markedly reduced staining of integrins  $\alpha 6$  and  $\beta 4$  compared to controls. (E) EM in EB050 showing separation in the lamina lucida and grossly reduced hemidesmosomes with abnormal structure. (F) EM in EB049 showing a widening gap between the basal lamina and base of the epidermal cells at the right edge. (G) EM in EB013 showing a reduced number of hemidesmosomes at the basement membrane zone (BMZ), which are rudimentary in structure. (H) EM in EB013 showing a total absence of hemidesmosomes in the portion of the BMZ demonstrated.

Table I. Clinical features of junctional epidermolysis bullosa with pyloric atresia (JEB-PA) due to ITGB4 mutations. Summary of those cases reported in substantial clinical detail along with their mutations. Note: 16 cases from Varki (36) are omitted as the only substantial clinical feature listed was pyloric atresia and the other clinical features of these cases listed were variable

Case (Ref)	Proband age/sex	Ethnic origin	Consanguinity (Yes/No)	Pyloric atresia (Yes/No)	Skin	Nail	Dental	Ear or nose	Eye	Kidney	Miscellaneous
1 (2)	Alive at 3 years/M	British	N	Y	Mild skin fragility to mechanical trauma	Dystrophy	-	-	-	Hydro-nephrosis	-
2 (2)	Alive at 6 years/M	British	N	Y	Scanty blisters, erosions on limbs during 1st day	Dystrophy	Enamel hypoplasia	-	-	Haematuria and dysuria in 3 <sup>rd</sup> years	-
3 (3)	Alive at 7 years/F	Turkish	Y	Y at birth	Skin involvement at 2 years	Dystrophy	Enamel pitting	-	-	-	-
4 (3)	Alive at 10 mo./M	Bangladeshi	-	Y	Blisters on fingers, toes, scalp	-	-	-	-	-	Antral atresia at birth
5 (3)	Alive at 4 mo./M	Jewish	Y	Y at birth	Blisters on the sacral area at 3 months	Dystrophy at 2 months	-	-	-	Severe nephrotic syndrome	-
6 (4)	Alive at 15 mo./F	-	-	Y	Severe blistering at birth, absent at 1 year	-	-	-	-	-	-
7 (4)	Alive at 13 years/F	-	-	Y	Scarring on legs	-	Hypoplastic enamel	-	Ocular involvement	Urologic obstruction	Laryngeal obstruction
8 (4)	Alive at 13 mo./NG	-	-	Y	Mild blistering	-	-	-	Severe corneal erosions	-	-
9 (5)	Alive at 18 mo./M	-	N	Y at birth	Mild blistering	Dystrophy	-	-	-	-	Extra unilateral sixth toe
10 (38)	Demise at 2 years/F	Korean	N	Y after birth	Blisters on the trunk and extremities since birth	-	-	-	-	-	Chronic diarrhoea, pneumonia
11 (27)	Alive at 68 years/M	Japanese	Y	N	Blisters at birth, life-long trauma-induced skin fragility	Dystrophy	Loss of permanent dentition	-	-	Recurrent urethral stenosis for 12 years	Alopecia, absence of axillary and pubic hair
12 (6)	Alive at 14 years/M	-	N	Y at birth	Extensive blistering at birth, improvement with age	-	-	-	-	Urethro-vesical occlusion	-
13 (EB013-2*)	Alive at 4.5 years/M	Chinese	N	Y	Blisters on feet	-	-	-	-	-	-
14 (EB013-1*)	Alive at 8 years/F	Chinese	N	N	Blisters in hands and feet	-	-	-	-	-	-
15 (8)	Demise at 3 mo./M	Indian	-	Y	Denuded areas over neck, extremities, Denuded over the right ear	-	-	-	Corneal erosion	-	-
16 (8)	Demise at 4 days/M	-	N	Y	Extensive blistering	Shedding of the nails	-	-	-	-	-
17 (8)	Demise at 66 days/M	Pakistani	Y	Y	Blisters and erosions at birth, involvement mucosa	-	-	-	-	-	Protein-losing enteropathy, died from pseudomonas sepsis
18 (23)	Demise at 2.5 mo./F	Italian	N	Y at birth	Generalized blisters and erosions at birth	-	-	Nasal hypoplasia	-	-	-

Table 1 continued

19 (3)	Demise at 3 mo./M	-	N	Y at birth	Generalized blistering and erosions at birth	-	-	-	Swallowing dysfunction, aspiration
20 (3)	Demise at 2 weeks/F	-	-	Y at birth	Extensive blistering in 1st wk	-	-	-	-
21 (39)	Demise at 13 days/F	-	N	Y	Large areas of blisters and erosions	-	Ears hypoplastic	-	Severe sepsis
22 (EB050*)	Demise at 4.5 mo./F	Caucasian	N	Y	Mild blistering at birth	-	-	-	Anaemia, respiratory distress, gastro-oesophageal reflux
23 (4)	Demise at 2 mo./M	-	-	Y	Aplasia cutis congenita of all 4 extremities	-	-	Multicystic dysplasia of left kidney, hydro-nephrosis of right kidney	Oesophageal trachea, bladder, small intestinal involvement
24 (4)	Demise at 1 mo./F	-	-	Y	-	-	-	-	Obstructed sigmoid colon
25 (4)	Demise at 2.5 mo./M	-	-	Y	Mild blistering at birth	-	-	-	-
26 (31)	Demise at the day after birth/F	Italian	N	Y	Widespread blisters and erosions at birth, Skin aplasia of legs, feet	-	Skin aplasia of ears and nose	-	Severe oesophageal stenosis
27 (31)	Demise at 7.5 months/F	Turkish	N	Y after birth	Several blisters on the trunk at 3rd days, involved mucosa	-	-	-	Respiratory system infection
28 (9)	Demise at 8 mo./NG	French, Italian	N	Y at birth	Cutis aplasia of left hand, blisters and erosions of mucosa	-	-	-	Generalized infection
29 (22)	Demise at 4 mo./NG	Jordanian	Y	Y	Extensive blistering and erosions	-	-	-	Secondary bacterial superinfection
30 (22)	Demise at 4 mo./NG	Spanish	Y	Y	Extensive blistering and erosions	-	-	-	Secondary bacterial superinfection
31 (26)	Demise at 11 days/NG	Japanese	-	Y at birth	Extensive blisters at birth	-	-	-	-
32 (25)	Demise at 1 mo./NG	German	Y	Y at 2nd days	Large skin defects in right legs, right arms, neck at birth	-	-	-	Spontaneous breathing, cardiovascular distress
33 (EB049*)	Demise at 2 days/F	Caucasian	N	N	Widespread blistering and skin fragility	-	Ears, nose atrophic	Ectropion, palpebral fissures	Pelvic/lyceal dilatation; tortuous ureters
34-49 (36)	V	V	V	Y	V	V	V	V	V
	Varki 06								

\*This study. V: Variable; NG: not given.

was largely lost. TEM showed HD on the most proximal layer of the blister roof were few and poorly formed (Fig. 2F). IFM of skin biopsies showed cleavage within the lamina lucida with absence of staining for  $\beta$ 4 and  $\alpha$ 6 integrin. In addition, antibodies to laminin V  $\beta$ 3,  $\alpha$ 3,  $\gamma$ 2 chain, type IV collagen, type VII collagen, LAD1 and CD151 were positive below the blister (lamina lucida); and antibodies to BP230, BP180, plectin, and keratin5/6, 14 were positive above the blister.

Molecular analysis of genomic DNA extracted from blood saved after death was performed using the same PCR and sequencing primers as those developed for Family 1. This revealed heterozygous *ITGB4* mutations c.3903dupC/p.G273D. The novel mutation c.3903dupC in exon 31 was a single base insertion, which is predicted to cause a frameshift and a downstream stop codon in exon 31, resulting in a prematurely truncated protein product, or nonsense-mediated mRNA decay. The p.G273D was detected in exon 8, resulting in the substitution of aspartate for glycine at a highly conserved codon 273. This mutation has been reported in association with PA and another missense mutation (Case 30, Table II) (4).

**Family 3: EB013-1 and 013-2.** This Chinese girl (EB013-1), now 8-years-old, was born in mainland China to non-consanguineous parents and had blisters on the hands at birth. She did not have PA. A clinical diagnosis of EB simplex-Weber-Cockayne was made, but no further investigations were performed. The family moved to Australia and her blisters remained mostly localized to the feet (Fig. 1E). The blistering was exacerbated both by extensive walking and during the summer. There was no scarring or atrophy from the blisters and no other health problems noted. Her now 4-year-old brother (EB013-2) was born in Australia and had PA at birth, which was surgically repaired. He developed blisters on the feet, which were not as severe as his sister's (Fig. 1F). There was no scarring, atrophy or milia from the blisters. IFM of a skin biopsy specimen showed no blistering, and staining for both integrins  $\alpha$ 6 and  $\beta$ 4 was markedly reduced compared with controls (Fig. 2C and D), whereas all other antibodies used routinely, including collagen VII, stained normally. Unusually, GOH3 against integrin  $\alpha$ 6 stained basal and suprabasal keratinocytes. EM showed a decreased number of HD at the BM zone, which were rudimentary in structure (Fig. 2G and H).

*ITGB4* gene mutation studies were performed. The paternal mutation was identified as c.264G>A at the exon/intron 4 splice junction. The paternal grandfather was also found to be a carrier of this mutation. The maternal mutation was identified as c.3111-1G>A at the border of intron 26 and exon 27, predicted to alter the consensus splice sequence. Two years later they still had very mild blistering (Fig. 1E and F).

Table II. Mutations in *ITGB4* reported to date in patients with junctional epidermolysis bullosa with pyloric atresia (JEB-PA). This is a comprehensive list including those condensed in Table I from Varaki (36)

Case (Ref.)	Mutations	Exon or intron	Location in protein	Consequences	Clinical variability	IF mapping	EM
1 (2)	C38R/4776delG	E3/E36	EC/FnIII 3	Mis/PTC	Non-lethal	B4, A6 greatly reduced;laminin-5 normal; bp180, 230, plectin reduced	Hypoplastic HDs, separated in intracellular
2 (2)	3793+1G-A/W1478X	E30/E36	FnIII 2/ FnIII 3	PTC/PTC	Non-lethal	B4 greatly reduced;A6 positive, laminin-5 normal	Hypoplastic HDs, lamina lucida separate
3 (3)	C562R/C562R	E14/E14	CR3/CR3	Mis/Mis	Non-lethal	B4, A6 reduced;laminin 5 normal	Hypoplastic HDs without distinct inner and outer plaques
4 (3)	R252C/R1281W	E8/E31	EC/FnIII 2	Mis/Mis	Non-lethal	-	-
5 (3)	R1281W/R1281W	E31/E31	FnIII 2/ FnIII 2	Mis/Mis	Non-lethal	B4 reduced;A6, laminin 5, BP230 normal	-
6 (4)	ND/R283C	ND/E8	ND/EC	ND/Mis	Non-lethal	B4 red A6 red;plec altered	HDs cleavage
7 (4)	3112-3C-T, L336P/R1225H	I26, E9/E30	CP, EC/FnIII 2	Mis, Mis /Mis	Non-lethal	B4 normal, A6 normal, plectin normal/altered	-
8 (4)	4790delTC/4790delTC	E36/E36	FnIII 3/FnIII 3	PTC/PTC	Non-lethal	B4 red; A6 red;plec alt	Hypoplastic HDs, absence of sub-basal densa plate, lamina lucida cleavage
9 (5)	L156P/R554X	E5/E14	EC/CR3	Mis/PTC	Non-lethal	B4 normal;A6 attenuated;cytokeratins, BP230, colXVII, IV, VII, laminin 5 normal	Hypoplastic HDs without distinct inner and outer plaques
10 (38)	594insC/Q425P	E7/E11	EC/EC	PTC/Mis	Lethal	B4 absence	Lamina lucida separate
11 (27)	G931D/G931D	E25/E25	CP/CP	Mis/Mis	Non-lethal	B4, A6, plectin, BP230 weakened;col XVII, VII, laminin 5 normal	Hypoplastic HDs, lamina lucida separate
12 (6)	3977-19T-A/3793+1G-A	I31/I30	CP/FnIII 2	PTC/in-frame deletion	Non-lethal	B4, A6 reduced	Mature HDs

Table II continued

		14/126	EC/CP	Spl/Spl	Non-lethal	B4, A6 reduced, laminin 5, col IV, VII, BP230, BP180, plectin, keratin 5/6, 14 Positive	Hypoplastic HDs, lamina lucida cleavage
13 (EB013-2*)	<b>264G&gt;A/3111-IG&gt;A</b>	14/126	EC/CP	Spl/Spl	Non-lethal	B4, A6 reduced, laminin 5, col IV, VII, BP230, BP180, plectin, keratin 5/6, 14 Positive	Hypoplastic HDs, lamina lucida cleavage
14 (EB013-1*)	<b>264G&gt;A/3111-IG&gt;A</b>	14/126	EC/CP	Spl/Spl	Non-lethal	B4, A6 reduced, laminin 5, col IV, VII, BP230, BP180, plectin, keratin 5/6, 14 Positive	Hypoplastic HDs, lamina lucida cleavage
15 (8)	120delITG/C245G	E3/E7	EC/EC	PTC/Mis	Lethal	B4 Neg: A6 barely detectable; laminin 5 normal	Hypoplastic HDs
16 (8)	Q73X/ND	E4/ND	EC/ND	PTC/ND	Lethal	—	Hypoplastic HDs
17 (8)	4501delITC/4501delITC	E34/E34	CP/CP	PTC/PTC	Lethal	—	Hypoplastic HDs, Lamina lucida cleavage
18 (23)	ΔR59-A69 del11/ΔR59-A69 del11	E4/E4	EC	In-frame deletion	Lethal	B4 Neg: A6 reduced	Hypoplastic HDs, Lamina lucida cleavage
19 (3)	C738X /4791delICA	E18/E36	CP/FnIII 3	PTC/PTC	Lethal	B4, A6 reduced; Laminin 5, coll IV, VII, XVII, BP230, plectin/HD1 normal	Hypoplastic HDs
20 (3)	C61Y/C61Y	E4/E4	EC/EC	Mis/Mis	Lethal	—	Absence HDs
21 (39)	3807delC/310delC	E31/E5	FnIII 2/EC	PTC/PTC	Lethal	B4 Neg: A6 reduced	Lamina lucida cleavage
22 (EB050*)	658delC/R252C	E7/E8	EC/EC	PTC/Mis	Lethal	B4, A6 Neg: plectin dec, BP180 red	Lamina lucida cleavage, reduced HDs
23 (4)	D131Y/G273D	E5/E8	EC/EC	Mis/Mis	Lethal	B4 Neg: A6 Neg	—
24 (4)	1874delITC/TinsC/V325D	E16/E8	EC/EC	PTC/Mis	Lethal	B4 Neg: A6 red, plectin altered, neg BP180	Lamina lucida cleavage
25 (4)	Q1767X/Q1767X	E41/E41	CP/CP	PTC/PTC	Lethal	—	Intraepidermal cleavage
26 (31)	ΔN318del/ND	E8/ND	EC/ND	In frame del/ND	Lethal	B4 Neg: A6 reduced; col VII, XVII, laminin 5 normal	Hypoplastic HDs, Lamina lucida cleavage
27 (31)	4298-4299ins4/R252C	E34/E8	CP/EC	PTC/Mis	Lethal	B4 markedly reduced; A6 reduced; col VII, XVII, lamin 5 normal	Hypoplastic HDs, Lamina lucida cleavage
28 (9)	1150delG/3801+2insT	E10/I30	EC/FnIII 2	PTC/in-frame deletion	Lethal	B4, A6 markedly reduced; BP230, HD1 reduced; laminin 5 normal	Hypoplastic HDs, Lamina lucida cleavage
29 (22)	1379-2A-G/1379-2A-G	I11/I11	CR1/CR1	PTC/PTC	Lethal	—	—
30 (22)	3321delI/3321delI	E28/E28	CP/CP	PTC/PTC	Lethal	—	—
31 (26)	3434delIT/4050del8	E28/E32	FnIII 1/CP	PTC/PTC	Lethal	B4 reduced; A6 Neg; laminin 5, col VII, IV, BP230, BP180 normal	—
32 (25)	3793+1G-A/3793+1G-A	I30/I30	FnIII2/FnIII2	PTC/PTC	Lethal	—	Hypoplastic HDs without distinct inner and outer plaques
33 (EB049*)	G273D/ <b>3903dupC</b>	E8/E31	EC/FnIII 2	Mis/PTC	Lethal	B4, A6 neg; others normal	Abnormal HDs
34 (36)	Q866X/Q866X	E22/E22	CP/CP	PTC/PTC	Non-lethal	—	—
35 (36)	600delC/ND	E7/ND	EC/ND	PTC/ND	Non-lethal	—	—
36 (36)	953del3/953del3	E8/E8	EC/EC	PTC/PTC	Non-lethal	—	—
37 (36)	4580del2/4580del2	E35/E35	CP/CP	PTC/PTC	Non-lethal	—	—
38 (36)	5046delC/5046delC	E37E37	FnIII 4/FnIII 4	PTC/PTC	Non-lethal	—	—
39 (36)	R60C/3793+1G-A	E4/I30	EC/FnIII 2	Mis/PTC	Non-lethal	—	—
40 (36)	2250+1G-A/3793+1G-A	I19/I30	CP/FnIII 2	Spl/PTC	Non-lethal	—	—
41 (36)	C706X/2254+4A-G	E18/I19	EC/CP	PTC/PTC	Lethal	—	—
42 (36)	125del2/C245G	E3/E7	EC/EC	PTC/PTC	Lethal	—	—
43 (36)	884del2/957del4	E8/e8	EC/EC	PTC/PTC	Lethal	—	—
44 (36)	4576del2/C738X	E35/E18	CP/CP	PTC/PTC	Lethal	—	—
45 (36)	5040delC/ND	E9/ND	FnIII 4/ND	PTC/ND	Lethal	—	—
46 (36)	E357X/ND	E9/ND	EC/ND	PTC/ND	Lethal	—	—
47 (36)	C245Y/C61Y	E8/E4	EC/EC	Mis/Mis	Lethal	—	—
48 (36)	G1307W/G1307W	E31/E31	FnIII 2/FnIII 2	Mis/Mis	Lethal	—	—
49 (36)	2254+4A-G/C706X	I19/E18	CP/EC	Spl/PTC	Lethal	—	—

\*In this study

EM: electron microscopy; EC: extracellular domain; CR: cysteine-rich domain (4 EGF-like repeat domains each with 8 cysteine residues); TM: transmembrane segment; CP: the large cytoplasmic domain; FnIII: fibronectin III-like domains; ND: not determined; PTC premature termination codons; Mis: missense; Spl: splice site. Bold text are novel mutations in this study.

DISCUSSION

*Clinical analysis*

We have identified 50 cases of JEB-PA reported in the literature, including the 4 cases reported here. Twenty-three of the previously reported cases had TEM performed, which predominantly showed blistering within the lamina lucida (8, 9, 25, 26). However, blistering within the basal cell and even below the lamina densa had been reported in some patients (8). IFM demonstrated reduced immunoreactivity to integrin  $\beta 4$  in non-lethal cases, and complete absence in lethal cases (Tables I and II). Three cases with JEB caused by an *ITGB4* mutations did not have gastrointestinal atresia, including one reported by Inoue et al. (27) and cases 2 and 3 reported here. In addition to PA, other commonly reported complications in these patients included nail dystrophy ( $n=7$ ), enamel hypoplasia ( $n=4$ ), aplasia cutis congenita or congenital localized absence of skin ( $n=6$ ), eye involvement ( $n=4$ ), ear or nose hypoplasia or atrophy ( $n=4$ ), urinary tract involvement ( $n=8$ ) and respiratory involvement ( $n=5$ ). Many patients died of this disease owing to the extensive denudation of skin, resultant loss of barrier function, fluid and electrolyte problems and sepsis. Difficulty with oral feeding and the development of diarrhoea seem to be common features in many of these cases.

*Identification of novel mutations in this study*

In our study of 3 families with JEB-PA, we have described 4 probands with 3 novel *ITGB4* mutations: 2 splice-

site mutations (c.264G>A/C and c.3111-1G>A) and one insertion mutation (c.3903dupC) (Table II, Fig. 3). Two cases had lethal phenotypes due to the combination of PTC and missense mutations (c.3903dupC/p.G273D and c.658delC/p.R252C). The PTC mutations may cause mRNA decay or result in truncated non-functional  $\beta 4$  integrin polypeptides and the missense mutations will determine the phenotype of patients when non-functional  $\beta 4$  integrin polypeptides are synthesized (4). Because arginine-252 and glycine-273 are located in a highly conserved region that may abolish ligand-binding properties similar to those of  $\beta 3$  integrin (4), the phenotypes are lethal when p.G273D and p.R252C are combined with PTC mutations (c.3903dupC and c.658delC, respectively). Additionally, p.R252C, which creates a new cysteine residue, may change disulphide bonding and alter the secondary structure of the polypeptide, resulting in the loss of the putative ligand-binding function of the  $\beta 4$  integrin. There were 2 novel mutations in our non-lethal cases including c264G>A and c.3111-1G>A, and both mutations are predicted to cause mis-splicing, but we were not able to determine the exact nature of the products.

It is interesting that we found 2 cases without PA, cases 2 (c.3903dupC/p.G273D) and 3 (c.264G>A/c.3111-1G>A). The latter's affected brother, with the same mutations, did have PA, and we found a similar report of a homozygous c.1856+1G>T mutation in the cytoplasmic domain of *ITGA6* in a family with 3 affected individuals with JEB-PA, but one child did not have duodenal atresia (28). Inoue et al. (27) also reported one

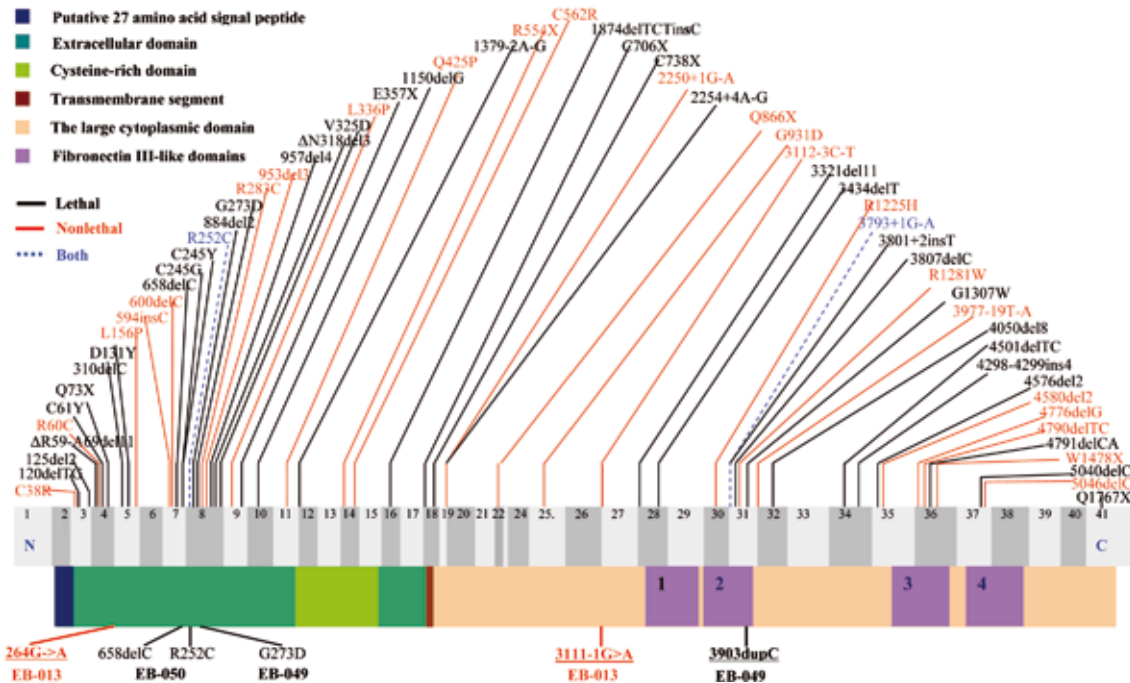


Fig. 3. Mutations in *ITGB4* with JEB-PA. Schematic diagram of the *ITGB4* gene above showing the exons in alternating dark and light grey. The representative domains of the integrin  $\beta 4$  protein, are shown below, in different colours indicated by the bar key. The published mutations above are shown above in black if they have occurred in lethal cases, red in non-lethal cases and blue if in both. The mutations in the cases in this report are indicated below.



non-lethal JEB case without PA due to homozygous *ITGB4* mutations p.G931D/p.G931D affecting the cytoplasmic tail of integrin  $\beta 4$ . Overall, at least one mutation, either in *ITGB4* or *ITGA6*, was located in the cytoplasmic domain; however, it could not provide evidence for a domain with a functional role relevant to the development of PA. Recently, the plectin gene was emphasized to be important in the pathogenesis of EB-PA (29, 30) and perturbed interactions between plectin and  $\alpha 6\beta 4$  integrin within attachment structures expressed during gastrointestinal development were proposed as a possible cause of the PA (29). Nevertheless, *ITGA6* and *ITGB4* knock-out mice expressed the cutaneous JEB phenotype but not the PA, suggesting that there may be other factors involved (30).

#### *Genotype-phenotype correlation from ITGB4 mutations reported in the literature and in this study*

We have summarized a total of 49 cases with JEB-PA, 21 being classified as non-lethal cases and 28 as lethal cases (Table II). From the mutation database in *ITGB4*, there is a predominance of PTC mutations in the lethal forms, whereas compound heterozygous missense and PTC mutations are more common in the non-lethal cases. In fact, 22 (78.6%) of lethal cases of JEB-PA had PTC mutations in at least one allele, 4 cases (14.3%) had missense mutations in both alleles and 2 cases (7.1%) had in-frame deletions. In contrast, in non-lethal forms of JEB-PA, at least 19 of 41 alleles (46.3%) in 13 individuals were PTC mutations, 15 alleles (36.6%) were missense mutations and 7 alleles (17.1%) were splice site mutations. This is in contrast to previous reports suggesting that the presence of a missense or splice mutation in at least one allele predicted a milder phenotype (31). It appears that one PTC mutation is not necessarily predictive of lethality, nor is PA. All reported cases of JEB-PA with a lethal outcome who had IFM performed, had either absent or markedly attenuated staining for integrin  $\beta 4$ , in contrast to the non-lethal cases (Table II).

#### *Prevalence of PTC/PTC mutations in lethal JEB-PA*

Nonsense, small out-of-frame insertion or deletion mutations in *ITGB4* predicted synthesis of a truncated polypeptide and/or down-regulation of the *ITGB4* mRNA levels by nonsense-mediated mRNA decay (32, 33). Thus, no functional integrin  $\beta 4$  polypeptides are synthesized, resulting in the JEB-PA phenotype. The presence of PTC mutations in both alleles, either in a homozygous or compound-heterozygous state, would result in a lethal phenotype (3). For example, in Case 19 (Table II), p.C738X/c.4791delCA, combined 2 PTC mutations. The p.C738X mutation within the large cytoplasmic domain was adjacent to the transmembrane segment and is predicted to cause deletions of the entire

intracellular domain of the integrin  $\beta 4$  polypeptide, which could affect HD assembly, but ligand binding is preserved (34). The c.4791delCA mutation is predicted to delete the region spanning the last 278 amino acids, which have been identified to interact with the 180-kD bullous pemphigoid antigen (BP180) (35).

However, some non-lethal cases, for example cases 8, 37 and 38 were homozygous for PTC/PTC mutations: 4790delTC/4790delTC, 4580del2/4580del2 and 5046delC/5046delC, respectively (4, 36). IFM was only reported for case 8, showing reduced but positive staining of both integrins  $\alpha 6\beta 4$ . Case 2 was heterozygous for a PTC mutation (3793+1G-A/W1478X) with positive but reduced staining for integrin  $\beta 4$  and normal integrin  $\alpha 6$  staining (2). All of these mutations predicted truncation of integrin  $\beta 4$  polypeptides close to the carboxyl-terminal end (Fig. 3), and might have minor effects.

#### *Missense/missense mutations resulted different clinical variants in a position-dependent pattern*

Four lethal and 4 non-lethal JEB-PA cases with *ITGB4* (3, 4, 27, 36) mutations had missense/missense combinations, which suggested that the position of these mutations influenced the phenotype. The mutations in 3 lethal cases were located in the extracellular domain of the integrin  $\beta 4$  protein (cases 20, 23, 47 in Table II) (3, 4, 36). The mutations p.C61Y/p.C61Y and p.C245Y/p.C61Y changed cysteine residues to lysine, which may interfere with the formation of intra- or inter-chain disulphide bonds and subsequently change the conformation and/or ligand-binding affinity of integrin  $\beta 4$  (3). Some of the missense mutations in *ITGB4*, including these ones, resulted in substitution of highly conserved cysteine residues, most of which were associated with a severe phenotype (22). Alternatively, missense mutations that affect highly conserved residues may have significant effects. For example, in Case 23 (p.D131Y/p.G273D), which was lethal at only 2 months of age, aspartic-131 and glycine-273 are located in a highly conserved region, so these mutations may abolish important ligand-binding sites of integrin  $\beta 4$  (4). Our second case which was also lethal also included this p.G273D mutation.

Previous work has shown that the recruitment of plectin into HD was dependent on a region of the integrin  $\beta 4$  cytoplasmic domain containing the first 2 FNIII repeats and a short region of the CS (14, 18). Two missense mutations, p.R1281W (cases 4 and 5 in Table II) and p.R1225H (case 7 in Table II) in the non-lethal form of JEB-PA were located in the second FNIII repeat (3, 4). R1281W was located in a loop region that connected 2  $\beta$  strands, whereas R1225H is located at the N-terminal end of the second FNIII repeat (37). Both mutations caused a disruption of the interactions with plectin. Thus, the linkage of the intermediate filaments to HD was likely to be compromised because of an inability of integrin  $\beta 4$  to

recruit plectin into HD. This helps to explain why these mutations caused a non-lethal type of JEB-PA.

Collectively, most of the missense mutations and the amino acids deletions described in lethal JEB-PA were located in the extracellular domain of *ITGB4*. Missense or splice mutations associated with the non-lethal form were frequently located in the cytoplasmic tail (4, 8, 36) (Fig. 3).

#### *Missense/PTC mutations associated with lethal and non-lethal phenotype*

The presence of a missense mutation in one allele combining with a PTC mutation could predict a more variable phenotype. Six lethal cases in previous study (case 15, 22, 24 and 27 in Table II) (4, 8, 31) and in this study (case 33, EB-50) and 4 non-lethal cases (case 1, 9, 10 and 39) (2, 5, 36, 38) were compound heterozygotes for PTC and missense mutations. PTC could cause mRNA decay or synthesize truncated non-functional integrin  $\beta 4$  polypeptides. Therefore, the missense mutation would direct the phenotype of patients. For example, p.C245G along with p.R252C highly conserved amino acids located in a putative ligand-binding region in integrin  $\beta 4$  polypeptides in human, rat and mouse (4, 8); these mutations created or abolished cysteine residues changing disulphide bonding and the secondary structure of the integrin  $\beta 4$  polypeptides. Mutations p.V325D and p.G273D also occurring in a conserved position substitute a non-polar for an acidic residue (4). Therefore, these phenotypes were lethal when PTCs were combined with missense mutations, including c.120delTG/p.C245G, c.658delC/p.R252C, c.1874delTCTinsC/p.V325D, c.4298-4299ins4/p.R252C and c.3903dupC/p.G273D (4, 8, 31).

In non-lethal cases, such as Case 1 (p.C38R/c.4776delG), c.4776delG resulting in a downstream PTC also predicted an unstable mRNA transcript. The missense mutation, p.C38R, arose in the part of the extracellular amino-terminal domain, a position in a highly conserved region in terms of different integrin  $\beta 4$  polypeptides and different species. So the mutation might disrupt heterodimer formation with the integrin  $\alpha 6$  subunit or interaction with ligands within the lamina lucida. Perturbation rather than abolition of  $\beta 4$  subunit function by p.C38R might explain the mild phenotype with only minimal cutaneous involvement and no evidence of other manifestation (2).

In summary, we have identified a total of 3 novel mutations in all 6 *ITGB4* alleles of 4 patients affected with JEB-PA, 2 of them without PA. The results indicated that PTC mutations in both alleles in either a homozygous or compound heterozygous state would be more likely to result in a lethal phenotype. Missense mutations, either in combination with a PTC mutation or in both alleles, could predict either a lethal or non-lethal variety, the latter more likely to be related to positive integrin

$\beta 4$ . Missense mutations causing substitutions of highly conserved amino acids might be associated with a lethal phenotype, while less conserved amino acid substitutions caused milder phenotypes. However, in these cases it would be difficult to predict the phenotype from the genotype as this may depend not only on the nature of the mutations but may also be influenced by other, as yet unknown, genetic or environmental factors.

#### ACKNOWLEDGEMENTS

We acknowledge Jinan Central Hospital, Shandong Province, China for supporting Dr Dang's postdoctoral studies with DM. Also, a grant from DEBRA Australia to DM to support Dr Dang's work for an extended time in Australia. This work was selected for oral presentation at the Australasian Society for Dermatological Research and the European Academy of Dermatovenereology in May 2007.

#### REFERENCES

- Dank JP, Kim S, Parisi MA, Brown T, Smith LT, Waldhausen J, Sybert VP. Outcome after surgical repair of junctional epidermolysis bullosa-pyloric atresia syndrome: a report of 3 cases and review of the literature. *Arch Dermatol* 1999; 135: 1243-1247.
- Mellerio JE, Pulkkinen L, McMillan JR, Lake BD, Horn HM, Tidman MJ, et al. Pyloric atresia-junctional epidermolysis bullosa syndrome: mutations in the integrin beta4 gene (*ITGB4*) in two unrelated patients with mild disease. *Br J Dermatol* 1998; 139: 862-871.
- Pulkkinen L, Rouan F, Bruckner-Tuderman L, Wallerstein R, Garzon M, Brown T, et al. Novel *ITGB4* mutations in lethal and nonlethal variants of epidermolysis bullosa with pyloric atresia: missense versus nonsense. *Am J Hum Genet* 1998; 63: 1376-1387.
- Nakano A, Pulkkinen L, Murrell D, Rico J, Lucky AW, Garzon M, et al. Epidermolysis bullosa with congenital pyloric atresia: novel mutations in the beta 4 integrin gene (*ITGB4*) and genotype/phenotype correlations. *Pediatr Res* 2001; 49: 618-626.
- Pulkkinen L, Bruckner-Tuderman L, August C, Uitto J. Compound heterozygosity for missense (L156P) and nonsense (R554X) mutations in the beta4 integrin gene (*ITGB4*) underlies mild, nonlethal phenotype of epidermolysis bullosa with pyloric atresia. *Am J Pathol* 1998; 152: 935-941.
- Chavanas S, Gache Y, Vailly J, Kanitakis J, Pulkkinen L, Uitto J, et al. Splicing modulation of integrin beta4 pre-mRNA carrying a branch point mutation underlies epidermolysis bullosa with pyloric atresia undergoing spontaneous amelioration with ageing. *Hum Mol Genet* 1999; 8: 2097-2105.
- Fine JD, Bauer EA, Briggaman RA, Carter DM, Eady RA, Esterly NB, et al. Revised clinical and laboratory criteria for subtypes of inherited epidermolysis bullosa. A consensus report by the Subcommittee on Diagnosis and Classification of the National Epidermolysis Bullosa Registry. *J Am Acad Dermatol* 1991; 24: 119-135.
- Pulkkinen L, Kim DU, Uitto J. Epidermolysis bullosa with pyloric atresia: novel mutations in the beta4 integrin gene (*ITGB4*). *Am J Pathol* 1998; 152: 157-166.
- Vidal F, Aberdam D, Miquel C, Christiano AM, Pulkkinen L, Uitto J, et al. Integrin beta 4 mutations associated with

- junctional epidermolysis bullosa with pyloric atresia. *Nat Genet* 1995; 10: 229–234.
- 10 Hogervorst F, Kuikman I, von dem Borne AE, Sonnenberg A. Cloning and sequence analysis of beta-4 cDNA: an integrin subunit that contains a unique 118 kd cytoplasmic domain. *EMBO J* 1990; 9: 765–770.
  - 11 Rebay I, Fleming RJ, Fehon RG, Cherbas L, Cherbas P, Artavanis-Tsakonas S. Specific EGF repeats of Notch mediate interactions with Delta and Serrate: implications for Notch as a multifunctional receptor. *Cell* 1991; 67: 687–699.
  - 12 Lee EC, Lotz MM, Steele GD Jr., Mercurio AM. The integrin alpha 6 beta 4 is a laminin receptor. *J Cell Biol* 1992; 117: 671–678.
  - 13 Suzuki S, Naitoh Y. Amino acid sequence of a novel integrin beta 4 subunit and primary expression of the mRNA in epithelial cells. *EMBO J* 1990; 9: 757–763.
  - 14 Spinardi L, Ren YL, Sanders R, Giancotti FG. The beta 4 subunit cytoplasmic domain mediates the interaction of alpha 6 beta 4 integrin with the cytoskeleton of hemidesmosomes. *Mol Biol Cell* 1993; 4: 871–884.
  - 15 Tamura RN, Rozzo C, Starr L, Chambers J, Reichardt LF, Cooper HM, Quaranta V. Epithelial integrin alpha 6 beta 4: complete primary structure of alpha 6 and variant forms of beta 4. *J Cell Biol* 1990; 111: 1593–1604.
  - 16 Mainiero F, Pepe A, Wary KK, Spinardi L, Mohammadi M, Schlessinger J, Giancotti FG. Signal transduction by the alpha 6 beta 4 integrin: distinct beta 4 subunit sites mediate recruitment of Shc/Grb2 and association with the cytoskeleton of hemidesmosomes. *EMBO J* 1995; 14: 4470–4481.
  - 17 Dellambra E, Prislei S, Salvati AL, Madeddu ML, Golisano O, Siviero E, et al. Gene correction of integrin beta4-dependent pyloric atresia-junctional epidermolysis bullosa keratinocytes establishes a role for beta4 tyrosines 1422 and 1440 in hemidesmosome assembly. *J Biol Chem* 2001; 276: 41336–41342.
  - 18 Nievers MG, Schaapveld RQ, Oomen LC, Fontao L, Geerts D, Sonnenberg A, et al. Ligand-independent role of the beta 4 integrin subunit in the formation of hemidesmosomes. *J Cell Sci* 1998; 111: 1659–1672.
  - 19 Schaapveld RQ, Borradori L, Geerts D, van Leusden MR, Kuikman I, Nievers MG, et al. Hemidesmosome formation is initiated by the beta4 integrin subunit, requires complex formation of beta4 and HD1/plectin, and involves a direct interaction between beta4 and the bullous pemphigoid antigen 180. *J Cell Biol* 1998; 142: 271–284.
  - 20 van der Neut R, Krimpenfort P, Calafat J, Niessen CM, Sonnenberg A. Epithelial detachment due to absence of hemidesmosomes in integrin beta 4 null mice. *Nat Genet* 1996; 13: 366–369.
  - 21 Dowling J, Yu QC, Fuchs E. Beta4 integrin is required for hemidesmosome formation, cell adhesion and cell survival. *J Cell Biol* 1996; 134: 559–572.
  - 22 Ashton GH, Sorelli P, Mellerio JE, Keane FM, Eady RA, McGrath JA. Alpha 6 beta 4 integrin abnormalities in junctional epidermolysis bullosa with pyloric atresia. *Br J Dermatol* 2001; 144: 408–414.
  - 23 Micheloni A, De Luca N, Tadini G, Zambruno G, D'Alessio M. Intracellular degradation of beta4 integrin in lethal junctional epidermolysis bullosa with pyloric atresia. *Br J Dermatol* 2004; 151: 796–802.
  - 24 Titeux M, Pendaries V, Tonasso L, Décha A, Bodemer C, Hovnanian A. A frequent functional SNP in the MMP1 promoter is associated with higher disease severity in recessive dystrophic epidermolysis bullosa. *Hum Mutat* 2008; 29: 267–276.
  - 25 Pulkkinen L, Kurtz K, Xu Y, Bruckner-Tuderman L, Uitto J. Genomic organization of the integrin beta 4 gene (ITGB4): a homozygous splice-site mutation in a patient with junctional epidermolysis bullosa associated with pyloric atresia. *Lab Invest* 1997; 76: 823–833.
  - 26 Takizawa Y, Shimizu H, Nishikawa T, Hatta N, Pulkkinen L, Uitto J. Novel ITGB4 mutations in a patient with junctional epidermolysis bullosa-pyloric atresia syndrome and altered basement membrane zone immunofluorescence for the alpha6beta4 integrin. *J Invest Dermatol* 1997; 108: 943–946.
  - 27 Inoue M, Tamai K, Shimizu H, Owaribe K, Nakama T, Hashimoto T, McGrath JA. A homozygous missense mutation in the cytoplasmic tail of beta4 integrin, G931D, that disrupts hemidesmosome assembly and underlies Non-Herlitz junctional epidermolysis bullosa without pyloric atresia? *J Invest Dermatol* 2000; 114: 1061–1064.
  - 28 Pulkkinen L, Kimonis VE, Xu Y, Spanou EN, McLean WH, Uitto J. Homozygous alpha6 integrin mutation in junctional epidermolysis bullosa with congenital duodenal atresia. *Hum Mol Genet* 1997; 6: 669–674.
  - 29 Pfindner E, Uitto J. Plectin gene mutations can cause epidermolysis bullosa with pyloric atresia. *J Invest Dermatol* 2005; 124: 111–115.
  - 30 Nakamura H, Sawamura D, Goto M, Nakamura H, McMillan JR, Park S, et al. Epidermolysis bullosa simplex associated with pyloric atresia is a novel clinical subtype caused by mutations in the plectin gene (PLEC1). *J Mol Diagn* 2005; 7: 28–35.
  - 31 Iacovacci S, Cicuzza S, Odorisio T, Silvestri E, Kayserili H, Zambruno G, et al. Novel and recurrent mutations in the integrin beta 4 subunit gene causing lethal junctional epidermolysis bullosa with pyloric atresia. *Exp Dermatol* 2003; 12: 716–720.
  - 32 Frischmeyer PA, Dietz HC. Nonsense-mediated mRNA decay in health and disease. *Hum Mol Genet* 1999; 8: 1893–1900.
  - 33 Hentze MW, Kulozik AE. A perfect message: RNA surveillance and nonsense-mediated decay. *Cell* 1999; 96: 307–310.
  - 34 Spinardi L, Einheber S, Cullen T, Milner TA, Giancotti FG. A recombinant tail-less integrin beta 4 subunit disrupts hemidesmosomes, but does not suppress alpha 6 beta 4-mediated cell adhesion to laminins. *J Cell Biol* 1995; 129: 473–487.
  - 35 Aho S, Uitto J. Direct interaction between the intracellular domains of bullous pemphigoid antigen 2 (BP180) and beta 4 integrin, hemidesmosomal components of basal keratinocytes. *Biochem Biophys Res Commun* 1998; 243: 694–699.
  - 36 Varki R, Sadowski S, Pfindner E, Uitto J. Epidermolysis bullosa. I. Molecular genetics of the junctional and hemidesmosomal variants. *J Med Genet* 2006; 43: 641–652.
  - 37 Koster J, Kuikman I, Kreft M, Sonnenberg A. Two different mutations in the cytoplasmic domain of the integrin beta 4 subunit in nonlethal forms of epidermolysis bullosa prevent interaction of beta 4 with plectin. *J Invest Dermatol* 2001; 117: 1405–1411.
  - 38 Masunaga T, Ishiko A, Takizawa Y, Kim SC, Lee JS, Nishikawa T, Shimizu H. Pyloric atresia-junctional epidermolysis bullosa syndrome showing novel 594insC/Q425P mutations in integrin beta4 gene (ITGB4). *Exp Dermatol* 2004; 13: 61–64.
  - 39 De Jenlis Sicot B, Deruelle P, Kacet N, Vaillant C, Subtil D. Prenatal findings in epidermolysis bullosa with pyloric atresia in a family not known to be at risk. *Ultrasound Obstet Gynecol* 2005; 25: 607–609.