

INVESTIGATIVE REPORT

Efficacy of a Single Oral Dose of 200 mg Pramiconazole in Vulvovaginal Yeast Infections: An Exploratory Phase IIa Trial

Gilbert DONDERS¹, Jannie AUSMA², Luc WOUTERS², Geert CAUWENBERGH³, Marcel BORGERS^{2,4} and Dirk JANSSENS⁵
¹Clinical Center Femicare, Tienen, ²Barrier Therapeutics nv, Geel, Belgium, ³Barrier Therapeutics Inc, Princeton, USA, ⁴Department of Molecular Cell Biology, Maastricht University, Maastricht, The Netherlands, and ⁵Gynaecologische Dienst, Turnhout, Belgium

Pramiconazole (R126638) is a novel azole with potent antifungal activity against yeasts, dermatophytes and many other fungal species. The aim of this study was to evaluate the efficacy and tolerance of a single oral dose of 200 mg pramiconazole in acute and recurrent vulvovaginal yeast infections. Thirty-two patients (15 acute and 17 recurrent cases) were KOH microscopy- and culture-positive at inclusion. Clinical cure was 53% at one week and 66% at one month. Mycological eradication was obtained in 88% at one week, whereas at one month 75% of the patients were still culture-negative. Effects in both acute and recurrent cases appeared to be similar for mycological cure. The composite sign and symptom score (sum of scores for oedema, erythema, excoriation pruritus, burning and irritation) had a median value of 7.5 (range 2–17) at inclusion. At one week this value was reduced to 1.0 (range 0–8) and at one month a further reduction to 0 (range 0–11) was seen. *p*-values compared with baseline at both follow-up visits were <0.001. The drug was well tolerated and the reported adverse events were rare and minimal. In conclusion, the results of this trial indicate that pramiconazole possesses properties that warrant further clinical studies in a larger number of patients with acute and recurrent vulvovaginal yeast infection to confirm its efficacy and tolerability. **Key words: pramiconazole; vulvovaginal yeast infection; *Candida*; phase IIa trial.**

(Accepted March 10, 2007.)

Acta Derm Venereol 2008; 88: 462–466.

Marcel Borgers, Barrier Therapeutics nv, Ciplastraat 3, BE-2440 Geel, Belgium. E-mail: mborgers@barriertherapeutics.be

Vulvovaginal yeast infections are very common infections, affecting up to 75% of sexually active women at least once in their lifetime (1). For acute vulvovaginal yeast infections short-term topical and systemic antifungal treatments are usually recommended (1). Although topical agents are often effective for acute episodes of vulvovaginal yeast infections, they tend to be messy and can be responsible for contact irritation or allergic reactions. In contrast, oral therapy is easy to administer, and therefore often preferred by patients (2). Short-term

therapies were found to be associated with a higher rate of patient compliance (3). In chronic recurrent vulvovaginal yeast infections in particular, where longer treatment durations are recommended, oral antimycotic therapy that can be prescribed for shorter schedules may result in better patient compliance and a better outcome (4).

Vaginal yeast infections are caused by *Candida albicans* or related fungi. The fungi isolated from the vagina include *C. albicans* in 80–90% and others, such as *C. glabrata* and *C. tropicalis* (5).

Pramiconazole is a broad-spectrum antifungal belonging to the class of triazoles (6–8). It has excellent potential for oral and topical treatment of fungal infections of skin, hair, nails, oral and genital mucosa. *In vitro* data demonstrated the activity of pramiconazole against dermatophytes (*Trichophyton* spp., *Microsporum canis*, *Epidermophyton floccosum*), yeasts (*Candida* spp. and *Malassezia* spp.) and many other fungi. Furthermore, animal experiments provided evidence for a potent therapeutic effect of pramiconazole that proved to be 4–8-fold superior to that of itraconazole, especially for superficial fungal infections (6). The strong activity of pramiconazole is ascribed to its prominent affinity for fungal cytochrome P450, which is involved in the biosynthesis of ergosterol from lanosterol. Ergosterol is a vital cell membrane component in fungi, and its inhibition by pramiconazole leads to abated fungal growth (7). Activity of pramiconazole against several dermatophyte and yeast infections in man have been reported recently (9–11).

The objective of this phase IIa trial was to evaluate the efficacy and tolerability of pramiconazole given orally as a single dose of 200 mg in patients with acute and recurrent vulvovaginal yeast infections.

PATIENTS AND METHODS

This trial is a multi-centre, open-label study to assess the efficacy, tolerability and safety of oral pramiconazole in patients with acute and recurrent vulvovaginal yeast infections. Thirty-six women participated in the study: mean age 35.0 (standard deviation (SD) 10.5) years, mean weight 63.8 (SD 10.3) kg, 32 women had the clinical diagnosis of vulvovaginal yeast infection based on signs (oedema, erythema and excoriation of the vagina/vulva) and symptoms (pruritus, burning and irritation) associated with vaginal yeast infections confirmed by positive culture and potassium hydroxide (KOH) microscopy showing one of the dimorphic forms (hyphae/pseudohyphae or budding

yeasts). Fifteen patients had an acute infection (defined as less than 4 episodes over the last year) and 17 patients had recurrent infections (defined as ≥ 4 episodes over the last year).

The study protocol and patient information have been reviewed by the independent ethics committee of the Academic Hospital of the Free University of Brussels and the local ethics committee of the Hospital Tienen and all patients provided written informed consent prior to study enrolment. All clinical investigations were conducted according to the principles of the Declaration of Helsinki.

Treatment

The patients received a single oral dose of 200 mg pramiconazole. The trial medication (200 mg pramiconazole: 20 ml of 10 mg/ml pramiconazole oral solution containing 30% hydroxypropyl- β -cyclodextrin pH 2.5) was produced by Cardinal Health, Bolton, UK. They were instructed to drink the contents of one bottle in the morning after overnight fasting.

The patients were prohibited to use: (i) any local or systemic antimycotic therapy one week (local) or 2 weeks (systemic) before entry into the study and during the complete study period, (ii) other medication potentially interacting with azoles, (iii) other medication that influenced the bioavailability of azoles, (iv) systemic antibiotics or (v) immuno-suppressive medication.

Assessments

A mycological examination and an evaluation of the clinical symptoms was performed at baseline (visit 1, before dosing), 7–12 days after treatment (visit 2) and at 21–30 days after treatment (visit 3).

Mycology

At each study visit a high vulvovaginal swab was taken and used for culture as well as KOH microscopy. The KOH preparation from the inflamed vaginal mucosa had to reveal hyphae/pseudohyphae or budding yeasts and the entry culture had to be positive. Mycological outcomes were defined as follows:

Mycological eradication: patient with negative culture for *C. albicans* (or baseline yeast pathogen). KOH microscopy based cure was defined as no hyphae/pseudohyphae or budding yeasts present.

Detailed microscopic evaluation

Swabs of 6 patients were used for detailed light- and electron microscopy in order to verify the outcome of KOH microscopy. Samples taken at each visit were fixed at room temperature in 3% glutaraldehyde buffered to pH 7.4 with 0.1 M sodium cacodylate for several days and rinsed in the same buffer supplemented with 7% sucrose. Samples were post-fixed in 1% OsO₄ buffered to pH 7.4 with 0.1 M sodium cacodylate at room temperature for 1 h. Thereafter the samples were rinsed in the same buffer and dehydrated in graded series of ethanol and routinely embedded in EPON epoxy resin. Two micrometer thick EPON sections, stained with toluidine blue, were used for light microscopic examination. Ultra-thin sections of the EPON-embedded material were stained with uranyl acetate and lead citrate prior to transmission electron microscopic examination in a Philips CM100 (12).

Clinical evaluation

The clinical signs assessed by the investigator included: oedema, erythema and/or excoriation of the vagina/vulva. Symptoms assessed by the patient included: pruritus, burning

and irritation of the vagina/vulva. Each evaluated sign and/or symptom was scored with a 4-point rating scale, where 0 = absent, 1 = mild, 2 = moderate and 3 = severe. The composite sign and symptom score was defined as the sum of the 3 scores of the investigator's assessment of signs and the 3 scores of the patient's assessment of symptoms.

Clinical cure was defined as resolution of signs and symptoms without further antifungal treatment. Specifically, any sign or symptom with a score of 1 or 2 at entry had to be absent (score = 0) and any sign or symptom with a score of 3 (severe) at entry had to be a score of 0 or 1. Therapeutic cure was defined as the combined clinical cure and the mycological eradication.

Daily symptom evaluation by the patient

The patient received a diary from the investigator for 2 periods: from visit 1 to visit 2 and between visits 2 and 3. Using a visual analogue scale (VAS), the patient was asked to record on a daily basis the severity of pruritus, burning and irritation.

Safety analysis

At each visit the investigator asked the patients whether they had experienced any adverse events (AEs). In addition, blood samples for haematology, biochemistry, and a midstream urine sample for urinalysis were taken at visits 1 (before drug intake) and at visit 2. If clinically relevant deviations were recorded in any of these safety variables at visit 2, the clinical laboratory tests were repeated at visit 3.

Clinically relevant changes in laboratory parameters, vital signs or body weight as well as any intercurrent illness were considered AEs.

RESULTS

Therapeutic cure

Therapeutic cure (combined clinical cure and mycological eradication) was obtained in 47% of the patients at day 7–10 (visit 2). At day 21–30 (visit 3) therapeutic cure was obtained in 59% of the population. For patients with acute vulvovaginal yeast infection, therapeutic cure was obtained in 53% of the patients at day 7–10 and in 80% at day 21–30. For patients with recurrent vulvovaginal yeast infection therapeutic cure was 41% both at day 7–10 and at day 21–30 (Table I).

Mycological evaluation

At the start of treatment 28 of 32 cultures were positive for *C. albicans*, 3 of these were combined *C. albicans* and *C. glabrata* infections. One other patient had a *C. tropicalis* combined with *C. glabrata* and one patient had a *S. cerevisiae* infection.

At visit 2 (day 7–10) mycological eradication was obtained in 88% of the patients and at visit 3 (day 21–30) in 78% of the patients. In the patients with acute vulvovaginal yeast infection mycological eradication was 93% at day 7–10 and 80% at day 21–30. Mycological eradication was seen in 82% of the patients at day 7–10 and in 71% at day 21–30 of the patients with recurrent vulvovaginal yeast infection (Table I).

Table I. Summary of efficacy variables: % responders (frequencies)

	Visit	Day	Acute ^a	Recurrent ^b	Total
Mycological eradication ^c	2	7–10	93 (14/15)	82 (14/17)	88 (28/32)
	3	21–30	80 (12/15)	71 (12/17)	75 (24/32)
Microscopy-based cured ^d	2	7–10	100 (15/15)	76 (13/17)	88 (28/32)
	3	21–30	80 (12/15)	71 (12/17)	75 (24/32)
Culture- and microscopy-based cure ^e	2	7–10	93 (14/15)	65 (11/17)	78 (25/32)
	3	21–30	80 (12/15)	59 (10/17)	69 (22/32)
Clinical cure ^f	2	7–10	60 (9/15)	47 (8/17)	53 (17/32)
	3	21–30	80 (12/15)	53 (9/17)	66 (21/32)
Therapeutic cure ^g	2	7–10	53 (8/15)	41 (7/17)	47 (15/32)
	3	21–30	80 (12/15)	41 (7/17)	59 (19/32)

^aAcute vulvovaginal yeast infection defined as less than 4 episodes over the last year.

^bRecurrent vulvovaginal yeast infection defined as ≥ 4 episodes over the last year.

^cMycological eradication: a patient with negative culture (no growth) for *Candida albicans* (or baseline yeast pathogen) at the test-of-cure visit and at days 21 to 30 of the study.

^dMicroscopy-based cure is defined as no hyphae/pseudohyphae or budding yeasts present.

^eMycological eradication and no microscopic signs of hyphae/pseudohyphae or budding yeasts.

^fClinical cure: resolution of signs and symptoms without further antifungal treatment. Any sign or symptom scored mild to moderate at entry should be completely resolved and any sign or symptom that was scored as severe at entry should be moderate or absent.

^gA patient is defined as therapeutically cured if she is considered clinically cured by the investigator and has achieved mycological eradication.

Clinical evaluation

At visit 2 (day 7–10) clinical cure was obtained for 53% of the patients. A further improvement was seen at visit 3 (day 21–30), since clinical cure was obtained for 66% of the patients. Clinical cure in patients with acute vulvovaginal yeast infection was 60% at day 7–10 and 80% at day 21–30, whereas for patients with recurrent vulvovaginal yeast infections clinical cure was seen for 47% of the patients at day 7–10 and for 53% at day 21–30 (Table I).

Sign and symptom scores

A composite sign and symptom score (CSSS) was calculated for all signs and symptoms together. All patients included in the study had a CSSS ≥ 2 at visit 1, 62.5% of the patients had moderate disease, i.e. a CSSS ≥ 7 . Nine percent of the patients had severe disease, i.e. CSSS ≥ 13 . The mean CSSS was 7.8 at visit 1, 1.6 at visit 2 ($p < 0.001$) and 1.7 at visit 3 ($p < 0.001$). All individual signs and symptom scores were reduced at the follow-up visits. All p -values were < 0.001 at both follow-up visits (Table II).

Daily symptom evaluation by the patient

The patients reported pruritus, burning and irritation daily on a VAS. Time-to-resolution was based on the daily recording in the patient diaries and defined as the number of days from study medication start to the first occurrence of symptom resolution. The mean time-to-resolution was 9.8 ± 0.8 days, while the median (95% confidence interval) was 10 (8–13) days (Table II).

Safety evaluation

During the study a total of 20 AEs were reported by 13 patients. Ten AEs were reported as moderate and 10 were reported as mild. The relationship to trial medication was reported as “none” for 10 of the AEs, “possible” for 8 AEs and “probable” for 2 AEs. No AEs were reported as “certainly” related to trial medication. One AE was reported more than once: diarrhoea was reported in 2 patients as moderate and possibly related to trial medication. One laboratory value, hypercholesterolemia, resulted in an AE. Vital signs did not reveal clinically significant changes during the study period. No serious adverse events (SAEs) were reported.

Table II. Composite sign and symptom score and individual signs and symptoms. Mean values, (range)

	Visit 1 (day 1)	Visit 2 (day 7–10)*	Visit 3 (day 21–30)*
Composite score of signs and symptoms	7.8 (2–17)	1.6 (0–8)	1.7 (0–11)
Investigator assessment of oedema severity	1.2 (0–2)	0.1 (0–1)	0.2 (0–2)
Investigator assessment of erythema severity	1.8 (0–3)	0.4 (0–2)	0.4 (0–3)
Investigator assessment of excoriation severity	0.8 (0–3)	0.2 (0–2)	0.1 (0–2)
Patient assessment of pruritus severity	1.5 (0–3)	0.3 (0–1)	0.3 (0–1)
Patient assessment of burning severity	1.3 (0–3)	0.2 (0–2)	0.4 (0–3)
Patient assessment of irritation severity	1.3 (0–3)	0.4 (0–2)	0.3 (0–3)

* $p < 0.001$ with 2-sided Wilcoxon signed-rank test vs. value at visit 1.

Microscopic evaluation

Light- and electron microscopy confirmed the presence of yeasts in the samples before treatment (Fig. 1a). With transmission electron microscopy the pre-treatment sample shows yeast and hyphae with intact subcellular organelles (Fig. 1a). In some of the post-treatment samples, a few yeast cells remained; however, in most samples only lactobacilli could be displayed (Fig. 1b).

Fig. 2 shows an overview of the study and the results.

DISCUSSION

The results of this trial indicate that a single oral dose of 200 mg pramiconazole is an effective treatment of vulvovaginal yeast infections.

Fluconazole is at the present the only oral therapy available as a single-dose regimen. Itraconazole is available as single-day oral therapy but administered in 2 doses. Data on itraconazole are described in several publications (13–18). In these trials mycological cure rates ranged from 51% to 96%, in the same range as obtained in our trial with pramiconazole i.e. 75% at one month post-treatment. Clinical cure rates ranging from 83–90% were described for itraconazole. The clinical cure rate of 66% obtained with pramiconazole was lower. However, most of the reported studies concern acute vulvovaginal yeast infections or included only a low percentage of patients with recurrent vulvovaginal yeast infections. In addition, over time the efficacy criteria for therapeutic cure have evolved and have become more stringent than in the past. A sub-division for acute and recurrent vulvovaginal yeast infections was made by Cauwenbergh & De Doncker (17). They described a mycological cure of 75% for patients with acute vulvovaginal yeast infections vs. 65% for patients with recurrent vulvovaginal yeast infections. In the current trial with pramiconazole slightly higher mycological

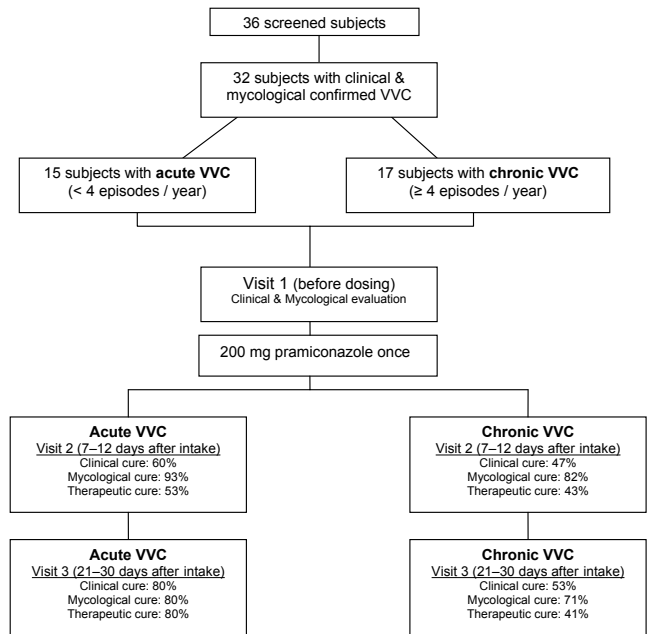


Fig. 2. Flow-chart of the study. VVC: vulvovaginal candidiasis.

cure rates were obtained, i.e. 80% for acute infections vs. 71% for recurrent infections.

Fluconazole cure rates differentiating between acute and recurrent vulvovaginal yeast infections have been reported (19). Approximately 75% of the patients had acute vaginitis and achieved 81% clinical cure and 69% mycological eradication. In the pramiconazole trial 80% clinical cure, and 80% mycological eradication was obtained for patients with acute vaginitis.

Patients with recurrent candidiasis who were treated with fluconazole (19) achieved 55% clinical cure and 47% mycological eradication. For the pramiconazole treated patients with recurrent vulvovaginal yeast infections, 53% clinical cure and 71% mycological eradication were achieved.

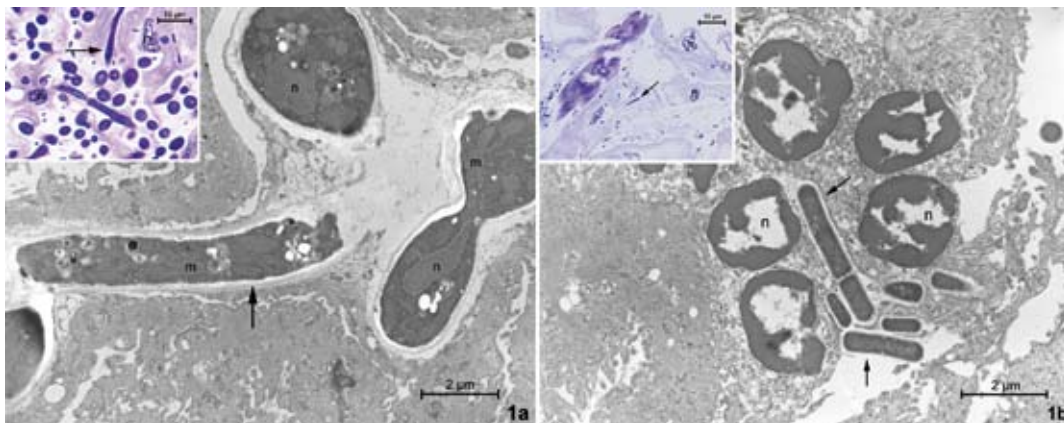


Fig. 1. Transmission electron microscopy and light microscopy (inserts) of vaginal mucosa (a) before treatment and (b) one week after treatment with a single 200 mg dose of pramiconazole. (a) Before treatment the numerous yeast and hyphae of *C. albicans* are visible on the light microscopic picture (insert). Transmission electron microscopy shows that the cells (arrow) have intact subcellular structures. n: nuclei; m: mitochondria. (b) After treatment no yeasts remain, only intact lactobacilli (arrows) are predominantly present. n: nuclei of desquamating epithelial cells.

In conclusion, the results of this phase IIa trial indicate that pramiconazole possesses properties that warrant further clinical studies in a larger number of patients with vulvovaginal yeast infection to confirm its efficacy and tolerability.

REFERENCES

1. Guidance for Industry. Vulvovaginal candidiasis – developing antimicrobial drugs for treatment. Draft guidance. US Department of Health and Human Services, FDA, CDER, 1998.
2. De Punzio C, Garutti P, Mollica G, Nappi C, Piccoli R, Genazzani AR. Fluconazole 150 mg single dose versus itraconazole 200 mg per day for 3 days in the treatment of acute vaginal candidiasis: a double blind randomized study. *Eur J Obst Gynecol Reprod Biol* 2003; 106: 193–197.
3. Yule V. Treatment option: a patient's viewpoint. Finding from a pan-European survey. *Int J Gynecol Obstet* 1992; 37: 45–49.
4. Sobel JD. Treatment of vaginal *Candida* infections. *Expert Opin Pharmacother* 2002; 3: 1059–1065.
5. Odds FC. Genital candidiasis. *Clin Exp Dermatol* 1982; 7: 345–354.
6. Odds F, Ausma J, Van Gerven F, Woestenborghs F, Meerpoel L, Heeres J, et al. In vitro and in vivo activities of the novel azole antifungal agent R126638. *Antimicrob Agents Chemother* 2004; 48: 388–391.
7. Vanden Bossche H, Ausma J, Bohets H, Vermuyten K, Willemsens G, Marichal P, et al. The novel azole R126638 is a selective inhibitor of ergosterol synthesis in *Candida albicans*, *Trichophyton* spp. and *Microsporum canis*. *Antimicrob Agents Chemother* 2004; 48: 3272–3278.
8. Meerpoel L, Backx LJJ, Van der Veken LJE, Heeres J, Corens D, De Groot A, et al. Synthesis and in vitro and in vivo structure-activity relationship of novel antifungal triazoles for dermatology. *J Med Chem* 2005; 48: 2184–2193.
9. Faergemann J, Ausma J, Vandeplasseche L, Borgers M. The efficacy of oral treatment with pramiconazole in Pityriasis versicolor: a phase IIa trial. *Br J Dermatol* 2007; 156: 1385–1387.
10. Degreef H, Heeres J, Borgers M. Antifungal azoles for skin disorders. *Expert Opin Ther Patents* 2006; 16: 1235–1253.
11. Decroix J, Ausma J, Cauwenbergh G, Borgers M, Wouters L. The efficacy of oral treatment with pramiconazole in tinea pedis and tinea cruris/corporis: 2 exploratory phase IIa trials. *Br J Dermatol* 2008; e-pub january.
12. Faergemann J, Borgers M. The effect of ketoconazole and itraconazole on the filamentous form of *Pityrosporum ovale*. *Acta Derm Venereol* 1990; 70: 172–175.
13. Sanz-Sanz F and Hernanz P. Randomized comparative trial of three regimens of itraconazole for treatment of vaginal mycosis. *Rev Infect Dis* 1987; 9: S139–S142.
14. Woolley PD and Higgins SP. Comparison of clotrimazole, fluconazole and itraconazole in vaginal candidiasis. *Br J Clin Pract* 1995; 49: 65–66.
15. Urünsak M, Ilkit M, Evrücke, Urünsak I. Clinical and mycological efficacy of single-day oral treatment with itraconazole (400 mg) in acute vulvovaginal candidosis. *Mycoses* 2004; 47: 422–427.
16. Wesel S. Itraconazole; a single-day oral treatment for acute vulvovaginal candidosis. *Br J Clin Pract Suppl* 1990; 71: 77–80.
17. Cauwenbergh G, De Doncker P. The clinical use of itraconazole in superficial and deep mycosis. Recent trends in discovery, development and evaluation of antifungal agents. Fromtling RA, editor. J. R. Prous Science Publishers, S.A. 1987.
18. Tobin JM, Loo P, Granger SE. Treatment of vaginal candidosis; a comparative study of the efficacy and acceptability of itraconazole and clotrimazole. *Genito-urin Med* 1992; 68: 36–38.
19. Sobel JD, Brooker D, Stein GE, Thomason JL, Wermeling DP, Bradley B, et al. Single oral dose fluconazole compared with conventional clotrimazole topical therapy of *Candida* vaginitis. *Am J Obstet Gynecol* 1995; 172: 1263–1268.