

Mycetoma of the Chest Wall due to *Nocardia brasiliensis*

Carolina Gouveia¹, Ana Fraga¹, Paulo Filipe¹, Horténsia Sequeira², Patrick Boiron³, Andrée Couble³, Verónica Rodríguez-Nava³ and Manuel Marques Gomes^{1,2}

¹University Clinic of Dermatology, Santa Maria Hospital, ²Laboratory of Mycology, Faculty of Medicine of Lisboa, PT-1649-028 Lisbon, Portugal,

³University of Lyon, Lyon, France, University of Lyon 1 and CNRS, UMR5557, Microbial Ecology, Villeurbanne, Veterinary National School of Lyon, Marcy L'Étoile, France, Institute of Pharmaceutical and Biological Sciences, Lyon, France, and French Nocardiosis Observatory, Lyon, France.

E-mail: carolinagouveia@gmail.com

Accepted January 30, 2008.

Sir,

Nocardiosis is an uncommon but world-wide infection caused by several species of soil-borne aerobic bacteria belonging to the genus *Nocardia* (1).

Nocardiosis can be divided into two broad categories: disseminated and cutaneous. Disseminated nocardiosis, which accounts for most occurrences of nocardiosis, is most commonly caused by *N. asteroides*, and typically affects immunocompromised hosts, although individuals with presumed immunocompetency also can develop the disease (1, 2).

Among the several species of *Nocardia* causing cutaneous infections, *N. brasiliensis* is the commonest species isolated (3, 4). Recently, new species including *N. mexicana* and *N. veterana* were reported as causative agents of human mycetoma (5, 6). Cutaneous involvement with *N. asteroides* is usually secondary to haematogenous dissemination from a pulmonary focus. The commonest predisposing event in all the reported cases of primary cutaneous nocardiosis is a local trauma caused by thorns or splinters or, less commonly, insect bites and cat scratches (7, 8). It is most commonly caused by *N. brasiliensis*, typically affects immunocompetent individuals, and can be subdivided into 3 clinical entities, including: lymphocutaneous infection, mycetoma, and superficial skin infection, including ulceration, abscess, and cellulites (8–10). An intermediate form

of the disease between mycetoma and superficial skin infection has been reported recently (4).

We report here a case of an immunocompetent female adolescent patient with extensive and destructive primary cutaneous nocardiosis over the thoracic wall and neck.

CASE REPORT

A 14-year-old black female was admitted to the dermatology ward of Hospital de Santa Maria in Lisbon with multiple inflammatory nodules, keloidal scars and discharging sinuses over the thoracic wall and neck. She gave no history of injury, and reported that the first lesion had appeared 4 years previously, over the left shoulder. She had subsequently developed a swelling, followed by multiple discharging sinuses with purulent and serosanguinous material. The lesions slowly expanded to the contiguous thoracic wall, eventually leading to deformity of both breasts. Over the previous year, she had complained of fever, intense anorexia with heavy weight loss (that she could not quantify) and dry cough. There was no history of chronic illness such as diabetes, tuberculosis or malignancy. She had first been observed in her homeland (Guinea-Bissau) and had had unspecified treatment without improvement. As a consequence, she was evacuated to Portugal, for aetiological investigation and treatment.

Physical examination revealed a discharging area that occupied the entire thoracic wall, extending up to the left shoulder and scapular region. There were numerous large sinuses discharging viscous yellow pus and serosanguinous material, often plugged with protuberant masses of granulation tissue. Several keloidal scars could be seen over the entire area and severe deformity of

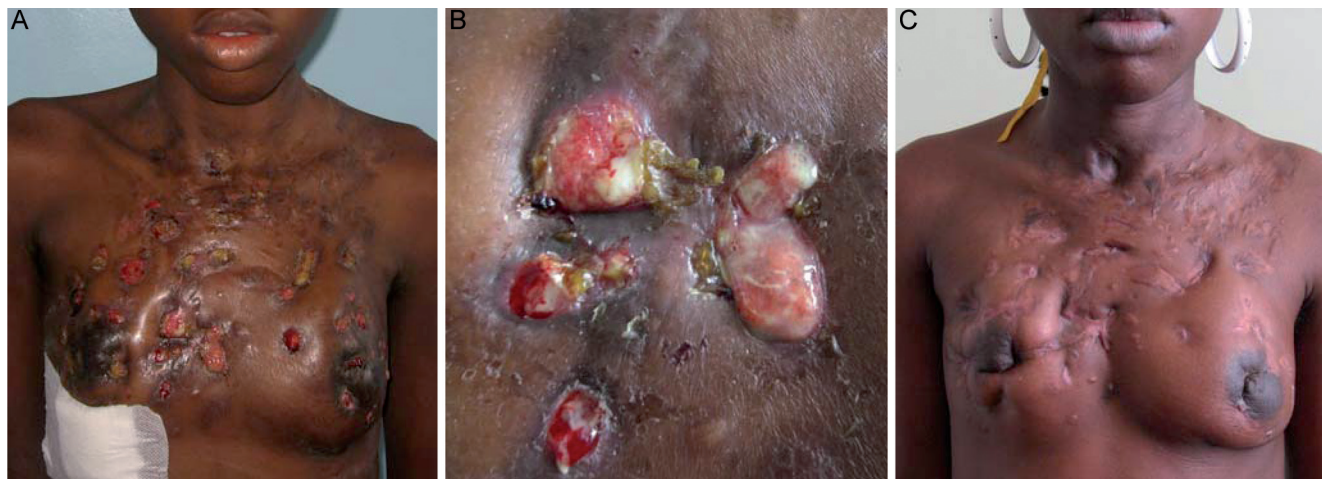


Fig. 1. (A) The patient before treatment. Nodules, keloidal scars, sinuses and protuberant masses of granulation tissue over the neck and thoracic wall with severe destruction of the breasts. (B) Large sinuses discharging viscous yellow purulent and serosanguinous exudate. (C) After an 8-week course of treatment with imipenem-cilastatin.

both breasts was evident (Fig. 1). Systemic examination of the patient showed that she was in bad general health, with emaciation, weighing 35 kg (body mass index 13.3). There was no palpable regional lymphadenopathy and no fever.

Among routine investigations, ESR was increased (113 mm) as was reactive C-protein (11 mg/dl). Her white blood count was normal, but she had a severe normocytic anaemia (Hb of 6.8 g/l), which warranted a blood transfusion. Serologies for HIV 1 and 2 were negative. Roentgenograms of the chest were normal. Computed tomography scan of the lungs and chest wall showed densification of the soft and breast tissues, with involvement of the part of the anterior mediastinum related to the internal mammary chains. Several blood cultures were performed, which were all negative. Histological study of the biopsy taken from the left breast revealed granulation tissue with neutrophilic abscesses containing basophilic grains with an eosinophilic rim, which was suggestive of mycetoma (Fig. 2).

Sequential mycological and bacteriological studies were carried out on the exudate from discharging sinuses and from the dressings. The first bacteriological cultures revealed *S. aureus*.

Direct examination of samples stained with lactophenol blue for microscopic observation revealed white grains (mean diameter 0.5 mm); isolates consisting of orange-white colonies and a white mycelium were obtained from cultures at 24°C and 37°C (mycobiotic agar, Sabouraud dextrose agar and Brain Heart agar alone or supplied with 0.5/1000 w/w chloramphenicol), which were suggestive of *Nocardia*.

The same isolate was thereafter sent to the French Nocardiosis Observatory, where cultures were repeated on Bennett's agar medium at 37°C for 10 days. Morphological and microscopic examinations revealed orange-white, Gram-positive colonies that form filamentous with tendency to fragmentation. Biochemical reactions were also repeated according to Boiron et al. (11) showed the production of catalase and hydrolysis of urea.

A PCR assay was conducted to confirm phenotypic identification of the isolate 639.07 by genomic DNA extraction from pure culture using an achromopeptidase method and sequence analysis of the 16S rRNA gene. Primers *Noc-1* (5'-GCTTAA-CACATGCAAGTCG-3') and *Noc-2* (5'-GAATTCAGTC-TCCCCTG-3') (position 46 to 64 and 663 to 680 from *E. coli* numbering), which amplified a 606 bp segment were employed (12). After 40 cycles consisting of denaturation at 94°C for 60 sec, primer annealing at 58°C for 60 sec, and primer extension at 72°C for 60 sec, followed by a post-amplification extension at 72°C for 5 min. The PCR products were sequenced by using an

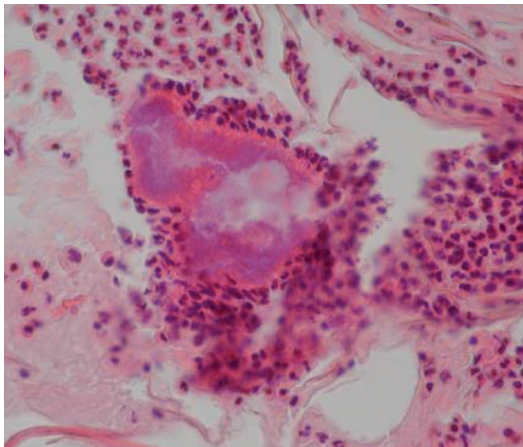


Fig. 2. Histological examination of a biopsy of a skin lesion, showing an abscess containing a basophilic grain with an eosinophilic rim (haematoxylin-eosin $\times 400$).

ABI Prism 377 automated sequencer (PE Applied Biosystems). The nucleotide sequence was analysed with use of BLAST search of the National Institutes of Health Genbank Database. The strain was definitively identified as *N. brasiliensis* (ATCC 19296, accession number AY756544).

The patient was medicated with imipenem-cilastatin (60 mg/kg/day i.v. q6h) for 8 weeks, with a good response (healing of most of the cutaneous lesions, improvement of general health, weight gain of 13 kg and Hb increased to 11.4 g/l) (Fig. 1B) and subsequently with trimethoprim and sulphamethoxazole (160 mg TMP/800 mg SMZ p.o. q12h) until complete eradication of the organism was documented.

DISCUSSION

Primary cutaneous nocardiosis remains a diagnostic challenge. None of the three types has any characteristic feature that would make a definitive clinical diagnosis possible (4). In the case described here the initial clinical differential diagnosis was made with diseases having a similar clinical presentation and included deep mycosis with high prevalence in African countries, actinomycetoma, cutaneous tuberculosis and atypical mycobacteriosis (13).

It was not possible to elicit a history of trauma; this might be explained by a long incubation period because that of *Nocardia spp.* can vary from one week to several months (14).

Mycetoma is described as a chronic, indurated, progressively destructive, granulomatous infection of skin, subcutaneous and eventually deeper tissues following localized trauma, with multiple draining sinus tracts and elimination of grains (sulphur granules). It occurs most commonly on the extremities, especially the foot, but other locations have been reported (2, 9, 13, 15).

Identification of the *Nocardia* species by culture is a tedious process and it is advisable to submit multiple clinical specimens for culture because smears and cultures are simultaneously positive in only one-third of infections. The organism is slow growing and it may take up to 2–3 weeks for isolation from a clinical specimen. The small nocardial colonies are occasionally overgrown by other rapidly growing organisms, resulting in an initial negative culture report. Species identification is based on classical biochemical methods. These can be completed by Western blot assay, using monoclonal antibodies against 54-kDa circulating antigens of *Nocardia*, and species specific DNA probing help in the rapid and definitive diagnosis of nocardiosis. ELISA for serodiagnosis of nocardial infection is also useful (9).

An antibiogram is suggested for all species isolated because of the varied antibiotic sensitivity pattern (9, 13). Sulphonamides have been the mainstay of antimicrobial therapy for human nocardiosis (2). Trimethoprim and sulphamethoxazole (TMP-SMZ) is used most commonly. Other effective drugs include minocycline, dapsone, tetracycline, amikacin, amoxicillin-clavulanic

acid, cefotaxime, imipenem, and rifampicin. Although the optimal duration of therapy is uncertain, suggestions range from 6 weeks to one year (1, 8, 13, 15).

In our case, we chose to start intravenous antimicrobial therapy with imipenem-cilastatin because: (i) the patient was also infected with *S. aureus*; (ii) she had been submitted to previous antimicrobial therapy in Guinea-Bissau; (iii) the cutaneous disease was extensive.

The clinical response to imipenem-cilastatin was impressive, with a rapid improvement not only from the cutaneous lesions but also from the anaemia and the emaciation. She stopped coughing 3 days after beginning antibiotic therapy.

After 8 weeks she was discharged and oral TMT-SMZ was started. She is being followed-up regularly in our outpatient clinic and will maintain this antimicrobial therapy scheme until control microbiological exams are consistently negative.

REFERENCES

1. Saarinen KA, Lestringant GG, Czechowski J, Frossard PM. Cutaneous nocardiosis of the chest wall and pleura-10-year consequences of a hand actinomycetoma. *Dermatology* 2001; 202: 131–133.
2. Hornef MW, Gandorfer A, Heesemann J, Roggenkamp A. Humoral response in a patient with cutaneous nocardiosis. *Dermatology* 2000; 200: 78–80.
3. Beaman BL, Beaman L. *Nocardia* species: host-parasite relationships. *Clin Microbiol Rev* 1994; 7: 213–264.
4. Laurent F, Mick V, Boiron P. *Nocardia* infections: clinical and biological aspects. *Ann Biol Clin* 1999; 57: 545–554.
5. Rodríguez-Nava V, Couble A, Molinard C, Sandoval H, Boiron P, Laurent F. *Nocardia mexicana* sp. nov., a new pathogen isolated from human mycetomas. *J Clin Microbiol* 2004; 42: 4530–4535.
6. Kashima M, Kano R, Mikami Y, Takahama H, Ito M, Hasegawa A, Mizoguchi M. A successfully treated case of mycetoma due to *Nocardia veterana*. *Br J Dermatol* 2005; 152: 1349–1352.
7. Paredes BE, Hunger RE, Braathen LR, Brand CU. Cutaneous nocardiosis caused by *Nocardia brasiliensis* after an insect bite. *Dermatology* 1999; 198: 159–161.
8. Astudillo L, Dahan S, Escourrou G, Sailler L, Carreiro M, Ollier S, Arlet P. Cat scratch responsible for primary cutaneous *Nocardia asteroides* in an immunocompetent patient. *Br J Dermatol* 2001; 145: 684–685.
9. Inamadar AC, Palit A. Primary cutaneous nocardiosis: a case study and review. *Indian J Dermatol Venereol Leprol* 2003; 69: 386–391.
10. Angelika J, Hans-Jurgen G, Uwe-Frithjof H. Primary cutaneous nocardiosis in a husband and wife. *J Am Acad Dermatol* 1999; 41: 338–340.
11. Boiron P, Provost F, Dupont B, editors. Technical protocols. In: *Methodes de laboratoire pour le diagnostic de la nocardiose*. Paris: Institut Pasteur, 1993; p. 107–126.
12. Rodríguez-Nava V, Couble A, Devulder G, Flandrois J-P, Boiron P, Laurent F. Use of PCR-restriction enzyme pattern analysis and sequencing database for hsp65 gene-based identification of *Nocardia* species. *J Clin Microbiol* 2006; 44: 536–546.
13. Wong YW, Waghorn D, Ratnavel RC. Antibiotic-resistant cellulitis acquired in Turkey. *J R Soc Med* 2003; 96: 32–33.
14. Sherber NS, Olivere JW, Martins CR. An 80 year-old man with a nonhealing glabellar lesion. *Arch Pathol Lab Med* 2006; 130: 100–101.
15. Shimizu A, Ishikawa O, Nagal Y, Mikami Y, Nishimura K. Primary cutaneous nocardiosis due to *Nocardia nova* in a healthy woman. *Br J Dermatol* 2001; 145: 154–156.