

## Acute Streptococcal Infection of the Vulva

Stefano Veraldi, Claudia Francia and Angelo Valerio Marzano

Department of Anaesthesiology, Intensive Care and Dermatological Sciences, University of Milan, IRCCS Foundation, Cà Granda Ospedale Maggiore Policlinico, Milan, Italy. E-mail: stefano.veraldi@unimi.it  
Accepted September 20, 2011.

Erysipelas is an acute streptococcal infection of the dermis that mainly occurs in women over the age of 60 years. The legs and face are the most frequently involved areas (1). Erysipelas of the vulva is very rare (2–5). We describe here a case of acute streptococcal infection of the vulva that is clinically similar to erysipelas.

### CASE REPORT

A 54-year-old woman was admitted to our department with a swelling of the vulva accompanied by pain and fever. The patient reported that she was in good general health and that she was not being treated with any systemic drugs. The patient also reported that the swelling had appeared suddenly 3 days earlier: it was treated unsuccessfully with topical gentamicin (3 applications/day for 2 days). The patient reported vulvar pain as well as burning sensations in the anus, perianal region and perineum. Dermatological and gynaecological examinations revealed mildly erythematous oedema and a round erosion, 3 mm in diameter, on the right labium majus (Fig. 1). General physical examination revealed right inguinal lymphadenopathy and fever (38.3°C). Laboratory examinations showed leukocytosis (11,200 cells/mm<sup>3</sup>) and increased erythrocyte sedimentation rate (ESR) (63 mm in the first hour) (normal: <20 mm), C-reactive protein (8.4 mg/l) (normal: <1.5 mg/l) and  $\alpha$ -1 acid glycoprotein (65 mg/dl) (normal: <25 mg/dl). Urinalysis and urine bacteriological cultures were negative. Bacteriological examinations of the vulva and vagina were positive for Group B *Streptococcus*  $\beta$ -hemolyticus (type II) as well as pharyngeal and anal swabs. On the basis of antibiogram results, the patient was treated with oral amoxicillin/clavulanic acid (3 g/day for 10 days). The pain, burning and fever disappeared within 48 h. Complete remission of the swelling was observed within 3 days. Laboratory tests normalized 7 days after the beginning of the therapy, except for ESR. At the end of the therapy, all swabs were negative for bacteria. Follow-up (at one year) showed normal finding.

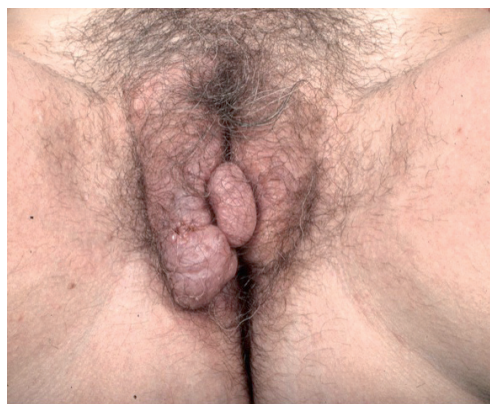


Fig. 1. Swelling and small erosion on the right labium majus.

### DISCUSSION

In this patient, we made a diagnosis of acute streptococcal infection of the vulva, rather than a diagnosis of true erysipelas of the vulva, because of the presence of mild erythema (usually severe in erysipelas) and the absence of well-defined borders typical of erysipelas. In 1960, Norburn & Coles (2) reported two cases of recurrent erysipelas following vulvectomy for squamous cell carcinoma. In 1980, Binnick et al. (3) reported a case of recurrent erysipelas in a woman with chronic lymphoedema due to radical hysterectomy and radiotherapy for squamous cell carcinoma of the cervix. Group B *Streptococcus*  $\beta$ -hemolyticus (type III) was isolated from vulvar vesicles, vaginal mucosa and blood. In 1996, a case of vulvar lymphangiectasia that developed after recurrent episodes of erysipelas was described (4). A similar case was published in 1999 (5).

In this patient, an important differential diagnosis was necrotizing fasciitis. The latter may occur rarely as a complication of caesarean delivery, vulvar or Bartholin's abscess, and herpes genitalis. However, the most important risk factors for necrotizing fasciitis of the genital area are age > 50 years, atherosclerosis, diabetes, obesity, smoking, previous radiotherapy or surgery, and immunosuppression due to neoplastic diseases (vulvar carcinoma, uterine sarcoma, leukaemias) or chemotherapy (6). In this patient, we excluded necrotizing fasciitis in the early phase for several reasons: (i) the presence of mildly erythematous oedema alone, without vesicles, blisters, pustules, petechiae, ulcers and necrosis: only a small erosion was observed; (ii) absence of gas by means of palpation and X-rays; (iii) the mild systemic involvement (only fever  $\leq$  38.3°C); (iv) the very rapid improvement after antibiotic therapy.

As far as the pathogenesis of this case is concerned, 3 hypotheses may be advanced. Group B *Streptococcus*  $\beta$ -hemolyticus is currently considered as non-pathogenic in the female genital tract (7). In our patient, however, it is possible that these streptococci became, for unknown reasons, pathogenic and flourished. It is also possible that streptococci reached the vulva, vagina and anus by auto-inoculation from the oral cavity. Perianal streptococcal dermatitis is rare in adults and, to our knowledge, no cases associated with vulvar and/or vaginal streptococcal infection have been reported (8).

## REFERENCES

1. Gabillot-Carré M, Roujeau JC. Acute bacterial skin infections and cellulitis. *Curr Opin Infect Dis* 2007; 20: 118–123.
2. Norburn LM, Coles RB. Recurrent erysipelas following vulvectomy. *J Obstet Gynaecol Br Emp* 1960; 60: 279–280.
3. Binnick AN, Klein RB, Baughman RD. Recurrent erysipelas caused by group B streptococcus organisms. *Arch Dermatol* 1980; 116: 798–799.
4. Buckley DA, Barnes L. Vulvar lymphangiectasia due to recurrent cellulites. *Clin Exp Dermatol* 1996; 21: 215–216.
5. Mu XC, Tran TA, Dupree M, Carlson JA. Acquired vulvar lymphangioma mimicking genital warts. A case report and review of the literature. *J Cutan Pathol* 1999; 26: 150–154.
6. Thompson CD, Brekken AL, Kutteh WH. Necrotizing fasciitis: a review of management guidelines in a large obstetrics and gynecology teaching hospital. *Infect Dis Obstet Gynecol* 1993; 1: 16–22.
7. Shaw C, Mason M, Scoular A. Group B streptococcus carriage and vulvovaginal symptoms: causal or casual? A case-control study in a GUM clinic population. *Sex Transm Infect* 2003; 79: 246–248.
8. Neri I, Bardazzi F, Marzaduri S, Patrizi A. Perianal streptococcal dermatitis in adults. *Br J Dermatol* 1996; 135: 796–798.