

Subungual Oxalate Deposits in a Patient with Secondary Hyperoxaluria

Stamatis Gregoriou¹, Kanella Kalapothakou¹, George Kontochristopoulos², Helena Belyayeva¹, Eftihia Chatziolou³ and Dimitris Rigopoulos¹

¹1st Department of Dermatology, ²2nd Department of Dermatology and ³Pathology Department, University of Athens Medical School, Andreas Sygros Hospital, 5 Ionos Dragoumi Street, GR-16121 Athens, Greece. E-mail: drigop@hol.gr

Accepted August 16, 2010.

Oxalosis describes the deposition of calcium oxalate crystals in renal and extrarenal tissues. Primary hyperoxaluria encompasses three genetic disorders of glyoxylate metabolism, characterised by excessive urinary excretion of oxalic acid, which results in oxalosis (1). Secondary or acquired hyperoxaluria results from increased intake of oxalate or oxalate precursors such as ethylene glycol, or from increased absorption of oxalate in patients with intestinal disease or who have undergone ileal resection (2). It has also been described in patients with acute or chronic renal failure (3). They fail to excrete oxalates, leading to the formation and deposition of stones in tissues and organs such as the heart, arterial walls, bone, the digestive system and the skin (4–6).

We report here a patient with secondary oxaluria caused by chronic renal failure who presented with subungual deposits of oxalate crystals.

CASE REPORT

A 41-year-old man presented at the nail clinic of our hospital with opaque painless hard masses resembling subungual hyperkeratoses or warts under two fingernails, which had developed 6 months previously (Fig. 1).

The patient had been diagnosed with end-stage renal disease 18 years before and had undergone three kidney transplantations. The first one had been performed 15 years previously and the patient had retained the graft for 8 years. He had received a second graft 3 years after removal of the first one, but his body rejected it within a month. A third transplantation had been performed 11 months prior to his presentation at our clinic, since which he had been receiving tacrolimus (2.5 mg/day) and methylprednisolone (6 mg/day). The patient had displayed hyperoxaluria since his last transplant operation. A recent urinary analysis showed urine oxalates of 93 mg/day

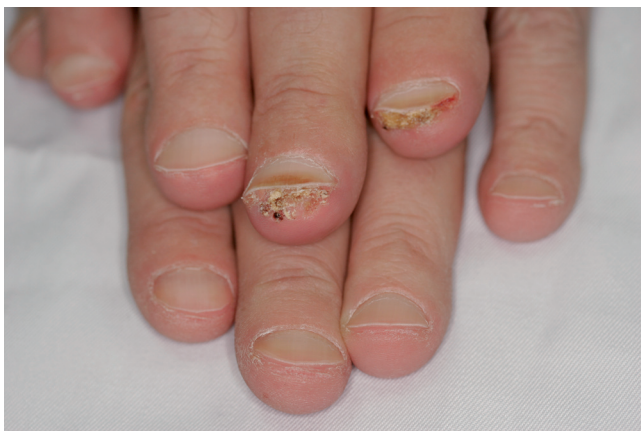

Fig. 1. Hyperkeratosis-like deposits under two fingernails.

(normal limits (10–35 mg/day). Previous genetic testing for primary oxaluria-related enzyme deficiencies was negative, and a diagnosis of secondary hyperoxaluria was made by the patient's nephrologists. The patient had also been diagnosed with vascular calcinosis. He did not report history of arthritis, arrhythmias or neuropathy. He did not have any vision problems, and the results of a routine examination performed by an ophthalmologist 6 months previously were normal.

Clinical examination revealed nothing abnormal aside from the hyperkeratosis-like lesions under two fingernails. There were no signs of livedo reticularis or miliary lesions on the skin. The patient did not report any history of Raynaud's phenomenon. Histological analysis of a biopsy specimen obtained from one of the affected nail beds revealed confocal needle-like crystals in the dermis, arranged in rectangular rosette-like arrays characteristic of oxalate crystals (Fig. 2). A lymphocytic and neutrophilic infiltrate surrounded these formations. The crystals appeared birefringent under polarised light.

A diagnosis of subungual oxalate deposits was made based on the patient's history of oxalosis and the characteristic morphology of the crystals. The patient was scheduled for a fundoscopy to determine the presence or absence of retinal oxalate deposits, but he died before this could be accomplished.

DISCUSSION

Hyperoxaluric disorders result in total-body oxalate overload and, subsequently, pathologic accumulation of oxalate in tissues (7). The kidneys are the primary route of oxalate excretion and, due to their unique anatomical and pathophysiological features, the first organs to be severely affected. Complications include renal

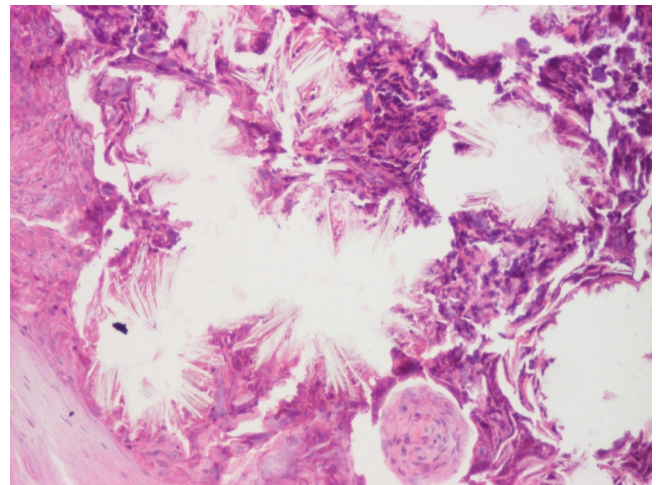


Fig. 2. Confocal needle-like crystals in the dermis, arranged in rectangular rosette-like arrays characteristic of oxalate crystals (H&E, ×100). A lymphocytic and neutrophilic infiltrate surrounds the formations.

stone formation, nephrocalcinosis, interstitial nephritis and, finally, end-stage renal disease. Interestingly, the increase in plasma oxalate is inversely correlated with a decline in the glomerular filtration rate, as a result of which oxalate crystals form in extrarenal tissues.

Involvement of the myocardium and cardiac conduction system may lead to myocardial insufficiency and arrhythmias. Restrictive cardiomyopathy and cardioembolic stroke have also been reported (4). Crystal deposits in the joints can cause arthritis (6), while retinal crystals may also be found (8). Intraaxonal calcium oxalate deposits may cause peripheral neuropathy, and circulatory problems caused by oxalate accumulation may cause ischaemic neuropathy (9). Cutaneous manifestations of systemic oxalosis can be divided into those caused by oxalate crystal deposition in the cutaneous vasculature and those caused by extravascular skin deposits (6). Vascular involvement, in the form of livedo reticularis, peripheral gangrene, ulcers, acrocyanosis or Raynaud's syndrome, is prominent in primary hyperoxaluria. Secondary hyperoxaluria has been occasionally associated with milium papules and calcified nodules, caused by extravascular skin deposits and typically affecting the palmar aspect of the fingers (1).

The pathogenesis of oxalate deposition in the kidneys has been studied. It has been shown that renal epithelial cell membrane injury is essential for the deposition of calcium oxalate crystals, and that exposure to oxalate causes membrane damage (10). Damaged renal epithelial cells can bind oxalate crystals through crystal-binding proteins expressed on their surfaces, while intact ones cannot (11). Moreover, exposure to oxalate has been shown to cause toxic reactions in renal epithelial and liver portal connective tissue cells, including modification of cellular lipids and the expression of genes encoding membrane surface crystal-binding proteins such as osteopontin and hyaluronan, as well as their cell surface receptor, CD44 (11–13). In addition, oxalate exposure can alter mitochondrial enzymatic activity, resulting in the formation of reactive oxygen species and, consequently, cellular oxidative damage (13). Further data from renal cell culture studies suggest that oxalate-induced oxidative stress leads to the production of chemokines such as monocyte chemoattractant protein-1, which is known to recruit a range of immune cells, including macrophages and monocytes, to injury sites, thereby increasing local inflammation (14). We can assume that similar oxalate-induced oxidative or non-oxidative injury in the endothelial cells of the dermal vasculature may lead to vascular inflammation, a subsequent increase in vascular permeability, and, finally, the release of oxalate crystals into the dermis. Alternatively, in accordance with the process by which oxalate crystals appear in the renal interstitium (15), it could be hypothesised that oxalate crystals may translocate to the dermis through transcytosis across vascular endothelial cells, or are formed *de*

novo in the dermis. Which of these proposed mechanisms for initiating cutaneous oxalate deposition is correct is a matter that requires further investigation in *in vitro* and *in vivo* studies.

An interesting feature of the present case is the confinement of oxalate deposits to subungual locations. Our patient had no related symptoms in other cutaneous locations or organ systems. The fingers are a predilection site of extrarenal oxalate deposit (5), probably due to local differences in calcium oxalate metabolism/concentration, or changes in blood circulation.

REFERENCES

1. Spiers EM, Sanders DY, Omura EF. Clinical and histologic features of primary oxalosis. *J Am Acad Dermatol* 1990; 22: 952–956.
2. Rahman N, Hitchcock R. Case report of paediatric oxalate urolithiasis and a review of enteric hyperoxaluria. *J Pediatr Urol* 2010; 6: 112–116.
3. Ohtake N, Uchiyama H, Furue M, Tamaki K. Secondary cutaneous oxalosis: cutaneous deposition of calcium oxalate dihydrate after long-term haemodialysis. *J Am Acad Dermatol* 1994; 31: 368–372.
4. Schulze M, Wachter R, Schmeisser A, Fischer R, Strasser RH. Restrictive cardiomyopathy in a patient with primary hyperoxaluria type II. *Clin Res Cardiol* 2006; 95: 235–240.
5. Bogle MA, Teller CF, Tschen JA, Smith CA, Wang A. Primary hyperoxaluria in a 27-year-old woman. *J Am Acad Dermatol* 2000; 49: 725–728.
6. Rubenstein MC, Martinelli PT, Bayer-Garner IB, Klebuc MJ, Curry JL, Hsu S. Persistent cutaneous manifestations of hyperoxaluria after combined hepatorenal transplantation. *Dermatol Online J* 2004; 10: 10.
7. Sikora P, Beck B, Zajackowska M, Hoppe B. Plasma oxalate level in paediatric calcium stone formers with or without secondary hyperoxaluria. *Urol Res* 2009; 37: 101–105.
8. Small KW, Scheinman J, Klintworth GK. A clinicopathological study of ocular involvement in primary hyperoxaluria type I. *Br J Ophthalmol* 1992; 76: 524–557.
9. Galloway G, Giuliani MJ, Burns DK, Lacomis D. Neuroopathy associated with hyperoxaluria: improvement after combined renal and liver transplantations. *Brain Pathol* 1998; 8: 247–251.
10. Bijarnia RK, Kaur T, Singla SK, Tandon C. Reversal of hyperoxaluria-induced alteration in rat liver by administration of N-acetylcysteine. *Drug Chem Toxicol* 2007; 30: 229–240.
11. Asselman M, Verhulst A, de Broe ME, Verkoelen CF. Calcium oxalate crystal adherence to hyaluronan-, osteopontin-, and CD44-expressing injured/regenerating tubular epithelial cells. *J Am Soc Nephrol* 2003; 14: 3155–3166.
12. Jonassen J, Kohjimoto Y, Scheid CR, Schmidt M. Oxalate toxicity in renal cells. *Urol Res* 2005; 33: 329–339.
13. Khan SR, Glenton PA, Byer KJ. Modeling of hyperoxaluric calcium oxalate nephrolithiasis: Experimental induction of hyperoxaluria by hydroxyl-L-proline. *Kidney Int* 2006; 70: 914–923.
14. Habibzadegah-Tari P, Byer K. Oxalate induced expression of monocyte chemoattractant protein-1 (MCP-1) in HK-2 cells involves reactive oxygen species. *Urol Res* 2005; 33: 440–447.
15. Guo C, McMartin KE. The cytotoxicity of oxalate, metabolite of ethylene glycol, is due to calcium oxalate monohydrate formation. *Toxicology* 2005; 208: 347–355.