

Cutaneous Glomangiopericytoma on the Tip of the Nose

Young Bok Lee, Kyung Jin Lee, Hyun Jeong Park* and Baik Kee Cho

Department of Dermatology, Yeouido St Mary's Hospital, College of Medicine, The Catholic University of Korea, 62 Yeouido-dong, Youngdeungpo-ku, Seoul, 150-713 Korea. *E-mail: hjpark@catholic.ac.kr

Accepted November 1, 2010.

Myopericytomas are characterized histopathologically by a distinctive, concentric perivascular proliferation of round-to-spindle cells with a “staghorn” branching vascular pattern. In the past, these features were regarded as those of hemangiopericytoma (1). However, the term hemangiopericytoma has been abandoned by pathologists for several reasons (2). The original descriptive histopathological features of hemangiopericytoma were not specific for a given entity. The tumours that display a hemangiopericytoma-like histological pattern include various diseases, such as synovial sarcoma, mesenchymal chondrosarcoma and solitary fibrous tumour. The concept of hemangiopericytoma also presented difficulties in predicting clinical behaviour (2). In recent years, the concept of hemangiopericytoma has been evolving to myopericytoma because the spindle cells show myoid differentiation with positivity for smooth muscle actin (3). If the tumour cells closely resemble glomus cells and these tumour cells are characterized by round, punched-out central nuclei and pale eosinophilic cytoplasm, then these cases are referred to as glomangiopericytomas (4).

Although hemangiopericytoma is known to be a rare tumour, more than 100 cases have been reported in the otorhinolaryngology journals (5–7). The predilection sites were the nasal cavity and paranasal sinuses and it was termed as a sinonasal hemangiopericytoma. The term sinonasal hemangiopericytoma has also been renamed intranasal myopericytoma (8) and glomangiopericytoma (9). There have been only a few case reports of glomangiopericytoma in the otorhinolaryngology and pathology journals.

CASE REPORT

A 68-year-old woman presented with an asymptomatic, 0.5 cm-diameter, blue-red, dome-shaped nodule on the tip of her nose (Fig. 1). The lesion had grown slowly for the last 3 years. She had been diagnosed with rheumatoid arthritis 40 years previously and she had been taking medication that included methylprednisolone, hydroxychloroquine and methotrexate. Histopathological examination showed variable numbers of vascular channels that were elongated and displayed prominent branching (a stag-horn appearance) (Fig. 2A). The tumour cells resembled glomus cells with round and ovoid nuclei arranged in short fascicles around thin-walled vessels (Fig. 2B). There was no cytological atypia. Immunohistochemically, the tumour cells stained for smooth muscle actin (Fig. 2C) and vimentin. CD34 immunoperoxidase staining only decorated the endothelium of the vessels, but the perivascular concentric myoid cells were not immunoreactive (Fig. 2D). They did not stain for desmin. On the basis of the histological findings, the tumour was diagnosed as a glomangiopericytoma. The patient underwent successful surgical excision, with no recurrence in the 8 months following the excision.

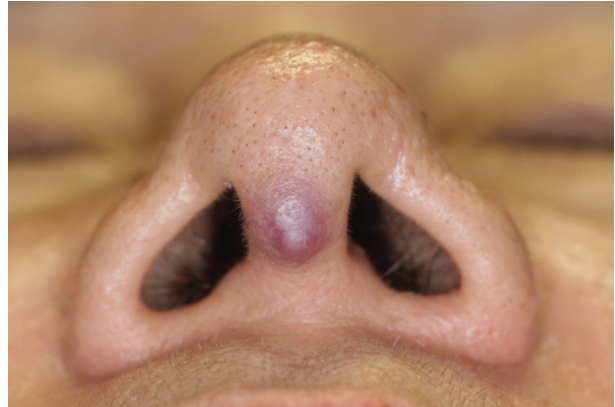

Fig. 1. An asymptomatic, 0.5 cm-diameter, blue-red, dome-shaped nodule on the tip of the nose.

DISCUSSION

The differential diagnoses of glomangiopericytoma include glomangioma, myopericytoma and angioleiomyoma. Although glomus tumours also show varying proportions of glomus cells and blood vessels, glomangioma does not display the concentric perivascular growth. Glomus tumour is composed of sheets of glomus cells, and small vessels are not apparent without the use of special stains. Although numerous vessels are apparent in cases of glomangioma, the vessels are dilated, cavernous-like, thin-walled vascular spaces surrounded by a few layers of glomus cells, and the cells do not show a perivascular concentric growth pattern. Clinically, glomus tumours are classically associated with paroxysmal pain that is often elicited by changes in temperature or pressure and glomangioma usually presents with multiple glomus tumours on the whole body (4). Myopericytoma is a more extensive term of glomangiopericytoma and it does not show glomus-like tumour cells. Angioleiomyoma shares some features with myopericytoma. Angioleiomyoma is composed of mature smooth muscle cells with abundant vascular channels. The smooth muscle cells are more strongly eosinophilic and elongated than glomus-like tumour cells and the smooth muscle cells show desmin positivity (10). In our case, the glomus-like cells were arranged in a concentric perivascular array with smooth muscle actin positivity and desmin negativity, which are the histological characteristics of glomangiopericytoma.

Myopericytoma commonly occurs on the lower extremities, followed by the upper extremities. It rarely affects

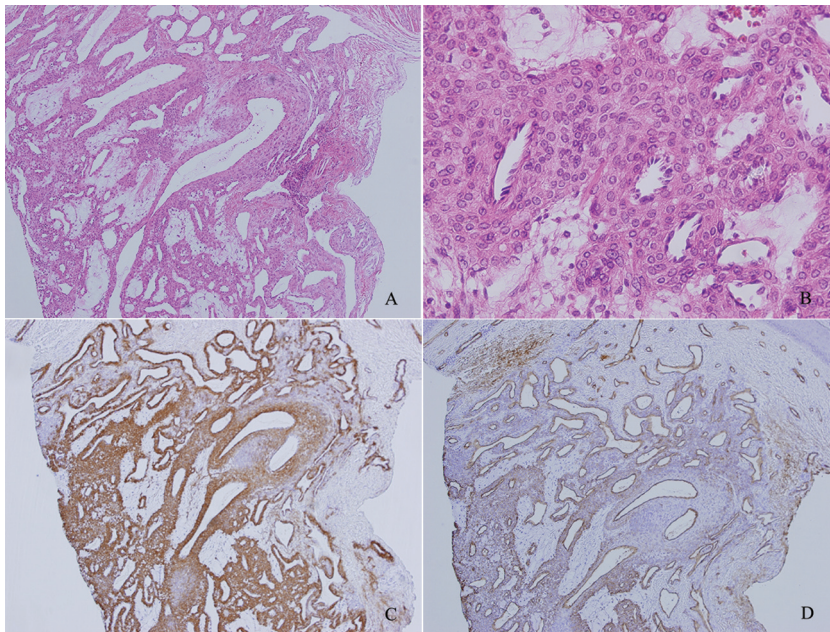


Fig. 2. (A) Histopathological examination showed a variable numbers of vascular channels and perivascular concentric cellular growth (haematoxylin-eosin stain (H&E) $\times 100$). (B) Glomus-like round cells were arranged around the vessels (H&E $\times 400$). (C) The tumour cells stained for smooth muscle actin (smooth muscle actin stain, $\times 100$). (D) CD34 stain was reactive on the endothelium of the vessels (CD34 stain, $\times 100$).

the head and neck region (11). Although more than 100 cases of hemangiopericytoma-like tumours have been reported in the otorhinolaryngeal journals (5–7), all the reported cases involved the nasal cavity and perinasal sinuses, thus the tumours are called sinonasal hemangiopericytomas. The most common clinical manifestation of sinonasal hemangiopericytoma is epistaxis. Sinonasal hemangiopericytoma has been reclassified into myopericytoma (8), glomangiopericytoma (9) and angioleiomyoma (12). Myopericytoma of the oral cavity has been recently reported (13). The cases of glomangiopericytoma reported previously occurred in the nasal cavity. Although there was a case of myopericytoma on the nose (14), to the best of our knowledge, there has been no previous report of cutaneous glomangiopericytoma.

The pathogenesis of glomangiopericytoma is unclear. The possible association of myopericytoma with trauma has been suggested (15). Our patient denied any history of previous trauma. There is currently no evidence to explain why glomangiopericytoma usually occurs in the nasal cavity. Further research into the pathogenesis and prognosis of glomangiopericytoma is needed.

ACKNOWLEDGEMENTS

This work was supported by the National Research Foundation of Korea(NRF) grant funded by the Korea government(Ministry of Education, Science and Technology) (Science research center program, No. R11-2005-017-05003-0 and No. 2010-0002431).

The authors declare no conflicts of interest.

REFERENCES

1. Stout AP, Murray MR. Hemangiopericytoma: a vascular tumor featuring Zimmermann's pericytes. *Ann Surg* 1942; 116: 26–33.
2. Gengler C, Guillou L. Solitary fibrous tumour and haemangiopericytoma: evolution of a concept. *Histopathology* 2006; 48: 63–74.
3. Granter SR, Badizadegan K, Fletcher CD. Myofibromatosis in adults, glomangiopericytoma, and myopericytoma: a spectrum of tumors showing perivascular myoid differentiation. *Am J Surg Pathol* 1998; 22: 513–525.
4. Calonje E. Vascular tumors : tumors and tumor-like conditions of blood vessels and lymphatics. In: Lever WFE, editors *Lever's histopathology of the skin*. 10th edn. Philadelphia: Lippincott Williams & Wilkins, chapter 33, 2009, p. 1049–1051.
5. Hekkenberg RJ, Davidson J, Kapusta L, Freeman JL, Irish JC, Gullane PJ. Hemangiopericytoma of the sinonasal tract. *J Otolaryngol* 1997; 26: 277–280.
6. Catalano PJ, Brandwein M, Shah DK, Urken ML, Lawson W, Biller HF. Sinonasal hemangiopericytomas: a clinicopathologic and immunohistochemical study of seven cases. *Head Neck* 1996; 18: 42–53.
7. Marianowski R, Wassef M, Herman P, Huy PT. Nasal haemangiopericytoma: report of two cases with literature review. *J Laryngol Otol* 1999; 113: 199–206.
8. Wilson T, Hellquist HB, Ray S, Pickles J. Intranasal myopericytoma. A tumour with perivascular myoid differentiation: the changing nomenclature for haemangiopericytoma. *J Laryngol Otol* 2007; 121: 786–789.
9. Tagliatela SC, D'Antonio A, Tagliatela SS, Scotto CS, Parascandolo S. Glomangiopericytoma of the pterygomandibular space: an unusual case. *Br J Oral Maxillofac Surg* 2007; 45: 673–675.
10. Matsuyama A, Hisaoka M, Hashimoto H. Angioleiomyoma: a clinicopathologic and immunohistochemical reappraisal with special reference to the correlation with myopericytoma. *Hum Pathol* 2007; 38: 645–651.
11. Mentzel T, Dei Tos AP, Sapi Z, Kutzner H. Myopericytoma of skin and soft tissues: clinicopathologic and immunohistochemical study of 54 cases. *Am J Surg Pathol* 2006; 30: 104–113.
12. He J, Zhao LN, Jiang ZN, Zhang SZ. Angioleiomyoma of the nasal cavity: a rare cause of epistaxis. *Otolaryngol Head Neck Surg* 2009; 141: 663–664.
13. Sapelli S, Ribas M, Martins WD, de Noronha L, Gomes AP. Myopericytoma of the lip: report of case. *Head Neck* 2009; 31: 561–564.
14. Numata I, Nakagawa S, Hasegawa S, Aiba S. A myopericytoma of the nose. *Acta Derm Venereol* 2010; 90: 192–193.
15. Laga AC, Tajirian AL, Islam MN, Bhattacharyya I, Cohen DM, Plamondon CJ, et al. Myopericytoma: report of two cases associated with trauma. *J Cutan Pathol* 2008; 35: 866–870.