

Treatment of Pre-ulcerative Necrobiosis Lipoidica with Infliximab

Hélène Conte, Brigitte Milpied, Mamadou Kaloga, Nathalie Lalanne, Emilie Belin, Thomas Jouary, Alain Taïeb and Khaled Ezzedine

Department of Dermatology and National Reference Centre for Rare Skin Disorders, Hôpital St-André, CHU de Bordeaux, 1, rue Jean Burguet, FR-33075 Bordeaux, France. E-mail: khaled.ezzedine@chu-bordeaux.fr

Accepted January 19, 2011.

Necrobiosis lipoidica (NL) is a chronic idiopathic granulomatous skin disease often occurring in the setting of diabetes mellitus. Clinically, the lesions present as painful yellow-brown inflammatory plaques with raised borders and atrophic centres. NL typically involves the anterior lower leg and has a tendency to progress to ulceration and scarring. Treatment is often challenging and, to date, no standardized therapy has been proposed. We report here the case of a patient who was seen at a pre-ulcerative stage of NL that had not responded to conventional therapies.

CASE REPORT

A 27-year-old white man consulted for a slightly eroded lesion of the external side of his left ankle, which had gradually enlarged becoming very painful. The lesion had been present for more than 3 years. His medical history was otherwise unremarkable, except for a history of type 1 diabetes mellitus since childhood. Examination revealed atrophic, yellow-brown to red, telangiectatic plaque, 6×9 cm in size (Fig. 1a). The patient reported that the lesion had a tendency to ulcerate following minimal trauma, which clearly affected his quality of life. Skin biopsy from the lesion was consistent with NL, showing necrobiotic collagen with sclerosis and palisaded granuloma in the dermis. The dermal interstitial infiltrate consisted of histiocytes, multinucleated giant cells, lymphocytes, and plasma cells. Treatment with topical tacrolimus and intralesional triamcinolone acetonide (5 mg/l) was unsuccessful.

Given the young age of the patient, and based on previous reports arguing for efficacy of biological agents in NL (1, 2), it was decided to start therapy with infliximab. Chest X-ray, tuberculin test, hepatitis B and C and HIV serologies were all negative. The patient was therefore started on intravenous infliximab therapy, 5 mg/kg, associated for the first infusion

with 200 mg hydrocortisone. The patient received a total of four infusions (at weeks 0, 2, 6, and 12). At his first post-treatment visit (week 2), the lesion had become painless. Complete wound healing was achieved at week 6 of infliximab therapy, with fading of the erythematous component, flattening of the margin and an excellent cosmetic result (Fig. 1b). The treatment was well tolerated with no noted side-effects. At 9-month follow-up, no relapse had been noted.

DISCUSSION

NL is a rare chronic inflammatory granulomatous skin disease of unknown origin. It is reported to occur more frequently in women than men (3, 4). The disease is often associated with diabetes mellitus, although treatment of a patient's diabetes has not been shown to improve the cutaneous lesions (3). Elective sites for the lesion are the shins, back of the hands and the forearms. NL may resolve spontaneously; however, ulceration occurs in up to 35% of patients. Of note, unpredictable rapid and fulminant ulceration may occur, leaving debilitating scars (1).

Many therapies have been proposed for NL with varying degrees of success. These treatments include systemic corticosteroids, topical tacrolimus, cyclosporine, mycophenolate mofetil, fumaric acid esters, clofazimine, anti-malarial agents, topical psoralen plus ultraviolet A (PUVA), UVA1 phototherapy, photodynamic therapy and excision followed by skin grafting (2). However, no overall treatment for NL has proven to be effective in controlled studies (5). The reported response of NL to pentoxifylline (6) indicated a possible role of tumour necrosis factor alpha (TNF- α) in this disease and prompted some authors to initiate anti-TNF- α therapy in treatment-resistant NL (7). TNF- α is a pro-inflammatory cytokine that has been implicated in the maintenance of granulomas by macrophages. Thus, anti-TNF- α agents, such as infliximab and etanercept, have been employed in the treatment of various cutaneous granulomatous diseases, such as granuloma annulare (8), sarcoidosis (9) and, recently, NL (1). In the few reported cases of NL treated with anti-TNF- α agents, the response to infliximab was obtained in a shorter time than with etanercept and this observation has led us to favour infliximab.

Until now, anti-TNF- α agents have been used in extensively ulcerated NL. In our patient infliximab therapy was effective in treating pre-ulcerative NL with an excellent cosmetic outcome. This efficacy may be of interest in preventing debilitating scars related to heal-

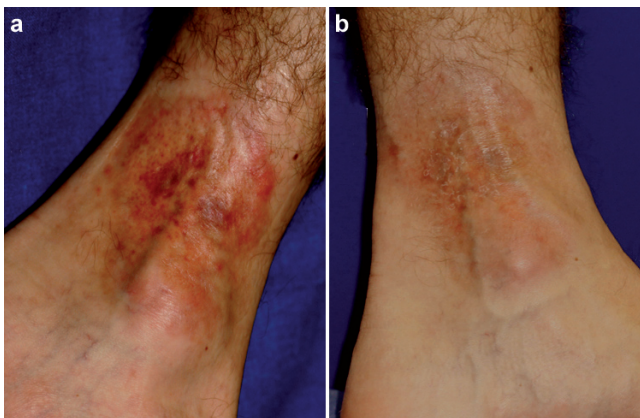


Fig. 1. (a) Atrophic, yellow-brown to red, telangiectatic plaque, 6×9 cm in size. (b) Week 6 of infliximab therapy with fading of the erythematous component and flattening of the margin.

ing of ulcerated NL with a positive impact on quality of life. However, although the reported clinical response to these therapies has so far been excellent, controlled studies are awaited to establish with certainty the efficacy of anti-TNF therapies in NL and better to define the optimal dose and duration of treatment.

The authors declare no conflict of interest.

REFERENCES

1. Hu SW, Bevona C, Winterfield L, Qureshi AA, Li VW. Treatment of refractory ulcerative necrobiosis lipoidica diabeticorum with infliximab: report of a case. *Arch Dermatol* 2009; 145: 437–439.
2. Suárez-Amor O, Pérez-Bustillo A, Ruiz-González I, Rodríguez-Prieto MA. Necrobiosis lipoidica therapy with biologicals: an ulcerated case responding to etanercept and a review of the literature. *Dermatology* 2010; 221: 117–121.
3. Peyri J, Moreno A, Marcoval J. Necrobiosis lipoidica. *Semin Cutan Med Surg* 2007; 26: 87–89.
4. Huntley AC. The cutaneous manifestations of diabetes mellitus. *J Am Acad Dermatol* 1982; 7: 427–455.
5. Elmholdt TR, Sørensen HB, Fogh K. A severe case of ulcerating necrobiosis lipoidica. *Acta Derm Venereol* 2008; 88: 177–178.
6. España A, Sánchez-Yus E, Serna MJ, Redondo P, Robledo A, Quintanilla E. Chronic balanitis with palisading granuloma: an atypical genital localization of necrobiosis lipoidica responsive to pentoxifylline. *Dermatology* 1994; 188: 222–225.
7. Drosou A, Kirsner RS, Welsh E, Sullivan TP, Kerdel FA. Use of infliximab, an anti-tumor necrosis alpha antibody, for inflammatory dermatoses. *J Cutan Med Surg* 2003; 7: 382–386.
8. Shupack J, Siu K. Resolving granuloma annulare with etanercept. *Arch Dermatol* 2006; 142: 394–395.
9. Haley H, Cantrell W, Smith K. Infliximab therapy for sarcoidosis (lupus pernio). *Br J Dermatol* 2004; 150: 146–149.