

## Scleroderma-like Reaction Restricted to the Red Parts of a Tattoo

Nicolas Kluger<sup>1</sup>, Pascale Mathelier-Fusade<sup>2</sup> and Philippe Moguelet<sup>3</sup>

<sup>1</sup>Department of Dermatology, University of Montpellier I, Hôpital Saint-Eloi, CHU Montpellier; 80, avenue Augustin Fliche, FR-34295 Montpellier cedex 5,

<sup>2</sup>Department of Dermato-allergology, and <sup>3</sup>Pathology, CHU Tenon, Paris, France. E-mail: nicolaskluger@yahoo.fr

Accepted May 26, 2008.

Sir,

The introduction of pigments or dyes during tattooing may trigger various histological types of hypersensitivity reaction, mainly lichenoid, granulomatous, sarcoidosis-like, pseudolymphomatous and eczematous (1). The time of appearance of these reactions is highly variable, from immediately after tattooing to 45 years later (2). We report here an unusual case of dermal sclerosis restricted to the red part of tattoos. Such “scleroderma-like” reactions have been reported on very few occasions (3, 4).

### CASE REPORT

An otherwise healthy 47-year-old woman presented for an inflammatory infiltration of an ankle tattoo, which had become symptomatic almost immediately after tattooing. Eighteen months earlier, a yellow, orange, red, white and black “sacred heart” had been tattooed on her ankle in a professional tattoo parlour (Fig. 1A). Within the first week, she noticed unusual swelling and delayed healing. Pruritus had been intense, with a severe impact on daily living and sleep for the past 18 months. This episode was the first she had reported after tattooing, as she had been tattooed three times previously without complication. However, a concomitant itchy reaction had also developed at this time on the red part of another tattoo located in the lumbar area, which had been drawn by the same artist with the same red

ink 6 months before the “sacred heart”. Both reactions had remained stable without improvement. She refused to apply any corticosteroid ointment during this time. Examination of the 18-month-old tattoo showed an inflamed, squamous and indurated infiltration confined to the red parts. Several exulcerations were noted over the red area (Fig. 1B). Physical examination was otherwise normal, with no sign of systemic scleroderma. The clinical features were suggestive of a red tattoo pigment hypersensitivity reaction.

Histological examination of a 4-mm punch biopsy of the red tattoo revealed a lichenified epidermis with compact hyperkeratosis, hypergranulosis and acanthosis. An inflammatory sclerosis was located in the superficial and mid-dermis with thickened and homogenized collagen bundles, lymphocytes and macrophages. Exogenous red tattoo pigments were localized around mid-dermal vessels free in the dermis or in macrophages. Focal lichenoid reaction was observed (Fig. 2). The features were not indicative of localized scleroderma. A diagnosis of dermal sclerosis related to a chronic inflammatory reaction to the red pigment was suspected. No test could be performed on the culprit red ink as the manufacturer did not reply to our request for a sample or information on its composition. Betamethasone dipropionate 0.05% ointment was applied daily for a month and then tapered slowly over 3 months. Pruritus resolved within a week and lesions improved within the first 2 months. After 3 months, no inflammation was noted. We suggested that the patient avoid further tattooing with any type of red ink in the absence of identified components. She had two new tattoos done with various colours (yellow, green, blue, orange, pink, violet, brown and black) without complication. However, one of them was a pink cat with red ink from a different manufacturer applied for the nose. Pruritus occurred on that very location after tattooing, but no recall reaction occurred elsewhere. She and her tattooist have decided to stop using red ink.

### DISCUSSION

We report here an unusual and severe “scleroderma-like” reaction after tattooing, which was restricted to the red parts of a tattoo. Symptoms of hypersensitivity reaction to tattoo pigments are often non-specific, including discomfort, swelling, papules or nodules and pruritus (5). Clinical induration is not an uncommon manifestation of tattoo reactions (5), but the

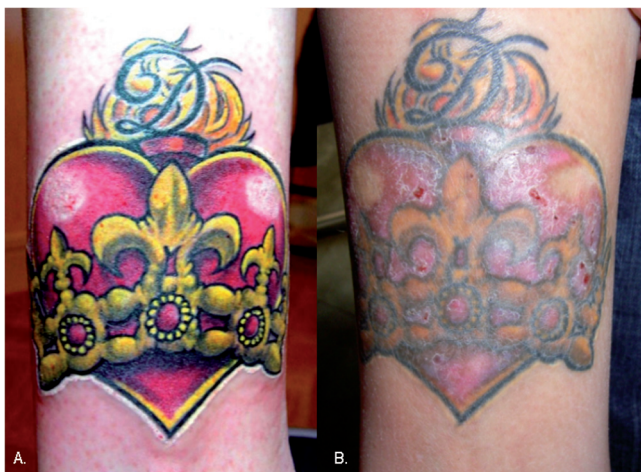

Fig. 1. (A) The fresh ankle tattoo immediately after the last tattooing session 18 months previously (the colour brightness is due to the presence of pigments in the epidermis). (B) Tattoo reaction after 18 months, with infiltration and exulcerations.

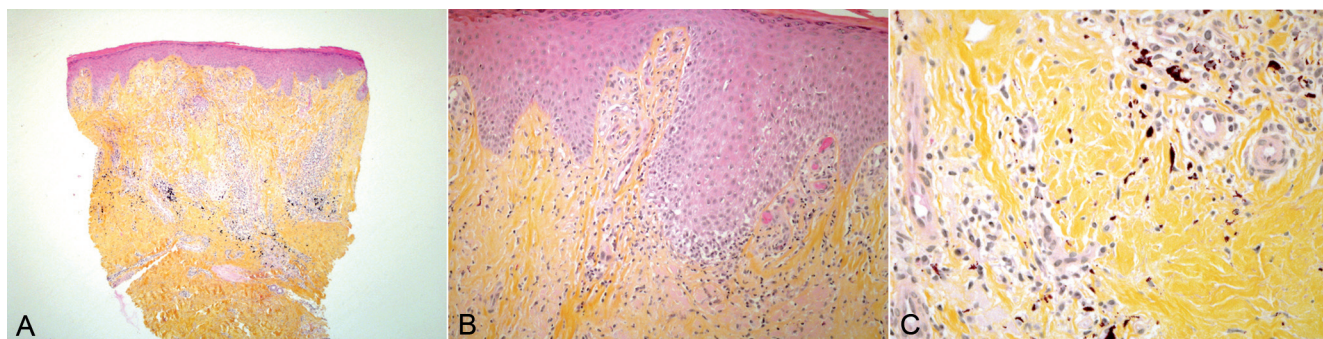


Fig. 2. (A) Superficial and mid-dermal inflammatory sclerosis. (B) Epidermal acanthosis with focal lichenoid reaction. (C) Dermal sclerosis with lymphocyte and macrophage infiltrate and "red" pigment deposit. (Hematoxylin and eosin: A:  $\times 25$ , B:  $\times 100$ , C:  $\times 200$ .)

relationship between induration and sclerosis is not clearly mentioned among the histological features (5). Therefore, induration is not predictive of the presence of sclerosis. Dermal fibrosis or sclerosis is rarely mentioned in the literature (6–8), and it occurs from months to years after tattooing (6–8). Müller et al. (9) stated that fibrous reactions were discrete in tattoos. In 2002, Mahalingam et al. (3) reported a histological "morphea-like" reaction that occurred in a one-year-old multicoloured tattoo. The clinical presentation was not specific (pruritus) and, as stated by the authors, the histology was more in favour of a non-specific sclerotic reaction to foreign bodies than a true morphea (3). Our case seems strikingly similar to this report. Our patient presented an 18-month history of untreated tattoo reaction. We speculate that dermal sclerosis may have been the final step in a chronic/persistent inflammatory process triggered by a specific compound in the ink. Evidence for an underlying hypersensitivity reaction to a red ink component includes: (i) a restriction of the reaction to the red parts (11); (ii) a lichenoid pattern on histology, which is the most common hypersensitivity tattoo-reaction (11); and (iii) a "recall" phenomenon in the red parts of two tattoos. Unfortunately, we could not obtain a sample of the culprit ink or any information on composition. One specific component of the red pigment (e.g. mercury, cadmium, nickel, etc.) or an azo dye may have triggered an inflammatory reaction in this case, leading to severe sclerotic manifestations. Chronic rubbing and scratching may also have contributed to this phenomenon, as suggested by the presence of erosions and epidermal lichenification.

Lastly, various types of trauma and injury have been associated with the onset of morphea and scleroderma (11). Nevertheless, such cases after tattooing are anecdotal. To date, only a single case of localized scleroderma after tattooing has been mentioned in the literature (4). Our patient did not present any sign of systemic disease or other lesion of morphea.

Dermal sclerosis is an unusual reaction that may occur in tattoos, complicating a chronic/persistent inflammatory reaction to pigments/dyes. While examining samples of tattoo-induced reaction, pathologists should look carefully for such modification in order to establish its true prevalence. Moreover, our case is a reminder that similar colours of ink from different manufacturers may share common components. Therefore, in the case of a tattoo reaction to a specific colour of ink and no identification of the culprit component by contact dermatitis studies, the patient should be advised to avoid the colour completely rather than trying another brand.

*The authors declare no conflicts of interest.*

## REFERENCES

1. Kazandjieva J, Tsankov N. Tattoos: dermatological complications. *Clin Dermatol* 2007; 25: 375–382.
2. Goldstein N. Mercury-cadmium sensitivity in tattoos. A photoallergic reaction in red pigment. *Ann Intern Med* 1967; 67: 984–989.
3. Mahalingam M, Kim E, Bhawan J. Morphea-like tattoo reaction. *Am J Dermatopathol* 2002; 24: 392–395.
4. Goldstein N. IV. Complications from tattoos. *J Dermatol Surg Oncol*. 1979; 5: 869–878.
5. Sowden JM, Byrne JP, Smith AG, Hiley C, Suarez V, Wagner B, Slater DN. Red tattoo reactions: X-ray microanalysis and patch-test studies. *Br J Dermatol* 1991; 124: 576–580.
6. Ravits HG. Allergic tattoo granuloma. *Arch Dermatol* 1962; 86: 287–289.
7. Verdich J. Granulomatous reaction in a red tattoo. *Acta Derm Venereol* 1981; 61: 176–177.
8. Singh RS, Hafeez Diwan A, Prieto VF. Potential diagnostic pitfalls in melanoma arising in a cutaneous tattoo. *Histopathology* 2007; 51: 283–285.
9. Müller KM, Schmitz I, Hupe-Nörenberg L. Reaction patterns to cutaneous particulate and ornamental tattoos. *Pathologe* 2002; 23: 46–53.
10. Mortimer NJ, Chave TA, Johnston GA. Red tattoo reactions. *Clin Exp Dermatol* 2003; 28: 508–510.
11. Torreló A, Suárez J, Colmenero I, Azorín D, Perera A, Zambrano A. Deep morphea after vaccination in two young children. *Pediatr Dermatol* 2006; 23: 484–487.