

CLINICAL REPORT

Simultaneous Onset of Segmental Vitiligo and a Halo Surrounding a Congenital Melanocytic Naevus

Uta B. HOFMANN, Eva-Bettina BRÖCKER and Henning HAMM
Department of Dermatology, University Clinics of Würzburg, Würzburg, Germany

Unlike in common melanocytic naevi, an acquired leukoderma (halo) surrounding a congenital melanocytic naevus is a rare phenomenon. A 6-year-old boy developed a depigmentation around a congenital melanocytic naevus on the right thigh. Simultaneously, segmental vitiligo appeared on the thigh, lower abdomen and buttock of the same side with sharp midline demarcation. Examination for associated autoimmune diseases proved negative. The simultaneous occurrence of a halo phenomenon around a congenital melanocytic naevus and segmental vitiligo, as well as identical histological and immunohistological findings in both pigmented lesions, suggest shared immunological mechanisms. Key words: segmental vitiligo; hypopigmentation; congenital melanocytic naevus; halo naevus.

(Accepted February 16, 2009.)

Acta Derm Venereol 2009; 89: 402–406.

Uta B. Hofmann, Department of Dermatology, University Clinics of Würzburg, Josef-Schneider-Str. 2, DE-97080 Würzburg, Germany. E-mail: hofmann_u1@klinik.uni-wuerzburg.de

A ring of depigmentation, called halo phenomenon, occasionally occurs around acquired melanocytic lesions, including compound and intradermal naevi, but much less often around congenital melanocytic naevi (CMN), blue naevi and Spitz naevi. Halo naevi are usually located on the trunk of up to 1% of the general population (1). In approximately half of the patients, several to multiple lesions may occur. Histological examination showing naevus cells in contact with a dense, lymphocytic mononuclear infiltrate differentiate halo naevi from vitiligo. Both entities are more often present in the same individual than by chance (2). In two large studies halo naevi were found to be associated with vitiligo in 7.2% (3, 4) and 4.4% (5) of patients, respectively.

Vitiligo is an acquired disease characterized by progressive depigmentation of the skin, which affects 0.5–2% of the general population (2). The aetiology of this disorder is unclear, but there are at least three theories, including autoimmune, autocytotoxic, and neural hypotheses. Autoimmune mechanisms are widely discussed as a possible cause, and this is supported by genetic predisposition, association with (other) autoimmune diseases as well as the presence of anti-

melanocytic antibodies and lesional lymphohistiocytic inflammatory infiltrates (6–9). Furthermore, a complex biochemical imbalance with defective free-radical defence, in which redox enzymes play an important role, could interfere with melanin content and synthesis (10, 11). Based on existing research, it has recently been proposed that vitiligo has a multi-factorial aetiology, characterized by multiple sequential pathogenetic steps. The first step is an increase in external or internal phenol/catechol concentration in the melanocyte environment, serving as a preferred surrogate substrate of tyrosinase, competing with its physiological substrate tyrosine. The conversion of these substrates into reactive quinones is reinforced by a disturbed redox balance with increasing hydrogen peroxide (H₂O₂). Such reactive quinones can be covalently bound to the catalytic centre of tyrosinase (haptentation) and may serve as a new antigen presented by Langerhans' cells and stimulating the proliferation of cytotoxic T cells (12, 13).

Vitiligo may be divided into the common disseminated form (vitiligo vulgaris), a form with predilection of face and distal extremities (vitiligo acrofacialis), and unilateral asymmetric forms, including focal and segmental types. A mixed pattern of distribution has also been described. Segmental or unilateral vitiligo is a rare subtype that usually develops in children and, after rapid progression, persists unchanged throughout life (3). Segmental or unilateral vitiligo is often preceded by a steep increase in oxidative stress (e.g. exposure to paraquat) and/or increase in catechols (intradermal injections containing adrenaline) (13). The sharp delineation at the midline is assumed to be a reflection of the action of cytotoxic T cells, which originate from the lymph nodes and are trafficked via the efferent microvascular tree via homing receptors. It has been shown that the receptors sometimes have a unique unilateral homing code (14).

We describe here the case of a 6-year-old boy with the rare association of a halo emerging around a CMN and segmental vitiligo that appeared simultaneously. Similarities and differences between these two pigmentary disorders are discussed.

CASE REPORT

A Turkish boy was born with a CMN on the lateral aspect of the right thigh. On initial presentation at the

age of 4 years the pigmented naevus was 2.5×1 cm in size and had no halo or other areas of depigmentation. Re-examination 10 months later revealed a 2.7×1.2 cm pigmented lesion with a verrucous surface. A depigmented halo of 1.5 cm breadth around the congenital naevus appeared at the age of 6 years (Fig. 1A). Simultaneously, large depigmented patches developed on the thigh, the lower abdomen and buttock of the same side of the body in a segmental arrangement with sharp midline demarcation (Fig. 1B). There was no family history of vitiligo, other autoimmune disorders or melanoma. Physical and blood examinations revealed no disorders known to be sometimes associated with vitiligo.

On the request of the patient's parents the CMN was excised under local anaesthesia after obtaining written informed consent. Histological examination of the pigmented lesion showed a predominantly intradermal melanocytic naevus with many infundibular cysts scattered in the epidermis. The melanocytes had a band-like pattern occupying the entire dermis. Melanocytes and nests followed the adnexal structures in the deeper dermis, where the cells were arranged in an infiltrating pattern involving the upper subcutis. The CMN was surrounded and infiltrated by a dense lymphocytic infiltrate (Fig. 2A). Immunohistology with an antibody against MART-1 (melan A, clone A103, # M7196, DAKO, Hamburg, Germany) revealed that melanocytes were markedly reduced or absent along the dermo-epidermal junction at the margin of the naevus (Fig. 2B). The dense lymphocytic infiltrate was composed of predominantly CD3-positive (DAKO, clone F7238, # M7254) (Fig. 2C) and CD8-positive cytotoxic T cells (DAKO, clone C8/144B, # N1592) (Fig. 2D) as well as some CD20-positive cells (data not shown). The surrounding halo of the CMN and a punch biopsy from a depigmented area on the lower abdomen showed similar histological and immunohistochemical features. In both lesions a regular epidermis and a mild dermal lymphocytic infiltrate were seen (Fig. 2E). MART-1-positive melanocytes were almost absent in the basal layer (Fig. 2F). The mild infiltrate in the dermis was composed of predominantly

CD3-positive (Fig. 2G) and some CD8-positive cytotoxic T cells (Fig. 2H).

DISCUSSION

A halo naevus, also termed leukoderma acquisitum centrifugum, characteristically presents as a pigmented melanocytic naevus surrounded by a well-defined, depigmented ring. Frequently, the naevus loses its pigment and finally fades away, leaving a depigmented patch of 0.5–5 cm (2). Halo naevi develop during childhood or adolescence and are most often located on the trunk of approximately 1% of Caucasians (1). A halo naevus may remain solitary, but up to half of patients may develop multiple lesions that occur simultaneously or successively (1). Although the pathogenesis is unknown, a cytotoxic T-cell-mediated immune response is suspected to be involved in the destruction of melanocytes (15). In accordance with this concept, a local proliferation of T-cell clones activated by common naevus antigens has been found in different halo naevi of the same patient (16). The cell infiltrate is composed mainly of CD8-positive T lymphocytes, which express the early cell activation antigen CD69 and also actively synthesize tumour necrosis factor (TNF) alpha (17, 18). It is well established that the dermal infiltrate in halo naevi leads to an oxygen burst including H_2O_2 generation (16), which plays a crucial role in the new convergence theory of the pathogenesis of vitiligo, as described above (12, 13). Clinically, the halo phenomenon around naevi resembles the depigmentation seen in vitiligo. However, several investigations support the assumption that halo naevi and vitiligo are distinct entities and exhibit different pathomechanisms (15, 16, 19, 20). Nevertheless, it has been proven that these two pigmentary disorders are often associated (21). Usually, halo naevi are already present long before the manifestation of vitiligo lesions.

CMN are present in 0.6–1.6% of newborns (22). In contrast to acquired melanocytic naevi, the occurrence of a halo phenomenon around CMN has been reported

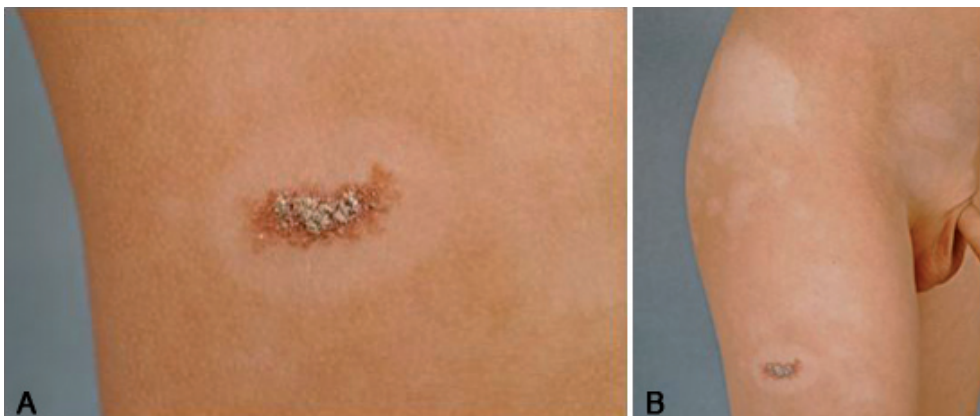


Fig. 1. (A) Congenital melanocytic naevus with a verrucous surface surrounded by a depigmented halo 1.5 cm in diameter. (B) Large depigmented patches in a segmental arrangement on the lower abdomen, buttock and thigh of the right side of the body.

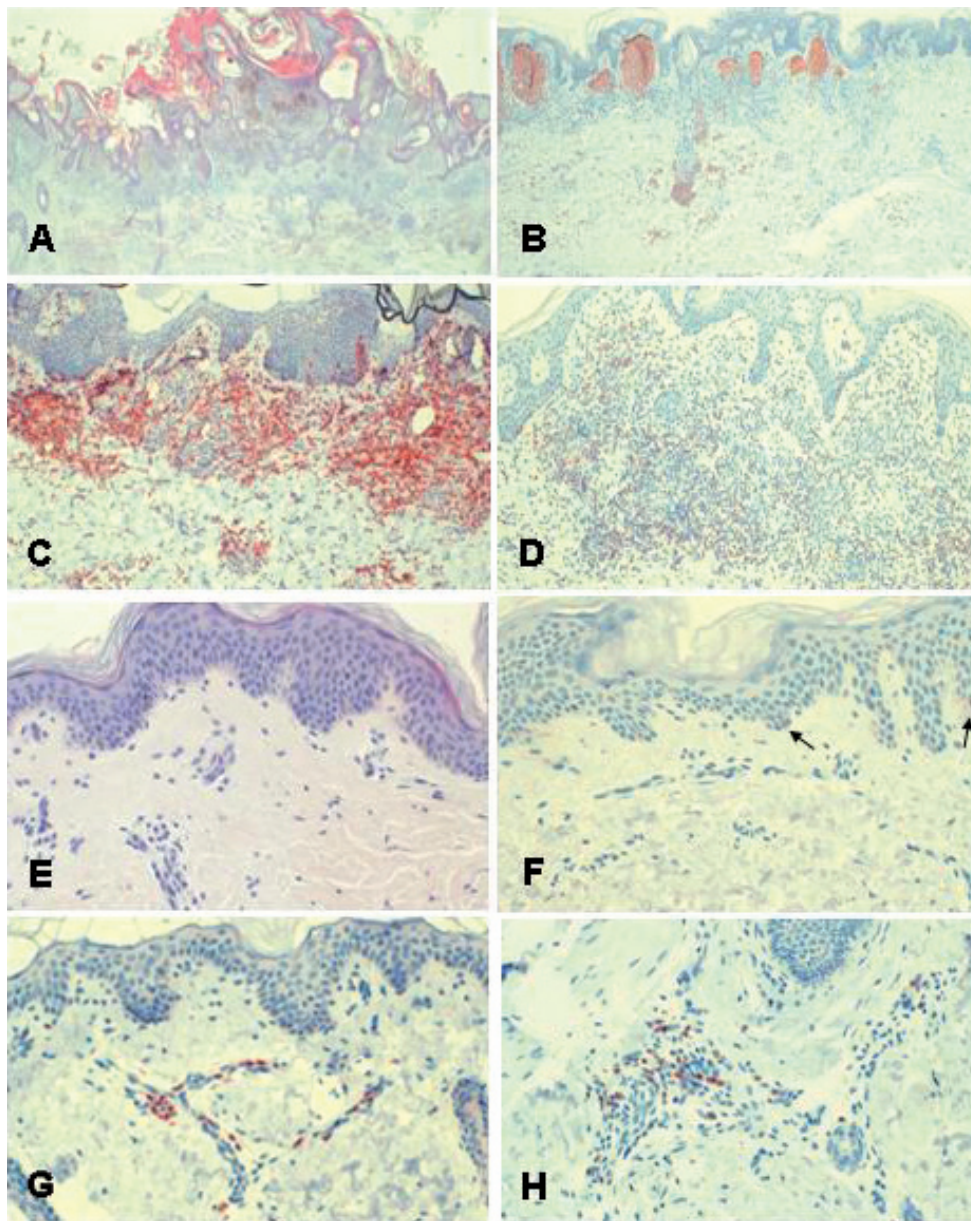


Fig. 2. Histological examination of the excised congenital naevus (A–D) and a punch biopsy from a depigmented area (E–H). (A) Mainly intradermal melanocytic naevus. The cells are disposed in a broad band-like pattern and naevus cells and nests extend into the deep dermis (haematoxylin-eosin (H&E), $\times 20$). (B) Melanocytes are markedly reduced or absent along the dermo-epidermal junction at the border of the naevus (MART-1 $\times 20$). The naevus is surrounded and infiltrated by a dense lymphocytic infiltrate composed of predominantly (C) CD3-positive and (D) CD8-positive cytotoxic T cells (C, D $\times 100$). (E) Punch biopsy from a depigmented area on the lower abdomen revealed a regular epidermis with a mild dermal lymphocytic infiltrate (H&E). (F) The basal layer shows only a few MART-1-positive melanocytes (*arrows*). The mild infiltrate in the dermis is composed of predominantly (G) CD-3 positive and (H) some CD8-positive cytotoxic T cells (H&E $\times 200$).

only rarely (reviewed in (23)). A depigmentation can develop around and/or inside the naevus. For example, Itin & Lautenschlager (23) described a 6-year-old boy who developed depigmentation of a CMN and a whitish halo around the naevus when he was 3 years old. In addition, depigmented lesions distant from the CMN occurred one year later. Recently, Dainichi et al. (24) reported a patient whose CMN disappeared after concomitant onset of vitiligo vulgaris at the age of 19 years. In contrast to the cases mentioned above, the halo around the naevus of our patient did not feature regression or depigmentation of the naevus itself. To our knowledge, the simultaneous appearance of a halo phenomenon around a CMN and the manifestation of segmental vitiligo, as occurred in our patient, has not been described so far. This coincidence could have happened by chance, but an interrelation between these

conditions appears much more likely, as immunological factors seem to play a crucial role for the induction of both the halo phenomenon and vitiligo (25). Immunohistology of the CMN of our patient revealed a dense CD3- and CD8-positive infiltrate. The surrounding halo, as well as a biopsy from a distant vitiligo lesion, showed a mild perivascular infiltrate of the same type.

The presence of infiltrating cytotoxic CD8-positive T cells in halo naevi supports the hypothesis that these cells may participate in the regression of the naevus by direct cytotoxic damage. The emigration of these cells may, in turn, be responsible for vitiligo lesions at sites distant from the halo naevus, although circulating antibodies may also contribute to this phenomenon (15). The disappearance of almost all naevus cells from a lesion of a CMN after concomitant onset of typical vitiligo, as described by Dainichi et al. (24) and in our

case, indicate that the pathogenic mechanism of vitiligo, probably associated with melanocyte-specific cytotoxic T cells, can attack not only epidermal and follicular melanocytes but also congenital naevus cells.

De Vijlder et al. (26) investigated the human leucocyte antigen (HLA) class II profile in patients with vitiligo vulgaris and vitiligo associated with halo naevi. These authors identified distinct HLA antigens in both groups and suggest that different auto-antigens may be involved in different forms of vitiligo. As a clinical argument for their diversity, the extensiveness and activity of vitiligo were lower in patients with vitiligo associated with halo naevi compared with patients with vitiligo vulgaris.

There are many reports about the possible relationship between vitiligo, halo naevi or vitiligo-like leukoderma and melanoma (6). Studies on cellular immunity in 7 melanoma patients with associated vitiligo revealed an infiltrate consisting of CD8-positive lymphocytes with a clonal or oligoclonal T-cell receptor profile as a possible sign of specific antigen stimulation (27, 28). It has been postulated more than 20 years ago that vitiligo might be an indicator of a good prognosis in melanoma patients (29, 30). Accordingly, occurrence of autoimmune phenomena including vitiligo was found to be a marker of better prognosis in melanoma patients treated with high-dose adjuvant interferon alpha-2b (31). However, larger studies are needed to clarify whether vitiligo is a protective factor against melanoma or its progression (5).

Halo naevi have occurred in patients with melanoma as well as in patients with melanoma in giant CMN (32, 33). However, a giant CMN *per se* carries a considerable risk of malignant transformation (34).

In summary, the simultaneous appearance of a halo phenomenon around a CMN and segmental vitiligo, as well as the presence of cytotoxic CD8-positive T cells in both lesions, suggest common immunological mechanisms directed against similar or even identical molecular targets.

REFERENCES

- Mollet I, Ongenaes K, Naeyaert JM. Origin, clinical presentation, and diagnosis of hypomelanotic skin disorders. *Dermatol Clin* 2007; 25: 363–371.
- Herane MI. Vitiligo and leukoderma in children. *Clin Dermatol* 2003; 21: 283–295.
- Hu Z, Liu JB, Ma SS, Yang S, Zhang XJ. Profile of childhood vitiligo in China: an analysis of 541 patients. *Pediatr Dermatol* 2006; 23: 114–116.
- Schallreuter KU, Lemke R, Brandt O, Schwartz R, Westhofen M, Montz R, et al. Vitiligo and other diseases: coexistence or true association? Hamburg study on 321 patients. *Dermatology* 1994; 188: 269–275.
- Handa S, Dogra S. Epidemiology of childhood vitiligo: a study of 625 patients from north India. *Pediatr Dermatol* 2003; 20: 207–210.
- Hartmann A, Bedenk C, Keikavoussi P, Becker JC, Hamm H, Bröcker EB. Vitiligo and melanoma-associated hypopigmentation (MAH)-shared and discriminative features. *J Dtsch Dermatol Ges* 2008; 6: 1053–1059.
- Kemp EH, Waterman EA, Gawkrödger DJ, Watson PF, Weetman AP. Autoantibodies to tyrosinase-related protein-1 detected in the sera of vitiligo patients using a quantitative radiobinding assay. *Br J Dermatol* 1998; 139: 798–805.
- Ogg GS, Rod DP, Romero P, Chen JL, Cerundolo V. High frequency of skin-homing melanocyte-specific cytotoxic T lymphocytes in autoimmune vitiligo. *J Exp Med* 1998; 188: 1203–1208.
- Palermo B, Campanelli R, Garbelli S, Mantovani S, Lantelme E, Brazzelli V, et al. Specific cytotoxic T lymphocyte responses against Melan-A/MART1, tyrosinase and gp100 in vitiligo by the use of major histocompatibility complex/peptide tetramers: the role of cellular immunity in the etiopathogenesis of vitiligo. *J Invest Dermatol* 2001; 117: 326–332.
- Dell'Anna ML, Picardo M. A review and a new hypothesis for non-immunological pathogenetic mechanisms in vitiligo. *Pigment Cell Res* 2006; 19: 406–411.
- Schallreuter KU. Oxidative stress in the human epidermis. *G Ital Dermatol Venereol* 2005; 140: 505–514.
- Schallreuter KU, Bahadoran P, Picardo M, Slominski A, Ellassiuty YE, Kemp EH, et al. Vitiligo pathogenesis: autoimmune disease, genetic defect, excessive reactive oxygen species, calcium imbalance, or what else? *Exp Dermatol* 2008; 17: 139–140.
- Westerhof W, d'Ischia M. Vitiligo puzzle: the pieces fall in place. *Pigment Cell Res* 2007; 20: 345–359.
- Picker LJ, Terstappen LW, Rott LS, Streeter PR, Stein H, Butcher EC. Differential expression of homing-associated adhesion molecules by T cell subsets in man. *J Immunol* 1990; 145: 3247–3255.
- Zeff RA, Freitag A, Grin CM, Grant-Kels JM. The immune response in halo nevi. *J Am Acad Dermatol* 1997; 37: 620–624.
- Musette P, Bachelez H, Flageul B, Delarbre C, Kourilsky P, Dubertret L, et al. Immune-mediated destruction of melanocytes in halo nevi is associated with the local expansion of a limited number of T cell clones. *J Immunol* 1999; 162: 1789–1794.
- Fernandez-Herrera J, Fernandez-Ruiz E, Lopez-Cabrera M, Garcia-Diez A, Sanchez-Madrid F, Gonzalez-Amaro R. CD69 expression and tumour necrosis factor-alpha immunoreactivity in the inflammatory cell infiltrate of halo naevi. *Br J Dermatol* 1996; 134: 388–393.
- Baranda L, Torres-Alvarez B, Moncada B, Portales-Perez D, de la Fuente H, Layseca E, et al. Presence of activated lymphocytes in the peripheral blood of patients with halo nevi. *J Am Acad Dermatol* 1999; 41: 567–572.
- Schallreuter KU, Kothari S, Elwary S, Rokos H, Hasse S, Panske A. Molecular evidence that halo in Sutton's naevus is not vitiligo. *Arch Dermatol Res* 2003; 295: 223–228.
- Akasu R, From L, Kahn HJ. Characterization of the mononuclear infiltrate involved in regression of halo nevi. *J Cutan Pathol* 1994; 21: 302–311.
- Schallreuter KU, Lemke R, Brandt O, Schwartz R, Westhofen M, Montz R, et al. Vitiligo and other diseases: coexistence or true association? Hamburg study on 321 patients. *Dermatology* 1994; 188: 269–275.
- Karvonen SL, Vaajalahti P, Marenk M, Janas M, Kuokkanen K. Birthmarks in 4346 Finnish newborns. *Acta Derm Venereol* 1992; 72: 55–57.
- Itin PH, Lautenschlager S. Acquired leukoderma in congenital pigmented nevus associated with vitiligo-like depig-

- mentation. *Pediatr Dermatol* 2002; 19: 73–75.
24. Dainichi T, Moroi Y, Urabe K, Hashimoto T, Furue M. Vitiligo onset removes congenital nevocellular nevus cells. *J Dermatol Sci* 2008; 51: 66–69.
 25. Brandt O, Christophers E, Folster-Holst R. Halo dermatitis followed by the development of vitiligo associated with Sutton's nevi. *J Am Acad Dermatol* 2005; 52: S101–S104.
 26. de Vijlder HC, Westerhof W, Schreuder GM, de Lange P, Claas FH. Difference in pathogenesis between vitiligo vulgaris and halo nevi associated with vitiligo is supported by an HLA association study. *Pigment Cell Res* 2004; 17: 270–274.
 27. Becker JC, Guldberg P, Zeuthen J, Brocker EB, Straten PT. Accumulation of identical T cells in melanoma and vitiligo-like leukoderma. *J Invest Dermatol* 1999; 113: 1033–1038.
 28. Le Gal FA, Avril MF, Bosq J, Lefebvre P, Deschemin JC, Andrieu M, et al. Direct evidence to support the role of antigen-specific CD8(+) T cells in melanoma-associated vitiligo. *J Invest Dermatol* 2001; 117: 1464–1470.
 29. Nordlund JJ, Kirkwood JM, Forget BM, Milton G, Albert DM, Lerner AB. Vitiligo in patients with metastatic melanoma: a good prognostic sign. *J Am Acad Dermatol* 1983; 9: 689–696.
 30. Bystryń JC, Rigel D, Friedman RJ, Kopf A. Prognostic significance of hypopigmentation in malignant melanoma. *Arch Dermatol* 1987; 123: 1053–1055.
 31. Gogas H, Ioannovich J, Dafni U, Stavropoulou-Giokas C, Frangia K, Tsoutsos D, et al. Prognostic significance of autoimmunity during treatment of melanoma with interferon. *N Engl J Med* 2006; 354: 709–718.
 32. Bouffard D, Barnhill RL, Mihm MC, Sober AJ. Very late metastasis (27 years) of cutaneous malignant melanoma arising in a halo giant congenital nevus. *Dermatology* 1994; 189: 162–166.
 33. Epstein WL, Sagebeil R, Spitler L, Wybran J, Reed WB, Blois MS. Halo nevi and melanoma. *JAMA* 1973; 225: 373–377.
 34. Krengel S, Hauschild A, Schafer T. Melanoma risk in congenital melanocytic naevi: a systematic review. *Br J Dermatol* 2006; 155: 1–8.