

## Successful Hair Re-growth with Multimodal Treatment of Early Cicatricial Alopecia in Discoid Lupus Erythematosus

Tatyana Hamilton<sup>1</sup>, Nina Otberg<sup>1\*</sup>, Wen-Yu Wu<sup>1,2</sup>, Magdalena Martinka<sup>1</sup> and Jerry Shapiro<sup>1</sup>

<sup>1</sup>Department of Dermatology and Skin Science, University of British Columbia, 835 West 10<sup>th</sup> Avenue, Vancouver, BC, V5Z 4E8, Canada, and <sup>2</sup>Huashan Hospital, Fudan University, Shanghai, P. R. China. \*E-mail: ninaotberg@gmx.com  
Accepted January 19, 2009.

Sir,

Cicatricial alopecias represent true trichological emergencies, as they can lead to irreversible hair loss once hair follicles are scarred. Thus, prompt diagnosis and aggressive, early multi-modal therapy are crucial to prevent disfiguring hair loss and the associated psychosocial sequelae.

Here we present a rare case of successful reversal of hair loss in discoid lupus erythematosus (DLE) scarring alopecia using early combination treatment.

### CASE REPORT

A 37-year-old man of East Indian origin was referred to our clinic for evaluation of hair loss. The patient reported that he first noticed hair loss on the vertex and right temple of the scalp 8 months before presenting at the clinic. The lesions were initially pruritic, but not painful. The patient stated that he attempted to treat the areas with his wife's topical steroid (betamethasone 0.025% cream). The patient denied any chemical or physical trauma to the area. His review of systems was negative for skin disease or other illnesses. He denied fevers, arthralgias, photosensitivity, oral ulcers or other cutaneous changes. His medical history was negative except for asthma treated with albuterol inhaler (Ventolin<sup>®</sup>) when needed.

On initial presentation physical examination revealed four erythematous to violaceous plaques with scaling and follicular hyperkeratosis, 1–3 cm in size, three located over the vertex and one located over the right temporal area. Dermoscopy was employed to visualize the status of follicular ostia and showed a decrease in the density of follicular ostia, particularly in the lesion over the vertex.

Investigations included complete blood count and differential, antinuclear antibody levels, anti-Ro, anti-La, TSH, ferritin, liver and kidney function tests and urinalysis. All results were within normal limits including a negative potassium hydroxide scalp test for fungus. A baseline ophthalmological examination was also completed.

Two 4-mm deep punch biopsies including subcutaneous fat were taken from the scalp and submitted for histopathological analysis and for immunofluorescent staining. The following results were obtained: the total number of hair follicles was found to be moderately reduced, within the range 15–32 (normal value: 40). There were approximately 4 (12.5%) vellus and vellus-like hairs noted at the epidermal level. There were 9 (28%) telogen/catagen hairs. The histological sections showed a dense superficial and deep periadnexal and perivascular lymphocytic infiltrate associated with prominent vacuolar interface alteration. Alcian blue stain showed foci of dermal mucinosis. Dyskeratotic cells were very prominent. Sebaceous glands were partially absent or noticeably shrunken. The presence of increased dermal mucinosis was helpful in differentiating lupus erythematosus from lichen planopilaris. In addition, finely granular diffuse deposits of IgG and C3 along the basement membrane zone of epidermis and follicles on direct immunofluorescence were typical of lupus erythematosus. Overall,

the histological and immunofluorescence findings were compatible with discoid lupus erythematosus (DLE).

Shortly after the initial visit the lesions progressed in size and coalesced in the vertex. They measured 7×3 cm in the vertex area and 8×2 cm on the right temple. A hair pull test was positive in the affected areas.

Four weeks before presenting to our clinic the patient was started on topical Clobetasol 0.05% twice daily in combination with topical tacrolimus (Protopic<sup>®</sup>) and intralesional triamcinolone acetonide injections 10 mg/ml. Because the lesions were progressing and the patient was very concerned about his condition he asked for the maximal treatment available.

At our clinic the patient was started on the following regimen:

- oral prednisone 40 mg once daily, tapering by 5 mg/week over 8 weeks;
- hydroxychloroquine sulphate 200 mg twice daily;
- topical clobetasol 0.05% twice daily;
- topical tacrolimus (Protopic<sup>®</sup>, Astellas Pharma US, Inc.) twice daily;
- intralesional triamcinolone acetonide injections 10 mg/ml every 4 weeks.

The patient tolerated this treatment regimen well. Four months after initiation of the therapy, approximately 80% of hair regrowth was observed in all lesions and no further progression of scalp lesions could be detected (Figs 1 and 2).

### DISCUSSION

DLE is the most common cause of primary cicatricial alopecia. This scalp condition can be quite disfiguring and can cause significant psychological distress and physical discomfort to the patient.

It can present both a diagnostic and therapeutic challenge to a clinician. Differential diagnosis of DLE includes lichen planopilaris, alopecia mucinosis, subacute folliculitis decalvans, pseudopelade of Brocq, dermatomyositis and tinea capitis.

The goal of treatment of cicatricial alopecias is to induce a remission of the disease process with arrest of signs and symptoms. Delay in diagnosis and treatment can lead to permanent destruction of pilosebaceous units and irreversible hair loss. Thus, a scalp biopsy and a careful clinicopathological evaluation are mandatory in order to make a definitive diagnosis.

A step-wise approach is traditionally used, with topical therapy in limited active disease for the first 8 weeks, followed by systemic therapy after 8 weeks if the desired response is not achieved.

Topical treatment modalities include class I and class II corticosteroids in lotion, gel or foam formulations to provide symptomatic relief. Intralesional triamcinolone

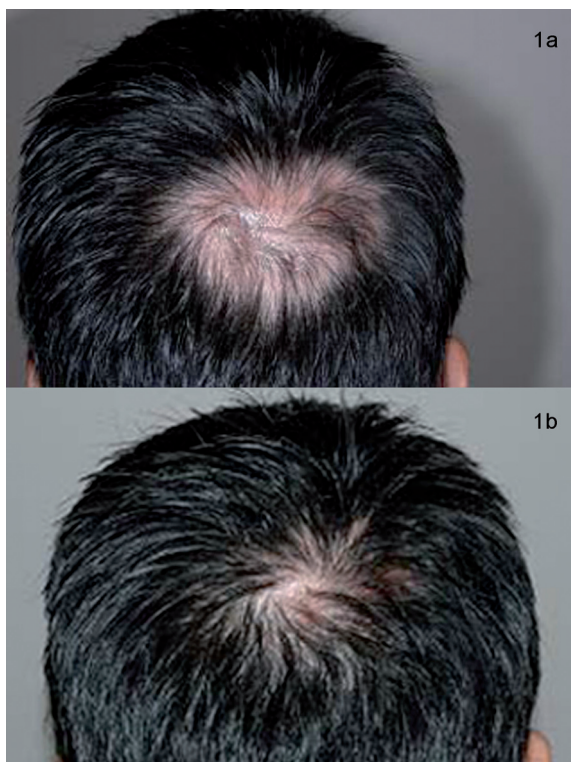


Fig. 1. (a) Vertex area before treatment. (b) After 4 months of multimodal treatment.

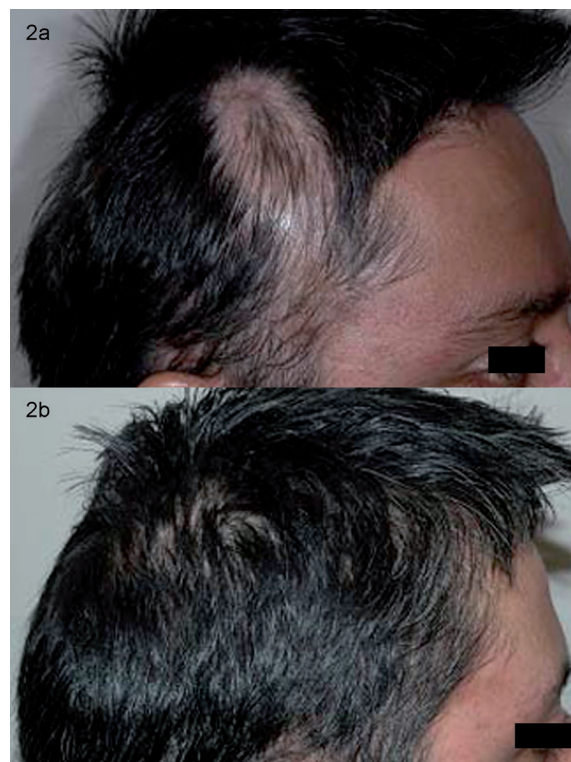


Fig. 2. (a) Temporal area before treatment. (b) After 4 months of multimodal treatment.

acetone injections, 10 mg/ml every 4–6 weeks, can be used alone or in conjunction with the topical treatments (1). Despite the lack of evidence-based data, hydroxychloroquine is considered first-line oral therapy in DLE (2). Oral prednisone is often used as a bridging therapy, starting at 0.5–1 mg/kg and tapering over 8 weeks. If symptoms and signs of the disease persist after 8 weeks of first-line therapy then a second-line systemic drug is considered. These include oral retinoids (3), mycophenolate mofetil (1), and cyclosporine (4). Other agents reported in the literature as effective treatment alternatives include topical agents tacrolimus (5), imiquimod (6), tazarotene (7), and systemic agents methotrexate (4), azathioprine (8), clofazamine (9), gold (10), dapsone (11), interferone- $\alpha$ -2 and monoclonal anti-CD4 antibodies (12).

In this case, we used an aggressive, multi-modal treatment approach employing both topical and systemic therapy, because the disease was progressing rapidly and because the patient desired the maximal treatment available. An excellent treatment response was achieved with not only arrest of symptoms and signs, but also successful hair regrowth. In our experience this is a rare example of reversal of hair loss in the treatment of DLE of the scalp.

*The authors declare no conflicts of interest.*

## REFERENCES

- Price VH. The medical treatment of cicatricial alopecia. *Semin Cutan Med Surg* 2006; 25: 56–59.
- Callen JP, Camisa C. Antimalarial agents. In: Wolverson SE, editor, *Comprehensive dermatologic drug therapy*. Philadelphia: WB Saunders; 2001, p. 251–268.
- Newton RC, Hebert AA, Freese TW, Solomon AR. Scarring alopecia. *Dermatol Clin* 1987; 5: 603–618.
- Goldstein E, Carey W. Discoid lupus erythematosus: successful treatment with oral methotrexate. *Arch Dermatol* 1994; 130: 938–939.
- Walker SL, Kirby B, Chalmers RJ. The effect of topical tacrolimus on severe recalcitrant chronic discoid lupus erythematosus. *Br J Dermatol* 2002; 147: 405–406.
- Gerdsen R, Wenzel J, Uerlich M, Bieber T, Petrow W. Successful treatment of chronic discoid lupus erythematosus of the scalp with imiquimod. *Dermatology* 2002; 205: 416–418.
- Edwards KR, Burke WA. Treatment of localized discoid lupus erythematosus with tazarotene. *J Am Acad Dermatol* 1999; 41: 1049–1050.
- Tsokos GC, Caughman SW, Klippel JH. Successful treatment of generalized discoid skin lesions with azathioprine. Its use in a patient with systemic lupus erythematosus. *Arch Dermatol* 1985; 121: 1323–1325.
- Wallace DJ. Occasional, innovative, and experimental therapies. In: Wallace DJ, Hahn BH, editors. *Dubois' lupus erythematosus* (6th edn). Philadelphia: Lippincott Williams & Wilkins; 2002, p. 1229–1241.
- Dalziel K, Going G, Cartwright PH, Marks R, Beveridge GW, Rowell NR. Treatment of chronic discoid lupus erythematosus with an oral gold compound (auranofin). *Br J Dermatol* 1986; 115: 211–216.
- Coburn PR, Shuster S. Dapsone and discoid lupus erythematosus. *Br J Dermatol* 1982; 106: 105–106.
- Prinz JC, Meurer M, Reiter C, Rieber EP, Plewig G, Riethmüller G. Treatment of severe cutaneous lupus erythematosus with a chimeric CD4 monoclonal antibody, cM-T412. *J Am Acad Dermatol* 1996; 34: 244–252.