

## CLINICAL REPORT

# Therapeutic Effectiveness of Various Treatments for Eosinophilic Pustular Folliculitis

Shoko FUKAMACHI, Kenji KABASHIMA, Kazunari SUGITA, Miwa KOBAYASHI and Yoshiki TOKURA  
Department of Dermatology, University of Occupational and Environmental Health, Kitakyushu, Japan

**Eosinophilic pustular folliculitis is a rare dermatosis. Recently, in addition to oral indomethacin, other treatments have been applied for eosinophilic pustular folliculitis. The aim of this study was to assess the effectiveness of various therapies encompassing conventional to newly applied drugs for eosinophilic pustular folliculitis. Twenty patients with eosinophilic pustular folliculitis seen in our department were investigated. The effectiveness of each treatment was assessed by a severity score index. Eleven patients were treated with oral indomethacin, and the severity scores of all patients were decreased after the treatment. Oral cyclosporine was markedly effective in all 11 patients treated, and topical tacrolimus ointment alleviated eosinophilic pustular folliculitis in 3 of 7 with one patient showing a remarkable reduction in the severity score. In addition to indomethacin or other oral non-steroidal anti-inflammatory drugs, oral cyclosporine and topical tacrolimus may be beneficial choices when patients have been resistant to previous treatments. Key words: eosinophilic pustular folliculitis; indomethacin; cyclosporine; tacrolimus.**

(Accepted August 25, 2008.)

Acta Derm Venereol 2009; 89: 155–159.

Shoko Fukamachi, Department of Dermatology, University of Occupational and Environmental Health, 1-1 Iseigaoka Yahatanishi-ku, Kitakyushu 807-8555, Japan. E-mail: fkmc-shk@med.uoeh-u.ac.jp

Eosinophilic pustular folliculitis (EPF), first reported in 1965 (1), is a rare dermatosis. It is clinically characterized by recurrent, pruritic, erythematous patches consisting of follicular papules and sterile pustules with peripheral blood eosinophilia. It affects the face, trunk and extremities, occasionally extending to the palms and soles. While some Western patients with EPF are positive for human immunodeficiency virus (HIV) and exhibit papules mainly on the trunk (2, 3), almost all Japanese patients are HIV-negative and have annularly configured lesions mostly on the face and upper back. Histopathologically, EPF shows predominant infiltration of eosinophils into hair follicles (4–6). Although the aetiology has not been fully elucidated, a Th2-mediated, interleukin (IL)-5-induced mechanism has been proposed (4–6). IL-5 is known to be a growth and differentiation factor for eosinophils

and may also be involved in the migration of eosinophils to the follicles (4, 6).

Among several treatment options for EPF, indomethacin has been used as one of the first-line treatments since 1984, when oral administration of this non-steroidal anti-inflammatory drug (NSAID) was reported to exert a therapeutic effect on EPF (7–10). Other treatments capable of improving EPF include oral and topical corticosteroids (11, 12), oral minocycline (13), roxithromycin (14) and aminodiphenyl sulfone (DDS) (15–17). More recently, systemic Th1-skewing reagent interferon- $\gamma$  (IFN- $\gamma$ ) (4, 6) and immunosuppressive agents, including oral cyclosporine (6, 18) and topical tacrolimus (5, 19), have been used for the treatment of EPF.

Over the past 10 years, we have seen 20 patients with EPF and treated them with various modalities. To evaluate further the efficacy of each therapy, we performed a retrospective study with the use of our records and photographs. We assessed changes in the intensity of skin eruption before and after treatment by using the severity score index composed of erythema, papules, pustules, pruritus, and number of involved sites.

## MATERIALS AND METHODS

### Patients

We included all patients who had been diagnosed and recorded as EPF in our hospital, and analysed them retrospectively. Twenty patients with EPF, who were seen from 1998 to 2007 in the Department of Dermatology of our University Hospital, were enrolled in this study (Table I). The patients consisted of 6 men and 14 women, mean age 38 years (age range 23–69 years). The diagnosis of EPF was made based on the clinical appearance, symptoms and histological findings (20–22). Peripheral eosinophil counts were examined in 13 patients, and 5 of them had eosinophilia ( $> 500/\mu\text{l}$ ). Skin biopsy was performed in 20 patients with the typical result of follicular infiltration of eosinophils, including one patient diagnosed as EPF by a dermatologist in another private clinic prior to referral to us. Although the eosinophil counts in cases 3 and 15 were more than  $1000/\mu\text{l}$ , they did not show any other organ symptoms seen in hyper-eosinophilic syndrome, and eosinophils infiltrated mainly around hair follicles in the biopsy specimens. This study included one HIV-positive patient (case 5).

### Assessment score

To assess the effect of each treatment, we used a “severity score index for EPF”, which we determined as follows. Based

Table I. Patients enrolled in this study

Pat. no.	Age/Sex	Eos/ $\mu$ l	Treatments							
			Systemic					Topical		
			Indomethacin	Loxoprofen	Cyclosporine	IFN- $\gamma$	DDS	Indomethacin	Tacrolimus	Combination with
1	24/F	208	PR							s-steroid
2	45/F	165	PR							MC
3	30/F	1123	PR							
4	45/M	609	PR							
5	69/M	ND	PR							t-steroid, MC
6	64/F	ND	PR							MC
7	49/F	256	PR				NR			s-steroid, MC
8	29/M	492	PR							t-steroid, MC
9	45/F	417	PR							t-steroid, RXM
10	23/F	340		PR	PR			NR	NR	s-steroid, RXM
11	24/M	ND	PR						PR	
12	26/M	667			PR	PR		PR	NR	s-steroid, RXM
13	25/F	294			CR				PR	
14	35/F	768		NR	PR				NR	t-steroid, MC, RXM
15	41/M	1555		NR	PR			NR	NR	RXM
16	31/F	235		PR				PR	CR	RXM
17	40/F	ND			PR					
18	44/F	ND								RXM
19	35/F	ND	PR							
20	43/F	ND						PR		

Eos: eosinophil counts per  $\mu$ l; s-steroid: systemic steroid; MC: oral minocycline; t-steroid: topical steroid; RXM: oral roxithromycin; DDS: dimethylidiphenyl sulfone; IFN- $\gamma$ : systemic interferon- $\gamma$ ; ND: not done; PR: partial response, defined as the severity score of post-treatment lower than that of pre-treatment; CR: complete response, defined as the severity score of post-treatment lowered to 0; NR: no response, defined as the severity score of post-treatment equal to or higher than that of pre-treatment.

on the essential features of EPF, we chose five items, three from eruption elements (erythema, papules and pustules), one from symptoms (pruritus), and the number of involved sites. We scored the former four items from 0 to 3 points (0, none; 1, mild; 2, moderate; and 3, severe). When the patient had several areas of lesions, we selected the most severe area for scoring. The number of involved sites was assessed from 0 to 4. In the patient enrolled, "4" was the highest number of the affected sites, and "0" was for patients completely improved after therapy. The final assessment was made with the sum of the above values (from 0 to 16), and we scored them before and after each treatment with revision of the records and photographs of the patients.

#### Therapies and evaluation

When a single therapy was applied, the assessment was performed before and after a given treatment. In some patients, two or more monotherapies were administered in a sequential fashion, and the efficacy of each therapy was evaluated just before and after treatment. The duration of each therapy was 1–4 weeks. In the case of combined therapies, the patients were administered with both the evaluated and non-evaluated drugs. The non-evaluated drug(s) continued without any change in dose for at least one week prior to the beginning of the evaluated drug. The duration of treatment with the evaluated drugs was 1–24 weeks, except for cases 5 and 8 who had been treated intermittently for one and 4 years, retrospectively. The evaluated drugs included oral indomethacin (25–50 mg daily for 1–8 weeks), another oral NSAID (loxoprofen, 60–120 mg daily for 1–8 weeks), topical indomethacin (1% [w/w] twice daily for 2–12 weeks), oral cyclosporine (100–150 mg daily for 2–12 weeks), and topical tacrolimus (0.1%). The non-evaluated drugs included oral corticosteroids (prednisolone 10 mg daily and betamethasone 1–2 mg daily), and topical corticosteroids (twice daily for 3–24 weeks), oral minocycline (100–200 mg daily) and oral roxithromycin (300 mg daily). We could not as-

sess the therapeutic effect of these non-evaluated drugs, because they were mostly used together with the above-evaluated drugs, including indomethacin, cyclosporine, or tacrolimus. Oral DDS (75 mg daily) and IFN- $\gamma$  ( $2 \times 10^6$  Japanese reference unit [JRU] daily) were used for a single patient.

## RESULTS

The changes in the severity score before and after treatments are shown in Fig. 1, and the number and percentage of patients showing complete or partial responses are summarized in Table II. The follow-up period was from one to 8 months.

Eleven patients were treated with oral indomethacin. Among them 4 patients received indomethacin monotherapy and the rest were given indomethacin in combination with other drugs (Table I). Indomethacin improved the skin lesions of all 11 patients, as the

Table II. Therapeutic effectiveness of each drug for eosinophilic pustular folliculitis

Drug	Patients successfully treated <sup>a</sup> n (%)
Systemic administration	
Indomethacin	11/11 (100)
Loxoprofen	2/4 (50)
Cyclosporine	6/6 (100)
Topical application	
Indomethacin	3/5 (60)
Tacrolimus	3/7 (43)

<sup>a</sup>Number of patients showing complete or partial response.

mean score was remarkably reduced from 10.2 to 3.7 (Fig. 1A). Four patients were treated with another oral NSAID, loxoprofen sodium. The mean severity score was changed from 8.5 to 6.0, without statistical significance ( $p=0.11$ ), but it is notable that 2 of 4 patients were improved by this treatment (Fig. 1B). Oral cyclosporine was greatly effective in all 6 patients treated, as the mean severity score was reduced from 8.3 to 3.3 (Fig. 1C). Topical indomethacin did not statistically alter the severity score (Fig. 1D). Seven patients were treated with topical tacrolimus. In one patient (case 16) among them, whose biopsied skin specimen from the face showed a dense infiltrate of eosinophils around hair follicles and sebaceous glands, confirming the diagnosis of EPF (Fig. 2C), the eruption disappeared completely with topical tacrolimus treatment (Fig. 2 A, B), and in the other 2 patients (cases 11 and 13), their severity scores were reduced by this drug. However, the overall scores in all 7 patients were not significantly decreased (Fig. 1E). IFN- $\gamma$  and DDS were used in a single patient, respectively, and each patient showed a partial response or no response; the severity score indices were changed from 15 to 7 and from 3 to 3, respectively.

## DISCUSSION

Oral indomethacin is a conventional treatment for EPF (9). The present study further confirmed its effectiveness, since the severity scores were reduced in all 11 patients. Four patients responded well to indomethacin alone and the rest did so in combination with other drugs. However, it should be noted that some of the 9 patients who were not treated with oral indo-

methacin in this study had already received this drug in other clinics without a good therapeutic response. This exclusion of potential low responders from this study might yield a biased result in its effectiveness. Another oral NSAID, loxoprofen, was also effective in 2 of 4 patients, but the overall efficacy seemed to be limited. Although the mechanism underlying NSAID efficacy remains unclear, it has been proposed that this inhibitor of cyclooxygenase reduces a certain factor that attracts eosinophils into the hair follicles (23), and indomethacin decreases the expression of major eosinophil chemokine receptor CCR3 on eosinophils (24). In addition, the action of NSAIDs depends on the activity of cellular kinases, but the dependency differs among NSAIDs. For example, indomethacin is capable of acting peroxisome proliferator-activating receptor  $\gamma$  (PPAR $\gamma$ ), whereas other NSAIDs are incapable (25). It might influence the differential effectiveness for EPF between indomethacin and other NSAIDs. Topical indomethacin partially improved EPF in 3 out of 5 patients, but the overall severity score was not statistically decreased. Moreover, 2 out of 3 patients improved with topical indomethacin were treated with roxithromycin or systemic steroid in combination, further suggesting its partial contribution to the therapeutic effect.

Cyclosporine is a potent generalized suppressor of cytokine production by T lymphocytes, and a couple of reports documented successful treatment of EPF with systemic cyclosporine (6, 18). Our study demonstrated that cyclosporine is a powerful drug for EPF in patients refractory to other treatments. Since the doses used in this study were low (100–150 mg daily, corresponding to 1.7–3.0 mg/kg/day), cyclosporine is considered to

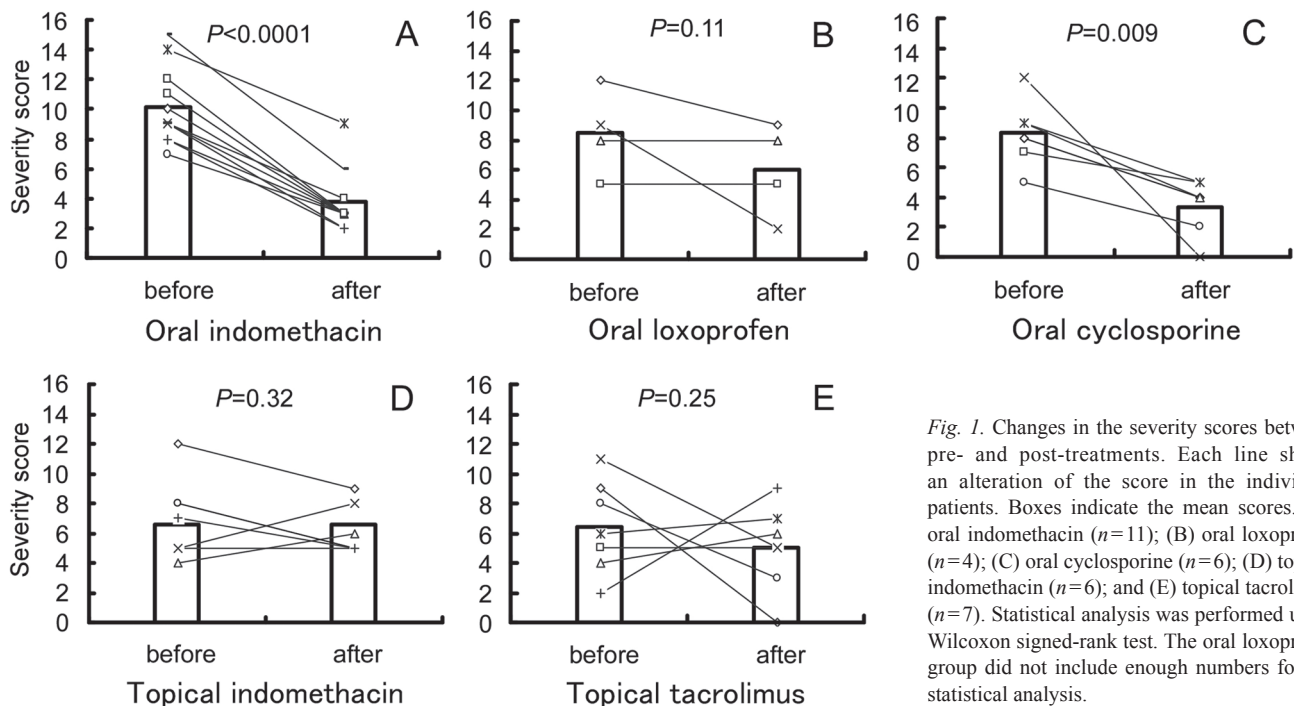


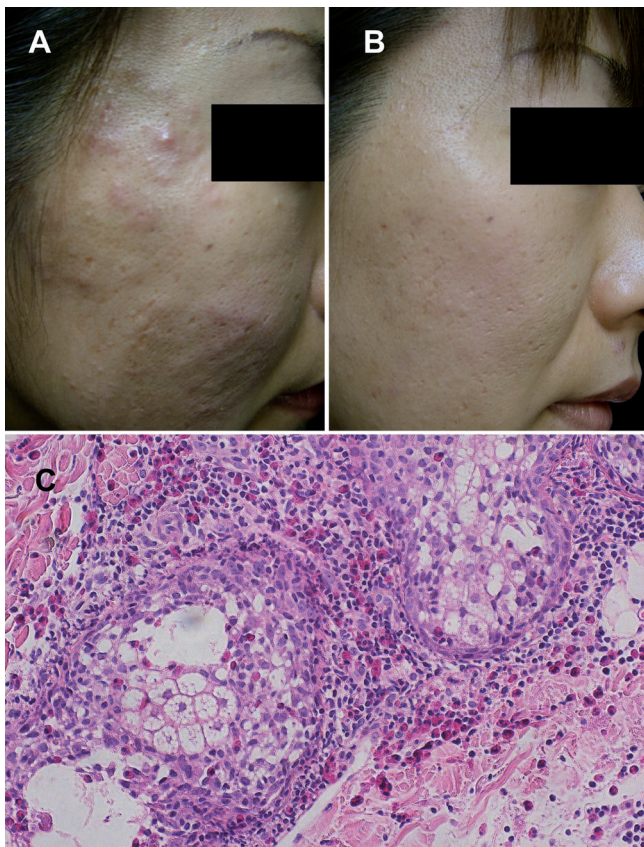
Fig. 1. Changes in the severity scores between pre- and post-treatments. Each line shows an alteration of the score in the individual patients. Boxes indicate the mean scores. (A) oral indomethacin ( $n=11$ ); (B) oral loxoprofen ( $n=4$ ); (C) oral cyclosporine ( $n=6$ ); (D) topical indomethacin ( $n=6$ ); and (E) topical tacrolimus ( $n=7$ ). Statistical analysis was performed using Wilcoxon signed-rank test. The oral loxoprofen group did not include enough numbers for the statistical analysis.



exert a clinical efficacy without side-effects in most patients. Another immunosuppressive calcineurin inhibitor, tacrolimus, has been established as an alternative to topical corticosteroids for inflammatory skin diseases (26), such as atopic eczema. Tacrolimus inhibits T-cell activation and resultant release of both Th1 and Th2 cytokines (27, 28), including IL-2, IL-4, and IL-5. There have been several reports of successful treatment with topical tacrolimus for EPF (5, 29, 30). Our study suggests that topical tacrolimus has a therapeutic effect in limited patients; it occasionally exerts a positive effect, presumably when the patient's skin condition allows the drug to penetrate. It is also notable that this study included only two cases that show complete responses to the calcineurin inhibitors, one treated with oral cyclosporine and the other with topical tacrolimus. This may provide not only a good therapeutic indication of

these immunosuppressants but also an important clue for elucidation of the mechanism of EPF.

EPF is an uncommon disease with prominent symptoms and often refractory to treatments. Lack of comprehensive reports on therapies for EPF may have yielded some confusion on the therapeutic approaches. The number of patients enrolled here is limited and the study is retrospective. However, we found that the severity score index is a useful means of assessment of EPF therapies. By using this score, it is suggested that oral cyclosporine is highly effective as well as oral indomethacin. It is recommended that oral indomethacin serves as the first choice for treatment of EPF. When it is ineffective or unavailable because of its side-effects, oral cyclosporine is a candidate for second-line treatment. Topical indomethacin and tacrolimus can be used in combination with the systemic drugs. Further assessment of combination therapy is required in future studies.



**Fig. 2.** A patient showing remarkable improvement with topical tacrolimus treatment. Clinical pictures (A) pre-treatment (severity score: 12) and (B) post-treatment (severity score: 0). The patient was a 31-year-old woman who presented with 4-month history of an annular eruption on her face and multiple red and brownish plaques accompanied with papules and pustules on her trunk and extremities. She was initially treated with oral loxoprofen sodium 120 mg daily, oral roxithromycin 300 mg and topical indomethacin twice a day. Two weeks later, the redness became mild and pustules disappeared, but the eruption and pruritus remained at level 9 of the severity score. Topical tacrolimus twice a day was added to her regime for another 24 weeks. All plaques and pruritus disappeared completely (severity score: 0). (C) A biopsied skin specimen from the face (H&E stain  $\times 200$ ), showing a dense infiltrate of eosinophils around hair follicles and sebaceous glands.

## REFERENCES

- Ise S, Ofuji S. Subcorneal pustular dermatosis. A follicular variant? *Arch Dermatol* 1965; 92: 169–171.
- Rosenthal D, LeBoit PE, Klumpp L, Berger TG. Human immunodeficiency virus-associated eosinophilic folliculitis. A unique dermatosis associated with advanced human immunodeficiency virus infection. *Arch Dermatol* 1991; 127: 206–209.
- Soeprono FF, Schinella RA. Eosinophilic pustular folliculitis in patients with acquired immunodeficiency syndrome. Report of three cases. *J Am Acad Dermatol* 1986; 14: 1020–1022.
- Fushimi M, Tokura Y, Sachi Y, Hashizume H, Sudo H, Wakita H, et al. Eosinophilic pustular folliculitis effectively treated with recombinant interferon-gamma: suppression of mRNA expression of interleukin 5 in peripheral blood mononuclear cells. *Br J Dermatol* 1996; 134: 766–772.
- Kabashima K, Sakurai T, Miyachi Y. Treatment of eosinophilic pustular folliculitis (Ofuji's disease) with tacrolimus ointment. *Br J Dermatol* 2004; 151: 949–950.
- Sugita K, Kabashima K, Koga C, Tokura Y. Eosinophilic pustular folliculitis successfully treated with sequential therapy of interferon-gamma and ciclosporin. *Clin Exp Dermatol* 2006; 31: 709–710.
- Hosokawa H, Asada Y. A case of eosinophilic pustular folliculitis successfully treated with indomethacin. *Hifu* 1984; 26: 560–562.
- Rattana Apiromyakij N, Kullavanijaya P. Eosinophilic pustular folliculitis: report of seven cases in Thailand. *J Dermatol* 2000; 27: 195–203.
- Ota T, Hata Y, Tanikawa A, Amagai M, Tanaka M, Nishikawa T. Eosinophilic pustular folliculitis (Ofuji's disease): indomethacin as a first choice of treatment. *Clin Exp Dermatol* 2001; 26: 179–181.
- Ishiguro N, Shishido E, Okamoto R, Igarashi Y, Yamada M, Kawashima M. Ofuji's disease: a report on 20 patients with clinical and histopathologic analysis. *J Am Acad Dermatol* 2002; 46: 827–833.
- De Dulanto F, Armijo Moreno M, Diaz Flores L, Camacho F, Ocana J, Sanchez Muros J, et al. [Eosinophilic pustular folliculitis (Ofuji syndrome)] *Med Cutan Ibero Lat Am* 1977; 5: 323–329.
- Kostler E, Gossrau G, Kuster P, Bergner V, Seebacher C.

- Steril eosinophile Pustulose (Ofuji). Eine in Europa seltene Entität. *Hautarzt* 1995; 46: 643–646.
13. Tanigaki T, Kanda R. Two cases of eosinophilic pustular folliculitis treated with minocycline chloride. *Nishinihon J Dermatol* 1984; 59: 558–561.
  14. Kobayashi M, Shimauchi T, Hino R, Tokura Y. Roxithromycin downmodulates Th2 chemokine production by keratinocytes and chemokine receptor expression on Th2 cells: its dual inhibitory effects on the ligands and the receptors. *Cell Immunol* 2004; 228: 27–33.
  15. Takematsu H, Nakamura K, Igarashi M, Tagami H. Eosinophilic pustular folliculitis. Report of two cases with a review of the Japanese literature. *Arch Dermatol* 1985; 121: 917–920.
  16. Steffen C. Eosinophilic pustular folliculitis (Ofuji's disease) with response to dapsone therapy. *Arch Dermatol* 1985; 121: 921–923.
  17. Malanin G, Helander I. Eosinophilic pustular folliculitis (Ofuji's disease): response to dapsone but not to isotretinoin therapy. *J Am Acad Dermatol* 1989; 20: 1121.
  18. Taniguchi S, Tsuruta D, Hamada T. Eosinophilic pustular folliculitis responding to cyclosporin. *Br J Dermatol* 1994; 131: 736–738.
  19. Dale S, Shaw J. Clinical picture. Eosinophilic pustular folliculitis. *Lancet* 2000; 356: 1235.
  20. Ofuji S, Ogino A, Horio T, Oseko T, Uehara M. Eosinophilic pustular folliculitis. *Acta Derm Venereol* 1970; 50: 195–203.
  21. McCalmont TH, Altemus D, Maurer T, Berger TG. Eosinophilic folliculitis. The histologic spectrum. *Am J Dermatopathol* 1995; 17: 439–446.
  22. Fearfield LA, Rowe A, Francis N, Bunker CB, Staughton RC. Itchy folliculitis and human immunodeficiency virus infection: clinicopathological and immunological features, pathogenesis and treatment. *Br J Dermatol* 1999; 141: 3–11.
  23. Takematsu H, Tagami H. Eosinophilic pustular folliculitis. Studies on possible chemotactic factors involved in the formation of pustules. *Br J Dermatol* 1986; 114: 209–215.
  24. Stubbs VE, Schratl P, Hartnell A, Williams TJ, Peskar BA, Heinemann A, et al. Indomethacin causes prostaglandin D(2)-like and eotaxin-like selective responses in eosinophils and basophils. *J Biol Chem* 2002; 277: 26012–26020.
  25. Tegeder I, Pfeilschifter J, Geisslinger G. Cyclooxygenase-independent actions of cyclooxygenase inhibitors. *FASEB J* 2001; 15: 2057–2072.
  26. Rallis E, Korfitis C, Gregoriou S, Rigopoulos D. Assigning new roles to topical tacrolimus. *Expert Opin Investig Drugs* 2007; 16: 1267–1276.
  27. Woo DK, James WD. Topical tacrolimus: a review of its uses in dermatology. *Dermatitis* 2005; 16: 6–21.
  28. Zabawski EJ, Costner M, Cohen JB, Cockerell CJ. Tacrolimus: pharmacology and therapeutic uses in dermatology. *Int J Dermatol* 2000; 39: 721–727.
  29. Kawaguchi M, Mitsuhashi Y, Kondo S. Successful treatment of eosinophilic pustular folliculitis with topical tacrolimus. *Int J Dermatol* 2004; 43: 608–610.
  30. Hara D, Kuroda K, Mieno H, Tajima S. Treatment of eosinophilic pustular folliculitis with tacrolimus ointment. *J Am Acad Dermatol* 2004; 51: S143–S145.