

Lymphangioma Circumscriptum of the Vulva: A Case Report

Müzeyyen Gönül¹, Seray Külcü Çakmak¹, Seçil Soylu¹, Arzu Kılıç¹, Hülya Gündüz¹, Ülker Gül¹ and Tuba Ünal²

¹2nd Dermatology Clinic and ²2nd Pathology Clinic, Ankara Numune Education and Research Hospital 44 Yenimahalle, Ankara, Turkey. E-mail:

muzezyengonul@yahoo.com

Accepted August 21, 2008.

Sir,

Lymphangioma circumscriptum (LC) is a rare benign disorder of lymphatic channels in deep dermal and subcutaneous layers. LC can occur either as a congenital abnormality or as acquired damage to previously normal lymphatic channels. LC of the vulva is very rare (1–6). We present here a case of congenital vulvar LC.

CASE REPORT

A 65-year-old woman attended our clinic with oedema and oozing vesicles on the vulva and mons pubis. The lesions had developed when the patient was 6 years old. She had a knee prosthesis and platinum plate in her femur due to previous surgery for trauma. She had had a hysterectomy and salpingo-oophorectomy for excessive vaginal haemorrhage following an abortion 30 years previously and had had diabetes mellitus for 4 years. She had no other organ complaints. Dermatological examination revealed oedema and multiple, grouped, oozing vesicles on the mons pubis and right labium majus (Fig. 1). Routine laboratory tests were normal except for the glucose level. A biopsy specimen was obtained from the lesions and histopathological examination revealed epidermal orthokeratosis and acanthosis, numerous dilated lymphatics and angiomatous spaces

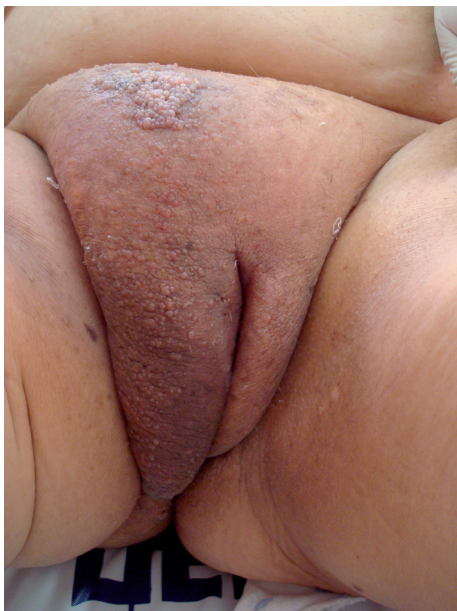

Fig. 1. Oedema and multiple, grouped, vesicles on the mons pubis and right labium majus.

with proliferation of capillaries (Fig. 2). The diagnosis of LC was confirmed. Pelvic magnetic resonance imaging could not be performed because of the platinum plate in the femur. The patient was referred to the gynaecology department for surgical therapy. However, she did not agree to surgery, because she hoped that her disease could be improved by topical or systemic drugs. Thus, the patient could not be followed up.

DISCUSSION

LC is characterized by the appearance of persistent clusters of thin-walled vessels, usually filled with clear, colourless fluid over a thickened area of subcutaneous tissue on the skin (3, 5–7). Although various classifications of LC have been proposed, the most accepted one is the division into classic and localized forms. In the classic form, the lesions are extensive and are concentrated over proximal body parts, adjacent to limb girdles. The lesions are often present at birth or appear early in life (<30 years). The localized form occurs less frequently and appears as small, discrete lesions (<1 cm²) that have no predilection for any site. The lesions may appear at any age (4, 5). Our case was the classic form.

LC involving the vulva is very rare; only 33 cases of vulvar LC have been reported. In 12 of these LC was congenital and in 21 acquired. The most common predisposing condition for acquired LC of the vulva was radical surgery and/or radiotherapy (12 cases). The other factors were genital tuberculosis (3 cases), Crohn's disease (3 cases), acute cellulitis (one case), varicose veins in both

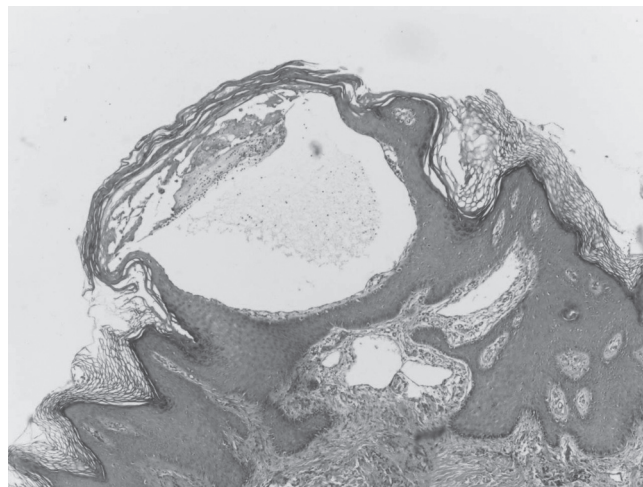


Fig. 2. Dilated lymphatics in superficial dermis (H&E x40).

legs (one case) and rhabdomyosarcoma (one case) (1, 4, 8). Our case was congenital vulvar LC.

Vulvar LC needs to be differentiated from various dermatological disorders for which treatment methods are different, such as genital warts, herpes zoster, molluscum contagiosum and leiomyoma. Biopsy of the lesions provides the diagnosis. LC may cause some complications, including clear exudate, swelling of the vulva, pain, recurrent cellulitis, and psychosexual dysfunction (1, 2).

The aetiological factors for LC are not clear. Lymphangiogenic growth factors, vascular endothelial growth factor-C (VEGF-C) and VEGF-D and their receptors on lymphatic endothelial cells, VEGF-3, may play a role in mechanisms controlling the development of LC (4).

There is no standard therapy for the management of LC. The most common procedures are abrasive therapy, sclerotherapy, electrocoagulation and surgical resection. Even with best treatment option, recurrence is common (4, 8). A case of acquired LC successfully treated with lymphaticovenular anastomosis has been reported (8). Our patient was referred to the gynaecology department for surgical resection, but she rejected any invasive therapy.

REFERENCES

1. Vlastos AT, Malpica A, Follen M. Lymphangioma circumscriptum of the vulva: a review of the literature. *Obstet Gynecol* 2003; 101: 946–954.
2. Gómez JIE, Miranda-Romero A, Vallés CC, Pozo CB, Sambucety PS, Fernández MM, et al. Lymphangioma circumscriptum of the vulva. *Cutis* 2001; 67: 229–232.
3. Jappe U, Zimmerman T, Kahle B, Petzoldt D. Lymphangioma circumscriptum of the vulva following surgical and radiological therapy of cervical cancer. *Sexual Trans Dis* 2002; 29: 533–535.
4. Roy KK, Agarwal S, Kumar S, Malhotra N, Gopendru. Recurrent vulvar lymphangioma circumscriptum – a case report and literature review. *Int J Gynecol Cancer* 2006; 16: 930–934.
5. Johnson TL, Kennedy AW, Segal GH. Lymphangioma circumscriptum of the vulva. *J Repr Med* 1991; 36: 808–812.
6. Murugan S, Srinivasan G, Kaleelullah MCA, Rajkumar L. A case report of lymphangioma circumscriptum of the vulva. *Genitourin Med* 1992; 68: 331
7. Buckley DA, Barnes L. Vulvar lymphangiectasia due to recurrent cellulitis. *Clin Exp Dermatol* 1996; 21: 215–216.
8. Motegi S, Tamura A, Okada E, Nagai Y, Ishikawa O. Successful treatment with lymphaticovenular anastomosis for secondary skin lesions of chronic lymphedema. *Dermatology* 2007; 215: 147–151.