

Sudden Eruption of Pigmentary Spots on Vitiligo Universalis Patient: Possible Misdiagnosis

Eun Chun Han, Kyu-yeop Lee, Jung-U Shin, Yoon Kee Park and Mi Ryung Roh*

*Dermatology and Cutaneous Biology Research Institute, Yonsei University College of Medicine, 134 Shinchon-Dong, Seodaemun-Gu, Seoul, South Korea. *E-mail: karenroh@yuhs.ac*

Accepted August 25, 2008.

Sir,

Vitiligo is a disease caused by loss of melanocytes. It can be classified as segmental, acrofacial, generalized and universal, or by pattern of involvement, such as focal, mixed, and mucosal types. In generalized and universal vitiligo, the entire body surface may be depigmented, leaving only a few normally pigmented macules and patches in some areas (1). Therefore it is sometimes difficult to diagnose generalized vitiligo if the patient does not show any normally pigmented macules. We report here a rare case of repigmentation after strong sun exposure in a patient diagnosed with vitiligo universalis.

CASE REPORT

A 63-year-old man, known to have generalized vitiligo of 40 years' duration, presented with newly developed multiple brown to black macules on both the periorbital areas and cheeks (Fig. 1a). Pigmentary lesions had developed after exposure to strong sun 3 months previously. He had not received any treatment, such as phototherapy, systemic or topical steroids and immunosuppressants, for over 30 years. Initially, pigmentary disease was suspected, with the differential diagnosis including freckles, lentigines and melasma. A skin biopsy performed on the cheek showed increased basal melanin pigmentation (Fig. 2). In combination with the histopathological results and medical history, the hyperpigmented lesions were diagnosed as the patient's

normal skin with increased melanin deposition in the basal layer due to activation of residual melanocytes. Since the patient did not want to treat the vitiligo lesion himself, we treated the hyperpigmented lesion with a Nd:YAG (532 nm) laser. The hyperpigmented lesions cleared after two treatments with the laser (Fig. 1b).

DISCUSSION

Although several theories have been proposed to explain the loss of functioning melanocytes in vitiligo, the precise cause remains unknown. Theories include the presence of autoantibodies against various tissues, cytotoxic T cells, oxidative stress, neural and viral mechanisms (2). Most of the published studies report the complete absence of melanocytes in depigmented vitiliginous skin, suggesting that only hair follicles act as a reservoir. However, several reports suggest that vitiligo lesions are not totally devoid of melanocytes (3–5). A study by Tobin et al. (5) provides evidence that melanocytes are never completely absent in the depigmented epidermis and that these melanocytes can recover their functionality under an appropriate stimulus. It is possible that sun exposure was responsible for initiating melanocyte activity in the depigmented skin of our patient.

In patients with extensive vitiligo, depigmentation therapy is often preferred over attempts to restore skin colour. Monobenzone or monobenzyl ether of hydroquinone is used routinely for depigmentation of normally

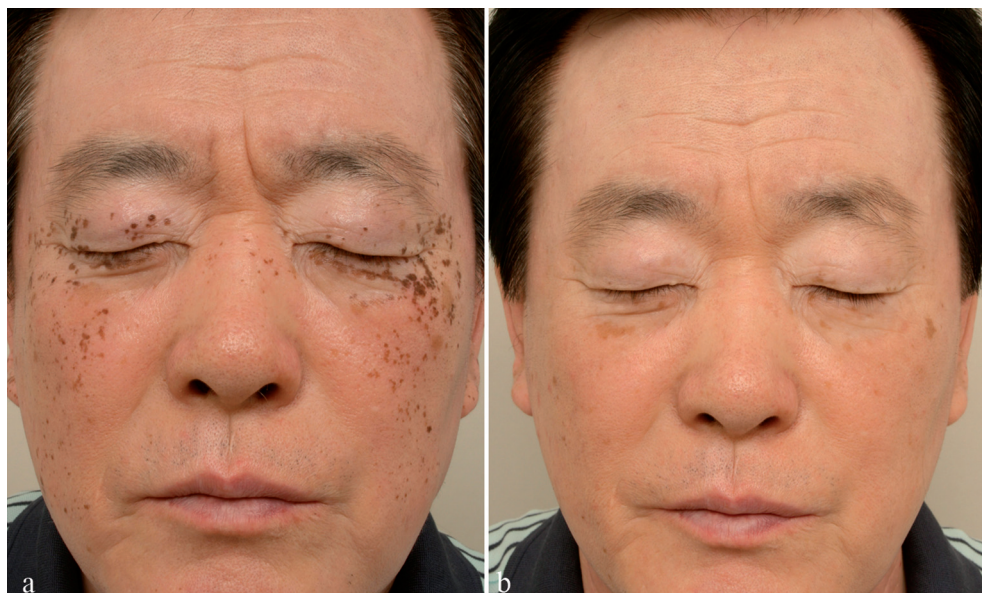

Fig. 1. (a) Multiple brown to black macules on periorbital areas and cheeks. (b) Complete depigmentation after 2 sessions of Nd:YAG (532 nm) laser treatment.

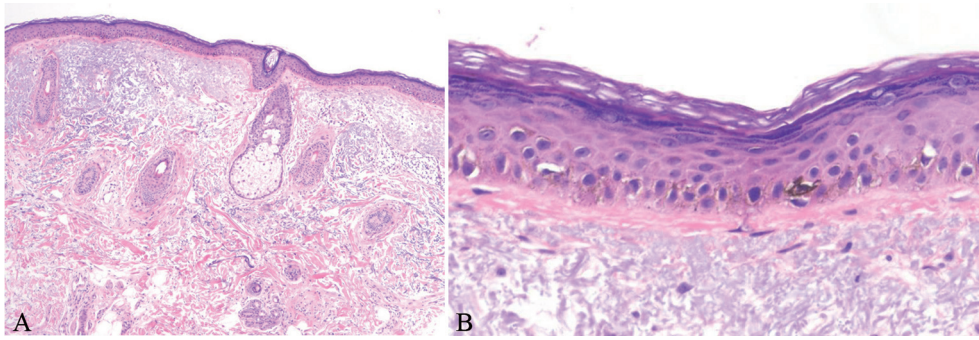


Fig. 2. A skin biopsy, performed on the cheek, showed increased basal melanin pigmentation and solar elastosis (haematoxylin and eosin (H&E : a $\times 40$; b $\times 100$).

pigmented macule and patches in patients with universal vitiligo (6). Q-switched ruby laser (694 nm), alexandrite laser (755 nm) and cryotherapy are shown to be highly effective in selectively targeting melanocytes for destruction, thus causing depigmentation (7–9). In our case, Nd:YAG (532 nm) laser was effective in removing repigmented lesion in patients with universal vitiligo. Pigmentary spots appearing in a patient with vitiligo universalis may be misdiagnosed as pigmentary disease rather than vitiligo. To avoid misdiagnosis, physicians must evaluate the hyperpigmented macule with care.

REFERENCES

1. Cho YH, Lee SJ, Lee HJ, Hann SK, Lee MG, Park YK. The possibility of misdiagnosis of generalized vitiligo as pigmentary disease. *J Eur Acad Dermatol Venereol* 2006; 20: 1364–1366.
2. Halder RM, Taliaferro SJ. Vitiligo. In: Wolff K, Goldsmith LA, Katz SI, Gilchrest BA, Paller AS, Leffell DJ, editors, *Fitzpatrick's dermatology in general medicine*, 7th edn. New York: McGraw-Hill, 2008: p. 616–622.
3. Husain I, Vijayan E, Ramaiah A, Pasricha JS, Madan NC. Demonstration of tyrosinase in the vitiligo skin of human beings by a sensitive fluorometric method as well as by $^{14}\text{C}(\text{U})\text{-L-tyrosine}$ incorporation into melanin. *J Invest Dermatol* 1982; 78: 243–252.
4. Bartosik J, Wulf HC, Kobayasi T. Melanin and melanosome complexes in long standing stable vitiligo – an ultrastructural study. *Eur J Dermatol* 1998; 8: 95–97.
5. Tobin DJ, Swanson NN, Pittelkow MR, Peters EM, Schallreuter KU. Melanocytes are not absent in lesional skin of long duration vitiligo. *J Pathol* 2000; 191: 407–416.
6. Mosger DB, Parrish JA, Fitzpatrick TB. Monobenzylether of hydroquinone: a retrospective study of treatment of 18 vitiligo and a review of the literature. *Br J Dermatol* 1977; 97: 669–679.
7. Kim YJ, Chung BS, Choi KC. Depigmentation therapy with Q-switched ruby laser after tanning in vitiligo universalis. *Dermatol Surg* 2001; 27: 969–970.
8. Rao J, Fitzpatrick RE. Use of the Q-switched 755-nm alexandrite laser to treat recalcitrant pigment after depigmentation therapy for vitiligo. *Dermatol Surg* 2004; 30: 1043–1045.
9. Radmanesh M. Depigmentation of the normally pigmented patches in universal vitiligo patients by cryotherapy. *J Eur Acad Dermatol Venereol* 2000; 14: 149–152.