

Eosinophilic Pustular Folliculitis Occurring after Bone Marrow Transplantation in a Child with Aplastic Anaemia

Eisaku Ogawa¹, Ryuhei Okuyama^{1*}, Hidetaka Niizuma², Hachiro Tagami¹, Shigeru Tsuchiya² and Setsuya Aiba¹

Departments of ¹Dermatology and ²Pediatrics, Tohoku University Graduate School of Medicine, 1-1 Seiryō-machi, Aoba-ku, Sendai 980-8574, Japan.

*E-mail: rokuyama@mail.tains.tohoku.ac.jp

Accepted September 11, 2008.

Sir,

Eosinophilic pustular folliculitis (EPF), first described by Ofuji, is characterized by the development of pruritic follicular papules and pustules, mainly on the face, trunk and upper arms (1). It is classified into three subtypes: classical, paediatric and HIV-associated EPF (2). In addition, there have been several reported cases of an association between EPF and haematological diseases (3–6). We describe here the development of EPF in a child with aplastic anaemia after bone marrow transplantation (BMT).

CASE REPORT

A 12-year-old Japanese girl with aplastic anaemia underwent BMT from a major histocompatibility complex (MHC) matching donor in April 2007, and was treated with oral tacrolimus, antibiotics, acyclovir and antifungal agent. Six weeks after the BMT, she presented with development of pruritic red eruptions on her forehead and cheek. Physical examination showed erythematous follicular papules, some of which were topped with pustules (Fig. 1). A blood analysis gave the following results: haemoglobin 11.4 g/dl; white blood cell count 9200 /mm³ (neutrophils 12%, lymphocytes 64%, monocytes 8%, eosinophils 11% and basophils 2%); and platelets 151,000 /mm³. Biochemical and immunological studies showed aspartate aminotransferase 49 IU/l; alanine aminotransferase 50 IU/l; lactic dehydrogenase 448 IU/l; and mildly elevated C-reactive protein 0.4 mg/dl (normal range 0–0.2 mg/dl). Tests for HIV and human T-cell leukaemia virus were negative. The patient had a history of atopic dermatitis. At first, under a diagnosis of folliculitis, she was treated with gentamicin ointment for one week, which failed to improve her skin eruptions. Skin biopsies showed an intense dermal infiltration of eosinophils, neutrophils and lymphocytes around the blood vessels, hair follicles and eccrine ducts, extending to the epidermis (Fig. 2a, b). Bacterial cultures from the content of pustules isolated only a small number of colonies of *Staphylococcus epidermidis* on several occasions. Thus, suspecting EPF, we treated her with oral indomethacin 50 mg/day and topical treatment with clobetasone butylate, and her lesions gradually resolved after 2 weeks. During this period the patient's systemic conditions remained good, requiring no intensive therapies for aplastic anaemia. She took only histamine H1-blockers orally

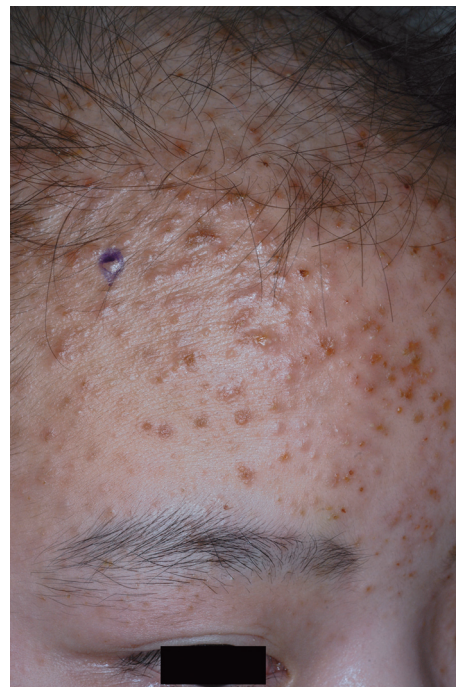

Fig. 1. Clinical finding of follicular reddish papules with occasional pustules on the forehead.

for atopic dermatitis. A follow-up examination one year later demonstrated occasional recurrence of the skin lesions.

DISCUSSION

To our knowledge, our patient is the first case of EPF associated with aplastic anaemia. EPF occasionally occurs in patients with haematological diseases. There have been 11 reported cases of EPF associated with HIV-negative haematological diseases (3–7). Among them, 8 patients developed EPF after BMT or peripheral blood stem cell transplantation. In all of them, EPF developed even when the haematological diseases were in remission, as in our patient. EPF may occur in conjunction with the transplantation rather than due to specific underlying haematological diseases. The aetiology of EPF is still unknown, but it is occasionally associated with HIV infection (8), suggesting that immunological aberrations might play a role in the development of EPF. Peripheral blood cells in EPF patients expressed increased level of interleukin-5 (IL-5), a cytokine that stimulates eosinophils, which was normalized after the

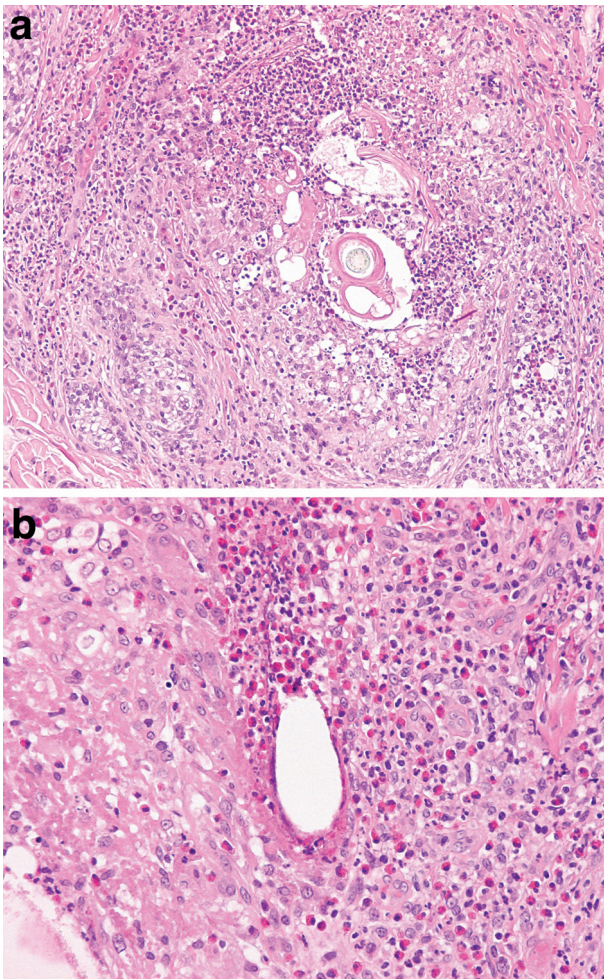


Fig. 2. Histopathological finding of infiltration of lymphocytes, neutrophils and eosinophils within and around the hair follicles (haematoxylin and eosin (H&E) stain: (a) $\times 100$; (b) $\times 400$).

disease was controlled (9). The pathogenesis is probably related to predominance of type 2 T-helper (Th2) cells, which produce IL-5. In addition, the involvement of Th2 cytokines is consistent with the fact that the paediatric subtype of EPF is occasionally associated with an atopy history (10).

In general, the prognosis of EPF is favourable when it occurs after blood transplantation. Several cases were

successfully treated with oral indomethacin or topical corticosteroids, but many cases were treated with oral corticosteroids. In our present case, EPF was successfully treated with systemic indomethacin and topical corticosteroids, although there were occasional recurrences. If we hesitate to use systemic therapy, such as oral corticosteroids or indomethacin, we can try topical tacrolimus, because it may also be beneficial due to its potent leuko-suppressive effects.

The authors declare no conflict of interest.

REFERENCES

1. Ise S, Ofuji S. Subcorneal pustular dermatosis; a follicular variant? *Arch Dermatol* 1965; 92: 169–171.
2. Moritz DL, Elmets CA. Eosinophilic pustular folliculitis. *J Am Acad Dermatol* 1991; 24: 903–907.
3. Bull RH, Harland CA, Fallowfield ME, Mortimer PS. Eosinophilic folliculitis: a self-limiting illness in patients being treated for haematological malignancy. *Br J Dermatol* 1993; 129: 178–182.
4. Evans TR, Mansi JL, Bull R, Fallowfield ME, Bevan DH, Harmer CL, Dalgleish AG. Eosinophilic folliculitis occurring after bone marrow autograft in a patient with non-Hodgkin's lymphoma. *Cancer* 1994; 73: 2512–2514.
5. Keida T, Hayashi N, Kawashima M. Eosinophilic pustular folliculitis following autologous peripheral blood stem-cell transplantation. *J Dermatol* 2004; 31: 21–26.
6. Patrizi A, Chiericato C, Visani G, Morrone P, Patrone P. Leukaemia-associated eosinophilic folliculitis (Ofuji's disease). *J Eur Acad Dermatol Venereol* 2004; 18: 596–598.
7. Patrizi A, Di Lernia V, Neri I, Gherlinzoni F. Eosinophilic pustular folliculitis (Ofuji's disease) and non-Hodgkin lymphoma. *Acta Derm Venereol* 1992; 72: 146–147.
8. Rosenthal D, LeBoit PE, Klumpp L, Berger TG. Human immunodeficiency virus-associated eosinophilic folliculitis. A unique dermatosis associated with advanced human immunodeficiency virus infection. *Arch Dermatol* 1991; 127: 206–209.
9. Fushimi M, Tokura Y, Sachi Y, Hashizume H, Sudo H, Wakita H, et al. Eosinophilic pustular folliculitis effectively treated with recombinant interferon-gamma: suppression of mRNA expression of interleukin 5 in peripheral blood mononuclear cells. *Br J Dermatol* 1996; 134: 766–772.
10. Boone M, Dangoisse C, Andre J, Sass U, Song M, Ledoux M. Eosinophilic pustular folliculitis in three atopic children with hypersensitivity to *Dermatophagoides pteronyssinus*. *Dermatology* 1995; 190: 164–168.