

From the Department of Operative Dentistry, of The Copenhagen Dental School. (Head: Professor J. J. HOLST, Dr. med. dent.)

Perimylolysis.

A Contribution Towards The Genesis Of Tooth Wasting From Non-Mechanical Causes.

By

J. J. HOLST and FINN LANGE.

616.314.13.

Both the ordinary text-books on dental pathology and monographs on the pathology of the hard dental tissues deal with the destruction of enamel and dentine caused by the action on the surfaces of the teeth of decalcifying substances. This destruction is caused either by weak acids being introduced into the cavity of the mouth through the food which may contain large quantities of weak organic acids, for instance fruit acid, or by the constant use of intensively sour dentifrices, or finally by the action of strong inorganic acids, where these are present in the atmosphere, and consequently also in the air breathed, in the shape of vapour or as finely divided little drops. It is of course only in certain trades, where such strong inorganic acids are constantly and extensively used that the last mentioned influence will operate.

Great uncertainty prevails both with regard to the classification within the systematic dental pathology of these forms of tooth wasting and with regard to the terminology employed. MILLER used the term "erosion" to designate the process of tooth wasting from chemical causes. The same term is employed by BLACK, but with a somewhat wider meaning, as to him it is of no importance whether the defect is a result of chemical action or not, he being mainly interested in the clinical manifestation irrespective of its cause. In French literature on the subject the term "erosion" is often used as a synonym of hypoplasia of the enamel (FREY).

VOGT in 1898 uses the term "Säurenkrose" to designate diseases of the teeth caused by the action of acids, and more especially of strong inorganic acids, while DETTLING in 1934 employs the somewhat strange term "odontomalacia nitrosa" for similar diseases of the teeth in nitration workers. The designation "perimyololysis" used in this article has been borrowed from FLEURY, who in 1929 defined myololysis as follows: "La mylolyse est une affection acquise, qui se manifeste par une destruction lente des tissus dures de la couronne des dents. Son siège, son étendue, son importance sont très variables. Elle est caractérisée par la dureté et la poli de sa surface, par la chronicité de son évolution et par le fait qu'elle ne répare jamais les pertes de substance qu'elle a causées."

The abovementioned destruction by decalcification of the hard dental tissue itself, where the decalcification takes place on the surface of the tooth, sometimes on a large part of the surface, and in some cases even on the whole tooth, is of rare occurrence, except where due to occupational causes.

This may quite naturally be ascribed to the fact that the introduction of a certain great quantity of weak acids or of a smaller quantity of strong acids will produce a series of harmful actions on the whole of the digestive tract, which will manifest itself long before the harmful actions have affected the calcified hard dental tissue.

On the other hand it might have been expected that the large quantity of acid contained in the stomach so near to the cavity of the mouth would not be without importance to the organs of the mouth cavity. It is true that the gastric juice does not in its ordinary course find its way to the mouth cavity, but it does happen even in perfectly healthy persons and frequently in persons suffering from a disease of the stomach. The reason why the teeth do not suffer in these cases is presumably that the comparatively great amounts of gastric contents brought up by vomiting pass the cavity of the mouth without being retained, and the comparatively small amounts brought up by pyrosis and regurgitation are insufficient to change the normal hydrogen ion concentration of the saliva to such an extent or for such a period that it might affect the surface of the teeth.

The extensive literature now existing on the subject of the interaction of the teeth and other parts of the digestive tract contains frequent references everywhere to the importance of the

insufficient mastication apparatus for the function of the stomach, and more particularly its aetiological importance to the gastritis. (DOMARUS, JORES, GUTZEIT, DENECKE, v. OSTEN-SACKEN and others.) Indications of the opposite side of the interaction, that is, the importance of gastric dysfunctions to the teeth, are much more rare. Where such possibility is ventilated at all, extremely vague statements are made regarding the importance to caries dentium of constant vomiting and pyrosis. JORES writes as follows: "Durch Aufstossen wie auch Erbrechen gelangt saurer Magensaft in die Mundhöhle, der den Zahnschmelz angreift und eine Karies verursachen kann." MISCH states that "bei erhöhtem Säuregehalt des Magensaftes können sie (the carious processes) dadurch eingeleitet oder verstärkt werden". A number of more recent dissertations (SCHACHSCHAL, MÜLLER, and others) likewise contain very indefinite statements as to the importance of gastric dysfunctions, and more especially that of hyperacidity, for the development of the carious processes.

These various statements are all of them couched in very general terms and evidently based on the clinical observation of an apparent interdependence between gastric dysfunctions and a more or less pronounced destruction of the mastication apparatus by dental caries.

The abovementioned forms of tooth wasting from non-mechanical causes have been very rarely considered as having any bearing on the disturbances of the gastric secretion. In his "Lehrbuch d. Zahnheilkunde" BAUME describes a case of facial erosion, which he calls "Abnutzung aus nicht genügend bekannten Ursachen", and in his description he mentions that for a lengthy period the patient was suffering from a disease of the stomach. MILLER mentions (D. C. 1907) two cases with facial erosions and notes that in both cases the patients showed dyspeptic symptoms. MISCH mentions that by rumination the gastric acid brought up together with the partly digested food must be presumed to be "nicht ohne nachteiligen Einfluss auf die Zähne", and BÜTTNER states (MISCH, Grenzgebiete) that by the excessive vomiting which often occurs by hyperemesis gravidarum "ist ein zweifellos schädigender Faktor gegeben". SCHACHSCHAL mentions that by *ulcus ventriculi* a very pronounced *abrasio dentium* may be observed.

In more recent literature at any rate two observations have been recorded of special interest in this connexion. FABIAN (1938) gives a detailed description of the teeth of a patient, aged 30, ♂,

who was for a long time suffering from pyrosis due to a disease of the stomach. The affection of the teeth manifested itself by wasting of the enamel of the upper anterior teeth and on the lingual surfaces of the canine teeth of the upper jaw and the premolars. This wasting is called "Entkalkung" by FABIAN, who also mentions that the consistence of the remaining tooth substance on the surfaces affected is similar to that of imperfectly decalcified dentine, as known from the preparation of teeth for histological examination. The wasting he considers a direct consequence of the sour eructations which are again caused by the disease of the stomach.

The second case is recorded by BARGEN and AUSTIN, 1936, from the Mayo Clinic. The patient was a woman, aged 26, who had for many years suffered from obstipation attended by continuous vomiting. On her admittance to the clinic her weight was 36 kilos and she was in a very poor condition. The Test for Hydrochloric Acid (TÖPFER) showed free hydrochloric acid 20 and total acidity 40; quantity 120 cm³. The hydrogen ion concentration of the saliva was pH8. On the lingual surfaces the teeth showed defects of the character of erosion, so much that the dentine was exposed. In the opinion of the authors the affection of the teeth was the direct result of long continued vomiting.

Below we propose to give a number of clinical cases demonstrating a peculiar defect in the hard dental tissue characterized by a very slow wasting of the tooth substance, confined to definite surfaces of the teeth and arising under such conditions that it cannot be a question of mechanical action only. And at the same time it is shown that all the patients examined suffered from gastric dysfunctions and periodical or continuous vomiting and pyrosis.

Case 1. P. J. ♂, about 50 years old, a gas-works manager. At present without material subjective complaints, except that after meals he is sometimes troubled by an unpleasant feeling of a heavy load in the epigastrium. Of this load he promptly and efficiently relieves himself by vomiting artificially produced. This voluntary evacuation of the stomach he has at periods effected several times a day after meals. The condition has existed for more than twenty years. He states that he has several times undergone a treatment for gastric ulcer. By a medical examination in 1928, when he was being treated for *ulcus duodeni* and frequently brought up by vomiting half a litre of a burning sour liquid, Ewald's test for hydrochloric acid showed a pronounced digestive hypersecretion: 150 + 25 cm₃, free hydrochloric acid 52, total acidity 73 = 128 cm₃ n/10 HCl. By a medical examination in 1933 Ewald's test for hydrochloric acid showed 230 + 50 cm₃, fairly well

chymified, free hydrochloric acid 30, total acidity 59.¹ An examination of the teeth of the patient immediately reveals (fig. 1) that the incisors of the upper jaw are conspicuously short and rounded, whereas the incisors of the lower jaw have completely preserved their normal shape and size. On further examination it appears that all the lower teeth have retained their shape and size, whereas the upper teeth all of them show a reduction of size, decreasing in the dorsal direction (fig. 2). At the first examination, in 1933, of the patient (fig. 3) the defect of the incisors of the upper jaw was not so pronounced. Fig. 4 shows quite clearly that the defects are confined to the lingual surfaces of the upper teeth, even though the anterior teeth have suffered to such an extent that their crowns have been reduced in height; in the premolars the whole lingual cusp has been reduced so that instead of an occlusal surface and a lingual surface, the tooth gets a very inclined lingual surface from the buccal cusp and to the neck of the tooth lingually. 5+ has a gold crown (see fig. 2) and therefore shows no similar deformation. The molars show changes similar to those in the premolars although less pronounced. The reduction of the lingual cusps of the molars is seen most distinctly (fig. 4) in 6+ and +7, where the difference between the level of the filling surface and that of the reduced tooth surface is very distinct. By a renewed examination of the teeth (October, 1937) an aggravation of their condition was observed (figures 6 and 7), which by an examination in March, 1939, appeared to be continuously progressing (fig. 8) so that by now the upper incisors are quite low, as regards +2 only about 1 or 2 millimetres high. The illustrations show quite distinctly that the defective places are quite smooth similar to the facets produced by attrition. When examined with a probe the affected tooth surface shows no roughness whatsoever, and it is quite as hard to the touch as the surrounding unaffected tooth substance. On comparing the examination of the teeth in 1933 with that of 1937 (fig. 3 and fig. 6) a considerable reduction of the bite will be noticed in fig. 6, besides which fig. 6 also in a much higher degree than fig. 3 shows the above-mentioned deformation of the occlusal surface of the upper premolars into an inclined lingual surface.

It should be pointed out here that a thorough investigation of the working conditions of the patient makes it absolutely impossible to presume that the affections of his teeth may be traced back to his occupation as a manager of a gasworks.

Case 2. W-A. ♀, aged 34, married to a managing director. Sixteen years ago the patient began to suffer from vomiting and heartburn, thinks herself it was due to a voyage of some length. Remarked herself that the vomiting especially occurred after meals, rich in fruit. To begin with the attacks of vomiting were comparatively rare, but gradually they became more frequent, until they occurred regularly after every meal and often also in between meals. At last she vomited ten or

¹ We gratefully acknowledge our indebtedness to SKAT KEMP, M. D., and E. JARLOV, M. D.

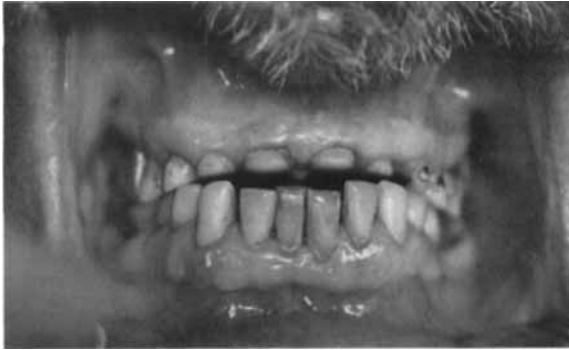

Fig. 1. Case no. 1. March 1939. Note premolars and molars in occlusion.

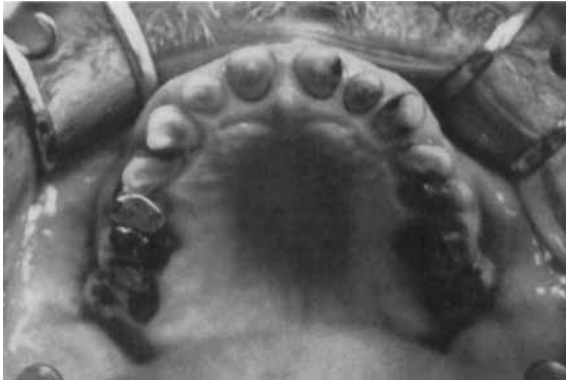

Fig. 2. Case no. 1. March 1939.

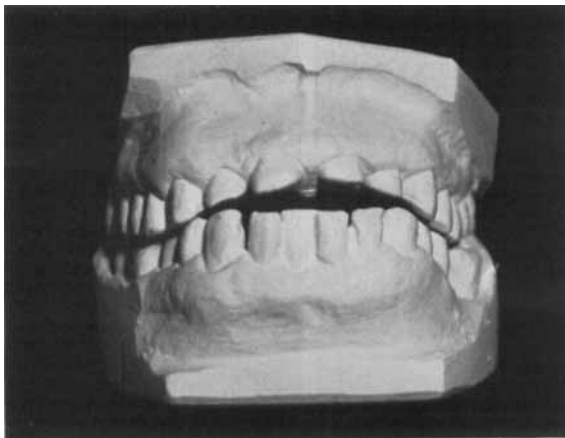


Fig. 3. Case no. 1. Oct. 1933.

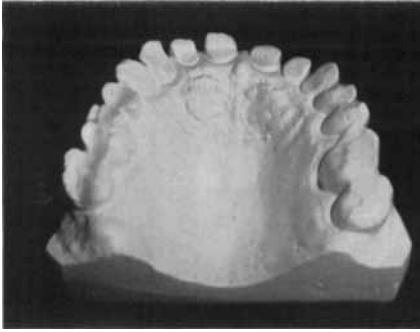


Fig. 4. Case no. 1. Oct. 1933. Note the difference between the filling surface and the reduced surface of the teeth 6+ and 7+.

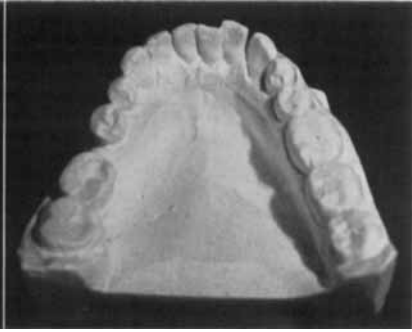


Fig. 5. Case no. 1. Oct. 1933.

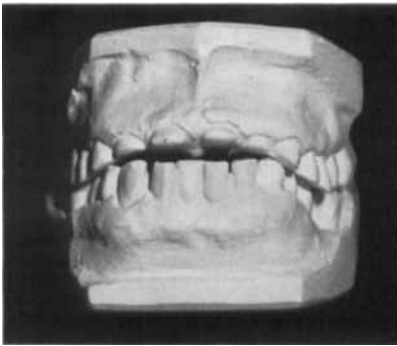


Fig. 6. Case no. 1. Oct. 1937.

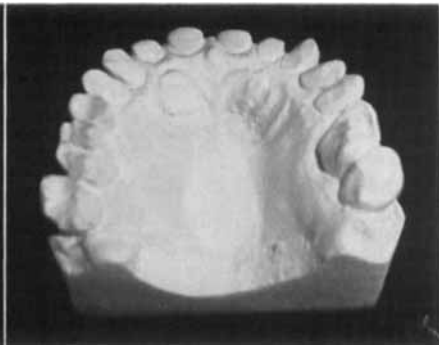

Fig. 7. Case no. 1. Oct. 1937.

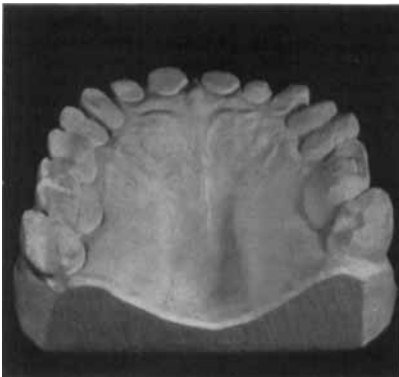

Fig. 8. Case no. 1. March 1939.

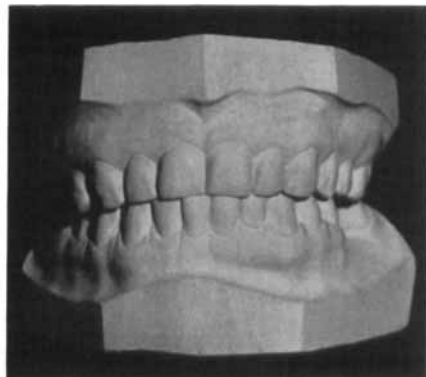


Fig. 9. Case no. 2. Oct. 1937. No reduction of the bite.

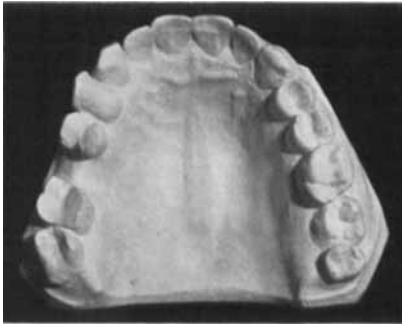

Fig. 10. Case no. 2. Oct. 1937.



Fig. 11. Case no. 2. Oct. 1937.

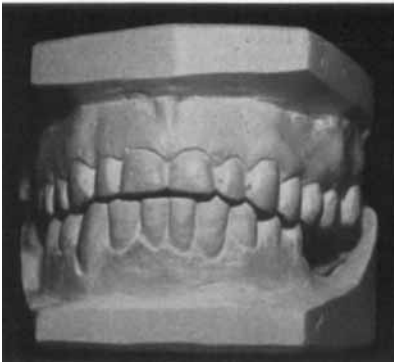

Fig. 12. Case no. 3. Jan. 1937.

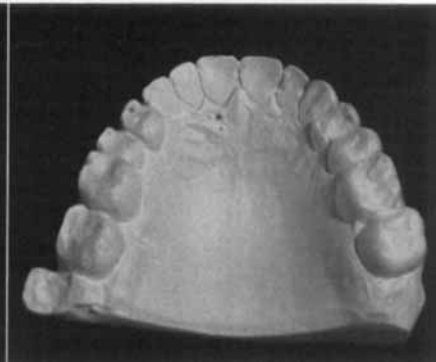


Fig. 13. Case no. 3. Jan. 1937.

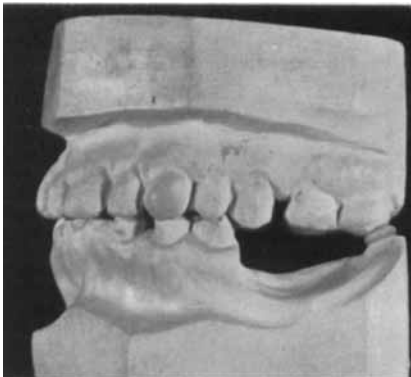

Fig. 14. Case no. 4. March 1939. Note the missing antagonists of +7 and +8.

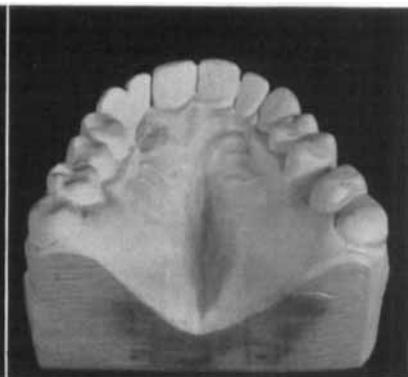

Fig. 15. Case no. 4. March 1939. Note the rounded outlines of +7 and +8, cf. «à l'extrémité d'un sucre d'orge, à moitié sucé» (Chompret).

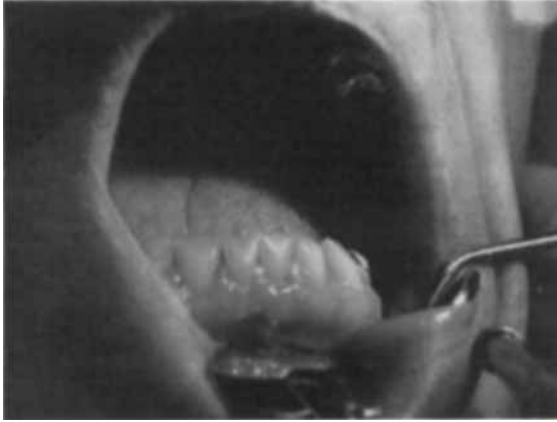


Fig. 16. Case no. 4. March 1939.

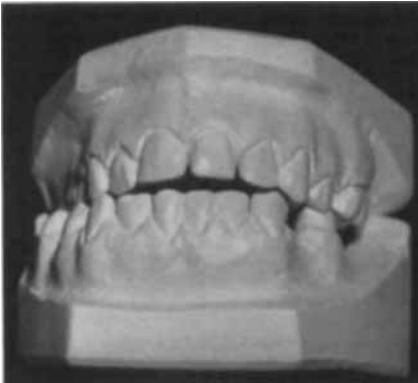

Fig. 17. Case no. 5. April 1934.

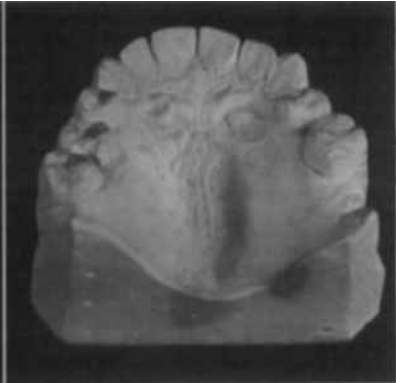

Fig. 18. Case no. 5. April 1934.

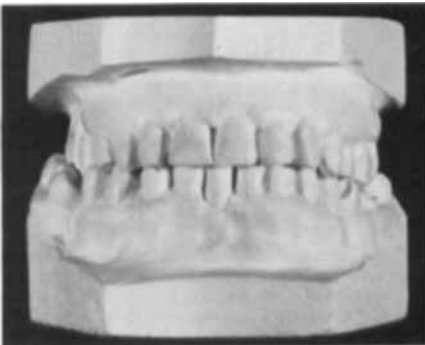


Fig. 19. Case no. 6. Oct. 1938.

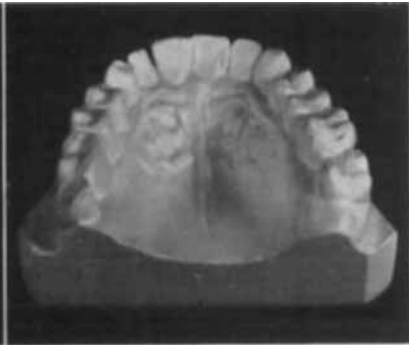


Fig. 20. Case no. 6. Oct. 1938.

fifteen times a day. Her condition has been much improved by a dietetic treatment, but still vomiting occurs after every meal and also in the morning and at night. A medical examination made in September, 1937, revealed digestive hypersecretion (110 cm₃ n/10 HCl) and obstipatio chronica c. colitide spastica (verified by X-ray photos). A renewed medical examination in November—December 1938 showed a considerable improvement of her condition, although she still suffered much from pyrosis. On November 25th, 1938, Ewald's test for hydrochloric acid showed 35 + 11 cm₃, free hydrochloric acid 25, total acidity 75, and on the 15th of December, 1938, the test showed: 55 + 14, free hydrochloric acid 30, total acidity 58.¹

An examination of her teeth undertaken in October, 1937, shows (figures 9—10—11) deformations similar to those apparent in case 1, only much less pronounced; fig. 9 shows the casts in occlusion. It is clearly seen that the extent of the over-bite is normal, making it quite certain that the defective places on the surfaces of the upper anterior teeth, which are clearly seen in fig. 10, cannot be due to mechanical action during their function. It is mainly the lingual surfaces of the upper incisors which have been reduced, so that the teeth have taken the form of a chisel; but also the canine teeth show a lingual reduction which appears clearly by the difference between the level of the filling surface and that of the reduced tooth surface in + 3. The reduced tooth surfaces are quite smooth and hard and extremely hypersensitive to mechanical and thermal and chemical stimuli. Fig. 11 shows that, as in case 1, not the slightest action is visible in the teeth of the lower jaw.

Case 3. E. W. ♀, aged 34, married to a managing director. Has for the last ten years been constantly troubled by dyspeptic symptoms, characterized by obstipation and continuous vomiting, dizziness and headache. Was appendectomized ten years ago without any effect on the symptoms. A medical examination revealed no organic diseases explaining her dyspeptic symptoms. Weight 53.4 kilos. Ewald's test for hydrochloric acid showed 5 + 9, free hydrochloric acid 20, total acidity 38, = mucus. X-ray examination of oesophagus and stomach shows normal conditions. She is dismissed with the diagnosis: vomitus nervosus, obstipatio chronica.²

Her present subjective symptoms (October, 1938) are lassitude, dizziness, general indisposition and particularly continued vomiting several times a day.

As in case number two an examination of her teeth shows (figures 12 and 13) a reduction corresponding to that of the upper teeth and particularly of the lingual surfaces of the upper teeth. In the medial incisors the wasting is so pronounced that it also shows by reduction of the length of the crowns of the teeth, which is clearly seen in figure 12. In figure 13 the corresponding reduction of the lingual surfaces of the canine teeth and the premolars is very distinct in the left side, where the

¹ We acknowledge our indebtedness to SKAT KEMP, M. D.

² We acknowledge our indebtedness to professor E. MEULENGRACHT, M. D.

difference between the level of the surface of the metal fillings and that of the surface of the tooth itself is particularly clear in + 3 and + 4. The surfaces affected are quite smooth and hard. In this case too there is not the slightest affection of the lower teeth.

Case 4. O. B. ♂, aged 46, provision dealer. Suffered already as a boy from indigestion especially after eating fat food. Underwent a treatment for an affection of the stomach ("too much gastric acid") ten years ago, at a time where he felt particularly bad, suffering from pyrosis and frequent vomiting and losing in weight. His condition improved somewhat, until, about six years ago, he again grew worse. He consulted a physician who made the diagnosis: pylorogastritis and probably ulcer duodeni. At that time he was suffering from frequent vomiting, ructus, head-ache, and retarded pains in the epigastrium. In March, 1935, Ewald's test for hydrochloric acid showed: 500 + 8, free hydrochloric acid 50, total acidity 76, + mucus, well chymified. His condition improved by a treatment for ulcer; but it is still difficult for him to retain his food, and periodically he suffers from vomiting, up to several times a day. On the whole his general condition must be considered quite good now.

The patient has observed that his teeth have become "stumpy" in the course of the last ten years or so. On examination the teeth (figures 14—15—16) are found to be rather defective. A number of the molars are lacking and the anterior teeth and the premolars of the upper jaw have artificial crowns. Fig. 15 shows that the other molars are considerably deformed. Their outlines have become very much rounded, and their crowns have become reduced in height. Fig. 16 shows that in this case also the lower teeth have been affected. Both the anterior teeth and the premolars show a reduction in height of their crowns and a characteristic rounding of their outlines. All the surfaces affected are smooth and just as hard as the other dental surfaces.

Case 5. ♂, aged 30, telegraph fitter. Feels subjectively well at present. As far back as he can remember he has suffered at times from dyspeptic symptoms, consisting of meteorism, periodical diarrhea, and regurgitations. Has not been troubled by actual vomiting, but has for months on end quite regularly had regurgitations after meals, as a rule for about 15 minutes. Ewald's test showed in 1934: 100 + 40, free hydrochloric acid 30, total acidity 75.

An examination of his teeth (figures 17 and 18) shows a similar tooth wasting as that noticed in the cases already reported. The occlusion picture (fig. 17), which was taken from below at a slightly oblique angle in order to demonstrate that the anterior teeth do not occlude at all, shows in + 1 the typical reduction of the length of the crown. 1 + has a $\frac{3}{4}$ gold crown, and accordingly its outlines are quite normal. Fig. 18 shows the lingual surfaces of the upper teeth and illustrates, although not quite so distinctly as did the above cases, the reduction of the lingual surfaces. All the surfaces affected are smooth and hyper-sensitive.

Case 6. H. N. ♀, aged 46, states that already as a child she suffered from indigestion. "Tuberculosis in the stomach" was mentioned; was on the whole ill very often when a child, was rickety, and contracted practically all infantile diseases. Feels at present subjectively well, when a little careful with regard to her diet and the opening of her bowels. Has suffered from childhood of heartburn, "burning water", and has for months on end been afflicted with frequent sour vomiting, up to several times a day. Is unwilling to submit herself to a closer examination and definitely refuses to take a test meal.

In the models in occlusion the examination of her teeth (figures 19 and 20) shows no reduction of the bite or of the length of the anterior teeth. Fig. 20, however, shows the same wasting of the lingual surfaces of the upper anterior teeth as that already described in the cases dealt with above. The surfaces affected are smooth and of the same hardness as the other dental surfaces.

Discussion.

The dental diseases of the six patients, described in detail above, show a number of common characteristics which may help to explain their occurrence. Of all of them it is known with certainty that they have been *acquired*, although in all the cases recorded their development has been extremely slow. This fact excludes the possibility that their occurrence might, in some way or other, be traced back to some constitutional defect. They are confined to quite definite surfaces of the teeth, especially to the lingual surfaces of the upper teeth. This fact excludes the possibility of their being due to a disturbance of the calcification. From their localization the possibility of a mechanical action as their sole cause may be excluded with certainty. They are always found first and foremost on surfaces which do not take a direct part in the mastication process, and there is nothing to indicate habitual or professional abrasion.

A chemical action on the tooth surface is actually the only possibility left, and this possibility is strongly borne out by the history of each particular case, and especially by the existence of gastric dysfunctions in all the cases observed. From the above statements it appears that all the six patients have been for long periods the victims of often frequent, excessively sour vomiting and sour eructations. This means that there is the possibility of the tooth surface having been exposed to an acid action.

However, the frequent bringing up of the sour contents of the stomach could hardly have effected a change, even of short dura-

tion, of the hydrogen ion concentration of the aggregate saliva. The very localization of the diseases of the teeth is against such a suggestion, as — assuming a sufficient amount of acid — a change in sour direction of the reaction of saliva would probably result in a uniform action on all the free surfaces of the teeth, quite apart from the fact that the buffer action of the saliva would quickly make up the difference from the normal reaction of saliva.

In order to throw some light on these matters, we have made an examination of the hydrogen ion concentration of the saliva in the oral cavity of five of the patients. (Patient number 3 is living abroad). The examination was performed with WULFF's folium colorimeter and showed the following values.

| | P_{H} in mixed saliva | P_{H} by papilla salivaris inf. | P_{H} on dorsum linguae | P_{H} by papilla salivaris sup. |
|------------------|-------------------------|-----------------------------------|---------------------------|-----------------------------------|
| Case 1 | 5.9 | 5.2 | 6.3 | 5.4 dextr. 6.3 sin. |
| Case 2 | 6.9 | 6.5 | 7.0 | 7.0 |
| Case 4 | 6.9 | 6.2 | 6.3 | 5.7 |
| Case 5 | 6.3 | 6.5 | 6.6 | 6.0 |
| Case 6 | 6.3 | 6.2 | — | 5.9 |

When it is borne in mind that the examinations were made at different times of the day, and regardless of the time when the last meal was taken, and so on, these figures show — as to cases 2—4—5—6 — no distinct deviation from the values stated as normal (STERN PH 6.8, BRAWLEY PH 6.75, MATHIS PH 6.75 \pm 0.2, STARR PH 6.35—6.80 for 86 % of 228 healthy persons, for 100 % PH 5.75—7.05). As to case 1 it seems as if the values are very high, but there being at the same time a very great difference between the values by papilla salivaris sup. dextr. and those by papilla salivaris sup. sin., the statement must, as regards case 1, be considered with some reservation (as the patient does not live in this town we have been unable to check it).

This random sample of the hydrogen ion concentration of saliva seems to bear out the view that the diseases of the teeth cannot be traced back to any direct action on the teeth of saliva.

But it is quite in accordance with the localization of the diseases of the teeth to explain their occurrence by a combined mechanical and chemical action, on the presumption that dorsum linguae

between papillae filiformes holds good possibilities for a retention, even if of short duration, of small amounts of excessively sour gastric contents brought up by the vomiting. By the movements of the tongue, the tip of the tongue, and the margin and part of the dorsum will touch just the lingual surfaces of the upper teeth, whereby the combined mechanical-chemical effect will be obtained. Against this explanation it might be argued that in none of the cases examined, the hydrogen ion concentration on dorsum linguae showed higher values than anywhere else in the cavity of the mouth, but in order to have any value as a proof, it would be necessary to measure the hydrogen ion concentration immediately after a vomiting, and as yet there has been no such possibility in the cases examined. In favour of the explanation it may be stated that in all the cases the defects are particularly prominent on the surfaces touched by the part of the tongue having papillae filiformes, during the function of the tongue by speech, chewing, swallowing, and so on. Further it is shown that the surface of the slowly arisen defective places are completely smooth, which presupposes a not purely *chemical* action with decalcification, but exactly a *combined chemical-mechanical* action, which in its turn, in combination with the said localization, presupposes the co-operation of the tongue. That it must be a question of acid introduced into the cavity of the mouth from somewhere else is shown partly by examinations of the hydrogen ion concentration, which excludes the hypothesis of a change of the reaction of saliva in a sour direction, and also by the localization that clearly reveals the place of the defects on the surfaces which are the last to be reached by the saliva secreted from regio sublingualis or vestibulum, and where consequently the acid introduced into the mouth remains untouched for a comparatively long period. As in all the cases examined a frequent and continuous bringing up of sour gastric contents precisely to cavum oris proprium has been observed, the hypothesis that the diseases of the teeth have arisen as here described seems to be extremely probable.

Summary.

1. Six clinical cases are reported, which all of them show a uniform tooth wasting from non-mechanical causes—perimyolysis.
2. In all the cases examined gastric dysfunctions have been attended by the same symptoms, namely, pyrosis and vomiting

for a lengthy period, and in a single case mainly regurgitation.

3. On basis of the localization of the diseases of the teeth to the lingual surfaces of the upper teeth, and on basis of the hydrogen ion concentration of saliva being found normal, both when examined in its entirety and when examined in several places of the cavity of the mouth, and on basis of the constant bringing up into the mouth cavity of sour gastric contents, shown to have taken place, we draw the inference

4. that the form of tooth wasting found in the cases recorded is caused partly chemically by the retention on dorsum linguae of gastric acid and partly mechanically by the movements of the tongue against the teeth.

Zusammenfassung.

1. Sechs klinische Fälle, die dadurch charakterisiert sind, dass sie alle dieselbe Form eines nicht mechanisch bedingten Zahnkronenschwundes zeigen, werden mitgeteilt.

2. In sämtlichen Fällen werden zugleich Ventrikeldysfunktionen, besonders digestive Hypersekretionen, gefunden; sämtliche Fälle haben folgende Symptome gemeinsam: seit langem bestehende Pyrosis und Vomitus, in einem Fall hauptsächlich Regurgitation.

3. Von der Lokalisation der Zahnkronendefekte, die zu den palatinalen Zahnflächen des Oberkiefers begrenzt sind, von der als normal — sowohl im Ganzen als an verschiedenen Stellen der Mundhöhle gemessen — beurteilten Wasserstoffionenkonzentration des Speichels, von dem Nachweis des durch längere Zeit stattgefundenen Aufbringens von saurem Magensaft in die Mundhöhle ausgehend, wird die Konklusion gezogen:

4. dass der Zahnkronenschwund in den mitgeteilten Fällen teils chemisch durch den auf dem Zungenrücken retinierten sauren Magensaft —, teils mechanisch durch die Bewegungen der Zunge verursacht ist.

Résumé.

1) Six observations cliniques sont présentées. Elles montrent toutes une usure dentaire uniforme dont la cause est non-mécanique perimyolysis.

2) Dans tous les cas examinés des troubles de l'estomac ont été constatés. Il s'agit des mêmes symptômes, soit pyrosis et vomissements durant une longue période; dans un seul cas surtout des régurgitations.

3) En nous basant sur la localisation de l'affection dentaire à la face linguale des dents supérieures; et sur la concentration normale du ion d'hydrogène dans la salive, examinée dans son entier ainsi qu'en divers points de la cavité buccale et enfin sur l'apport constant prouvé de contenu gastrique acide dans la cavité stomacale, nous avons conclu

4) que le genre d'usure dentaire rencontrée dans ces observations est provoquée en partie chimiquement par la rétention sur le dos de la langue de suc gastrique acide, et, en partie mécaniquement par les mouvements de la langue contre les dents.

Bibliography.

- BARGEN, A., AUSTIN, L.: Decalcification of Teeth as a Result of Obstipation with Long Continued Vomiting etc. J. of Americ. Dent. Assoc.: 24: 8: 1271: 1937.
- BAUME, R.: Lehrbuch der Zahnheilkunde. Leipzig 1890.
- BERCHER, FARGIN-FAYOLLE, FLEURY, LACAISSE: Pathologie dentaire. Paris 1935.
- COMROE, B. I.: Salivary Changes in Systemic Disease. Dent. Cosm. 76: 5: 563: 1934.
- DENECKE, GERHARD: Kursus der klinischen Untersuchungsmethoden. München 1926.
- DETLING, I.: Zahnkronenschwund bei Nitrierarbeitern. Zangger Festschrift, Zürich 1934.
- DOMARUS, A. v.: Grundriss der inneren Medizin. Berlin 1934.
- FABIAN, HEINRICH: Merkmale und Grenzen in der Domestikationsfrage am Gebiss. Deutsche Zahnheilkunde. Heft. 84: 1933.
- FLEURY: These. Paris 1929. (cit. BERCHER, etc.)
- FREY, L. et RUPPE, CH.: Pathologie de la Bouche et des Dents. Paris 1933.
- GUTZEIT, K.: Die Magenfunktion in ihrer Beziehung zu Vorgängen in der Mundhöhle. Deutsch zahnärztl. Wochenschr. 34: 8: 441: 1931.
- HÜBNER, O.: Über Säurewirkung im menschlichen Gebiss. Deutsch. zahnärztl. Wochenschr. 35. 12. 625. 1932.
- JORES, ARTHUR: Grundzüge der inneren Medizin, Leipzig 1935.
- MATHIS, HERMANN: Über die Wasserstoffionenkonzentration des menschlichen Speichels usw. Der prakt. Zahnarzt. 4: 7—8.
- MILLER, W. D.: Experiments and Observations on the Wasting of Tooth Tissue. Dents. Cosm. 49: 1: 1: 1907.
- MISCH, J.: Gewerbliche Schädigungen der Mundhöhle, Fortschr. d. Zahnh. 1: 1038; 1925.

- MISCH, JULIUS: Grenzgebiete, Leipzig 1923.
- MÜLLER: Zahn- und Mundkrankheiten in ihren Beziehungen zu Magenkrankungen. Inaug. Diss. Leipzig 1932.
- OSTEN-SACKEN, H. v. D.: Innere Medizin. München 1937.
- SCHACHSCHAL, HERBERT: Unters. des Zahnsystems und der Kaugewohnheiten an Magenkranken und Magengesunden in Pommern. Inaug. Dissert. Greifswalde 1935.
- STARR, H. E.: Studies on Human Mixed Saliva. J. Biol. Chem. 54: sept.: 55: 64: 1922. (Cit. eft. COMROE.)
- STERN, A. R.: The Hydrogen — Ion Concentration of Normal Resting Saliva etc. Dent. Cosm. 73: 10: 1017 1931.
- VOGT, R.: Gesundheitl. Gefahren für die Nitrierarbeiter usw. (cit. MISCH., J.: Grenzgebiete).

Address:

Trommesalen 5.

Copenhagen V.