

Serial Extraction as a Corrective Procedure in Dental Orthopedic Therapy.

By

BIRGER KJELLGREN.

616. 314089. 23

The aim in dental orthopedic treatment is, as ANGLE has pointed out, to therapeutically so influence a developing or fully developed malocclusion that a normal occlusion is reached and maintained. The experience assembled from a large number of dental orthopedic treatment methods in the past half century, including both fixed and removable appliances, labial or lingual, intra- or extra-oral, with intermittent or continuous force, functional or purely mechanically effective, shows, however, a rather limited possibility of reaching, and especially maintaining, this ideal result. There is more or less risk of relapse after the final treatment of certain malocclusion types. Present experience especially shows a strong tendency of recurrence in cases of evident crowding and contraction. It is frequently necessary in these cases to be satisfied with a compromise treatment. The size of the jaws may make it necessary to reduce the dental units where the bones are too small to allow a perfect occlusion in order to obtain a functioning and esthetic optimal result. Although extractions are fundamentally unsympathetic, they are, however, necessary for treatment of many malocclusions, especially contraction anomalies, in order that the best possible result may be obtained. When resorting to extraction, the scheme of procedure should be so systematically planned that disadvantages are at a minimum and the intended effect is the very best possible.

The extraction of teeth within the dental arch, at least temporarily, increases the available space for the remaining teeth (SEIPEL, 1946). The effect of such an extraction is to a certain

extent, more or less, calculable positional changes, or wanderings, of the remaining teeth of the dentition, primarily the approximating teeth and the functioning antagonists. Extractions should be made 1) when as a direct effect, the extraction provides possibility for the remaining teeth to shift so that the calculated result will be a better functioning and esthetically improved occlusion: or 2) when it provides a condition for, or fundamentally facilitates, the treatment of the malocclusion by orthopedic appliance.

Both the patient and the operating dentist will, at least to some degree, hesitate in the extraction of a non-carious tooth, even in cases of evident crowding, therefore, it can often be postponed so long that the anomaly is fully developed and manifested in the permanent dentition. In many cases the occlusion can be improved by suitable extractions, even at this time, but in other cases, perhaps the majority, the anomaly has become unnecessarily complicated, and, in addition to extraction, now requires treatment by appliances over a longer period of time. It therefore seems important, and of real therapeutic value, that at an early stage, preferably in the deciduous dentition, the dentist tries to perceive the development prognosis and makes clear if reduction of dental units by extraction will be necessary. He should even early in the development make plans for these extractions so they effect the most favorable possible development and facilitate any anticipated necessary orthopedic appliance treatment. The plans for the extractions ought fundamentally to concern both the permanent and deciduous teeth.

It is a relatively new conception to attempt to improve the development of the occlusion by extraction of deciduous teeth. Loss of deciduous teeth is generally designated in orthodontic literature, especially by the earlier writers, as solely harmful. This of course, is true in cases of normally developing deciduous arches. In such a normal occlusion case, the loss of a deciduous tooth can not improve the condition or development, but only cause functional impairment and endanger the normal development. Premature loss of a deciduous tooth, *i.e.* several years before the normal time, is here the basis of a malocclusion development, in that the teeth adjacent to the resulting space may drift into it, hereby constituting an obstruction to the permanent teeth which later should erupt. In this way, premature loss of deciduous teeth favors the crowding or bunching of the teeth. This commonly comprehended though not entirely undisputed

idea, probably has motivation, and a justified validity concerning the deciduous molars. It is debatable whether the loss of a deciduous incisor will cause a malocclusion in a normal case or aggravate tendency to contraction. In some cases, which are discussed later, it may even be considered that the premature loss of a deciduous lateral incisor or canine tooth has an appreciable mitigating effect upon a developing anomaly to such an extent, that a crowded unerupted or erupting permanent tooth will be given opportunity to erupt in a less abnormal position. The different results effected by the loss of deciduous molars and deciduous anterior teeth is mainly due to the dissimilar size relationships that exist between the deciduous and permanent teeth or the respective groups.

In the molar section, all the deciduous predecessors are wider mesiodistally than are the premolars of the second dentition; an inverse relationship is prevalent for the anterior teeth, the deciduous teeth are narrower than the succeeding permanent teeth. Therefore, if a deciduous, especially the second molar is lost, a significant drifting together of the adjacent teeth can begin before the permanent tooth provides a direct mechanical resistance, because of its size, shape and position. This holds true even if the permanent tooth is soon ready to erupt.

Even in the normal course of replacement, this drifting may be considered especially in the lower jaw, where the size differences are the greatest, often amounting to several mm. reduction in the distance between the first molar and the canine's distal point of contact (NORBERG 1925).

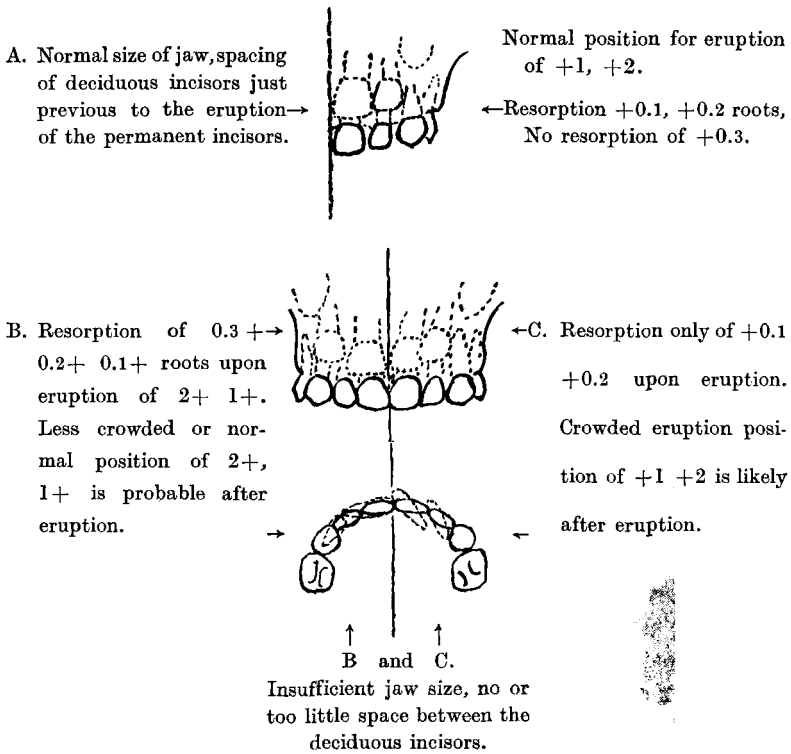
The partial reduction within the dental arch, is, however, fundamentally compensated for by the larger space required by the permanent canines. The anterior section of the jaw, on the contrary, will increase considerably up to 6—7 mm. from canine to canine during the eruption of the incisors and in case of favorable development (KORKHAUS, NEUMANN 1931). Contrary to the condition existing in the deciduous molars, proximal contact is not formally found between the deciduous incisors; wherefore, these can not be of mechanical value in maintaining the width of the arch, at least, not during the later years of their existence, when the considerably wider crowns of the soon erupting permanent incisors lie so close to each other and even to the nearly resorbed roots of the deciduous incisors.

Size relationship of the deciduous canine to its succeeding tooth

is similar to that of the incisors. A different correlation is, however, true regarding the relative position of this tooth to the corresponding permanent. The buds of the permanent canine start out, and for a relatively long time remain, at a greater distance from its normal erupting place, than do the other anterior teeth. They do not form any mechanical hindrance against migration of the adjacent teeth in cases of premature loss of the deciduous canine. The effect of premature loss of a deciduous canine is also obvious, as a drifting of the adjacent teeth into the provided space usually takes place. In cases of crowded permanent incisors, this drifting is especially pronounced and often results in a less crowded condition in that region. Unilateral loss of deciduous canines generally shows distortion of the midline to this side. Mesial drifting of the deciduous and permanent molars is less pronounced and is counteracted by the, at this time, especially strong fixation of these teeth as the deciduous molars and the anlage of the permanent premolars together, long form a sort of block. The also normally existing functional fixation of the deciduous molars (intercusping) by their antagonists still increases their stability.

When the tendency toward crowding, with constricted arches, is diagnosed early in the mixed denture, the dental orthopedist should try to comprehend the existing treatment possibilities for such anomalies, so that the result will be the best possible occlusion. Most often the choice lies between an attempt at 1) full expansion, aiming at a normal occlusion or 2) compromise treatment by reduction of dental units (extraction) in connection with simplified appliance treatment or 3) possibly reaching an acceptable compromise result through extraction alone. The prognosis for alternative 1 is, however, often uncertain; the treatment by appliances many times requires several years. It even may happen, especially in cases of poor health, nervousness etc. that the patient's psychical and physical tolerance to the treatment is overstrided. In these cases of appliance treated contraction malocclusions a later reduction in connection with the eruption of 8 ± 8 is generally required (ANDRESEN). The length and difficulties of this treatment for so prevalent an anomaly, even when using the modern simplified methods (lingual arches, Andresen- or Schwarz-plates), makes the general realization of this plan of treatment a Utopian scheme, under present social conditions. The frequency of contraction anomalies in need of treatment is so great that even alternative 2 would usually be a difficult therapeutic task. There-

Fig. 1.



fore the cases which are apt to be brought to an acceptable result according to alternative 3 and of course, even alternative 2 are always numerable, both in socialized dentistry as well as in private practice.

In early diagnosed malocclusion cases, where extraction seems evident in order to reach an optimal result, the idea of treatment according to alternatives 2 and 3 is to so plan the extractions, already in the mixed denture, as to facilitate the best possible development of the resulting reduced permanent denture.

The following nomenclature of the teeth is used:

Deciduous teeth

Upper: right 05 04 03 02 01 + 01 02 03 04 05 left
Lower: > 05 04 03 02 01 - 01 02 03 04 05 >

Permanent teeth

Upper: right 8 7 6 5 4 3 2 1 + 1 2 3 4 5 6 7 8 left
Lower: > 8 7 6 5 4 3 2 1 - 1 2 3 4 5 6 7 8 >

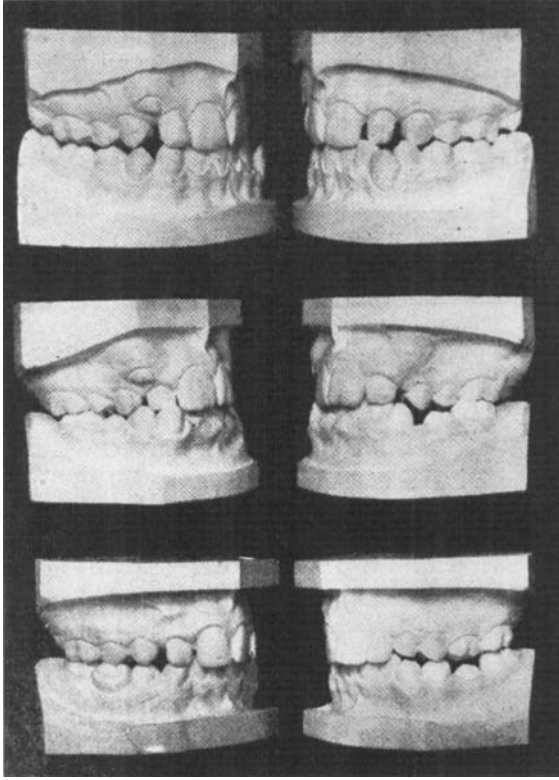


Fig. 2.

Malocclusions of the contraction type, which according to earlier prevalent thought, were caused by premature loss of the permanent canines. (Mc Coy, 1922.)

The applied method then consists of one or more extractions of deciduous teeth in the mixed denture, with the purpose of forming a most favorable possible situation for the extractions in the permanent denture, where the intended final reduction of the dental units is carried out. This method has been named "serial extraction" by the author since it was first made public in 1929.

Premature loss of deciduous molars is almost entirely due to caries or its consequences. The same is true of the deciduous central incisors, which, however, are also often lost by direct trauma. Deciduous lateral incisors and more especially canines, on the contrary, are often lost because of early root resorption, caused by contact with the crown of the relatively earlier forming and erupting, permanent mesially adjacent tooth. The eruption of the per-

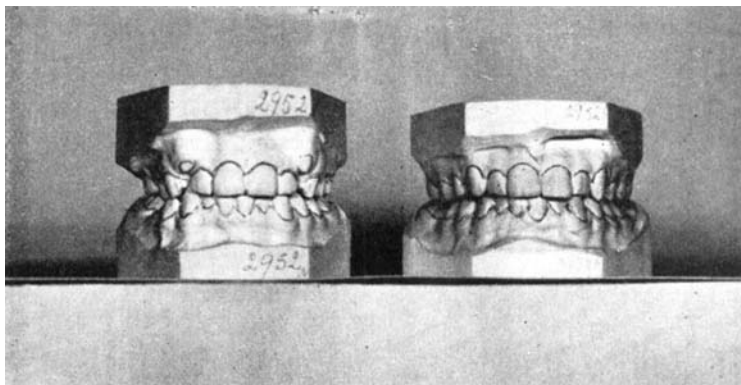
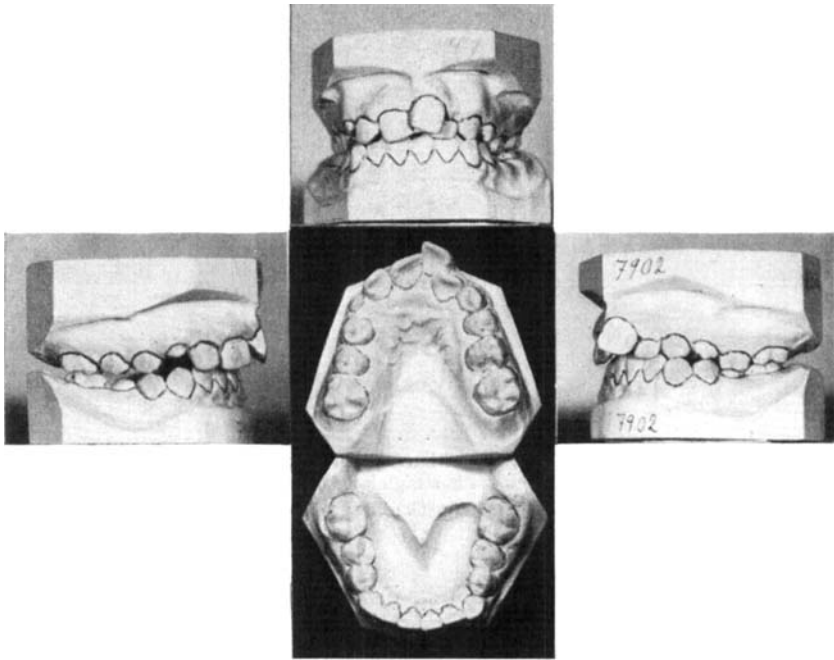


Fig. 3.

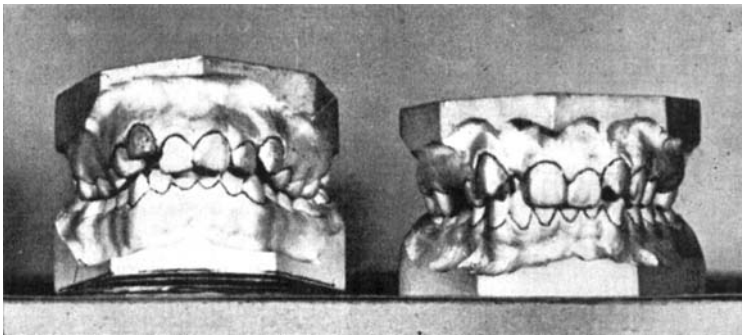
- A. Premature loss of 0.3+ +0.3 with eruption of 2+ +2, 2+ 1+ +1 +2 are in good position, 3+ +3 are in a high labial, crowded position of eruption.
- B. 3+ +3 have grown into good functioning positions, after the extraction of 4+ +4.

manent central incisors, especially in the upper jaw, often causes the premature resorption and loss of the deciduous lateral incisors, the permanent laterals cause the resorption and loss of the deciduous canines, fig. 1. As far as the deciduous canine is concerned, loss by such root resorption is incomparably more frequent than loss from caries, since this tooth, like its permanent successor, is relatively caries resistant.

The reason the deciduous canines so often resorb with the eruption of the laterals, is that the lateral incisors, in cases of restricted space in the anterior section of the jaw, are forced so far laterally by the central incisors that their crowns, through close contact cause the resorption of the root of the deciduous canines, fig. 1 B. The premature loss of the deciduous canines with the eruption of the laterals is, in these cases, a "result" of the constricted arch and the crowded position of the permanent teeth, "not", as is often pointed out in the literature, a "cause" of the same, fig. 2. In such cases where the deciduous canines resorb with the eruption of the laterals, the permanent incisors and especially the lateral incisors, usually assume an even position in the dental arch, without much rotation or distortion, because they make use of the space intended for the canines, fig. 2, 3 A. This is contrary to cases of crowding where the deciduous canines have not been resorbed by the eruption of the lateral incisors, fig. 4. In these latter cases, the incisors,



A



B

C

Fig. 4.

Occlusion anomalies of the contraction type, with crowded position of the incisors, and protrusion of the upper incisors, especially the lateral incisors. $0.3+ +0.3$ have not been lost with the eruption of $2+ +2$. Appliance treatment is necessary over a long period of time, and extraction of the upper premolars is advisable for correction. It is probable that the incisors and canines in these cases would have assumed acceptable positions if serial extraction had been employed.

Compare fig 4 A and fig. 8.

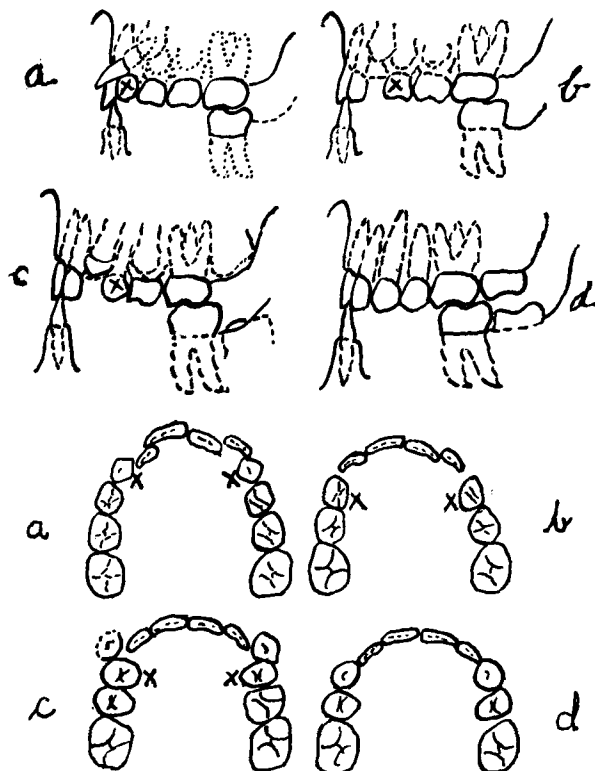


Fig. 5.

Serial extraction in case of contraction with crowded upper incisors. The mandibular arch in this case is supposed to be in distal occlusion, with no appreciable crowding, and with about normal overbite.

- a. Extraction $0.3+ +0.3$ at 8—10 years of age.
- b. Crowding of the incisors improved at 10—11 years. Eventual extraction of $0.4+ +0.4$.
- c. $3+ +3$ eruption in a crowded position at 11—12 years. Extr. of $4+ +4$.
- d. $3+ +3$ have taken normal positions.

after eruption, often assume a distorted and rotated position, forming a very disturbing malocclusion. In both cases, the crowded position is accentuated upon the eruption of the permanent canines.

In the cases where the deciduous canines are resorbed with the eruption of the laterals, and the incisors, on this account, come into relatively good positions, the permanent canines often erupt in so high a labial position, that a good self regulation can take place after the extraction of the first premolars, fig. 3B. Such cases are the typical good extraction self-regulating cases. Es-

pecially if the crowded eruption of the permanent canines exists only in the upper jaw, and the lower jaw has an almost normally shaped dental arch and is in distal occlusion, the extraction of the upper first premolar is very effective, and if the bite is not abnormally deep, is a suitable treatment for the occlusion in its entirety.

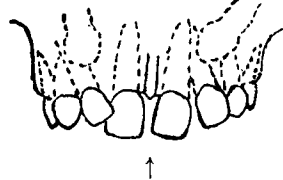
In cases where the deciduous canines are not resorbed by the laterals' eruption, and where the incisors in this connection are often crowded and rotated, the permanent canines can, of course, often grow into place after extraction of the first premolars, but the crowded position of the incisors usually does not improve much by such an extraction, and these cases, in addition to the extraction of the first premolars often require regulation of the incisors by appliances over a longer period of time, which are difficult to retain, fig. 4.

Permature loss of the deciduous canines due to resorption at the eruption of the lateral incisors results, therefore, in a malocclusion which is less complicated, less disturbing, and more adaptable to treatment, often only in need of extraction, fig. 3. On the contrary, cases of constricted arches, where the deciduous canines have not been resorbed by the eruption of the lateral incisors, give an essentially more serious malocclusion picture, both cosmetically and functionally as well as from a therapeutic viewpoint, fig. 4. Observation of these relationships motivates, that in such cases, as develop according to the latter type, attempt to attain an occlusion picture of the first type, by extraction of the deciduous canines at the most favorable time; which later, upon the eruption of the permanent canines, can be treated to advantage by extraction, usually of the first premolar.

In such cases where especially the lateral incisors are protruding (distorted) and the crowding is not too extreme, the method, serial extraction, may be used which consists in, first, extracting the deciduous canines at the age of 8—10 years, fig. 5a, and some year later, extracting usually the first deciduous molar, fig. 5b, and last, preferably close to the complete eruption of the first premolar and $\frac{1}{2}$ eruption of the canine, extracting, as a rule, one premolar, fig. 5c. In this way, the canine will be allowed to grow into the created space in the dental arch, fig. 5d. According to predominant thought, it cannot be denied that extraction of the deciduous canines at the time of the eruption of the laterals, about 8 years of age, involves some risk of decreasing the arch

Fig. 6.

A. Extreme mesial eruption position of the canines over the roots of the laterals. Their improvement is hindered by the permanent canines and extraction of the deciduous canines would not in such a case make the position of the laterals much better.



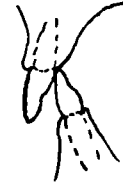B. Diastema should be corrected before eventual extraction of +0.3+.

C. The laterals have a distal inclination due to pressure from the erupting canines. Extraction of the deciduous canines would increase this inclination.

D. Extreme rotated positions of the laterals seems to be congenital, and does not often improve upon the extraction of the deciduous canines.



E. Extreme overbite, with gingival biting, counteracts improvement of crowding incisors after possible extraction of the deciduous canines.



development; therefore as a rule, it is not extracted until over half of the lateral has erupted, usually 9 years; since with the eruption of the incisors, the anterior portion of the dental arch has nearly reached complete lateral development. If the lateral incisors have protruded labially or lingually, or are not too much rotated (under 30°) when erupting, this malposition will now often improve in the now facilitated last phase of its eruption. If, however, the laterals are rotated as much as $45-90^\circ$, especially mesio-labial rotation, chances for improvement are decidedly less, fig. 6 D. Even at an early stage, these positions of extreme rotation seem to be a manifested occlusion type, which show strong resistance to all treatment, have an obstinate tendency toward relaps after treatment and lack ability for self improvement, even upon the abolishment of the crowding in the arch. A slightly rotated or protruding position of the erupting laterals, on the contrary, often seems to become involved by the opposition their eruption encounters from the deciduous canines' roots and crowns. If this opposition (the deciduous canine) is removed, conditions for eruption are, therefore, often relieved, and the lateral incisors

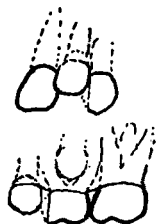


Fig. 7.

Slicing off contact points of the deciduous teeth.

- A. +0.3 is ground off to ease the position of the erupting +2.
 B. +0.5, to increase a distal drifting of +4.

can grow into a normal position. Sometimes the laterals are so rapidly and greatly effected, that it is apparant that their malposition was a crowded position, caused because during their eruption they slid along the roots of the deciduous canines and were forced into a malposition between these and the central incisors. Thus, even in developing inverted occlusions are found examples, fig. 15 & 16, of erupting laterals that rapidly grow into a normal labial position after the extraction of the deciduous canines that were pressing against them.

When the lateral incisors first start erupting in a constricted space, at 7—8 years of age, they can be aided to a more normal eruption by slicing off the mesial surface of the deciduous canines that presses against the lateral, fig. 7 A. This is the first step in helping the occlusion, extraction of the deciduous canine about half a year later will be the next step.

Extraction of the first deciduous molars at 10—11 years, helps to ease the eruption of the first premolars and thereby even the adjacent canines. In order that the first premolars can erupt as far distally as possible, the mesial contact point of the second deciduous molar may be ground off, fig. 7 B. The largest space possible is hereby provided for eruption of the canines without too early an extraction of the first premolars. If this extraction is made too early in the eruption stage of the canines, there is danger that the second deciduous molars or still more the second premolars and the molars may drift mesially to such an extent that there is not space enough left for the canines in spite of extraction. If the first premolars are thus extracted a long time before the completed downward growth of the canines, a space maintainer should be provided to keep the space after extraction.

It can also happen that to provide supplementary space for the erupting canines, it may be more advisable to eliminate the first molar, if it is carious, or the second molar, if it is in extreme malposition, instead of extracting the first premolar. In exceptional

A B C E

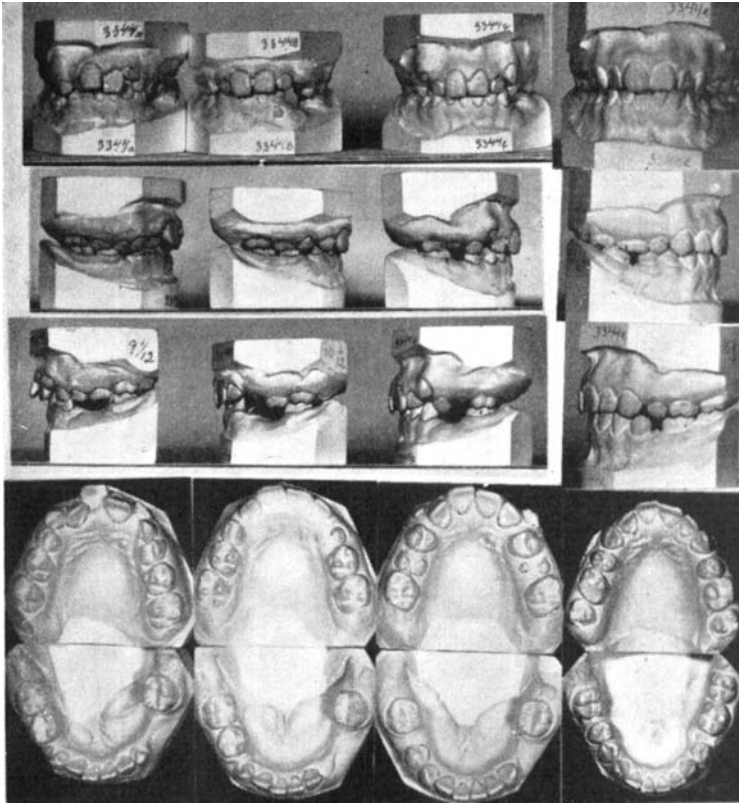


Fig. 8.

E 3344. I. M. S-n. ♀ 9—15 yrs. Contr. upper arch Rt. neutr. oocl. Lt. neutr. oocl.
 1939, Oct., *model A*, 9 yrs. X¹ 0.3+ +0.3.
 1940, Oct., *model B*, 10 yrs. 2+ +2 norm. X 0.4+. Slicing +0.5 mes.
 1941, Nov., X 0.5+, 3— —3 erupting. Spatula biting of 2+ /3—.
 1942, May, X +0.5.
 1942, Nov., *model C*, 12 yrs. X 4+ +4.
 1943, Aug., 3+ +3 grown into place. Crowded eruption of 5— X 6—, (*model D* excluded).
 1944, Sept., 6—, a 5 mm. space.
 1946, Feb., *model E* 15 yrs., 5— in occlusion, —5 crowded eruption position, X —6.

Extraction of 0.3+ +0.3 at 9 yrs. effected a rapid improvement of the upper incisors. The distance from 2+ distal ↔ +2 distal increased 3 mm. in one year, *model A* → *B*. No mesial drifting of 6+ 0.5+ 0.4+, +0.5 +6 were compared and measured from the occluding antagonizers. Eruption of 3+ +3 at the normal time. Extraction of 0.3+ +0.3 effected no retention. (Retarded eruption of —4 —5 after premature loss of —0.4 —0.5, which healed forming a hardened "leathery" gingiva.) The bite was slightly raised.
 Transverse distance 0.5+ ↔ +0.5 *model A = B*
 » » 6+ ↔ +6 » *A = B = C.*

¹ X = extraction.

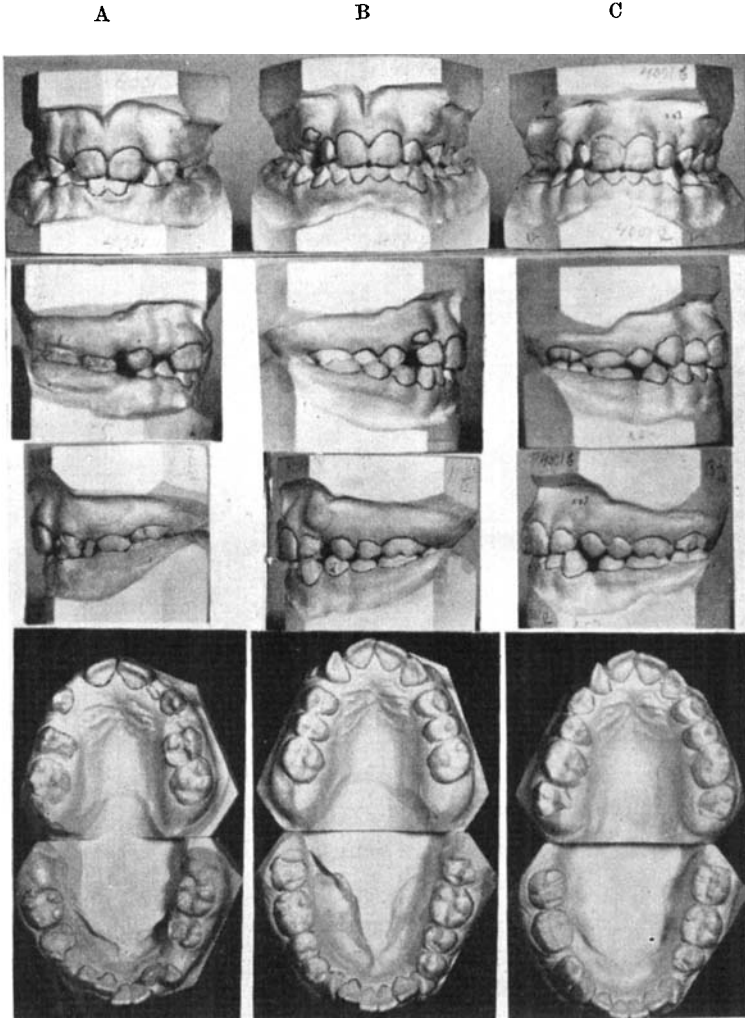


Fig. 9.

E 4001. L. E-m. ♀ 8—13 yrs. Contr. upper arch, lower arch. Rt. neutral occl., Lt neutral occl., crossbite rt.
 1940, May, 8 yrs. X 0.4+ +0.4 caries.
 1940, Sept., *model A*. 8½ yrs. +2 pal. -2 ling. erupt. X +0.3 -0.3.
 1941, April, +2 -2 norm., 2+ in crowded eruption position. X 0.3+.
 1942, Feb., -3 in crowded eruption position, X̄ -0.5.
 1944, Feb., *model B*, 12 yrs. 3+ in crowded eruption position. X 4+, X 5— cross-bite. Grinding off of 6+/6— for cross-bite.
 1944, Oct., +3 extreme buccal position. Spatula biting of +2/-3. X +3, -4.
 1945, April, *model C*, 14 yrs.
 0.4+ +0.4 were extracted at 8 years because of caries. Extraction of +0.3 -0.3 at 8½ yrs. effected rapid drifting of +2 -2 labially to a normal position.

cases when the primarily displaced canines erupt directly over the lateral incisor, it may seem advisable to remove the lateral, likewise with complete abnormal position of the canines, these may be extracted. For these reasons, and on general principles not to extract a permanent tooth before it is absolutely necessary, and when an accurate estimate of the result of such an action can be made, $+4$ should not be extracted in the early stages of its eruption.

Knowledge of the canines' positions and the existence of the premolars is of great importance in serial extraction. If the canines lie in a normal, slightly mesially-inclined labial position, a self-improvement of the laterals positions is very likely, as well as a good result for the canines. If, as sometimes happens, the canines have extreme mesial inclination with the crowns labial to, and in contact, with the roots of the laterals, fig. 6 A, self regulation of the laterals is hereby partially or completely hindered. In spite of this situation, the final eruption position of the canines, is, however, often improved by serial extraction. Although the adjustment effect of serial extraction in these cases may be limited, there is, however, no direct contraindication, unless the permanent canines are impacted in such difficult positions that they are not very likely to be moved into position.

In cases of diastema between the central incisors and also crowded erupting laterals, serial extraction should not be performed before the diastema is corrected, fig. 6 B, since the loss of the deciduous canines will increase the diastema. Extraction of the deciduous canines is unsuitable in cases of diastema between the lateral and central incisors, fig. 6 C. Serial extraction is less effective in a deep bite where the lower incisors bite onto the gingiva palatal to the upper incisors, fig. 6 E.

The serial extraction method is very adaptable for crowded or bunched incisors of the maxillary arch, fig. 8, 14, especially in Angle's class II distal occlusion, with a crowded protruding maxil-

Extrac. of 0.3+ at 9 yrs. slightly improved the extreme rotation of the erupting 2+. 4+ 5- were extracted to permit the downward growth of 3+ and to improve the crowded position of 3-; this was done even in order to improve the cross-bite of the right premolars, and with a grinding off of the cusps of 6+ 6-, the cross-bite on the right side was completely corrected. The distance 6+ \longleftrightarrow +6 increased 2.5 mm. model A \rightarrow C; 6- \longleftrightarrow -6 = A \rightarrow C. Extrac. of -4 effected an improvement of -3. Unfavorable position of +3, would take too much time for correction by appliance treatment even after X +4, satisfactory position of +2 and +4. Therefore +3 was extracted. The height of the bite was not notably changed. 3+ +3 erupted at their normal time, and there was no sign of retarded eruption because of the early extraction of 0.3+ +0.3.

A

B

C

D

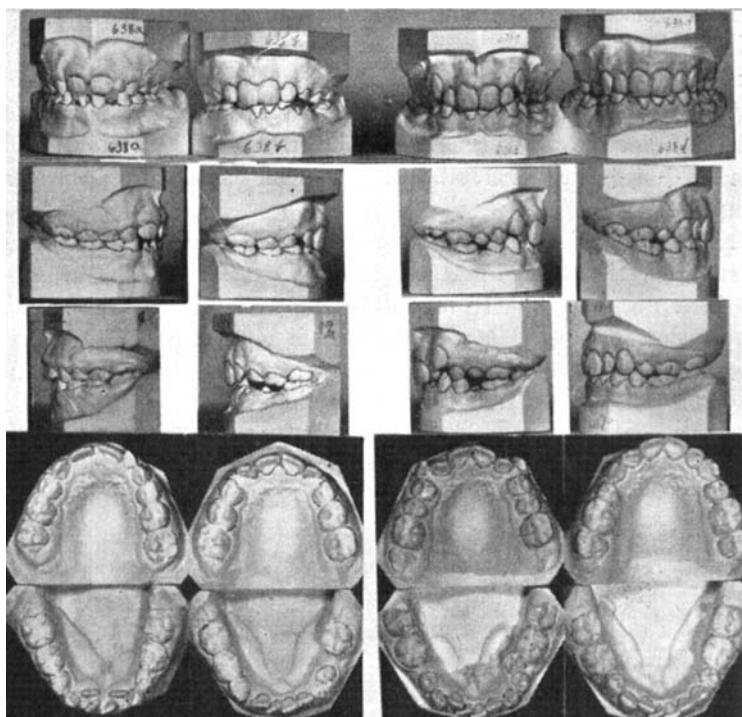


Fig. 10.

E 638. B. S-d. ♀ 7—13 yrs. Contr. upper and lower arches open-bite tendency, Rt. neutr. occl., Lt. neutr. occl.

1936, Dec., *model A*, 7½ yrs. Extremely crowded lower incisors.

1937, Sept., diastema 1+ +1 corrected. +2 in crowded eruption position. X +0.3, -0.3.

1938, April, 2+ erupting labially, X 0.3+, 0.3—.

1939, April, *model B*, 9½ yrs. 2+ +2, 2— -2 nearly normal.

1940, May, 4— 3— erupting. X 0.5—.

1941, May, *model C*, 11½ yrs. Some recurred crowding of incisors. 3+ +3 erupting, X 4+ +4.

1941, Nov., 3+ +3 norm. X -5.

1942, May, X 5—.

1942, Nov., *model D*, 13 years.

Extr. of +0.3 and -0.3 at 8 years, 0.3+ 0.3— at 8½ yrs., which eased the eruption of 2+ +2 so that they assumed normal positions, and improved the position of 2— -2. The transv. distance between 2— -2 increased 6 mm., *model A* → *B*. Tendency toward crowded incisors recurred and increased with the eruption of 3±3. Extr. of 4+ +4 effected a nearly normal growth of 3+ +3, whose eruptions were not delayed through the early extr. of 0.3+ +0.3. Extr. of 5— -5 somewhat improved the lower incisors. Transv. distance from 6+ ↔ +6 remained unchanged, *model A* → *C*, and decreased 1.5 mm. *C* → *D*, 6— ↔ -6 unchanged, *A* → *C*, and decreased 1.5 mm. *C* → *D*, and the bite was fundamentally lowered. Further X 1— or 2— can be considered at adult age.

A

B

C

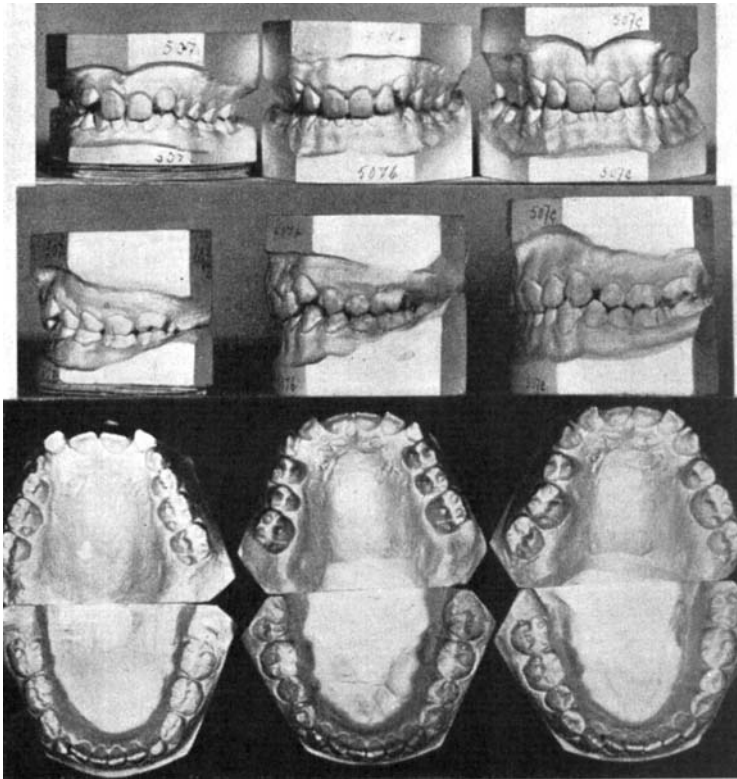


Fig. 11.

E 507. B. S-f. ♀ 10—16 yrs. Contr. upper arch. Rt. distal occl. $\frac{1}{2}$ cusp. Lt. distal occl. $\frac{1}{2}$ cusp.

1936, Oct., *model A*, 10 yrs. X 0.3+ +0.3.

1938, March, 2+ +2 norm. X 0.4+ +0.4.

1940, March., *model B*, 13 $\frac{1}{2}$ yrs. X 4+ +4.

1940, Nov., 3+ +3 grown into place.

1942, Jan., *model C*, 16 yrs.

Extraction of 0.3+ +0.3 at 10 yrs. effected an improvement of the protruded position of 2+ +2. X 4+ +4 effected a normal downward growth of 3+ +3. A mesial drifting of 6+ 5+, +5 +6 from a cusp occlusion (of distal $\frac{1}{2}$) to a full distal occl. relation (of d l), occurred, which was favorable in this case, and filled the spaces left by 4+ +4. The height of the bite was unchanged. Transv. distance 6+ \longleftrightarrow +6 = model A \rightarrow B, decreased 3 mm. B \rightarrow C, in connection with the mesial drifting. The somewhat delayed eruption of 3+ +3 was relatively normal in this case of generally late changing of the teeth. No tendency to retention (impaction) of 3+ +3 by the early extraction of 0.3+ +0.3

A

B

C

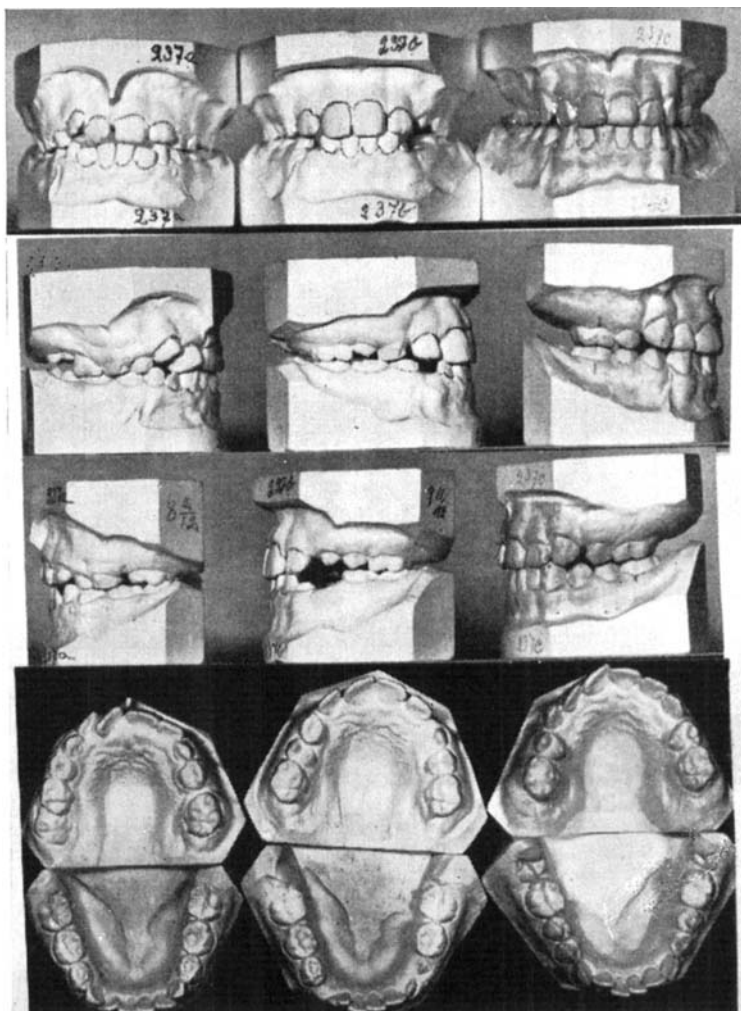


Fig. 12.

E 237. K. S-d. ♀ 8—13 yrs. Contr. of upper arch. Rt. neutr. oocl. Lt. distal oocl. 1 cusp. Open-bite tendency.

1936, June, *model A*, 8 yrs, X 0.5+, 0.3+, +0.3, 0.3—.

1937, March, 2+, 1+ improved, diastema 1+ +1 increased. Frenum op.

1938, March, *model B*, 10 yrs. 1+ 2+ norm. X 0.4+, 0.4—.

1940, March, 3+ +3 nearly beginning eruption X 4+.

1940, Oct., X +4.

1941, Aug., *model C*, 13 yrs. 3+ +3 grown into place.

Extr. 0.3+ at 8 yrs. effected a fundamental improvement of the positions of 2+ 1+. X +0.3 to avoid deviation of the median line of the upper arch. Extr. 4+ +4 effected downward growth of 3+ +3. Bite was somewhat lowered. 3+ +3 erupted at the normal age, and were not retarded by the early extr. of 0.3+ +0.3.

A

B

C

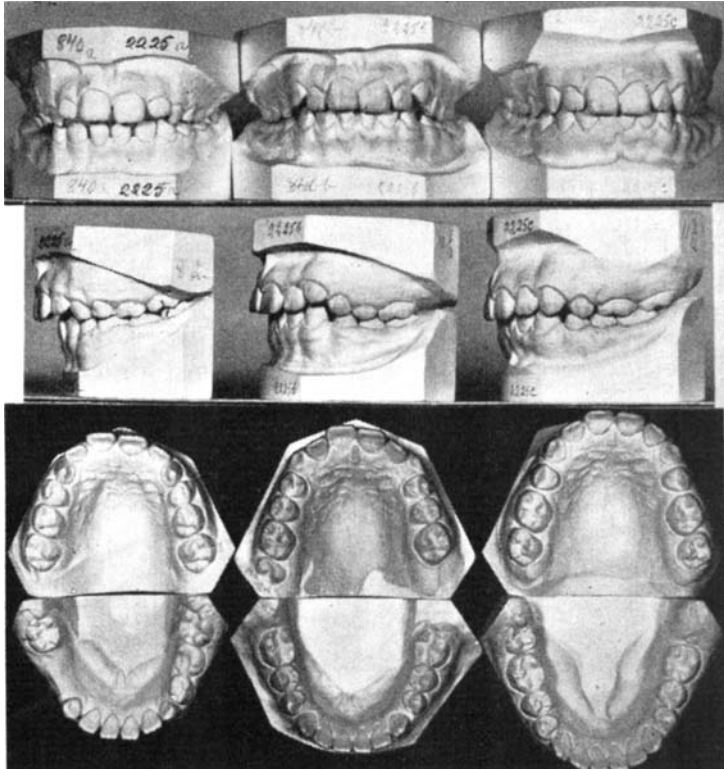


Fig. 13.

E. 2225. K. S.-m. ♀ 8—12 yrs. Contr. upper arch. Upper protrusion. tendency of open-bite. Rt. distal 1 cusp, Lt. distal 1 cusp.
 1938, Sept., *model A*, 8 yrs. X 0.3+ +0.3.
 1939, April, protrusion and open-bite somewhat improved.
 1941, May, *model B*, 10½ yrs. 3+ +3 partially erupted. V 5+ +5.
 1942, June, *model C*, 12½ yrs. Spaces left by 5+ +5 are closed, and 3+ +3 are normal.

Extraction of 0.3+ +0.3 at 8 yrs. effected a decreased prognatism, and improvement of the crowded position of the upper incisors, and of the open-bite tendency. Early erupt. of 3+ +3 i. e., no retarding due to premature extr. of 0.3+ +0.3. Extraction of 5+ +5 effected full correction of 3+ +3.

lary arch, where the bite is not too deep (not below the cingulum) and with no crowding of the teeth in the lower arch. Here serial extraction needs only be performed in the upper arch.

Cases of protruding and crowded upper arch, especially with an open bite, are often much improved, fig. 13. If these patients are

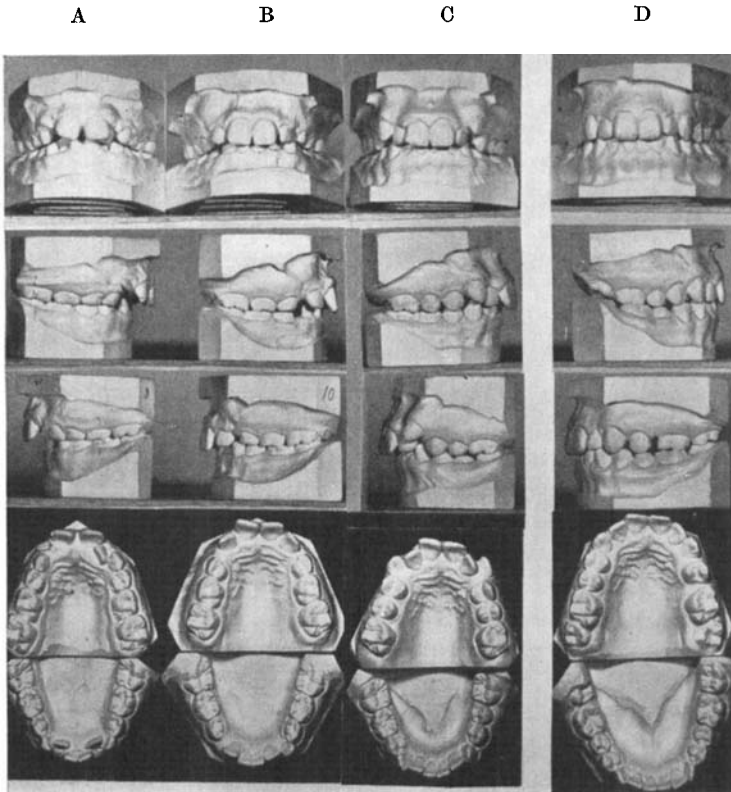


Fig. 14.

Kj. 313 S. B-g. ♀ 8—13 (15) yrs. Contr. upper and lower arches. Upper protrusion.

Rt. distal 1 cusp. Lt. distal 1 cusp.

1930, Aug., *model A*, 8 yrs. X 0.3+ +0.3.

1931, 2+ +2 improved. X -0.3.

1932, *model B*, 10 yrs. 2+ +2, 2-- -2 nearly normal.

1935, Sept., *model C*, 13 yrs. (Decided upon treatment with appliances X + 5, unfavorable position of +3.)

1937, *model D*, 15 yrs. After treatment with appliances.

Extr. of 0.3+ +0.3 effected significant improvement of position of upper incisors, and decreased the protrusion. Maintained molar relations, no noticeable forward drifting of +0.4+, +0.5+, +6+ after X 0.3+ +0.3. Erupt. of 3+ +3 not retarded by premature extr. of 0.3+ +0.3. Position of +3 unfavorable for treatment by serial extraction alone, therefore supplementary appliance treatment was used. Transv. distance 6— ←→ —6 unchanged A → C.

thumb-suckers, extractions of the deciduous canines often seems to help in breaking this habit.

In cases of bimaxillary contraction of neutroclulsion type, the method can be employed in both jaws, but it is here desirable to perform the extractions in the lower jaw somewhat later than in

A B C D

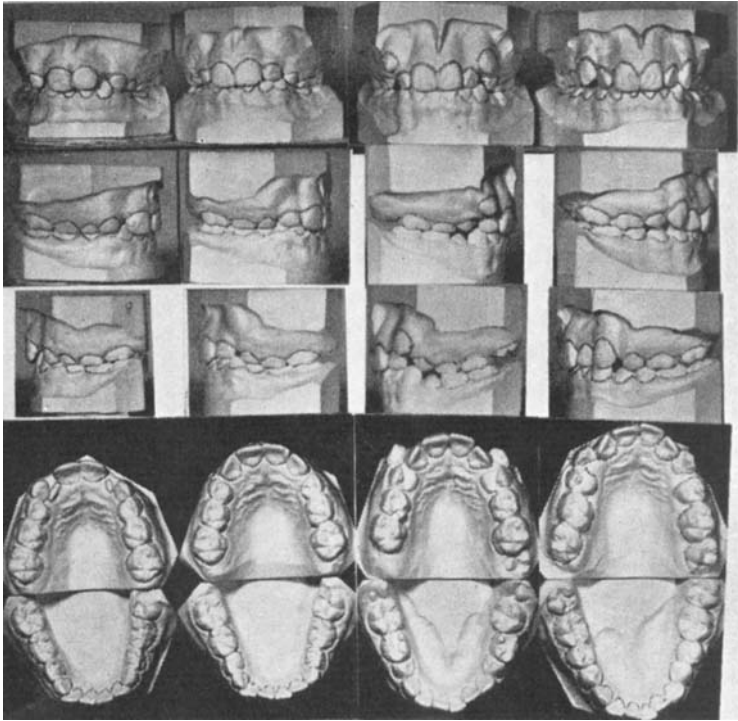


Fig. 15.

Kj. 425. E. L-m. ♀ 8—13 yrs. Contr. upper arch Rt. distal $\frac{1}{2}$ cusp Lt. distal 1 cusp.

1931, Nov., *model A*, 8 yrs. Palatal eruption of $2+ +2$, X $0.3+ +0.3$. Improvement of $2+ +2$ was noticeable after 2 weeks.

1933, March, *model B*, 10 yrs. $2+ +2$ drifted into labial positions.

1934, Oct., X $0.4+ +0.4$.

1935, June, *model C*, $11\frac{1}{2}$ yrs. X $4+ +4$.

1936, Aug., *model D*, 13 yrs. $3+3$ improved but still in somewhat labial positions.

Extraction of $0.3+ +0.3$ effected very rapid labial wandering of the palatal erupting $2+ +2$, increasing the transverse distance $2+ \leftrightarrow +2$ 8 mm., model A \rightarrow B, partly recurred contraction, 2 mm., B \rightarrow C. Mesial drifting $6+$, $0.5+$, $0.4+$ is hardly noted model A \rightarrow B, but there is definite drifting of $6+$ from an occlusion of distal $\frac{1}{2}$ cusp to full distal occlusion, model B \rightarrow C. No noted drifting on the left side after X $+0.3$, $+0.4$ model A \rightarrow D. Eruption position of $3+ +3$ rather unfavorable for normal downward growing development even after X $4+ +4$. This should have been supplemented with appliance treatment or also X $3+ +3$, and eventually some lower extr. should have been considered instead of X $4+ +4$. Eruption of $3+ +3$ was not retarded by premature extr. of $0.3+ +0.3$. Trans. distance $6\pm \rightarrow \pm 6$ unchanged. A \rightarrow C.

A

B

C

D

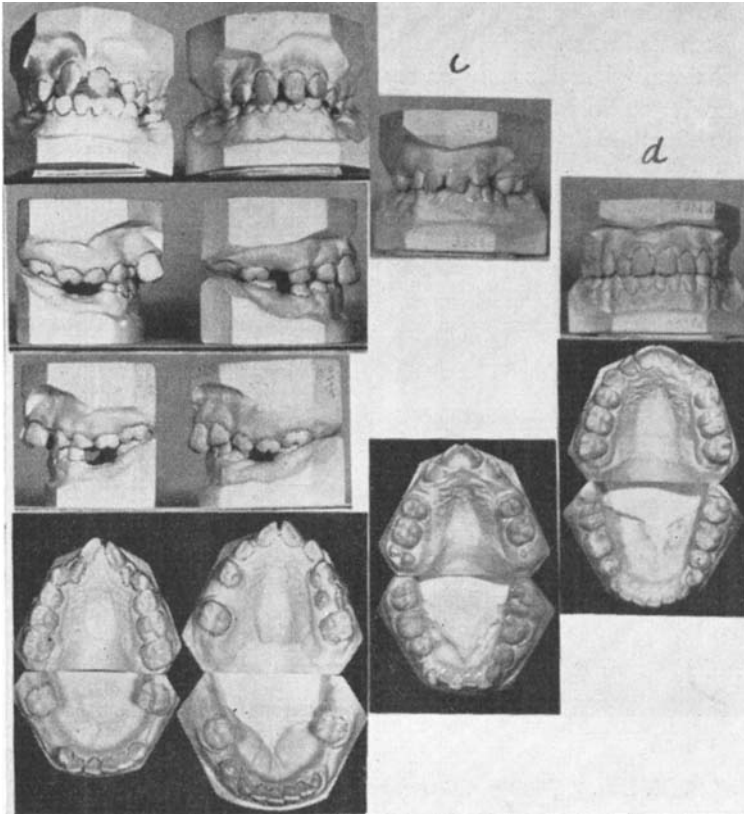


Fig. 16.

E 3038. D. H-n. ♀ 8—12 yrs. Extreme contr. transv. upper arch. Rt. neutral occl.
Lt. neutral occl.

1939, May, *model A*, 8½ yrs. X 0.3+ +0.3.

1939, Oct., 2+ +2 in labial position, diastema 1 mm.

1940, Oct., *model B*, 10 yrs. Expansive transverse growth 2+ ↔ +2 10 mm.

1943, Feb., *model C*, after X 4+ +4, 4—. Appliance treatment (twin arch).

1945, *model D*, result of appliance treatment.

Extraction of 0.3+ +0.3 effected fundamental improvement of 2+ +2 positions, with the trans. distance 2+ ↔ +2 increased 10 mm. in 1½/12 yr. Serial extraction was intended as a precedent for appliance treatment. 3+ +3 were not retarded by premature extr. of 0.3+ +0.3.

the upper jaw. Since the occlusion pressure in a normal overbite acts contracting upon the mandibular arch, opposite to the maxillary arch, and it is unnecessary to risk weakening the lower arch.

Early serial extraction in the lower jaw alone can often be of

A B D E

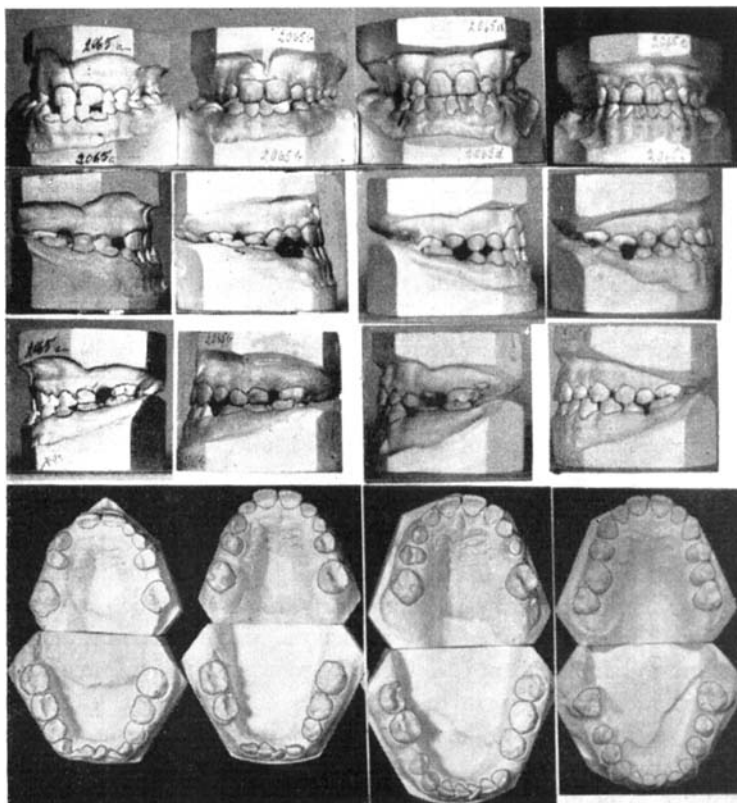


Fig. 17.

- E 2065. V. E. L.-g. ♀ 8—15 yrs. Progenia. Contr. upper and lower arch Rt. mesial oocl. $\frac{1}{2}$ cusp. Lt. neutral oocl. cross-bite rt.
- 1938, May, $7\frac{2}{12}$ yrs. model A. X 0.4— 0.3— —0.3.
Grinding off of 0.5— against cross-bite.
- 1939, Aug., model B, 9 yrs. Fundamental improvement of incisive oocl. Transv. development of upper arch, and some sagittal shortening of the lower arch.
- 1940, Sept., —3 erupting. X —0.4.
- 1941, Sept., 2+ +2, 3— —3 nearly normal. Grinding off of 6+, 6—. (Model C excluded.)
- 1942, Aug., model D. 12 yrs. X —0.5.
- 1943, May, +5 palat. erupt. X +6, —6.
- 1943, Dec., +5 norm. 5— in crowded erupt. position. X 6—.
- 1944, Sept., 5+ in completely palat. erupt. X 5+.
- 1945, Oct., model E, 15 yrs.
- Extraction of 0.3— —0.3 effected a spreading and lingual retrusion of the lower incisors, which were held in labial crowded position by 0.3— —0.3. Considerable transverse development of the upper arch followed, which should have eased, by doing a way with the inversion on the right side by a grinding off of 6 ± 0.5 — and X 0.4—, 0.3—, —0.3. Eruption of 3— —3 was not retarded by the premature extr. of 0.3— —0.3. Extraction of the deciduous lower teeth should have aided in evening out the tendency to progenia.

real therapeutic value in class III malocclusion with crowded tooth condition in the mandibular arch, fig. 17.

Crossbite can to a certain extent be helped by serial extraction through removal of deciduous lower canines locked by inversion, and finally by extraction of relatively non-antagonizing premolars on the cross-bite side, fig. 9 and 17.

Serial extraction will help both in closing an open-bite and relieving crowded position of the incisors which may be existing in an open-bite case.

Premature loss of deciduous teeth, especially of the deciduous canine, is sometimes reported in literature as the cause of retention of the corresponding permanent tooth. Experience from a great number of cases of serial extraction, does not, however, support this idea.

Very premature loss of a deciduous tooth, several years before the normal eruption time of its successor, often seems to give it less probability of normal eruption, even though the loss of the tooth did not result in a loss of space. Such an early loss slows up and often hinders the eruption, probably because it is more difficult for the anlage of the permanent tooth to resorb and push through the now scarred and rather compact bone and mucous membrane barrier, than to resorb the root of the deciduous tooth. This is more often true of premature loss of lower deciduous molars, compare fig. 8. Very early loss of upper deciduous incisors, especially the central incisors, often results in a "leathery" hardening of the gingiva, caused from biting on it, which hinders the eruption of the permanent incisor.

If the deciduous tooth is lost only about a year before the normal time of eruption of its permanent successor, according to clinical experience, the eruption is not retarded, but on the contrary, the process is speeded up through the opening which is hereby provided, and the respective permanent tooth has an earlier eruption than would otherwise be the case. This is true of all deciduous teeth. Such an induced eruption is confirmed by the strong eruption promoting effect, obtainable by the resection of the covering tissues formed after a very premature loss of a deciduous tooth, where otherwise the succeeding tooth would be retarded or hindered. This effect is most often noticed in the resection of tissues over a lower premolar which is retarded in erupting.

The early extraction of the deciduous canine, 3—4 years before the normal shedding time, in here related, and in many other

cases, has not shown to be accompanied by the obvious corresponding retarded eruption that premature loss of deciduous molars would have. The reason seems to be that the permanent canine in these cases of constricted jaw usually does not erupt on the crest of the alveolar process where the deciduous canine stood, and where some scar tissue can have formed after the extraction. The eruption point for the canine in these cases, which is to some extent true even in normal cases, lies relatively high on the labial surface of the alveolar process, where there, of course, can be no obstructing scar tissue caused by the extraction of the deciduous canine.

In opposition to the extraction of the deciduous canines in the constricted arches here designated, at 8—10 years of age, can even be stated that this should supposedly contribute to a greater contraction of the arches. Measurement of a number of cases, however, shows that no contraction of the transverse distance between the deciduous molars or first permanent molars can be observed. In the anterior portion of the arches, on the contrary, in favorable cases, there seems to be a measurable increase in width, even after extraction of the deciduous canines, and often after this extraction there is a rapid transverse increase in width between the lateral incisors. The space after the extracted deciduous canines is completely or partially filled by the erupting laterals which are now free to drift out of a crowded position, if the crowns of the permanent canines do not hinder the process, fig. 8, 10, 12, 14, 15, 16. In this connection, the incisor portion of the dental arches can greatly increase in width, even up to 10 mm., fig. 16.

Objection to the simple therapy of serial extraction may be that it does not attempt to reach fully normal occlusion, but aims at a result with a sacrifice of 2—4 teeth, usually the first premolars. Experience with purely orthodontic expansion treatment, however, shows the prognosis is very doubtful when attempting to maintain the full dentition; very often contraction recurs. The modification that consists of a combination of orthodontic movement of the crowded teeth, and extraction of some suitable tooth, usually the premolars, for acquiring space without proper expansion, has therefore, more and more, become the applied treatment plan. It is the one that gives most certain prognosis for a lasting result. By means of this treatment which usually begins after, or at the time of the eruption of the permanent canines, *i.e.* 11—13 years of age, results can be attained which are both esthetically and functionally acceptable. Similar and, at times equally good

results can, however, be attained through serial extraction without appliance treatment, fig. 8. In other cases, serial extraction provides a simplification and a fundamentally facilitated condition for the supplementary appliance treatment which must follow, fig. 14, 15, 16.

Correction of occlusion anomalies constitutes an exceedingly large problem in the modern age, which can impossibly be solved through appliance treatment alone. The modern person, at least those of Northern European race, seem to be more and more afflicted with a congenital tendency toward anomalies of the common contraction type, and as a result, nearly $\frac{1}{4}$ of all children are in need of some auxiliary treatment to improve the occlusion functionally and esthetically. Consequently, the entire need of treatment is and will be very extensive. Every facilitation of the therapy problems should, accordingly, have a significant social value. Therefore, the therapeutic intervention, here discussed and widely experienced, ought to have some value in the treatment of occlusion anomalies. Even the private practising dental orthopedist may find these viewpoints to be of important value, since they give a possibility of treating a large number of cases, without the need of choosing between two alternatives: either to attempt to carry out a long-lasting, risk-involving, detailed treatment, or no attempt at improving the malocclusion.

Summary.

According to experience, malocclusions characterized by crowding of the teeth and contraction of the jaws usually can not be treated with lasting results without reduction of the number of teeth. In some of these cases acceptable results can be obtained just by extractions even without the use of appliances. In order to direct the development of the occlusion in contraction cases along the most favourable lines, it is suitable to plan for the advisable or necessary extractions at an early age. The extractions will concern at first certain deciduous and later some permanent teeth. This line of extraction treatment is called serial extraction by the author, who has practiced the method for about 20 years. A serial extraction is usually performed in the following way. If in a contraction case the incisors, particularly the laterals, are erupting in crowded and distorted positions, extractions are

made of the deciduous canines. This treatment will, in well diagnosed cases, result in a very clear improvement of the incisor positions. Some year later extraction of the first deciduous molar might be done to facilitate and speed the eruption of the first premolar. At the time of the eruption of the permanent canines an extraction of some permanent tooth usually the first premolar is made, which will facilitate the normal eruption of the canines. The serial extraction method is practised in both jaws in cases of bimaxillary contraction, Class I. In Class II cases with contraction and protrusion of the upper jaw, it is employed in the maxillary arch. In cases of Class III characterized by crowding of the lower incisors, serial extraction is used with good results in the mandibular arch. The serial extraction method is more suitable in cases of normal overbite or even open bite than in cases of deep overbite. According to experience it does not cause impaction or retardation of eruption of the canines. Serial extraction is many times a suitable preliminary treatment in cases which are planned to get finally treated by appliances and it will often greatly facilitate this later treatment.

The author illustrates the serial extraction method by a casuistic including treated cases of different types.

Bibliography.

ANDRÉSEN: Gnatologisk empiri, Svensk Tandläkare Tidskrift 1945. — J. MC COY: Applied Orthodontia 1922. — I. KORKHAUS, NEUMAN: Kieferwachstum während des Schneidezahnwechsels. Fortschritte der Orthodontik 1931. — O. NORBERG: Käkskelettets phylogenes och ontogenes. Svensk Tandläkare Tidskrift 1925. — C. M. SEIPEL: Variation of tooth position. Svensk Tandläkare Tidskrift 1946. Supplementum.

Address:

Eastman Institut

Stockholm

Sweden