



REVIEW ARTICLE



## Clinical management of fusion in primary mandibular incisors: a systematic literature review

Sara Bernardi<sup>a</sup> , Serena Bianchi<sup>a</sup>, Guglielmo Bernardi<sup>b</sup>, Jörg Philipp Tchorz<sup>c</sup>, Thomas Attin<sup>d</sup>, Elmar Hellwig<sup>e</sup> and Lamprini Karygianni<sup>d</sup> 

<sup>a</sup>Department of Life, Health and Environmental Sciences, University of L'Aquila, L'Aquila, Italy; <sup>b</sup>Private Dental Practice, University of L'Aquila, L'Aquila, Italy; <sup>c</sup>Department of Operative Dentistry, Periodontology and Endodontology, University of Dental Medicine and Oral Health, Danube Private University (DPU), Krems-Stein, Austria; <sup>d</sup>Clinic for Conservative and Preventive Dentistry, Center of Dental Medicine, University of Zurich, Zurich, Switzerland; <sup>e</sup>Department of Operative Dentistry and Periodontology, Center for Dental Medicine, Medical Faculty, University of Freiburg, Freiburg, Germany

### ABSTRACT

**Objective:** Dental anomalies occurring in deciduous teeth can affect the eruption of the permanent dentition and the occlusion stability. The occurrence of dental anomalies such as double teeth during the primary dentition in the daily practice might be frequent. The study aimed to qualitatively summarize the therapeutic management of double teeth in primary incisors.

**Material and Methods:** A systematic review regarding the therapy of primary fused incisors in the mandible was performed and the obtained data were assessed according to Preferred Reporting Items for Systematic Reviews and Meta-Analyses guidelines. The following electronic databases were screened from 1st January, 1996 until 30th July, 2019: PubMed, Scopus, EBSCO and the archives of paediatric dental journals. The search terms were grouped in anatomic entity: (*tooth OR teeth OR incisor*), pathological condition: (*fused OR fusion OR geminated OR double*), intervention: (*treatment OR intervention OR therapy OR prevention OR control OR management OR restoration*), observed parameters: (*primary dentition OR primary tooth OR primary teeth*).

**Results:** Ten articles met all inclusion criteria. The data disclosed the occurrence of double teeth in mandibular incisors. The main management of this clinical condition is either preventive or surgical involving the extraction of fused teeth, based on the deciduous nature of the teeth, the degree of caries and malocclusion development risk.

**Conclusion:** An early diagnosis of dental anomalies is fundamental for the application of proper preventive strategies to avoid a potential malocclusion in permanent dentition and to maintain these teeth sound and caries-free until the eruption of the permanent dentition.

### ARTICLE HISTORY

Received 16 November 2019  
Revised 30 January 2020  
Accepted 19 February 2020

### KEYWORDS

Primary dentition; dental anomaly; fused tooth; double tooth; prevention

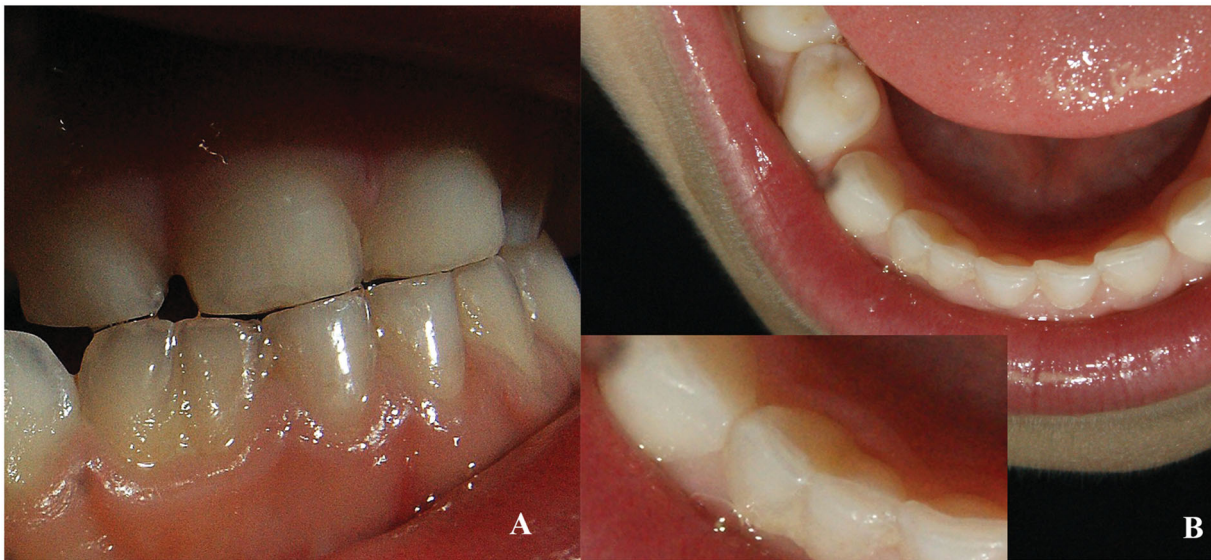## Introduction

Tooth anomalies are a class of dental disorders affecting the dental teeth both in primary and permanent dentition [1]. The aetiology of dental anomalies has not been fully understood yet. However, environmental and genetic factors can be considered as basic contributors to the manifestation of dental anomalies [2–4]. Based on their type, they can be distinguished in anomalies in structure (amelogenesis imperfecta, dentinogenesis imperfecta, enamel hypoplasia), anomalies in number (hypodontia, hyperodontia), anomalies in size (microdontia, macrodontia), anomalies in eruption (transposition, delayed or anticipated timing of eruption), and anomalies in shape (concrecence, gemination, fusion, dilaceration, double teeth) [5,6].

The anomalies of shape are the most frequent class of anomaly a general dentist can encounter in the daily practice. The dental anomaly named as double tooth (Figure 1) derives from the fusion of two or more adjacent tooth germs

during the embryological period. If the fusion is complete, the crown appears clinically large, without any substantial groove. In this case, the pulp chamber is not different from common teeth. If the fusion is incomplete, the crown appears with a separating groove mainly situated on the vestibular surface [7]. The pulp chamber in case of an incomplete fusion can appear bifid or separated [8].

The term 'double tooth' is a general term to indicate the clinical presentation of an anomaly of the crown morphology. However, the pathogenesis of this anomaly called either 'gemination' or 'fusion' can be attributed to two different pathogenic mechanisms. According to the Mader's two tooth rule [9], if the tooth presenting the anomaly is counted as 'two teeth' and the consequent teeth quantity in the dental arch is normal, then the anomaly is called 'fusion'. If the abnormal tooth is counted as 'two teeth' and the resulting number of teeth in the dental arch is higher than normal, then the anomaly is called 'gemination'. In order to avoid confusion in the present review, we want to point out that



**Figure 1.** Clinical presentation of a fused primary tooth (82). (a) Vestibular view. (b) Occlusal view

the term 'double teeth' was used to indicate the shape anomaly of the conjoined teeth and not the underlying pathogenic mechanisms.

Although the aetiological factors of the fused or double teeth are not fully understood, diverse genetic and physical forces (e.g. traumas) seem to play a fundamental role in the tooth germs fusion [5]. This clinical anomaly can be also a secondary appearance of various syndromic disorders, such as chondroectodermal dysplasia, focal dermal hypoplasia, achondrodysplasia, median cleft facial syndrome, oral-facial-digital syndrome, otodontal dysplasia and Russel-Silver syndrome [10].

As far as the prevalence, pattern and clinical presentation of double teeth is concerned, this type of dental anomaly can involve both primary and permanent teeth, but its incidence has been found to be higher in anterior primary teeth [11]. More specifically, the geminated teeth occurred more in the mandibular primary incisors, unilaterally and bilaterally [12].

In literature, there are few reports on the incidence [13] and management [6,8] of primary fused teeth. The reason is due to the temporary nature of the primary teeth which are usually extracted in case of complications, and thus, no evidence of possible treatment modalities has been reported so far. As reported by Guimarães Cabral et al. the assessment of the presence of the double teeth is important in relation to the associated clinical problems such as caries, delay in the exfoliation, impaction of the subsequent permanent teeth, presence of supernumerary teeth, presence of permanent double teeth, aplasia of the correspondent permanent teeth and tooth misalignment, with a predisposition to a future malocclusion [12]. Indeed, the anterior teeth play a key role in the morphological development of the jaws and the facial type [14,15]. Finally, a systematic review was conducted in order to qualitatively summarize the therapeutic management of double teeth in primary incisors. To the best of our knowledge, this is the first systematic review of the treatment options of double anterior teeth in the primary dentition.

### Search strategy

In order to search for relevant reports on fused anterior teeth in the primary mandibular dentition, the following electronic databases were screened from 1st January, 1996 until 30th July 2019 in order to detect eligible papers: PubMed, Scopus and EBSCO as well as the electronic archives of the following paediatric dental journals: International Journal of Paediatric Dentistry, Paediatric Dentistry, Journal of Dentistry for Children, as well as Journal of Indian Society of Pedodontics and Preventive Dentistry. The Journals Clinical Paediatric Dentistry, European Journal of Paediatric Dentistry and European Archives of Paediatric Dentistry were pre-screened but not taken into consideration since they contained solely epidemiological studies on geminated teeth.

### Search terms

The search terms for retrieving articles related with fused teeth in primary dentition were divided in the following groups: anatomic entity: (*tooth OR teeth OR incisor*), pathological condition: (*fused OR fusion OR geminated OR double*), intervention: (*treatment OR intervention OR therapy OR prevention OR control OR management OR restoration*), observed parameters: (*primary dentition OR primary tooth OR primary teeth*).

### Criteria for study selection

Reports included in the present review consisted of randomized controlled trials (RCTs), as well as all other types of clinical studies, such as clinical reports (case series, case reports), and retrospective studies. Only reports regarding solely fused primary incisors and eventual fusion with the canines in case of lateral incisors in mandibular jaws were included in this systematic review. Other literature- and systematic reviews, abstracts and conference proceedings were excluded. Furthermore, studies relating to other dental anomalies or

not referring to the occurrence and/or therapy of fused teeth were filtered out of this review. Finally, case reports on fused permanent incisors/molars, fused primary molars and maxillary incisors were not taken into account.

### Study selection

Two independent examiners (SB, LK) conducted the primary literature research using the main search terms. The same researchers re-evaluated the selected titles and abstracts in a second screening round, in which the studies not adapting to the established eligibility and inclusion principles were omitted. Subsequently, the remaining reports were introduced into a third screening round, in which the full-text articles were further appraised for compatibility. In case of any disagreement between the examiners after independent evaluation, consensus was reached by re-evaluation and discussion. In the event of discrepancies in the data, when possible, reference paper authors were contacted by email, for further explanation. The remaining studies were finally introduced into the final review step of qualitative synthesis.

### Data organization

The data were systematically listed in a standard document containing the authors' names, year of publication, study design, involved teeth with dental anomaly, type of intervention, main outcomes and conclusions. The dental libraries of the Universities of Zurich (Switzerland), Freiburg (Germany), and L'Aquila (Italy) were used for further interpretation of the extracted data when required. Furthermore, to guarantee the validity of the extracted data, the selected source studies were evaluated twice. No further classification was necessary because of the small number of the selected studies.

### Data quality evaluation

In order to evaluate the yielded data the guidelines of the Preferred Reporting Items for Systematic Reviews and Meta-Analyses (PRISMA, (<http://www.prisma-statement.org/statement.htm>)) were applied [16]. Two independent examiners (SB, LK) were responsible for systemising the extracted data and assessing their quality to limit probable inconsistencies.

### Assessment of methodological quality

The quality assessment of the studies' methodology was performed by two independent reviewers (SB, LK.) according to the methodological assessing tool designed by Murad et al. [17]. A quality score was given according basing of the fulfilment of the tool requirement. If all of the domains were fulfilled (Table 1) the study would be classified as 'good quality'; if three of the domains were fulfilled the study would be classified as 'fair quality'. If only two or one of the domains were fulfilled the study would be classified as 'poor quality'.

**Table 1.** Table-tool used for the evaluation of the methodological quality of case reports and case series [17].

Domains	Leading explanatory questions
Selection	1. Does the patient(s) represent(s) the whole experience of the investigator (centre) or is the selection method unclear to the extent that other patients with similar presentation may not have been reported?
Ascertainment	2. Was the exposure adequately ascertained? 3. Was the outcome adequately ascertained?
Causality	4. Were other alternative causes that may explain the observation ruled out? 5. Was there a challenge/rechallenge phenomenon? 6. Was there a dose-response effect? 7. Was follow-up long enough for outcomes to occur?
Reporting	8. Is the case(s) described with sufficient details to allow other investigators to replicate the research or to allow practitioners make inferences related to their own practice?

### Study selection process

The study selection process followed the PRISMA workflow, as showed in Figure 2. After running searches through the selected databases, a total number of 107 relevant articles was detected. After discarding the duplicates, 100 articles were further screened by title and abstract. A total of 83 full-text articles were then excluded for not meeting the inclusion criteria. Seventeen eligible studies published from 1998 until the 2019 were examined during the final review step and finally ten studies were selected [12,18–26]. Summarized information on the selected reports is listed in Table 2.

## Results

### Methodology assessment

Nine of the ten studies were classified as fair quality and only one fulfilled all of the domains. Indeed, the majority of the papers missed a reasonable follow-up and only one reported specifically the follow-up's details (Table 3).

### Qualitative synthesis

In this review, only journals reporting the clinical treatment of the primary double teeth were considered. The ten selected reports describe cases of fused mandibular incisors as well as their clinical treatment. From the qualitative synthesis of the articles, it appears that depending on the presence of caries on the fused teeth, the selected treatment approach had either a preventive [22,24–26] restorative [25] or surgical (extraction) nature [21,24]. When the involved tooth was caries-free or considered to be at low caries risk, preventive measures such as recall programmes with specific intervals e.g. every 3 months, restoration of the grooves or fluoride application were chosen. When the fused tooth was affected by caries, caries removal and restoration with a composite filling was conducted. When the tooth caused orthodontic disorder such as crowding, the extraction of the tooth was performed independently of the caries risk.

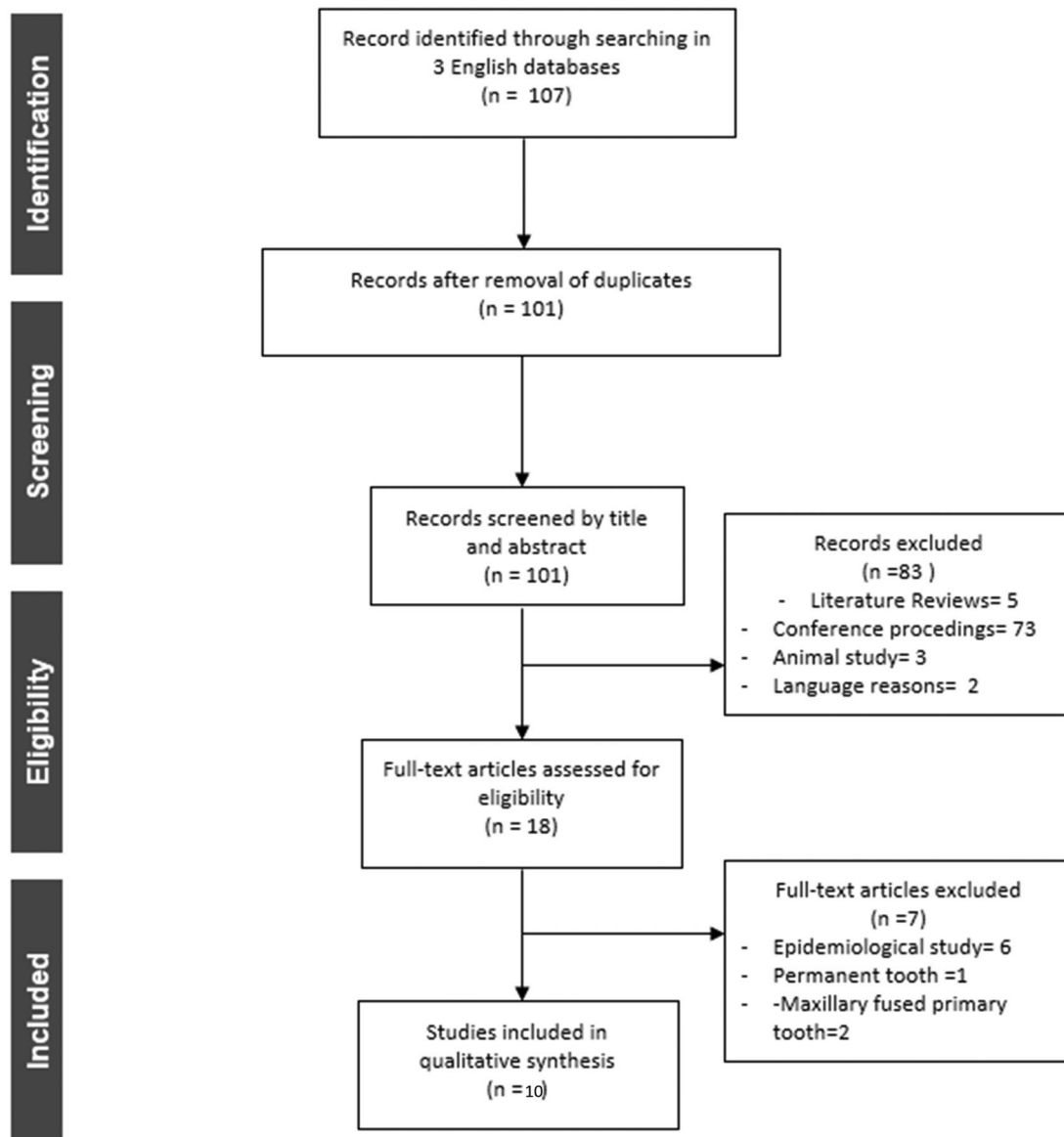


Figure 2. Flowchart of the search strategy, study selection and data management procedures.

### No approach

A total of six studies [12,19,20,23–25] reported the diagnosis of the anomaly and primarily focussed on the increase of awareness of the parent or the guardian about this condition. This was mainly accomplished by providing general preventive advice. The diagnostic process was successfully reached by clinical observation and conventional radiographs (OPG, intra-oral periapical) [12,19,20,23,26] and model cast [23]. One study reported a unilateral triple fusion between two primary teeth and a supernumerary tooth [26]. Regarding the radiographic diagnosis, the degree of tooth mobility must be considered. In case the tooth mobility is progressive, the permanent tooth will substitute the primary tooth soon and therefore no additional measures must be taken.

### Preventive/restorative approach

A total of 4 studies [18,22,24,25] suggested the application of preventive measures. In particular, Alpöz et al. [18]

reported on topical application of fluoride. Tewari et al. [25] filled the very deep incisal groove with a flowable composite for the purpose of a preventive approach, and followed a 3-month recall programme. Sekerci et al. [24] also suggested the prophylactic filling of the deep grooves with flowable composite and the fluoride application as a further preventive approach. Again no specific fluoride concentration was mentioned in their report. Prabhu et al. [22] proposed the application of topical fluoride, specific dietary changes and periodic follow-ups as the preventive approach of choice. One study [25] reported a restorative approach regarding the treatment of fused primary incisors. A carious lesion was notable on the gingival third of the labial surface of the fused tooth 82–83. The treatment included the removal of the caries and restoration with flowable composite.

### Surgical approach

Two studies [21,24] suggested surgical treatment, namely extraction of fused teeth. Specifically, Milano et al. [21]

Table 2. Summary of the selected cases of fused primary incisors.

Study	Type of study	Tooth involved	Type of intervention	Follow-up time	Main Outcomes	Conclusions
Favalli et al. [20]	Case Report	83 73	Radiographic control	N/A	The involved teeth appeared larger in their mesiodistal dimension. A groove without any sign of caries was situated on the facial surface. Radiographic exams revealed a single enlarged pulp canal and bifid crown. Presence of a smooth, large clinical crown for each fused pair bilaterally.	Dental practitioner should be aware of eventual asymmetries. Multidisciplinary approach and accurate follow-ups are recommended.
Milano et al. [21]	Case Report and literature review	81–71	Radiographic control and eventual surgical therapy	N/A	Absence of the permanent lateral incisor. Radiographic examination showed that 81 and 82 had their pulp chambers individualised with normal size. Absence of the mandibular permanent incisor was diagnosed. Periapical radiographs showed the teeth roots had two separated pulp chambers.	Fusion anomaly can lead to malocclusion, caries and periodontal issues. In some cases the permanent teeth can miss. Fused teeth can induce malocclusion, caries and periodontal issues. The knowledge of the features of this dental anomaly and a correct diagnosis help to establish an efficient therapy plan.
Alpöz et al. [18]	Case Report	82–83 72–73	Topical fluoride application	N/A	congenital absence of the permanent mandibular lateral incisors	Fused teeth may cause malocclusions and aesthetic issues. Monitoring is recommended. Multidisciplinary approach is fundamental to successfully treat fused teeth.
Guimarães et al. [12]	Case Report	1st case 81–82 2nd case 81–82	Information of the mother about the optimal preservation of the primary teeth. Radiographic control Radiographic control	N/A	The fused large teeth had buccal and lingual vertical grooves. Permanent teeth were present. The periapical radiographs revealed the crowns and the roots of 72–73 and 82–83 were fused with complete fusion of their pulp chambers and root canals. Bilateral absence of 32 and 42 was detected. The crowns and the roots of 71–72 were fused with complete fusion of their pulp chambers and root canals. The fusion of 81–82 resulted in a common pulp chamber and separated root canals.	Early pulp exposure can derive from the presence of deep grooves in fused primary teeth. Conservative and preventive approach together with follow-ups are advised.
Chalakkal and Thomas [19]	Case Report	72–73 82–83	Radiographic control	N/A	Permanent 31 and 41 were absent. Missing permanent mandibular lateral incisors in three cases	Early and efficient diagnosis of the anomaly is of considerable importance.
Rajashekhara et al. [23]	Case Report	72–73 82–83	Radiographic control and diagnostic cast	N/A	Missing permanent mandibular lateral incisors.	Fused teeth may cause malocclusion and aesthetic issues. When the fused tooth hinders the eruption of the permanent successor, its extraction is advised.
Tewari et al. [25]	Case Report	1st case 72–73 82–83 2nd case 71–72 81–82	Caries removal from the labial surface of the 82–83. Restoration of 82–83 and filling of the grooves of 72–73 using flowable composite. topical fluoride application, dietary changes, and periodic follow-ups.	3-month-recall programme 3-month-recall programme	The radiographs showed the triple fusion of the involved primary teeth. Permanent teeth were present.	Fused teeth may result asymptomatic. However a monitoring period is necessary due to the risk of developing a further malocclusion.
Sekerci et al. [24]	Case report (6 patients)	Mandibular incisors	orthodontic consultation, Fissure sealing , and a topical fluoride application. In one case the tooth has been extracted. topical fluoride application, dietary changes, and periodic follow-ups.	N/A		
Prabhu et al. [22]	Case Report	72–73 82–83	Radiographic control	N/A		
Shanthraj et al. [26]	Case Report	71–5-72	Radiographic control	3 months follow up		

**Table 3.** Quality assessment of the evidence.

Study	Domains				Classification
	Selection	Ascertainment	Causality	Reporting	
Favalli et al. [20]	X	X	–	X	Fair Quality
Milano et al. [21]	X	X	–	X	Fair Quality
Alpöz et al. [18]	X	X	–	X	Fair Quality
Guimarães, et al. [12]	X	X	–	X	Fair Quality
Chalakkal and Thomas [19]	X	X	–	X	Fair Quality
Rajashekhara et al. [23]	X	X	–	X	Fair Quality
Tewari et al. [25]	X	X	–	X	Fair Quality
Sekerci et al. [24]	X	X	–	X	Fair Quality
Prabhu et al. [22]	X	X	–	X	Fair Quality
Shanthraj et al. [26]	X	X	X	X	Good Quality

The significance of 'X' is the paper fulfil the respective item of the Table-tool used for the evaluation of the methodological quality of case reports and case series.

proposed radiographic control and eventually the extraction of the fused teeth (81–82 and 71–72) to avoid any interference with the eruption of the permanent successor teeth. Sekerci et al. [24] chose the extraction as the treatment of choice in a case of a primary double tooth 81–82, mainly because of a deep caries lesion.

## Discussion

The term 'double teeth' describes a shape dental anomaly which occurrence ranges from 0.1% to 5% unilaterally and from 0.01% to 0.12% bilaterally in primary dentition [27]. The aetiology seems to be unknown. In primary dentition the incidence of double teeth is 0.1% to 0.9% in Caucasian children, while it is more frequent (1.55%–3.0%) among Asian children. To date, no sex predilection has been found in literature [28,29]. Due to the clinical presentation, the nomenclature of this type of dental anomaly still appears to be controversial among clinicians. In literature, these teeth are commonly referred to as 'double teeth'. In general, the pathogenesis of this anomaly can follow two pathways. In particular, gemination occurs as a result of an attempted division of a single tooth germ, whereas fusion arises through the union of two normally separated tooth germs [6]. In order to avoid confusion in terminology, the use of the clinical definition 'double teeth' is suggested [11].

Being able to diagnose the presence of double teeth during the regular clinical controls is of great importance. This is because double teeth are often at risk of tooth decay, since the enamel surface appears weakened [7]. In addition, when maxillary anterior teeth are involved, the risk of trauma is higher, and compromised aesthetics can cause discomfort to the patients. In 2013, Agarwal et al. [28], proposed the silicone putty guide to allow for an aesthetic restoration of a traumatized maxillary central incisor fused with a supernumerary tooth. However, the direct restoration with composite is difficult and time-consuming. In the case reported by Agarwal et al. [28] the silicone putty provided an accurate guide of the incisal margins and proximal contours, proving to be a good technique to treat this type of dental anomaly.

Moreover, this dental anomaly does not only affect the external tooth morphology, but also the pulp. As a consequence, the abnormal anatomy of the pulp and the root

canals pose great technical difficulties for the endodontists in case a root canal treatment is needed [11]. The simplest pulp configuration observed in completely fused teeth is the presence of a single large pulp chamber with a voluminous root canal. Nevertheless, incompletely fused teeth may present a more complicated canal anatomy, as their pulp can be diversely separated in the presence of two different pulp chambers or roots. In particular, the existence of one pulp chamber with two different root canals as well as two pulp chambers with one root canal is possible in teeth with incomplete fusion. In these cases, the endodontic access cavity preparation has to be adequate and the operator has to be able to fully probe the pulp chamber [30]. Additionally, due to its excessive size the wide double tooth crown can negatively affect the respective arch, thus inducing size irregularity within the arch and thus, major aesthetic or even functional concerns, such as malocclusion. Finally, the resulting proclination caused by double teeth can induce an unfavourable modification of the incisal guide during the occlusion evaluation [26,30].

To our knowledge, and according to the most recent literature review performed by Shah et al. [6], the alternative management options for double teeth in general include diverse treatment modalities varying from no intervention at all, preventive measures (periodic recalls, local fluoride application, dietary changes), orthodontic treatment, restorative treatment (endodontic therapy, composite restorations), to surgical measures (crown modification with or without hemisection, extraction). A list of the suggested treatment measures for fused primary incisors as well as a clinical protocol or their management are provided on Tables 4 and 5, respectively. The determining factors for choosing the most suitable treatment for double teeth are the degree of the tooth mobility, the type of existing roots and the morphology of the root canal system. In their report Shah et al. [6] also underlined three additional factors to be assessed prior to taking the decision on the most suitable treatment of this dental anomaly: i) tooth prognosis, ii) patient's expectation in regard with aesthetics and iii) complications related to orthodontic therapy [6]. It seems that establishing an enhanced success rate for each reported treatment is rather impossible, due to various biases and the absence of concrete success criteria.

**Table 4** List of available treatment option to apply in case of fused primary teeth.

Available treatment options in case of primary fused teeth
Preventive approach
Prerequisites: No tooth mobility, no root resorption, absence of caries, presence or absence of permanent successor*.
Treatment: Information of parents or guardian about the presence of this dental anomaly, topical fluoride application, preventive sealing of the deep fissures when present and 3-month-follow-up programme. Dietary changes may be also proposed.
*In case of absence of the permanent successor*, the primary fused tooth should be maintained until the appropriate age for prosthodontics therapy has been reached.
Restorative approach
Prerequisites: No tooth mobility, no root resorption, presence of caries, presence or absence of permanent successor
Treatment: Caries removal and subsequent restoration with a flowable composite. In case of trauma or aesthetic issue, guided restoration with putty silicone and use of composite resin is indicated.
Surgical approach
Prerequisites: Tooth mobility, root resorption, presence of deep caries, presence or absence of permanent successor
Treatment: Extraction, also indicated when the fused tooth represents an obstacle for the eruption of the permanent successor.

**Table 5.** 'What to do' protocol in case of facing fused primary teeth cases.

Clinical protocol for the management of fused primary teeth
1) Clinical examination, evaluation of the tooth mobility,
2) Eventual radiological and model cast analysis.
3) Information of the parent or the guardian about the presence of this dental anomaly. If the tooth is stable and caries-free, a 3 month-follow-up programme should be prescribed.
4) If the tooth presents demineralisation but no mobility or root resorption, 1.25 % fluoride application should be prescribed, together with a 3 month-follow-up programme. If the tooth has a deep fissure, sealing with a flowable composite should be performed. In case the permanent tooth is absent, the maintenance of the tooth is fundamental until the patient has reached an appropriate age for an appropriate prosthodontic therapy.
5) If the tooth has (initial) caries in the absence of mobility or root resorption, caries removal with subsequent restoration with a flowable composite should be performed and the patient should be enrolled in a 3-month-follow-up programme.
6) If the tooth is compromised through deep caries, increasing tooth mobility or root resorption, it should be extracted, and orthodontic therapy for space maintenance should be applied.

Usually, clinical cases where the tooth has no evident pathology are treated in a rather conservative way including mostly preventive measures. Thereby it is expected that a tooth with a good prognosis do not have any clinical indication to be extracted. The preventive treatment approach for double teeth in primary dentition includes radiographic control, local application of fluoride and the enrolment of the patient in a 3-month recall programme. Nevertheless, in an earlier case study, Tewari et al. [25] treated a bilateral fusion in primary mandibular incisors by filling the very deep incisal groove with a flowable composite, followed by a 3-month recall programme.

Interestingly, a complication that seems to be associated with the presence of double teeth is the absence of the permanent successor teeth. A good diagnosis usually includes the radiographic assessment of the presence of the permanent successor teeth, in order to establish an efficient therapy plan. If the permanent successor teeth are present, only an accurate monitoring through thorough clinical examination, local fluoride application and radiographic control at specific

intervals of 3 months is necessary. If the permanent successor teeth are missing, the mentioned preventive and/or restorative treatment of the fused teeth is fundamental, so that a future prosthetic therapy can be initiated when the patient has reached the appropriate age of 18 years [21,24]. In our systematic review, all authors of the respective papers have agreed on the necessity of a multidisciplinary approach to treat these rare cases. Even though the absence of caries on the fused teeth could lead to the underestimation of this tooth anomaly, complications involving the pulp and the occlusion can still occur. Therefore, the accurate monitoring is one of the most recommended initial diagnostic measures. In addition, the clinical evaluation of the tooth mobility is fundamental to understand the degree of the root resorption and evaluate the timing of the eruption of the permanent tooth.

## Conclusions

In conclusion, all the treatment options found in literature seem to play a key role in relevant clinical cases involving primary anterior teeth, since they occur in young and growing organisms, and they can therefore induce significant alterations in the morphology of the permanent teeth and the jaw growth. Taking the rarity of this dental anomaly into consideration, a correct diagnosis is fundamental for a successful interdisciplinary management of double teeth.

## Acknowledgment

Authors G.B. and S.B(1). Want to acknowledge the paediatric patient and his family who was of inspiration of this paper.

## Disclosure statement

No potential conflict of interest was reported by the author(s).

## ORCID

Sara Bernardi  <http://orcid.org/0000-0001-6130-8533>

Lamprini Karygianni  <http://orcid.org/0000-0002-7893-0393>

## Data availability

The datasets are available from the corresponding author on reasonable request.

## References

- [1] Shokri A, Mortazavi H, Baharvand M, et al. Tooth abnormalities: an overview of more than 20 developmental and acquired disorders. *J Clin Dent.* 2014;7(4):347–362.
- [2] Choi SJ, Lee JW, Song JH. Dental anomaly patterns associated with tooth agenesis. *Acta Odontol Scand.* 2017;75(3):161–165.
- [3] Caruso S, Bernardi S, Pasini M, et al. The process of mineralisation in the development of human tooth. *Eur J Paediatr Dent.* 2016; 17(4):322–326.
- [4] Folan MO, Alade M, Adeniyi A, et al. Association between developmental dental anomalies, early childhood caries and oral

- hygiene status of 3-5-year-old children in Ile-Ife, Nigeria. *BMC Oral Health*. 2020;20(1):1.
- [5] Giffoni TCR, Brandt GZ, Rocha IS, et al. Relation of dental anomalies with occlusal alterations in the pediatric patients. *Pesqui Bras Odontopediatria Clín Integr*. 2019;19(1):e4026–10.
- [6] Shah P, Chander JML, Noar J, et al. Management of “double teeth” in children and adolescents. *Int J Paediatr Dent*. 2012; 22(6):419–426.
- [7] Tomizawa M, Shimizu A, Hayashi S, et al. Bilateral maxillary fused primary incisors accompanied by succedaneous supernumerary teeth: report of a case. *Int J Paediatr Dent*. 2002;12(3):223–227.
- [8] Aguiló L, Gandia JL, Cibrian R, et al. Primary double teeth. A retrospective clinical study of their morphological characteristics and associated anomalies. *Int J Paediatr Dent*. 2001;9(3):175–183.
- [9] Mader CL. Fusion of teeth. *J Am Dent Assoc*. 1979;98(1):62–64.
- [10] Zhu M, Liu C, Ren S, et al. Fusion of a supernumerary tooth to right mandibular second molar: a case report and literature review. *Int J Clin Exp Med*. 2015;8(8):11890–11895.
- [11] Neves AA, Neves MLA, Farinhas JA. Bilateral connotation of permanent mandibular incisors: a case report. *Int J Paediatr Dent*. 2002;12(1):61–65.
- [12] Guimarães Cabral LA, Firoozmand LM, Dias Almeida J. Double teeth in primary dentition: report of two clinical cases. *Med Oral Patol Oral Cir Bucal*. 2008;13(1):77–80.
- [13] Zengin AZ, Celenk P, Gunduz K, et al. Primary double teeth and their effect on permanent successors. *Eur J Paediatr Dent*. 2014; 15(3):309–312.
- [14] Nogueira Fialho MP, Pinzan-Vercelino CR, Nogueira RP, et al. Relationship between facial morphology, anterior open bite and non-nutritive sucking habits during the primary dentition stage. *Dental Press J Orthod*. 2014;19(3):108–113.
- [15] Bernardi S, Bianchi S, Fantozzi G, et al. Morphometric study on single-root premolars in a European population sample: an update on lengths and diameters. *Eur J Anat*. 2019;23(1):17–25.
- [16] Liberati A, Altman DG, Tetzlaff J, et al. The PRISMA statement for reporting systematic reviews and meta-analyses of studies that evaluate health care interventions: explanation and elaboration. *PLoS Med*. 2009;6(7):e1000100.
- [17] Murad MH, Sultan S, Haffar S, et al. Methodological quality and synthesis of case series and case reports. *BMJ Evidence-Based Medicine*. 2018;23(2):60–63.
- [18] Alpöz AR, Munanoğlu D, Oncag O. Mandibular bilateral fusion in primary. *J Dent Child (Chic)*. 2003;70(1):74–76.
- [19] Chalakkal P, Thomas AM. Bilateral fusion of mandibular primary teeth. *J Indian Soc Pedod Prev Dent*. 2009;27(2):108–110.
- [20] Favalli O, Webb M, Culp J. Bilateral twinning: report of case. *ASDC J Dent Child*. 1998;65(4):268–271.
- [21] Milano M, Seybold SV, McCandless G, et al. Bilateral fusion of the mandibular primary incisors: report of case. *ASDC J Dent Child*. 1999;66(4):280–282.
- [22] Prabhu R, Chatra L, Shenai P, et al. Bilateral fusion in primary mandibular teeth. *Indian J Dent Res*. 2013;24(2):277.
- [23] Rajashekhara BS, Dave B, Manjunatha BS, et al. Bilateral fusion of primary mandibular lateral incisors and canines: a report of a rare case. *Rev Odonto Ciênc (Online)*. 2010;25(4):427–429.
- [24] Sekerci AE, Sisman Y, Ertas ET, et al. Clinical and radiographic evaluation and comparison of six cases of fusion involving the primary dentition. *J Dent Child*. 2012;79(1):34–39.
- [25] Tewari N, Pandey RK. Bilateral fusion in primary mandibular teeth: a report of two cases. *J Indian Soc Pedod Prev Dent*. 2011;29(1): 50–52.
- [26] Shanthraj SL, Mallikarjun SB, Kiran S, et al. Triplication’ defect in deciduous teeth: an unusual odontogenic anomaly. *BMJ Case Rep*. 2015;2015:bcr2014205185.
- [27] Oliván Rosas G, López-Jiménez J, Giménez Prats MJ, et al. Considerations and differences in the treatment of a fused tooth. *Med Oral*. 2004;9(3):224–228.
- [28] Agarwal R, Chaudhry K, Yeluri R, et al. Esthetic management of a primary double tooth using a silicone putty guide: a case report. *J Calif Dent Assoc*. 2013;41(3):203–206.
- [29] Hattab FN. Double talon cusps on supernumerary tooth fused to maxillary central incisor: review of literature and report of case. *J Clin Exp Dent*. 2014;6(4):e400–407.
- [30] Indra R, Srinivasan MR, Farzana H, et al. Endodontic management of a fused maxillary lateral incisor with a supernumerary tooth: a case report. *J Endod*. 2006;32(12):1217–1219.