

## THE TOOTH DEVELOPMENT IN ERINACEUS EUROPAEUS

by

MÁRTHA KINDAHL

The following description of the tooth development in *Erinaceus europaeus*<sup>1</sup> is derived from a comprehensive investigation by the present author on the embryonic development of the teeth in Insectivora. Earlier publications by the author concern *Tupaia javanica* (1957), *Elephantulus myurus Jamesoni* (1958), *Talpa europaea* (1958), and *Soricidae* (1959).

The change of the teeth in *Erinaceus europaeus* was formerly a subject of contention. Thus, according to *Rousseau* (1838), *Huxley* (1880), *Baume* (1882), *Dobson* (1883), and several others, a complete change of the teeth takes place, while the opposite is maintained by *de Blainville* (1839-64). Some investigators (*Sundevall* 1842, *Blasius* 1857, *Owen* 1868) reported that they had actually found a few lacteal teeth. The first to give a detailed description of the change of the teeth was *Sahlertz* (1871). He described a lacteal dentition, in the upper jaw consisting of a first and a second incisor and a third and a fourth premolar, and in the lower jaw of a first incisor and a fourth premolar. In a few skulls only did he find an upper small deciduous canine. These lacteal teeth were assumed to function together with the permanent teeth, the change taking place before the first winter sleep. *Tauber* (1872) described a full lacteal dentition that under-

---

<sup>1</sup> A short notice of the change of the teeth of *Erinaceus europaeus* was included in the Proceedings of the XIV International Congress of Zoology in Copenhagen in 1953. The Proceedings were published in 1956.

goes two periods of change. The first change takes place *in uteri*, or immediately after birth, involving the upper third incisor and the lower second incisor, the canine and the first premolar in both jaws. These teeth are represented by small deciduous enamel organs, with the exception of the upper canine and the upper first premolar which are suppressed at an early stage. The second change occurs, in *Tauber's* opinion, when the animals are almost full-grown, and concerns the remaining antemolars. *Winge* (1882) expresses agreement with *Tauber's* views. Also *Schlosser* (1887–1890) refers to a full lacteal dentition. However, in a personal communication to *Leche*, he stated that upon renewed investigation only a lacteal upper first incisor and a fourth premolar in both jaws were found.

*Leche* (1895) was the first to study embryos and young animals in serial sections. He described the same number of lacteal teeth as *Sahlertz*, but, according to *Leche*, the upper lacteal canine is invariably formed somewhat later than the other teeth. It develops more rapidly and falls out early. The lower anterior incisor he called  $Id_2$ , in contrast to *Sahlertz* who used the designation  $Id_1$ . *Leche* pointed out a small residuum of the first incisor. It emerges from his observations that, with the exception of the upper second incisor, the teeth which developed late in the first dentition are not changed, i.e.  $I^3$  and  $P^2$  in the upper jaw and  $I_3$ ,  $C$ , and  $P_3$  in the lower jaw. Further, the upper permanent third incisor develops similar to the antemolars which are without a predecessor, though it has a deciduous lacteal tooth, and the same would apply to the upper canine if its predecessor were to undergo a further reduction. *Leche* called the two lower premolars  $P_3$  and  $P_4$ . The functional teeth of *Erinaceus europaeus* would belong to two dentitions. The change of the teeth *in uteri* described by *Tauber* was refuted by *Leche*, with the exception of the upper canine.

*Woodward* (1896) was able to ascertain deciduous enamel organs with an irregular calcification of no physiological significance in two older embryos of *Erinaceus*, relating to the upper third incisor, the canine and the first premolar in both jaws. He found a remnant of the true lower first incisor, both in the lacteal and in the permanent series, like a slightly bell-shaped bud of the dental lamina with a small labial outgrowth.

*Woodward* observed a trace of one of the missing marsupial incisors in the strongly developed dental lamina between the lower third incisor and the canine. According to him, the vestige of a suppressed tooth between the two premolars is indicated by an enlargement of the dental lamina. In the molar region, he noticed indications of three or more sets of teeth. *Leche* also mentioned similar observations. *Woodward* did not mention *Tauber's* earlier statements regarding deciduous tooth germs. *Woodward* writes: "It is just possible that our English hedgehog differs in respect to the amount of development of these milk-tooth vestiges from its continental cousin, although they are considered as one species; on the other hand, my two specimens may represent individual variations."

At first with some hesitation, but later, without going into details, *Leche* (1897, 1902) accepted *Woodward's* earlier results concerning the presence of deciduous tooth rudiments. In the tooth formula, finally presented by *Leche*, all the antemolars but the lower third incisor have a predecessor. The lower anterior premolar was now referred to by him as  $P_2$ , instead of earlier  $P_3$ . He discovered in *Erinaceus senaarensis* a small tooth between the two premolars which he considered to be an atavism or, possibly, belonging to a younger dentition. In a full-grown *Erinaceus europæus*, he found a labially displaced upper first premolar. In a specimen of *Erinaceus albiventris*, he observed a supernumerary tooth between the lower two incisors. If this were an atavism, the anterior incisor would be  $I_1$ , and the real  $I_2$  would be reduced or resemble the bud-shaped germ found earlier in *Erinaceus europæus*, medially to the third incisor, in which case it would belong to a younger dentition.

The reduction in the teeth of the hedgehog does not seem to be concluded, to judge from *Fuchs's* (1912) observations. In a full-grown specimen of *Erinaceus europæus*, *Fuchs* found that the lower lateral incisors  $I_3$  had completely disappeared.

However, *Leche* does not seem fully convinced of the accuracy of the tooth formula of the hedgehog, at least not as regards the premolars and the lower incisors. *Woodward* suggested individual variations or a difference in the development of the teeth of the English and the Continental hedgehog. Therefore, renewed in-

quiries seem called for in order to shed light on the development of the teeth of *Erinaceus europaeus*.

The present author's *Erinaceus europaeus* material consists of embryos of 8 mm, 12.5 mm, 13 mm, 23 mm, 33.5 mm, and 55 mm, and young animals of 80 mm and 95 mm in length, from which serial sections of different thicknesses (8–20  $\mu$ ) were made and stained according to Mallory's method. The author's investigation is based on graphic reconstructions.

#### Upper jaw

No dental lamina has formed in the upper jaw of an 8 mm embryo. In a 12.5 mm embryo the dental lamina extends to the medial line, though without any connection with the other side of the jaw. On the upper side of the anterior part of the dental lamina, there are two cell-concentrations. The first group is small and round, the posterior one bigger and oval. The corresponding buds of the dental lamina that might be interpreted as tooth anlagen are lacking. Five tooth germs have developed. Three of them are small, cup-shaped, decreasing successively. A fourth is considerably bigger and more developed. The fifth consists only of a high bud-shaped swelling of the dental lamina. All the tooth germs are surrounded by a concentration of mesenchymatic cells.

The first incisor anlage is slightly more developed in a 13 mm embryo, though still in a cup-shaped stage. The second is less developed. The third tooth germ of the preceding embryo is lacking. The next tooth anlage is bigger and less developed. The last one seems unchanged.

The dental lamina in the far front is very low and thin in a 23 mm embryo. Seven tooth anlagen are developed (Fig. 1). The first incisor anlage ( $Id^1$ ) is slightly cup-shaped. The second incisor germ ( $Id^2$ ) is somewhat smaller and bud-shaped with only a small invagination. It is localized nearer to the oral epithelium than the others. The third incisor anlage ( $Id^3$ ) is also bud-shaped. It has a small lateral process, as observed by *Leche*. The canine anlage ( $Cd$ ) is slightly cup-shaped. The third premolar germ ( $Pd^3$ ) is in the bud-shaped stage. The anlagen of the fourth premolar ( $Pd^4$ ) and the first molar ( $M^1$ ) have developed the most.

The molar anlage is the biggest. The dental lamina is here very high and so is the neck of this tooth anlage. The dental lamina continues some distance behind the tooth germs.

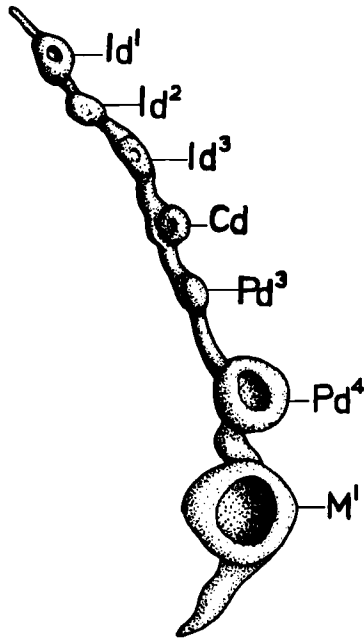
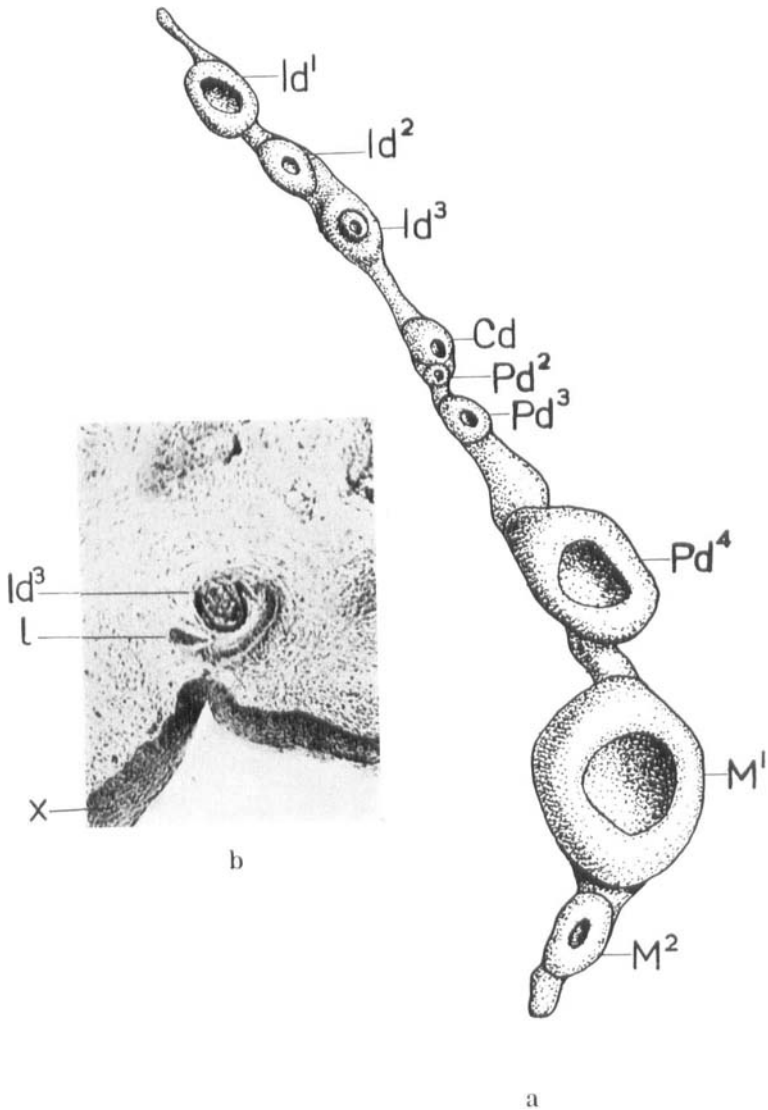


Fig. 1. *Erinaceus europaeus*. Embryo 23 mm. Graphic reconstruction of the dental lamina of the upper jaw with the tooth germs.  $\times 30$ .

The first incisor anlage in a 33.5 mm embryo (Fig. 2,  $Id^1$ ) has increased in volume, as has the second ( $Id^2$ ), which still lies nearer to the oral epithelium. The third is a large bud of the dental lamina, its dorso-lateral wall being considerably invaginated (Fig. 2 b). This invagination is filled with an irregular calcification. In all probability this constitutes a deciduous lacteal tooth anlage ( $Id^3$ ). (Such deciduous tooth germs were also observed by the author in *Sorex araneus* and *Suncus orangiac*.) Apparently the lateral process (Fig. 2 b, l) does not, as presumed by *Leche*, take part in the formation of the lacteal tooth anlage. It remains unchanged from the preceding stage and lies outside and slightly below the lacteal germ. The dental lamina proceeds in a uniform thickness to the bell-shaped canine anlage (Fig. 2 a,



**Fig. 2.** *Erinaceus europaeus*. Embryo 33.5 mm. a) Graphic reconstruction of the dental lamina of the upper jaw with the tooth germs.  $\times 33.3$ . b) A section through the lacteal third incisor anlage.  $x$  = the oral epithelium,  $l$  = the dental lamina.

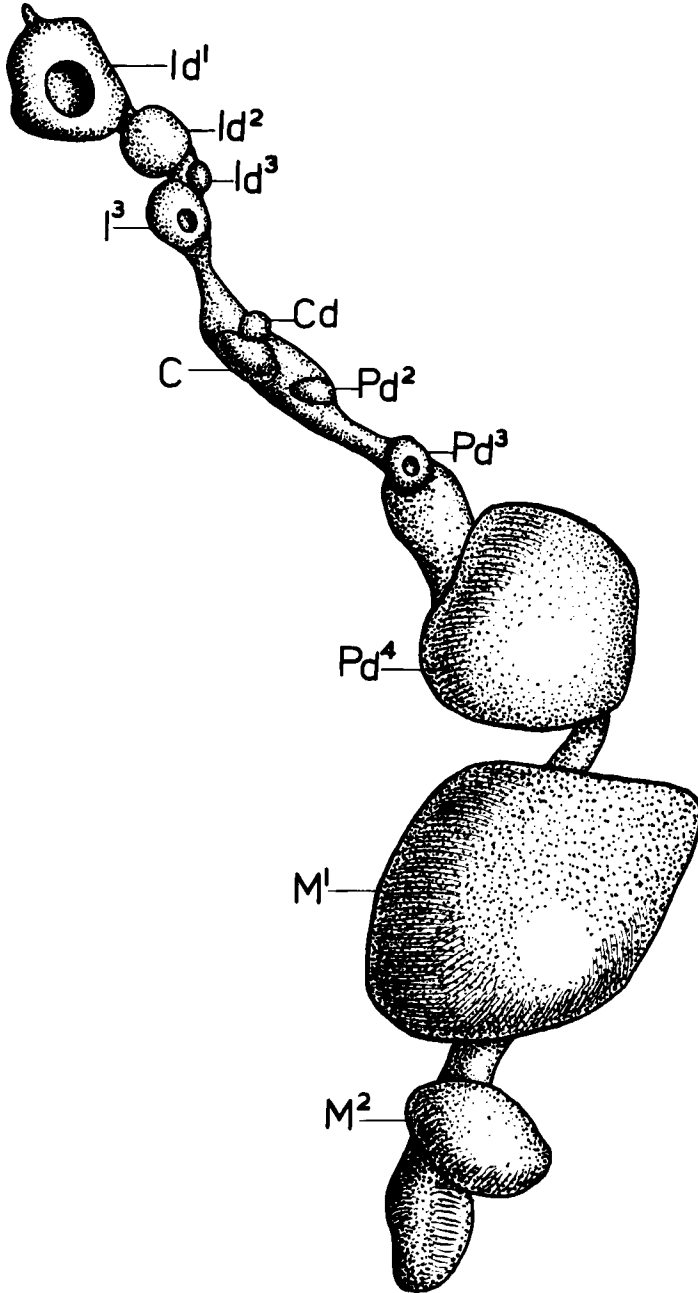


Fig. 3. *Erinaceus europaeus*. Embryo 55 mm. Graphic reconstruction of the dental lamina of the upper jaw with the tooth germs.  $\times 33.3$ .

Cd). There it becomes higher and pushes the tooth anlage deep into the mesenchyma. Just behind, a new cup-shaped tooth anlage follows, i.e. the second premolar anlage (Pd<sup>2</sup>). The third premolar germ (Pd<sup>3</sup>) has become bigger and bell-shaped. The dental lamina remains high as far as the large fourth premolar germ (Pd<sup>4</sup>), which has a medial process like the third incisor anlage. It is obvious that this process forms part of the dental lamina and not of the tooth anlage. The first molar anlage (M<sup>1</sup>) is the biggest. A second cup-shaped molar anlage (M<sup>2</sup>) has been added. The dental lamina extends a little further posteriorly.

In a 55 mm embryo the dental lamina runs for a short distance in front of the big first incisor anlage (Fig. 3, Id<sup>1</sup>) which has obtained a thin layer of dentine. The site of the considerably smaller second incisor anlage (Id<sup>2</sup>) lies quite close to and slightly labial to the first. The third incisor germ (Id<sup>3</sup>) is deciduous, consisting of a lump of remaining cells. Lingually is the cup-shaped successor anlage (I<sup>3</sup>). The dental lamina lies labially to the tooth anlage. At the lacteal tooth germs its position is lingual. The dental lamina increases in height as far as the big permanent canine anlage (C) which is cup-shaped and deeply immersed in the mesenchyma. At its anterior basal part, the deciduous predecessor anlage (Cd) is found. It is followed by the lacteal second premolar anlage (Pd<sup>2</sup>), which is also in the process of degeneration. The third premolar anlage (Pd<sup>3</sup>) is more developed, as is also the big fourth premolar germ (Pd<sup>4</sup>) which, like the first incisor anlage, has obtained a layer of dentine. The big first molar germ (M<sup>1</sup>) also has a thin layer of dentine on one of its cusps. The second molar germ (M<sup>2</sup>) is still in a very early stage of development.

In another specimen of 55 mm, a newborn animal, the first incisor anlage (Fig. 4, Id<sup>1</sup>) has grown so as to pass in front of the dental lamina with its anterior edge. The dentine layer has become considerably thicker. At the posterior edge of the tooth anlage, the dental lamina is swollen and forms the successor anlage (I<sup>1</sup>). In the lacteal second incisor germ (Id<sup>2</sup>) the dentine formation has not yet begun, and the dental lamina is swollen, forming the permanent second incisor anlage (I<sup>2</sup>). The permanent third incisor germ (I<sup>3</sup>) is at the cup-shaped stage. Some of the dentine net of its deciduous predecessor anlage remains. The

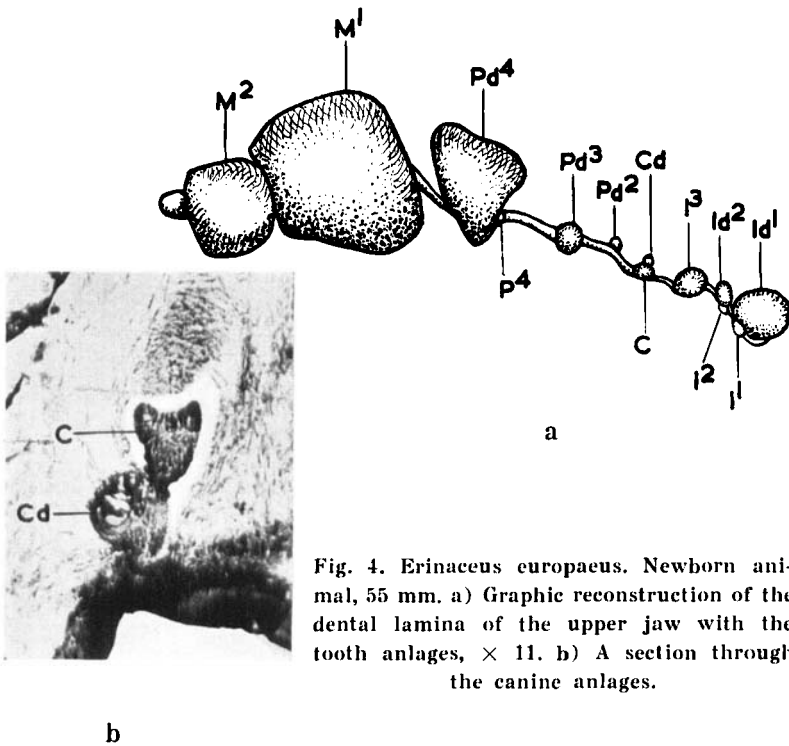


Fig. 4. *Erinaceus europaeus*. Newborn animal, 55 mm. a) Graphic reconstruction of the dental lamina of the upper jaw with the tooth anlagen,  $\times 11$ . b) A section through the canine anlagen.

deciduous canine anlage (Fig. 4 b, Cd) is represented by a bell-shaped formation, filled with an irregular dentine net situated labially to the permanent canine anlage (C) which is still cup-shaped. In the lacteal second premolar germ (Fig. 4 a, Pd<sup>2</sup>) the dentine is sparsely developed and occurs less regularly than in the deciduous canine anlage. The dental lamina is well developed, though not swollen. The third premolar anlage (Pd<sup>3</sup>) is bell-shaped. In the large posterior premolar germ (Pd<sup>4</sup>) the enamel has begun to form; the dental lamina is slightly swollen, forming the enamel organ of its successor (P<sup>4</sup>). The molar anlagen (M<sup>1</sup> and M<sup>2</sup>) have not undergone any great change.

The lacteal first incisor anlage has further increased in size in a young animal of 80 mm (Fig. 5, Id<sup>1</sup>), and its successor anlage (I<sup>1</sup>) is in a cup-shaped stage. The lacteal second incisor anlage (Id<sup>2</sup>) has a thick layer of dentine, but is barely half the size of the first. Its successor anlage (I<sup>2</sup>) is indicated by a bud-shaped

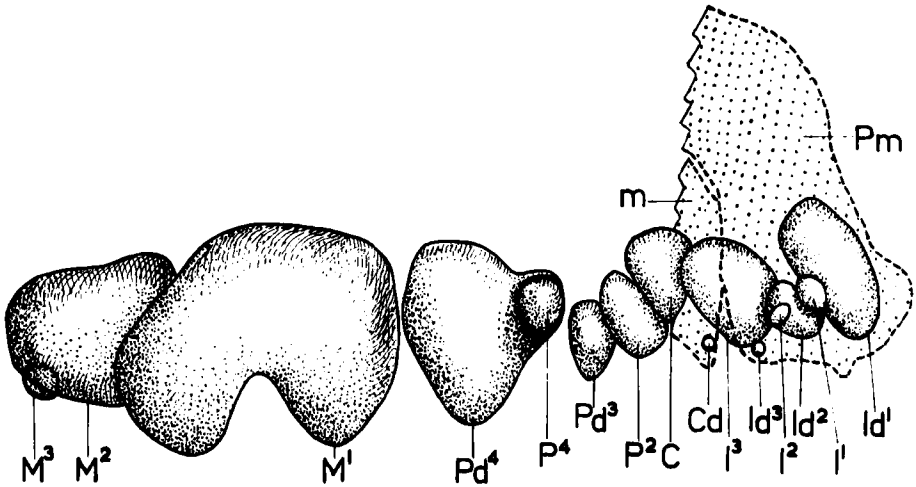


Fig. 5. *Erinaceus europaeus*. Young animal, 80 mm. Schematic reconstruction of the tooth anlagen of the upper jaw. Pm = praemaxilla. m = maxilla.

thickening. The permanent third incisor germ ( $I^3$ ) has attained the same stage as the two anterior lacteal incisor anlagen, being almost equal in size to the first. A small mass of deciduous cells remains of the lacteal third incisor ( $Id^3$ ). The permanent canine germ (C) is also well developed with a layer of dentine. Its predecessor anlage (Cd) consists of a mass of deciduous cells. It does not, accordingly, develop enough to break through the oral epithelium, as supposed by *Leche*, but degenerates long beforehand. The foremost premolar anlage ( $P^2$ ) probably belongs to the second dentition. It is developed in the same manner as the non-deciduous tooth anlage, and has a thin layer of dentine. No trace of its predecessor is found any longer. The lacteal third premolar anlage ( $Pd^3$ ) has grown considerably. Its successor ( $P^3$ ) is represented by a bud-shaped thickening of the dental lamina. The big posterior lacteal premolar anlage ( $Pd^4$ ) has become free from the dental lamina which has gradually been resorbed. In the permanent fourth premolar anlage ( $P^4$ ) the formation of dentine has begun. The first molar germ ( $M^1$ ) is by far the biggest tooth anlage. It has a thick layer of dentine and a thin layer of enamel, its connection with the dental lamina now being resolved. Also in the second molar germ ( $M^2$ ) the formation of dentine as well as

of enamel is in progress, though this germ is barely half the size of the first molar anlage. Its connection with the dental lamina is extremely thin. The third molar anlage ( $M^3$ ) consists of a cup-shaped thickening.

In a few places close to the dental lamina, small groups of densely situated cells occur, each surrounded by a thin membrane. These groups are connected by a thin string either with the dental lamina or with the oral epithelium. They are probably manifestations of a degenerative process. *Kollman* (1870) described similar findings in man under the name of "Epithelnester".

All the tooth anlages are bigger and their layer of dentine thicker in an animal of 95 mm. In several of them enamel has begun to form. The foremost part of the dental lamina is entirely resolved. At the permanent first incisor anlage, the dental lamina is well developed, while at the lacteal second incisor germ, it is resolved, though unchanged at the successor anlage. The permanent third incisor anlage is very large. It has grown rapidly and is now wider than the lacteal first incisor. Also the permanent canine anlage has undergone a rapid development. In the two last-mentioned permanent tooth anlages, the formation of enamel is marked. No trace is found of their deciduous predecessors. Fragments of the dental lamina with numerous "Epithelnester" are observed. Such bodies being quite isolated, can also be seen in the oral epithelium. The second premolar anlage, in which the formation of enamel is in process, belongs to the permanent dentition. The two posterior premolar anlages belong to the lacteal dentition. The lacteal fourth premolar is placed near the oral epithelium. The permanent third premolar anlage is in a cup-shaped stage, and the fourth shows beginning formation of dentine. In the first and second molar germs, dentine and enamel are being formed, but not in the third. The dental lamina is also entirely resolved at the most developed premolar and molar anlages.

#### Lower jaw

No dental lamina has developed in the lower jaw of an 8 mm embryo. In a 12.5 mm embryo a dental lamina with four bud-shaped tooth anlages is to be seen in each side of the jaw, two

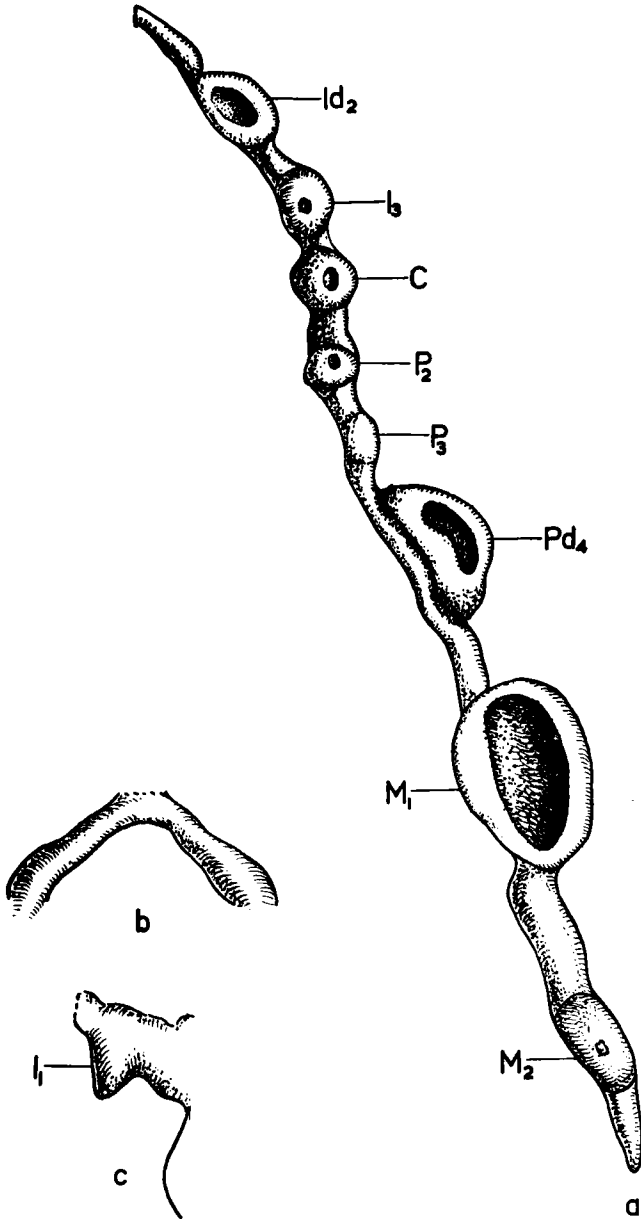


Fig. 6. *Erinaceus europaeus*. Embryo 23 mm. Graphic reconstructions a) of the dental lamina of the lower jaw with the tooth germs,  $\times 50$ , b) of the anterior part of the dental lamina with the commissure,  $\times 100$ , c) of the first incisor anlage,  $\times 100$ .

small ones at the front and two bigger ones more posteriorly. In a 13 mm embryo the more developed tooth anlagen are cup-shaped. There is, apparently, a commissure between the two lower dental laminae, as was also assumed by *Leche*. However, this could not be verified in this embryo owing to the unsuitable direction of the sections. In the 23 mm embryo, however, this is an established fact. The two dental laminae start from the oral epithelium at the mid-line of the lower jaw, quite close to one another (Fig. 6 b). In front of the lacteal second incisor anlage (Fig. 6 a,  $Id_2$ ) the dental lamina is slightly swollen, the swelling being probably a vestige of the disappeared first incisor anlage (Fig. 6 c,  $I_1$ ). *Leche*, as well as *Woodward*, observed traces of the first incisor. The germs of the lacteal second incisor (Fig. 6 a,  $Id_2$ ) and fourth premolar ( $Pd_4$ ), and the first molar anlage ( $M_1$ ) have attained the bell-shaped stage, while the anlagen of the third incisor ( $I_3$ ), the canine (C), and the second premolar ( $P_2$ ), which belong to the permanent dentition, are cup-shaped. Between the second and the fourth premolar anlagen is a very faint cup-shaped thickening, surrounded by a condensation of cells, without doubt constituting the germ of the deciduous third premolar ( $P_3$ ) observed earlier by *Woodward*.

The commissure between the two lower dental laminae is more evident in a 33.5 mm embryo. This also has the anterior swelling of the dental lamina, representing the first deciduous incisor. The number of the tooth anlagen is unchanged. All of them, even the third premolar germ, are now cup-shaped, though varying slightly in degree of development.

In a newborn animal of 55 mm (Fig. 7 a), the dental lamina is a little broader just in front of the lacteal second incisor anlage. However, this cannot be said to constitute a definite vestige of the first incisor. Four of the tooth anlagen, i.e. the lacteal second incisor ( $Id_2$ ), the lacteal fourth premolar ( $Pd_4$ ), and the first and second molars ( $M_1$  and  $M_2$ ), are large and well developed. The second incisor germ has a thin layer of dentine. At the neck of the dental lamina, its successor ( $I_2$ ) is manifested by a small swelling. The permanent third incisor anlage ( $I_3$ ), which is now in the cup-shaped stage, is found just beneath the oral epithelium, above the posterior part of the second incisor anlage. In three sections ( $15 \mu$  thick) just beside it a small mass of cells

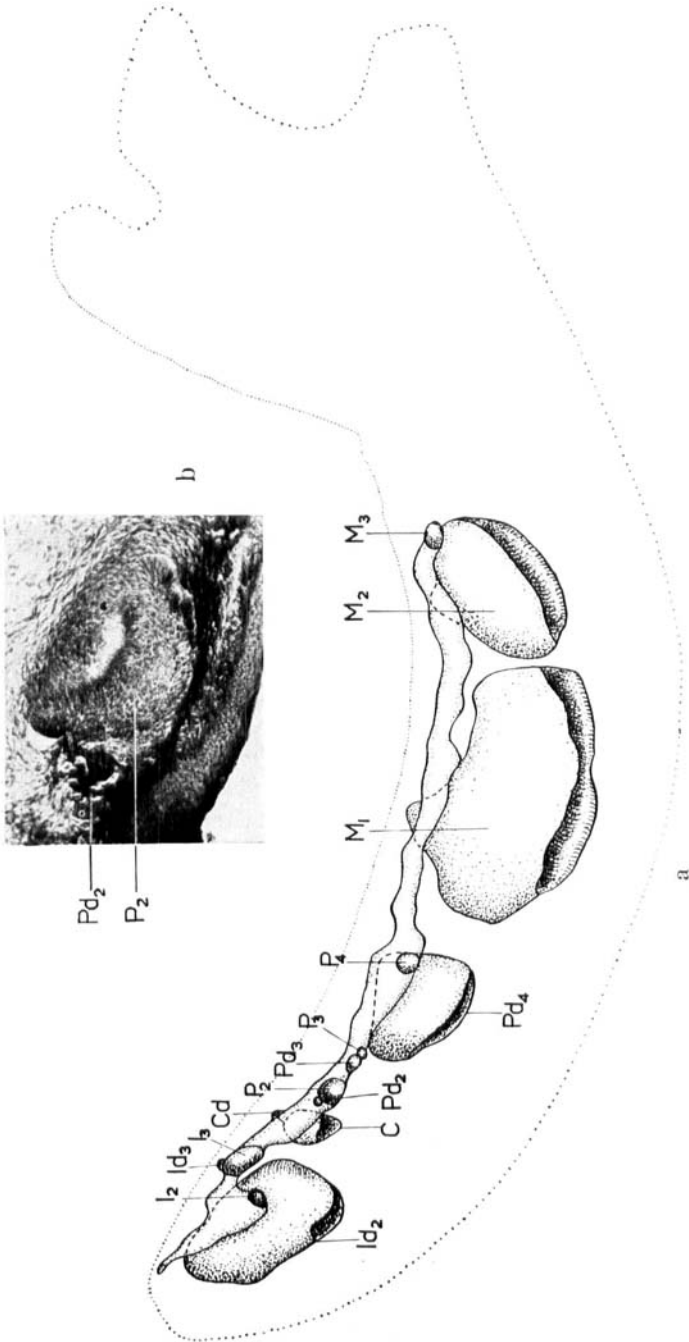


Fig. 7. Erinaceus europaeus. Newborn animal, 55 mm. a) Graphic reconstruction of the dental lamina of the lower jaw with the tooth germs,  $\times 14$ , b) A section through the second premolar anlage.

is seen, connected with the dental lamina by a thin string. In all probability, this is the deciduous third incisor anlage ( $Id_3$ ). The canine anlage (C) is a little bigger, and lies deeper than the third incisor germ. It has a broad connection with the dental lamina. A very small body, composed of a net of dentine, and situated dorsally, represents its predecessor anlage (Cd). Close to the posterior edge of the permanent canine germ, a cup-shaped swelling of the dental lamina is seen. It is probably the second premolar anlage ( $P_2$ ). Also, dorsally to this tooth anlage, a slightly bigger net of dentine, is found, representing the degenerated predecessor (Fig. 7 b,  $Pd_2$ ). The third premolar anlage (Fig. 7 a,  $Pd_3$ ) is a small bud-shaped swelling of the dental lamina, surrounded by a condensation of cells. Another swelling lies labially to this bud, though without a condensation of cells, representing no doubt a trace of the permanent third premolar germ ( $P_3$ ). The big lacteal fourth premolar germ ( $Pd_4$ ) discloses an incipient formation of dentine. Its successor anlage ( $P_4$ ) also appears like a small bud-shaped swelling. The first molar germ ( $M_1$ ), which is the biggest tooth anlage, has a thick layer of dentine. The second molar germ ( $M_2$ ) has a thin layer of dentine, and the third molar anlage ( $M_3$ ) is a small, cup-shaped bud.

The dental lamina is being resolved in front of the large lacteal second incisor anlage in a young animal of 80 mm (Fig. 8,  $Id_2$ ). A small swelling is still discernible. All the tooth anlages have increased in size and are therefore more compressed. In all the tooth germs but the permanent second incisor anlage ( $I_2$ ) and the third molar germ ( $M_3$ ), the formation of dentine is in progress. The lacteal second incisor anlage ( $Id_2$ ) has lost its connection with the dental lamina. The successor anlage ( $I_2$ ) is at the cup-shaped stage. The permanent third incisor anlage ( $I_3$ ) now lies entirely above the second incisor germ and its connection with the dental lamina is at the point of resolving. The connection of the canine anlage (C) is already resolved, but its site is still discernible. The second premolar germ ( $P_2$ ) has a broad connection with the dental lamina, as this tooth germ is still at an early stage of development. The third premolar anlage ( $P_3$ ) lies just behind it. At this point the dental lamina begins to shrink. The posterior premolar anlage, i.e. the lacteal fourth ( $Pd_4$ ), has become completely disconnected. Just in front of the bell-shaped successor

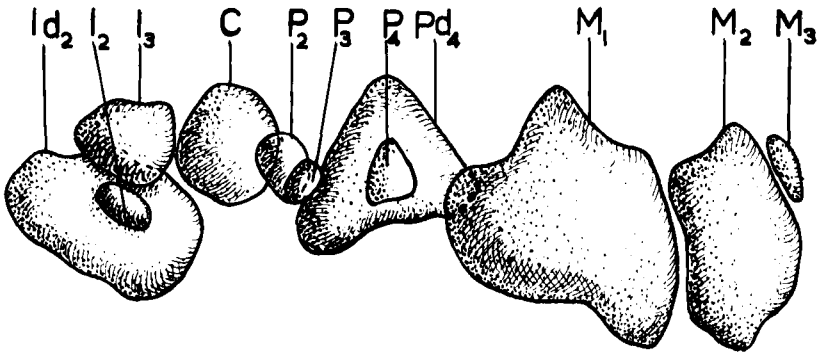


Fig. 8. *Erinaceus europaeus*. Young animal, 80 mm. Schematic reconstruction of the tooth sacs of the lower jaw.  $\times 10$ .

anlage ( $P_4$ ) the dental lamina broadens, then gradually dwindles further on. In the first molar anlage ( $M_1$ ), the formation of enamel has begun. At the small third molar anlage ( $M_3$ ), the dental lamina is well developed.

A residuum of the anterior part of the dental lamina is found in an animal of 95 mm as degenerative bodies, resembling those of the upper jaw. The lacteal second incisor has projected into the oral epithelium. At the successor anlage, which has now obtained a layer of dentine, the dental lamina reappears, being first exceedingly thin, then broadening towards the neck of the dental lamina. The third incisor anlage is still seen just above the second incisor anlage. Here degenerative bodies are again found, originating in the dental lamina. In the canine germ the formation of enamel is in progress. The second premolar germ is well developed. The fourth premolar anlage has proceeded close under the oral epithelium. Its successor anlage has obtained a thin layer of dentine. The dental lamina is clearly visible, though in places dissolved and replaced by degenerative bodies. In all the molar germs the formation of enamel is in progress, though the last one is still very small. Thus, this animal reveals only tooth anlagen that will develop into functioning teeth. The deciduous enamel organ anlagen have completely disappeared.

## RESULTS

The present investigation indicates that a lacteal dentition as well as a permanent dentition are established in *Erinaceus europaeus*. All the antemolars form a lacteal tooth anlage, but only those of the upper first and second incisors, the upper third and fourth premolars, and the lower second incisor and lower fourth premolar are brought to function. The predecessors of the third incisor, the canine and the second premolar in both jaws are aborted and only developed to the cup-shaped stage, with a degenerative formation of dentine. The lacteal tooth rudiments of the lower jaw are resolved at an earlier stage than those of the upper jaw.

During ontogenesis the permanent lower first incisor is represented merely by a swelling of the dental lamina. This also applies to its predecessor.

The upper canine of the lacteal dentition does not undergo rapid and full development, as suggested by *Leche*, but develops simultaneously with the other tooth anlagen. When the permanent canine begins to develop, the predecessor is resorbed.

The permanent lower third premolar reaches the cup-shaped stage before it degenerates, but its predecessor only the bud-shaped stage.

The permanent dentition in the upper jaw consists of three incisors, one canine, three premolars (the second, the third, and the fourth), and three molars, and in the lower jaw of two incisors (the second and the third), one canine, two premolars (the second and the fourth), and three molars.

No trace of a fourth marsupial incisor has been observed, as maintained by *Woodward*. Nor have any traces of a praelacteal or a postpermanent dentitions been ascertained by the present author, contrary to the opinion shared by *Leche* and *Woodward*.

A tooth change cannot be said to take place *in uteri* or immediately after birth, as supposed by *Tauber*, considering that the tooth rudiments were resorbed long before reaching full development. The teeth referred to by *Tauber* correspond to the deciduous lacteal rudiments.

There does not seem to be any difference between the development of the teeth in the English hedgehog and in the Continental

one, as *Woodward* proposed, nor have any individual variations been ascertained by the present author in that respect.

The tooth formula in *Erinaceus europaeus* obtained in this investigation is as follows (the rudimentary tooth anlagen in parentheses):

$$\begin{array}{cccccccccc}
 I^1 & I^2 & I^3 & C & P^2 & P^3 & P^4 & M^1 & M^2 & M^3 \\
 Id^1 & Id^2 & (id^3) & cd & pd^2) & Pd^3 & Pd^4 & & & \\
 \hline
 (id_1) & Id_2 & (id_3) & cd & pd_2 & pd_3) & Pd_4 & & & \\
 (i_1) & I_2 & I_3 & C & P_2 & (p_3) & P_4 & M_1 & M_2 & M_3
 \end{array}$$

This formula diverges from that of *Winge* (1923) with regard to the permanent teeth. According to *Winge*, there is no lower third incisor but a first one, and only one lower premolar viz., the fourth.

The reduction of the teeth does not take place in quite the same succession in all Insectivora. Usually, the incisors are reduced in the postero-anterior direction. The third incisor is the first to be resorbed, as is the case in *Erinaceus europaeus* in the lacteal dentition, but also the lower first incisor of both dentitions is reduced. The reduction of the premolars usually occurs in an antero-posterior direction. In *Erinaceus europaeus* the lower third premolar is reduced in the lacteal as well as in the permanent dentition, thus, slightly more than the second premolar, which is reduced only in the lacteal dentition. This does not prove, however, that the order of reduction of the premolars is reversed, i.e. in a postero-anterior direction, as demonstrated by *Grahnén* (1956) in man. Both the second and the third premolars in *Erinaceus europaeus* are subjected to reduction, while the fourth premolar has never shown any sign of being reduced, being invariably the farthest developed premolar. For this reason, the present author questions *Grahnén's* contention that the fourth premolar in the permanent dentition in man should be more often reduced than the third.

#### RÉSUMÉ

##### DÉVELOPPEMENT DENTAIRE CHEZ ERINACEUS EUROPAEUS

Cette investigation a indiqué que chez *Erinaceus europaeus* une dentition temporaire et une dentition persistante sont ébauchées. Toutes les antémolaires forment un germe dentaire de lait, mais

ce sont seulement celui des première et seconde incisives, des troisième et quatrième prémolaires dans le maxillaire supérieur et de la seconde incisive et de la quatrième prémolaire dans le maxillaire inférieur qui arrivent à remplir leurs fonctions. Les prédécesseurs de la troisième incisive, de la canine et de la seconde prémolaire dans les deux mâchoires sont rudimentaires et se développent seulement jusqu'à la phase de la coupe avec une formation dégénérée de dentine. Les germes dentaires de lait dans le maxillaire inférieur se dissolvent à une plus récente période du développement que ceux de maxillaire supérieur.

Pendant l'ontogénèse la première incisive inférieure persistante est représentée seulement par une enflure de la bande dentaire et cela s'applique à son prédécesseur aussi.

La canine supérieure de la dentition de lait se ne développe pas rapidement et entièrement comme le décrit *Leche*, mais peu à peu comme les autres germes dentaires. Quand la canine persistante commence à se développer le prédécesseur s'est résorbé.

La troisième prémolaire inférieure persistante atteint à la phase de la coupe avant de dégénérer, mais son prédécesseur vient à la phase du bouton seulement.

La seconde dentition est composée dans le maxillaire supérieur de trois incisives, d'une canine, de trois prémolaires (la seconde, la troisième et la quatrième) et de trois molaires, et dans le maxillaire inférieur de deux incisives (la seconde et la troisième), d'une canine, de deux prémolaires (la seconde et la quatrième) et de trois molaires.

En ce qui concerne une quatrième incisive marsupiale comme *Woodward* en décrit, je n'en ai pas trouvé de vestiges. Je n'ai pas non plus observé de dentition pré lactéale ni de dentition postpermanente, contrairement à l'opinion de *Leche* et *Woodward*.

Je ne peux pas dire qu'un changement des dents a lieu dans l'utérus ou immédiatement après la naissance, ainsi que croyait *Tauber*, puisque les germes dentaires sont résorbés bien avant le développement complet. Les dents, que *Tauber* avait observées doivent correspondre aux germes dentaires rudimentaires.

Il ne semble pas y avoir de différence du développement dentaire chez le hérisson d'Angleterre et celui du Continent, comme

*Woodward* le croyait, et je n'ai pas non plus constaté de variation individuelle.

La formule dentaire d'*Erinaceus europaeus*, qui résulte de cette enquête, serait ainsi (les germes dentaires rudimentaires en parenthèse): (voir tableau à la page 484).

Cette formule diverge de celle de *Winge* (1923) concernant les dents persistantes. Selon *Winge* il n'y a pas une troisième incisive inférieure mais une première, et une seule prémolaire inférieure, c'est-à-dire la quatrième.

La réduction dentaire numérique n'a pas lieu entièrement dans le même ordre chez tous les Insectivores. Les incisives se sont résorbées d'arrière en avant d'ordinaire. La troisième incisive s'est résorbée la première, comme c'est le cas dans la dentition de lait d'*Erinaceus europaeus*, mais la première incisive inférieure des deux dentitions est réduite aussi. Le réduction des pré-molaires vient d'avant en arrière ordinairement. Chez *Erinaceus europaeus* la troisième prémolaire inférieure est résorbée dans la dentition de lait et dans la seconde dentition, donc un peu plus que la seconde prémolaire, qui est réduite dans la dentition de lait seulement. Cela ne prouve pourtant pas, que l'ordre de réduction des pré-molaires est inverse, c'est-à-dire d'arrière en avant, comme *Grahnén* (1956) l'a démontré chez l'Homme. La seconde et la troisième pré-molaires chez *Erinaceus europaeus* sont sujettes à une réduction, pendant que la quatrième prémolaire ne montre aucun indice dans ce sens, mais elle est toujours la prémolaire la plus développée. Je mets donc en question l'affirmation de *Grahnén*, selon laquelle la quatrième prémolaire de la dentition persistante chez l'Homme serait résolue plus souvent que la troisième.

#### ZUSAMMENFASSUNG

#### UNTERSUCHUNGEN ÜBER DIE ZAHNENTWICKLUNG BEI ERINACEUS EUROPAEUS

Diese Untersuchung zeigt, dass bei *Erinaceus europaeus* sowohl ein lakteaies als ein bleibendes Gebiss angelegt werden. Alle Antemolaren bilden eine Milchzahnanlage, aber nur die der oberen ersten und zweiten Incisivi, dritten und vierten Prämolare und die des unteren zweiten Incisivus und vierten Prämolars werden

funktionsfähig. Die Vorläufer des dritten Incisivus, des Caninus und des zweiten Prämolars beider Kiefer sind rudimentär und werden nur zu dem kappenförmigen Stadium mit einer degenerierten Dentinbildung entwickelt. Die Milchzahnrudimente des Unterkiefers werden in einem jüngeren Stadium als die des Oberkiefers resorbiert.

Während der Ontogenese ist der permanente untere erste Incisivus nur von einer Anschwellung der Zahnleiste vertreten und dieses gilt auch für ihren Vorläufer.

Der obere Milchcaninus entwickelt sich nicht rasch und vollständig wie *Leche* glaubte, sondern allmählich wie die anderen Zahnanlagen. Wenn der permanente Caninus anfängt sich zu entwickeln, ist sein Vorläufer resorbiert.

Der permanente untere dritte Prämolare erreicht das kappenförmige Stadium ehe er degeneriert, aber sein Vorläufer nur das knospenförmige Stadium.

Die zweite Dentition besteht im Oberkiefer aus drei Incisivi, einem Caninus, drei Prämolaren (dem zweiten, dritten und vierten) und drei Molaren, im Unterkiefer aus zwei Incisivi (dem zweiten und dritten), einem Caninus, zwei Prämolaren (dem zweiten und vierten) und drei Molaren.

Keine Spuren von einem vierten marsupialen Incisivus, wie *Woodward* verfechtete, habe ich beobachtet. Auch keine Spuren von einer prälakteen und einer postpermanenten Dentition sind von mir festgestellt worden, im Gegensatz zu *Leches* und *Woodwards* Meinungen.

Ein Zahnwechsel im Uterus oder unmittelbar nach der Geburt, wie *Tauber* vermutete, kann nicht behauptet werden, in Erwägung, dass die Zahnanlagen lange vor voller Entwicklung resorbiert sind. Die Zähne, auf die *Tauber* hindeutete, müssen den lakteen Zahnrudimenten entsprechen.

Es scheint kein Unterschied zu sein zwischen der Zahnentwicklung des englischen Igels und der des kontinentalen, wie *Woodward* in Frage stellt, auch keine individuellen Variationen in dieser Hinsicht sind von mir ermittelt worden.

Die folgende Zahnformel von *Erinaceus europæus* ist aus dieser Untersuchung gewonnen (die rudimentären Zahnanlagen sind eingeklammert). Siehe Seite 484.

Diese Zahnformel weicht bezüglich der bleibenden Zähne ab von der die *Winge* (1923) aufgestellt hat. Nach *Winge* gibt es keinen unteren dritten Incisivus aber einen ersten, und nur einen unteren Prämolare, nämlich den vierten.

Die Reduktion der Zähne findet bei allen Insectivoren nicht ganz in derselben Ordnung statt. Gewöhnlich werden die Incisivi in einer postero-anteriorlichen Reihe reduziert. Zuerst wird der dritte Incisivus resorbiert, wie es in der Milchdentition bei *Erinaceus europaeus* der Fall ist, aber auch der untere erste Incisivus beider Dentitionen wird reduziert. Die Reduktion der Prämolaren geschieht gewöhnlich antero-posteriorlich. In *Erinaceus europaeus* ist der untere dritte Prämolare sowohl in dem laktealen als in dem bleibenden Gebiss reduziert, folglich ist er etwas mehr reduziert als der zweite Prämolare, der nur in der laktealen Dentition verschwunden ist. Dieses beweist jedoch nicht, dass die Ordnung der Reduktion der Prämolaren die umgekehrte ist, d. h. in einer postero-anteriorlichen Reihe, wie *Grahnén* (1956) für den Menschen geltend macht. Sowohl der zweite als der dritte Prämolare in *Erinaceus europaeus* ist einer Reduktion ausgesetzt, der vierte Prämolare aber hat niemals eine Andeutung dazu gezeigt, sondern ist immer der meist entwickelte Prämolare. Aus diesem Grunde scheint mir die Behauptung von *Grahnén* sehr fraglich, dass der vierte Prämolare in der permanenten Dentition beim Menschen öfter als der dritte reduziert sein soll.

#### REFERENCES

- Baume, R.* 1882: Versuch einer Entwicklungsgeschichte des Gebisses. *Odontologische Forschungen*, Thl. 1.
- Blainville, M. de*, 1839—64: *Osteographie des Mammifères*. Paris.
- Blasius, J. H.* 1857: *Naturgeschichte der Säugethiere Deutschlands*. Fauna der Wirbelthiere Deutschlands, Bd 1.
- Dobson, G. E.* 1883: *A Monograph of the Insectivora, Systematic and Anatomical*, II. London.
- Fuchs, H.* 1912: Bemerkungen über das Gebiss des *Erinaceus europaeus*, gegründet auf das Fehlen eines unteren Incisivus. *Zeitschrift für Morph. u. Anthrop.* Stuttgart. Bd XIV.
- Grahnén, H.* 1956: Hypodontia in the permanent dentition. *Odontologisk Revy* Vol. 7, suppl. 3
- Huxley, T. H.* 1880: On the Application of the Laws of Evolution to the Arrangement of the Vertebrata. *Proc. Zool. Soc. London*.

- Kindahl, M.* 1956: The change of the teeth of *Erinaceus europaeus*. Proc. XIV. International Congress of Zoology, Copenhagen 1953.
- > 1957: On the development of the tooth in *Tupaia javanica*. Arkiv för zoologi. Ser. 2, Bd 10.
- > 1958: Some observations on the development of the tooth in *Elephantulus myurus Jamesoni*. Arkiv för zoologi. Ser. 2, Bd 11.
- > 1958: Notes on the tooth development in *Talpa europaea*. Arkiv för zoologi. Ser. 2, Bd 11.
- > 1959: On the tooth development in Soricidae. Acta odont. scand. 17: 203—237.
- Kollman, J.* 1870: Entwicklung der Milch- und Ersatzzähne beim Menschen. Wiss. zool. Bd 20.
- Leche, W.* 1895: Zur Entwicklungsgeschichte des Zahnsystems der Säugethiere, zugleich ein Beitrag zur Stammesgeschichte dieser Thiergruppe. I. Ontogenie. Stuttgart.
- > 1897: Zur Morphologie des Zahnsystems der Insectivoren. I, II. Anat. Anz. Bd 13.
- > 1902: Zur Entwicklungsgeschichte des Zahnsystems der Säugethiere, zugleich ein Beitrag zur Stammesgeschichte dieser Thiergruppe. 2. Teil. Phylogenie. 1. Heft. Die Familie der Erinaceidae. Stuttgart.
- Owen, R.* 1868: Comparative Anatomy and Physiology of Vertebrates. Vol. III. London.
- Rousseau, L. F. E.* 1839: Anatomie comparée du système dentaire.
- Sahlertz, J.* 1871: Tandsættet og Tandskiftet hos Pindsvinet (*Erinaceus europæus*). Vidensk. Meddel. fra d. Naturhistoriske Forening. Bd 23. Kjöbenhavn.
- Schlosser, M.* 1887—90: Die Affen, Lemuren, Chiropteren, Insectivoren, Marsupialier, Creodonten und Carnivoren des europäischen Tertiärs. Wien.
- Sundevall, C. J.* 1842: Öfversigt af slägtet *Erinaceus*. Svenska Vetenskapsakademiens Handlingar. Stockholm.
- Tauber, P.* 1872: Om Tandsæt og Levemaade hos de Danske Flagermus og Insektædere. Naturhist. Tidsskrift. Kjöbenhavn. Bd 8.
- Winge, H.* 1882: Om Pattedyrenes Tandskifte især med Hensyn til Tændernes Former. Vidensk. Meddel. fra d. Naturhistoriske Forening, Kjöbenhavn.
- > 1923: Pattedyr-slægter. I. Kjöbenhavn.
- Woodward, M. F.* 1896: Contribution to the Study of Mammalian Dentition. Part. II. On the Teeth of certain Insectivora. Proc. Zool. Soc. London.

Address: *Märtha E. Kindahl, Ph.D.*

*Linnégatan 22*

*Stockholm Ö*

*Sweden*