

From: Department of Anatomy  
The Royal Dental College, Aarhus,  
Denmark.

# CONGENITAL MALFORMATIONS OF UPPER INCISORS IN EXENCEPHALIC MOUSE EMBRYOS, INDUCED BY HYPERVITAMINOSIS A

## I. TYPES AND FREQUENCY\*

by

P. A. KNUDSEN

### INTRODUCTION

By administering large doses of vitamin A to pregnant rats and mice, it is possible to induce in some of the embryos various malformations of the brain, face, oral cavity, and extremities. The nature, location, and degree of deformity are largely determined by the stage of pregnancy chosen for the administration of vitamin A and by the size of the dose. The method was first employed by *Cohlan* (1953 and 1954) who induced, for example, exencephaly, hydrocephalus, cleft palate, and cleft lip in rats. *Giroud & Martinet* (1956) induced facial deformities in rat embryos and also found tooth anomalies in the form of molar aplasia or fusions of the molars, in upper and lower jaws. *Deuschle, Geiger & Warkany* (1959) induced oculo-dental-facial anomalies in rat embryos. The molars were either hypoplastic or absent. *Kalter* (1960) observed supernumerary, absent or ectopic teeth in mice, in association with various anomalies of the mouth and face. The molars appear to be especially affected, but instances of unilateral and bilateral supernumerary incisors and one instance of fused upper incisors are recorded. *Kalter & War-*

---

\* This investigation was supported by a grant from The Danish State Research Foundation.

*kany* (1961) discuss the occurrence of supernumerary lower incisors in mouse embryos in connection with other malformations.

In the works referred to, the existence of various forms of dental anomaly has been established without further description and without investigation of the frequency with which they occur, alone or in connection with developmental disturbances in other organ systems. The occurrence of dental anomalies in connection with developmental defects in the central nervous system has thus not been subject to experimental study, whereas the problem has been dealt with in several clinical works. Thus *Miles* (1954) stresses the association of dental anomalies with mental deficiency and mongolism in particular. *Forrester & Miller* (1955) found dental changes associated with Kernikterus. *Via & Churchill* (1957) found the incidence of enamel hypoplasia to be 68 % in children with congenital cerebral disorders of all types.

In order to investigate the form and size of the choroid plexus in malformed brains, the present author induced cerebral malformations in mouse embryos by overdosing pregnant mice with vitamin A. The most frequent malformation was exencephaly (anencephaly). In this condition, which is also known in human pathology, both bones and soft tissues are lacking in the cranial roof, and the exposed surface of the brain is in direct contact with the amniotic fluid (Fig. 1, Plate 1). As various disturbances in the development of the oral cavity and teeth were observed in many of the exencephalic embryos, the investigation was extended to include a study of those dental changes which appear to occur quite frequently with this brain deformity. The present study summarizes the nature and frequency of the demonstrated changes in the upper incisors. A detailed description of the most characteristic deformities and the report of an investigation into lower incisors and molars are in preparation.

#### METHODS AND MATERIALS

Female mice of an inbred strain AK/a were placed with males of the same strain, one pair to a cage, and examined in the morning 24 hours later for a vaginal plug. Day 1 of pregnancy is taken

Table 1.

*Dosage of Vitamin A (I.U.), subcutaneously injected or orally administered on days 7 to 9 of gestation, to effect 272 exencephalic embryos included in the present investigation.*

Number of exencephalic embryos	Subcutaneous injection		Oral administration						
	6	67	2	109	45	8	26	5	4
Day of gestation:									
Day 7	4000	5000	4000	7500	5000	3000	7500	10000	15000
Day 8	0	0	0	0	0	3000	0	0	0
Day 9	0	0	0	0	3000	3000	2500	0	0
Total dose of Vitamin A	4000	5000	4000	7500	8000	9000	10000	10000	15000

as the day on which the copulation plug is found in the vagina of the mouse. The males were then removed and the impregnated females given from 4,000 to 15,000 I.U. vitamin A on days 7 to 9 of pregnancy. (For details see Table 1.) At the start of the experiment, a subcutaneous injection of an aqueous preparation of vitamin A was administered. Later, vitamin A in oil was administered orally by means of a blunt-ended needle and a syringe. The females were killed on days 16, 17, 18 or 19 of pregnancy, *i.e.*, about 1 to 4 days before term. The foetuses were removed, examined macroscopically and then fixed in Bouin's fluid. After 2 to 3 days' fixation and after photographing the foetus, its head was embedded in paraffin wax and cut in serial sections. Section thickness was 7 or 10  $\mu$ , and the sections were in most cases stained with haematoxylin-eosin. In some cases whole series or parts of a series were stained with pentachrome by the technique of *Movat* (1955) or with van Gieson's stain. All histological sections with incisor germs were examined and all important changes were registered on a special form. The most important changes were studied in a large number of microphotographs. Reichert's Visopan microscope was used for examining sections.

The measurements of the distance between the tooth germs and of the angle between their long axes, presented below, were made with a ruler and protractor directly on the projection screen of the microscope. The distance measurements are given in Length Units (L.U.), corresponding to the number of millimetres measured on the projection screen with 70 times linear enlargement.

In the present study, 272 exencephalic embryos were investigated, 73 being effected by injection and 199 by oral administration of vitamin A (Table 1). 260 of the embryos were sectioned frontally and 12 sagittally. A further 100 normal embryos at corresponding stages of development were examined with the view of describing the normal form and position of the incisors. 30 of the normal embryos were measured as described above.

## RESULTS

The incisor region of the upper jaw shows changes in many of the exencephalic embryos, and on the basis of the appearance of this region the embryos can be divided into 4 main groups.

### *Group I*

comprises embryos with two incisor germs separated by connective tissue.

### *Group II*

comprises embryos with two incisor germs, the mesial surfaces of which are locally *in contact*.

### *Group III*

comprises embryos with only *one* incisor germ in the upper jaw, and *where all the layers of the enamel organ (epithelial dental organ) as well as dentine and pulp with odontoblasts, cross the midline*. This condition is called *fusio dentium*.

### *Group IV*

comprises embryos where incisor germs are lacking on one or both sides of the upper jaw. This condition is named *agenesia dentium*.

Table 2 shows how frequently the various groups occur.

Table 2.

272 exencephalic mouse embryos, divided into four groups, according to the appearance of their upper incisors.

	Two incisors		Fusio dentium	Agenesis dentium		Total
	Separated by connective tissue	In contact		Unilateral	Bilateral	
	Group I	Group II	Group III	Group IV		
Number of embryos	107	2	140	3	20	272
Per cent	39.3	0.7	51.5	1.1	7.4	100

*Group I*

This large group exhibits many variations as to the distance between the incisor germs. In many exencephalic embryos, little or no difference from the normal is seen (cf. Figs. 2 and 3), while in other cases the distance is remarkably small. Examples of small intervals between germs (from 6 to 1 L.U.) are shown in Figs. 4—7. The layer of connective tissue separating the germs can be very thin, sometimes corresponding in thickness to an ameloblast layer (Fig. 7).

In order to obtain an exact expression for the variations in mesial displacement of the incisor germs, the smallest distance between the germs was measured in 30 normal and 104 exencephalic embryos. The results are given in Length Units (L.U.) and Text Fig. I gives the distribution for each group. In the group with normal embryos, only values of 14—20 L.U. occur, whilst values from 0—20 L.U. are found among the exencephalic embryos. In 45.2 % of the latter the distance is less than 14 L.U., which is the lower limit for the normal group.

Normal incisor germs in the upper jaw are connected with the epithelium of the oral cavity by an "epithelial lamina", which includes part of the stellate reticulum and the outer dental epithelium of the enamel organ. In normal mouse embryos the two plates are entirely separated by connective tissue and are only indirectly connected by oral epithelium (Figs. 2 and 3). On the other hand, many of the exencephalic embryos exhibit a partial

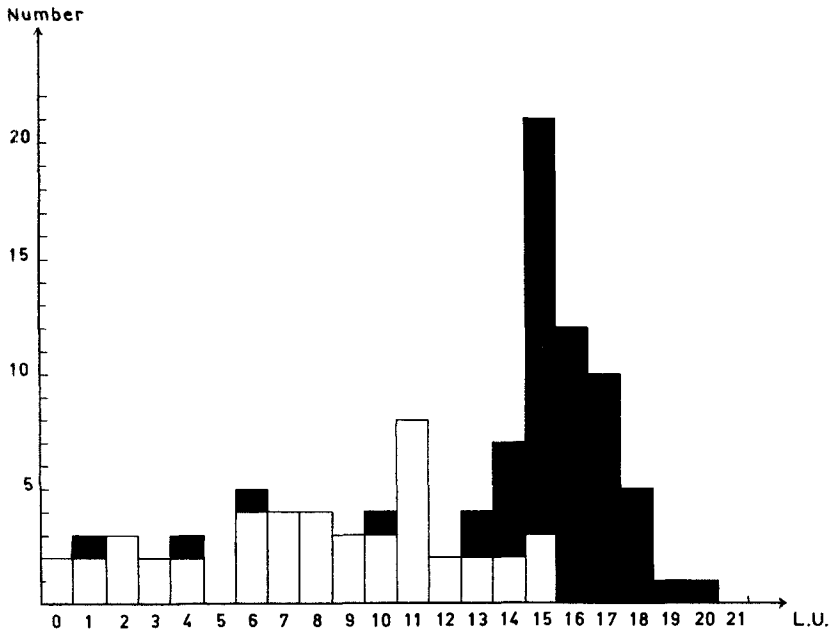
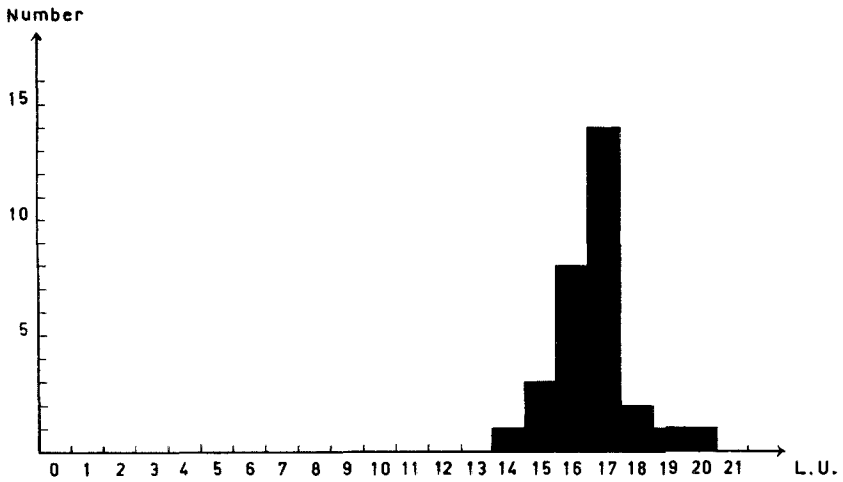


Fig. 1. Shortest distance between the upper incisor germs. *Above*: 30 normal embryos. *Below*: 104 exencephalic embryos (Groups I and II). The unshaded columns denote embryos with the enamel organs connected near the oral epithelium. L.U. = Length Units.

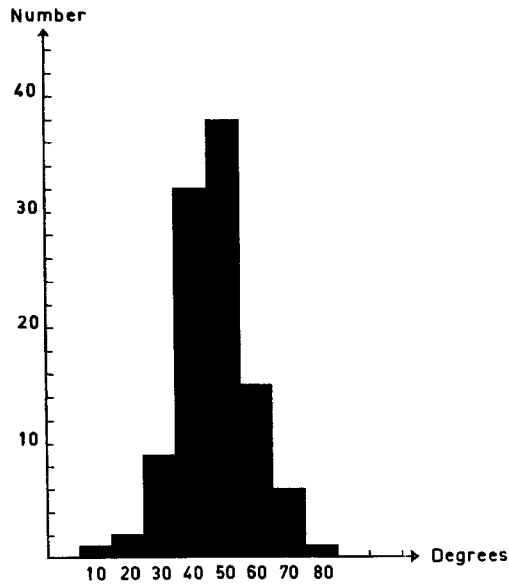
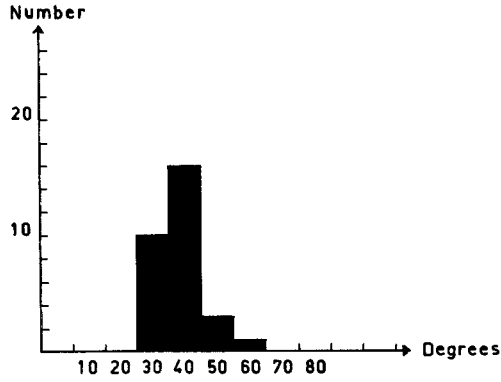


Fig. II. Size of the angle formed by the long axes of the upper incisor germs.  
*Above: 30 normal embryos, Below: 104 exencephalic embryos.*

fusion of the stellate reticula in the two germs. This is particularly the case when the distance between the germs is reduced. Fusion is seen in Figs. 4, 5, and 6. The extent of fusion from front to back is apparent from Figs. 11—15, which show five frontal sections from the same foetus. Anteriorly there is no connection between the stellate reticula of the two sides (Fig. 11). Further back the two enamel organs are connected with the epithelium of the oral cavity, which together with an incipient connection consisting of stellate reticulum and outer dental epithelium limits a recess containing mesenchyme (Fig. 12). In the following section the bridge has grown in thickness, and the recess is reduced (Fig. 13). In later sections, the stellate reticulum and the outer dental epithelium form a Y-shaped connection with the oral epithelium, and the recess has disappeared (Fig. 14). At the posterior end, the connection with the oral epithelium is V-shaped (Fig. 15).

As is seen from Text Fig. I, where the unshaded areas denote partial fusion of the stellate reticula in the two enamel organs, the possibility of fusion is present even with a germ interval of up to 15 L.U. When this distance is under 12 L.U., fusion is absent in only a few cases.

In several exencephalic embryos the position of the incisor germs in frontal sections deviates considerably from normal. This can be seen by comparing Figs. 6 and 7 with Fig. 3. By measuring the angle between the long axes of the germs one obtains an indication of the considerable variations which occur. The distribution of angle sizes in 30 normal and 104 exencephalic embryos is presented in Text Fig. II. The maximum angle for the normal embryos examined is about  $60^\circ$ , while 23.1 % of the exencephalic embryos show an angle of  $60^\circ$  or more. The relation between the angle formed by the long axes and the shortest distance between the germs is recorded in Text Fig. III, where fusion of the enamel organs is also indicated. Fusion is rare with angles under  $45^\circ$  and is entirely absent with angles under  $40^\circ$ . In three cases of angles between  $15^\circ$  and  $35^\circ$  and with distances between 1 and 6 L.U., fusion is absent, in spite of the short distances between the germs. These three cases correspond to three of the shaded columns to the left in Text Fig. I.

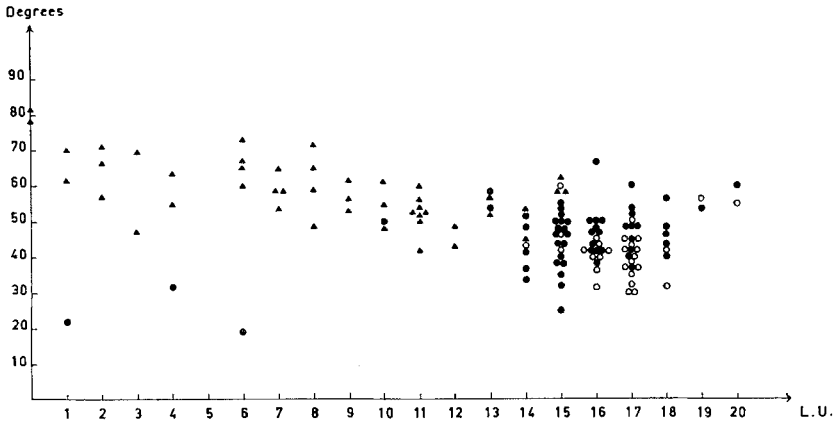


Fig. III. Relation between the angle formed by the long axes of the upper incisor germs and the shortest distance between the germs. *Ordinate*: Size of angle. *Abscissa*: Shortest distance (L.U. = Length Units). o, normal embryos; ●, exencephalic embryos with completely separated incisor germs; ►, exencephalic embryos with a connection between the enamel organs.

*Group II*

This group is sparsely represented, but as it comprises embryos with 'contact' between the incisor germs, it forms a natural transition between group I, where the germs are separate, and group III, where they are fused. An examination of all the sections from the region of the incisors shows that nowhere in the contact area is there a connection either between the dentine layers or between the pulps of the two sides. Moreover, the germs are not in contact in their whole length, but are separated by connective tissue in quite large areas. Figs. 8 and 9 show that there is contact anteriorly as well as centrally, where the largest area of contact is found. Here the two germs lie so close that the ameloblast layers apparently touch, as no other layer of the enamel organ is clearly seen. At the anterior end there seems to be contact between the outer dental epithelia in the two germs, and the stellate reticulum is seen in both (Fig. 8). At the posterior end there is no contact (Fig. 10).

*Group III*

This is the largest group, and it exhibits so many variations that systematization is only broadly possible.

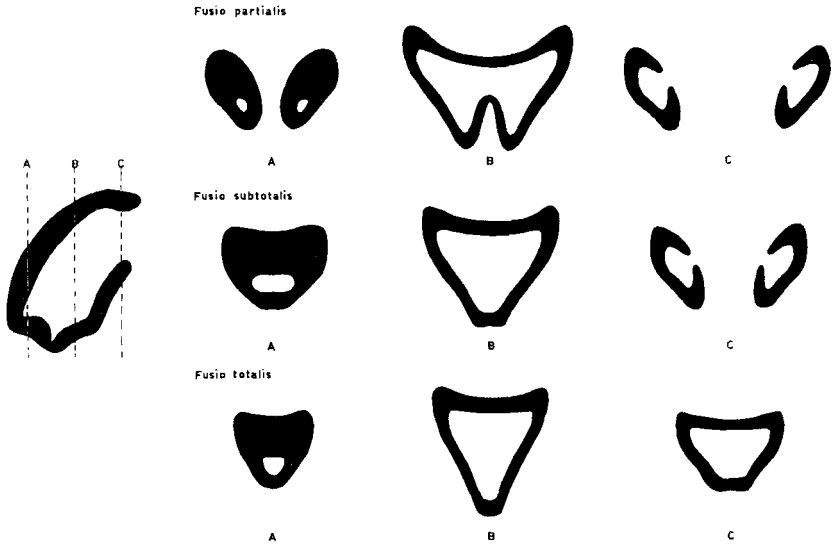


Fig. IV. Diagrammatic representation of the three degrees of fusio dentium. The locations of the three frontal sections used in the figures on the right are given on the sagittal section on the left.

A: anterior (incisal) end of the tooth germ  
 B: central part of the tooth germ  
 C: posterior (basal or apical) end of the tooth germ.

Three degrees of fusio dentium are distinguished: (1) *fusio partialis*, (2) *fusio subtotalis*, and (3) *fusio totalis*. Text Fig. IV shows the different degrees of fusio dentium.

In *fusio partialis*, the fusion is absent both at the anterior (incisal) and the posterior (basal or apical) end; and only in the central portion is there a connection over the mid-line between pulps, dentine and all layers of the enamel organs of the two sides. In *fusio subtotalis*, the fusion is absent only at the posterior end, and in *fusio totalis* only one tooth germ without signs of division is seen in all frontal sections. Table 3 shows that fusio totalis occurs in about 79 % of the 130 exencephalic embryos with fused upper incisors examined in frontal serial sections.

*Fusio partialis* forms an even transition between Group II, with contact between the two germs, and the more developed forms of fusio dentium. The anterior end of the tooth germ con-

Table 3.

*Fused upper incisors in 130 frontally sectioned exencephalic mouse embryos.*

	Fusio dentium			
	Fusio partialis	Fusio subtotalis	Fusio totalis	Total
Number of embryo:	10	17	103	130
Per cent	7.7	13.1	79.2	100

sists of two parts, which are closely adposed. Further back (Fig. 16), the two ameloblast layers near the mid-line are still well defined, while under the nasal septum there is a connection between the outer dental epithelia and the stellate reticula of the two sides. Further back still, the ameloblasts also continue across the mid-line corresponding to the nasal portion of the germ, and near the oral epithelium two extensions of the enamel organ can be seen separated from each other and from the epithelium by highly vascular tissue (Fig. 17). The following sections show an incipient connection between the dentine layers of the right and left sides. Furthermore there is established a connection between the two extensions of the enamel organ, which form a common stem which is connected with the oral epithelium. A recess full of connective tissue is thereby formed (Fig. 18). In the following frontal sections, the pulp with odontoblasts connects the two sides, the enamel organ forming a broad stem, connected to the oral epithelium, the recess having disappeared (Fig. 19). The 'pulp bridge' across the mid-line increases in height in the following sections, and the enamel organ has a larger connection with the oral epithelium. At the same time the border facing the stellate reticulum becomes irregular, ameloblasts, dentine and odontoblasts forming an irregular line with four projections of pulp directed towards the oral epithelium (Fig. 20). In the following sections, the connection between the pulps of the right and left sides narrows. The enamel organ's connection with the oral epithelium again divides and is separated by a recess filled with connective tissue, which is much larger than the first-mentioned. Next, the connection between

the layers of the enamel organ in the region below the nasal septum is lost (Fig. 21). The pulp bridge becomes narrower still and finally disappears. The posterior end of the tooth germ consists of two completely separated parts, which in form and location resemble the posterior ends of normal upper incisors (Fig. 22).

*Fusio subtotalis* is the second commonest type of fusion. It requires no special description. It resembles fusio partialis centrally and posteriorly, whilst the most anterior (incisal) part corresponds to the anterior part of fusio totalis. The oral portion of the stellate reticulum and the outer dental epithelium are centrally and posteriorly as described for fusio partialis.

*Fusio totalis* is the commonest and most complete type of fusio dentium. There are many morphological variations, but in all cases the pulp, dentine, and all the layers of the enamel organ cross the mid-line. The incisor germ appears in all frontal sections as one body, without any sign of division, as in Figs. 23—29, which are from the same embryo. In the most anterior section, where the incisor germ is cut tangentially, the outer dental epithelium and the stellate reticulum can be followed right around the germ (Figs. 23 and 24). The following sections show a connection across the mid-line for all layers of the germ, and the oral portions of the stellate reticulum and dental epithelium have formed a common stem, approaching the oral epithelium (Figs. 25 and 26). The connection between the enamel organ and the oral epithelium is seen in the following sections, where the width of the oral portion of the stellate reticulum is considerable (Figs. 27—29).

#### *Group IV*

Most embryos in this group lack both incisor germs in their upper jaws (Table 2). There are a few cases of unilateral agenesis, where the germ present does not cross the mid-line, thereby clearly differing from fusio dentium (Figs. 30 and 31). The unilateral location of the germ is emphasized by the well developed bone lamina in the mid-line, which forms the mesial alveolar wall. The form and size of the germ vary considerably and differ essentially from those of normal germs (cf. Fig. 2).

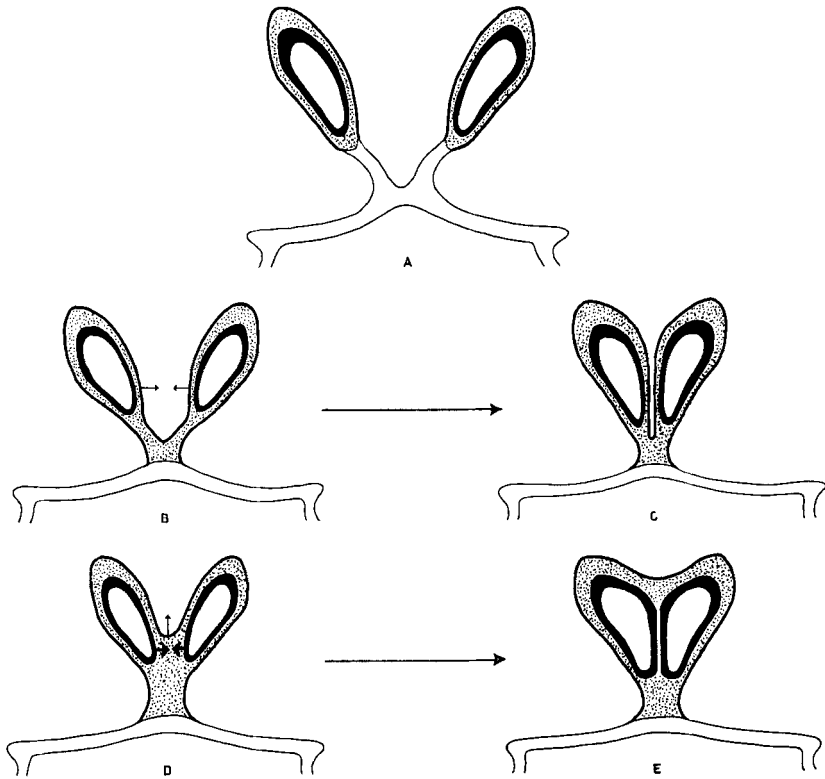


Fig. V. Diagrammatic representation of frontal sections.

Thick black line: ameloblasts

Dotted area: stellate reticulum

Black line surrounding dotted area: outer dental epithelium

Thin black line: oral epithelium.

A: *Normal upper incisor germs.* No connection between the enamel organs.

B-E: *Exencephalic embryos.*

B: Stellate reticula and outer dental epithelia are common for the oral parts of the enamel organs. Mesial displacement (small arrows) would lead to C.

C: 'Contact' between the incisor germs. All layers of the enamel organs are still represented mesially.

D: Stellate reticula and outer dental epithelia are common to a greater extent than in B. Mesial displacement (small arrows) would lead to E.

E: 'Contact' between the incisor germs. No intervening layers between the ameloblasts mesially.

## DISCUSSION

The problems touched on in the following will be more thoroughly discussed, when the results of current experiments become available. These experiments aim at studying the condition of the incisor germs with various forms of hydrocephalus in mouse embryos and with exencephaly induced in other animals by vitamin A overdosage. It is also being investigated whether exencephaly induced by other methods than vitamin A overdosage is accompanied by dental anomalies.

The cause of the anomalies described in the present paper is not known. The possibility of a direct influence of vitamin A on the primordia of the incisors cannot be excluded. The frequency with which dental anomalies occur in the exencephalic embryos rather seems to indicate a connection between brain defect and dental anomaly, without it being possible at the moment to explain the nature of this connection or to describe the processes leading to the changes. It might be that the dental anomalies are results of the cranial changes resulting from the abnormal brain development. The neurocranium, which is especially affected, has an intimate connection through the cartilaginous nasal capsule with the facial cranium and especially the primordial upper jaw. An analysis of cranial changes in mouse embryos will possibly yield interesting information.

A more direct effect of cerebral defects on tooth development should be considered in the light of the inductive effect the nervous system is believed to have on tooth formation. *Pourtois* (1961) believes that some observations support the inductive role of the trigeminal neural crest at the first stage of tooth development in the mouse. He places special emphasis on an RNA-rich cell region (mesectodermal cells), extending from the neural crest to the portion of the oral epithelium where the tooth germs are formed. *Dalcq* (1953) has demonstrated in rats and hamsters similar dense basophilic cell groups, which he believes induce tooth formation, without, however, mentioning their connection with the neural crest. If the inductive effect of the neural crest is decisive for tooth formation, it is possible that the severe changes in the exencephalic brain cause the formation of abnormal incisor germs by 'anomalous action' on the oral epithelium.

The designation 'fusio dentium' is appropriate to the appearance of the unpaired incisor germs at the end of foetal life. Moreover, the impression of 'fusion' is conveyed by the peculiar tendency to mesial displacement of the incisor germs, which in the material studied appears with an even transition from the normal distance between germs, via contact, to increasing degrees of connection across the mid-line. Whether fusion of two originally separate germs actually occurs or whether there is only one germ right from the earliest stages of fusio dentium, cannot be decided on the basis of the embryos examined so far.

In the definition of fusio dentium of the upper incisors it is emphasized that all the layers of the enamel organ together with the dentine and the pulp continue across the mid-line. The degree of fusio dentium is dependent on the antero-posterior extent of this connection. On the basis of these definitions, the material described is divided into four groups, of which Groups I and II comprise all embryos with two independent incisor germs in the upper jaw. A different conception of fusio dentium is, however, possible on the basis of the conditions of the enamel organ in a series of embryos belonging to Groups I and II. While normal mouse embryos have two quite separate incisor germs (Text Fig. V A), Groups I and II include 46 (of 109 exencephalic) embryos, in which the regions of the stellate reticulum (with stratum intermedium) and the outer dental epithelium situated nearest the oral epithelium cross the mid-line. As some of the layers of the enamel organ thereby fulfill the conditions of fusio, the two germs can be conceived as one — highly cleft — incisor germ. The division of the incisor germ will be more or less pronounced, dependent on the height of the stellate reticulum at the mid-line (Text Fig. V B and D).

Group II lacks, as does Group I, connection across the mid-line for the ameloblast layer as well as for the pulp and dentine. The ameloblasts from the two sides follow mesially an almost straight line and are so close, that there is apparent contact (Fig. 9). It cannot be determined with certainty, however, whether there are traces of outer dental epithelium and stellate reticulum, or of reticulum alone, between the ameloblasts in the region of contact (Fig. 32). If both layers are represented, stratification corresponds to that shown diagrammatically in Text Fig. V C.

This form could arise from the 'mesial displacement' of the germs shown in Text Fig. V B. If the outer dental epithelium has entirely disappeared between the two ameloblast layers, stratification must correspond to that shown in Text Fig. V E. This form could arise from mesial displacement to contact between the ameloblast layers in Text Fig. V D with simultaneous displacement in the nasal direction of the outer dental epithelium and an entire or partial exclusion of the stellate reticulum. As this possibility, on the basis of Fig. 32 and other sections, seems to be the most probable, it means that 'contact' in Group II is established between parts of the enamel organ in the same tooth germ and not between enamel organs from two different germs.

#### SUMMARY

272 mouse embryos in which exencephaly had been induced by maternal overdosage of vitamin A were investigated with reference to dental malformations. This paper reports malformations of upper incisors only. More than half of the embryos (51.5 %) show fusion of upper incisors. Three degrees of fusion are distinguished, *fusio partialis* (7.7 %), *fusio subtotalis* (13.1 %), and *fusio totalis* (79.2 %).

In 40 % of the embryos, the incisor germs are described as separate, even though a great number of them show fusion of the stellate reticula near the oral epithelium. It is discussed whether it is preferable to consider the two incisors thus connected as one strongly cleft tooth germ.

The distance between right and left incisors varies considerably and is often remarkably small. In 45.2 % of the embryos it is smaller than the distance measured in normal embryos. In a few cases 'contact' between incisor germs was observed (0.7 %). Tentative interpretation of this finding is presented. Agnesia dentium sometimes occurs on both sides (7.4 %) rarely on one side (1.1 %). The causal relationship between the effect of vitamin A and dental malformations is briefly discussed.

## RÉSUMÉ

MALFORMATIONS CONGÉNITALES DES INCISIVES SUPÉRIEURES CHEZ  
DES EMBRYONS DE SOURIS EXENCÉPHALES PAR SUITE D'HYPER-  
VITAMINOSE A.

## I. TYPES ET FRÉQUENCE

272 embryons de souris chez qui une exencéphalie avait été provoquée par surdosage maternel de vitamine A ont été examinés en ce qui concerne les malformations dentaires. Le présent article ne rend compte que des malformations des incisives supérieures. Plus de la moitié des embryons (51,5 %) présentaient une fusion des incisives supérieures. On distingue trois degrés: *fusion partielle* (7,7 %), *fusion subtotale* (13,1 %) et *fusion totale* (79,2 %).

Chez 40 % des embryons, les germes des incisives sont décrits comme séparés, bien qu'un grand nombre d'entre eux ait présenté une fusion du reticulum étoilé au voisinage de l'épithélium buccal. L'auteur discute le problème de savoir s'il est préférable de considérer comme un seul germe dentaire fortement divisé les deux incisives ainsi soudées.

La distance entre les incisives droite et gauche varie considérablement et est souvent remarquablement petite. Dans 45,2 % des embryons, elle est plus petite que la distance mesurée sur les embryons normaux. Dans quelques cas, on observe un "contact" entre les germes des incisives (0,7 %). L'auteur présente une tentative d'interprétation de ces résultats. Une agénésie dentaire est parfois observée des deux côtés (7,4 %), rarement d'un seul côté (1,1 %). Les relations de cause à effet entre l'action de la vitamine A et les malformations dentaires font l'objet d'une brève discussion.

## ZUSAMMENFASSUNG

ANGEBORENE MISSBILDUNGEN DER OBEREN SCHNEIDEZÄHNE IN  
EXENCEPHALEN MÄUSEMBRYONEN DURCH ÜBERDOSIERUNG  
MIT A-VITAMIN VERURSACHT

272 exencephale Mäuseembryonen verursacht durch Überdosierung der Mütter mit A-Vitamin sind mit Bezug auf dentale Missbildungen untersucht worden. Diese Arbeit berichtet nur von Missbildungen von oberen Schneidezähnen. Mehr als die Hälfte

der Embryonen (51,5 %) zeigt Fusion der oberen Schneidezähne. Drei Stufen von Fusion sind zu erkennen: fusio partialis (7,7 %), fusio subtotalis (13,1 %) und fusio totalis (79,2 %).

Bei 40 % der Embryonen sind die Schneidezahnanlagen als getrennt beschrieben, obwohl eine grosse Anzahl davon Fusion von der Schmelz-Pulpa in der Nähe des Mundepithels zeigen. Es wird diskutiert, ob es vorzuziehen ist, die zwei so verbundenen Schneidezähne als eine stark gespaltene Zahnanlage zu betrachten.

Die Entfernung zwischen den rechten und den linken Schneidezähnen variiert beträchtlich und ist oft beachtlich klein. Bei 45,2 % ist sie kleiner als die Entfernung bei normalen Embryonen gemessen. In einigen wenigen Fällen hat man "Kontakt" zwischen der Schneidezahnanlagen observiert (0,7 %). Die mögliche Erklärung dieses Fundes ist in Erwägung gezogen. Agenesia dentium kommt zuweilen bilateral vor (7,4 %) selten unilateral (1,1 %). Die kausale Verbindung zwischen der Wirkung des A-Vitamins und der Zahnmissbildung wird kurz erörtert.

#### REFERENCES

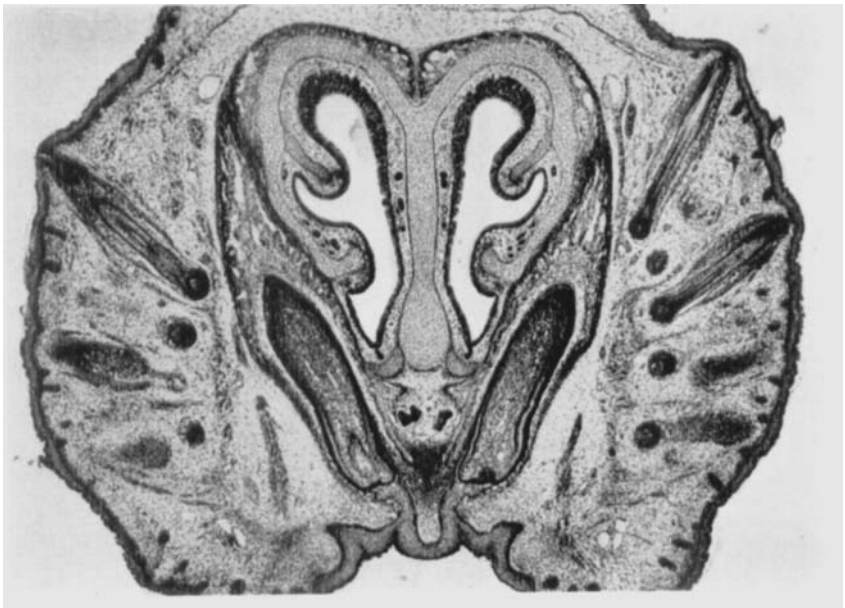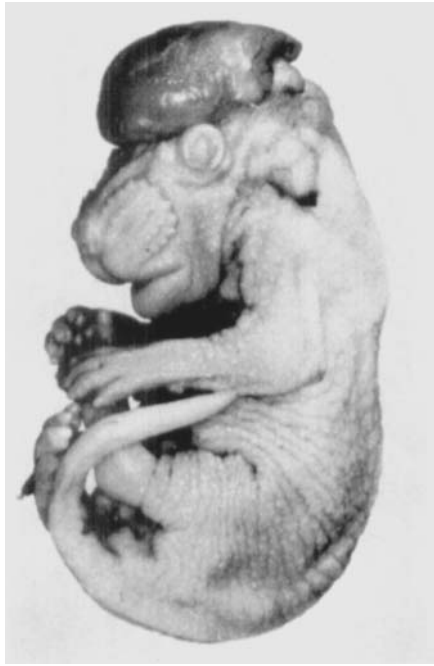- Cohlan, S. Q.*, 1953: Excessive intake of vitamin A as a cause of congenital anomalies in the rat. *Science* 117: 535—536.
- »— 1954: Congenital anomalies in the rat produced by excessive intake of Vitamin A during pregnancy. *Pediatrics* 13: 556—567.
- Dalcq, M. A.*, 1953: Ribonucléines et polysaccharides dans les ébauches dentaires des Rongeurs. *C. R. Soc. Biol.* 147: 2038—2040.
- Deuschle, F. M., J. F. Geiger & J. Warkany*, 1959: Analysis of an anomalous oculodentofacial pattern in newborn rats produced by maternal hypervitaminosis A. *J. dent. Res.* 38: 149—155.



**Plate 1.**

*Fig. 1.* Exencephalic mouse embryo. 18 days.

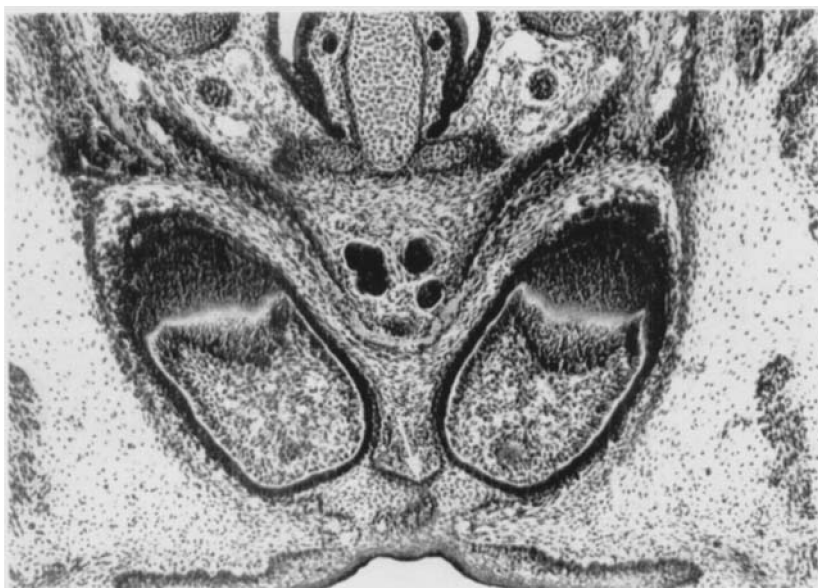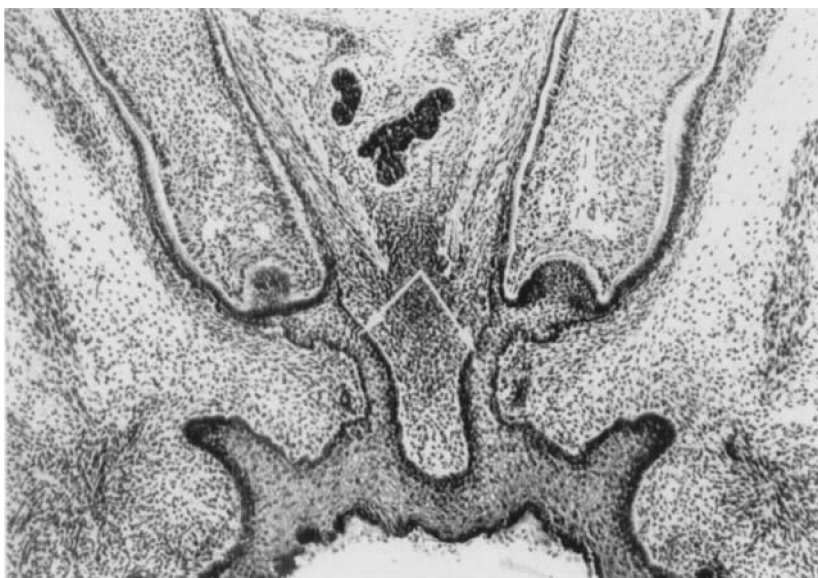*Fig. 2.* Normal mouse embryo (73 d III/2). Frontal section. The two incisor germs are each connected to the oral epithelium by an 'epithelial lamina'. ( $\times 25$ ).



## Plate 2.

*Fig. 3.* Epithelial laminae in a normal mouse embryo (29 d I/4). Frontal section. The portion nearest the tooth comprises stellate reticulum and outer dental epithelium, whilst the remainder has the same appearance as the epithelium in the oral cavity (arrows show the transition). ( $\times 63$ ).

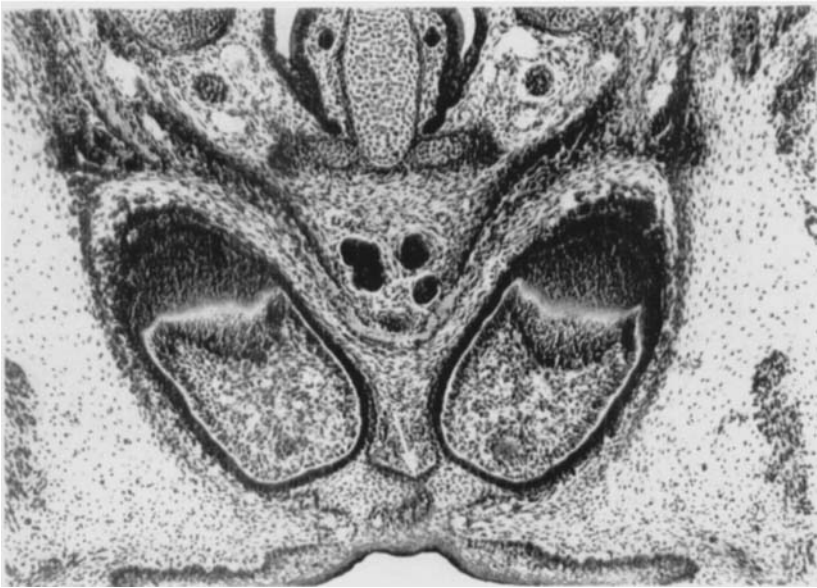
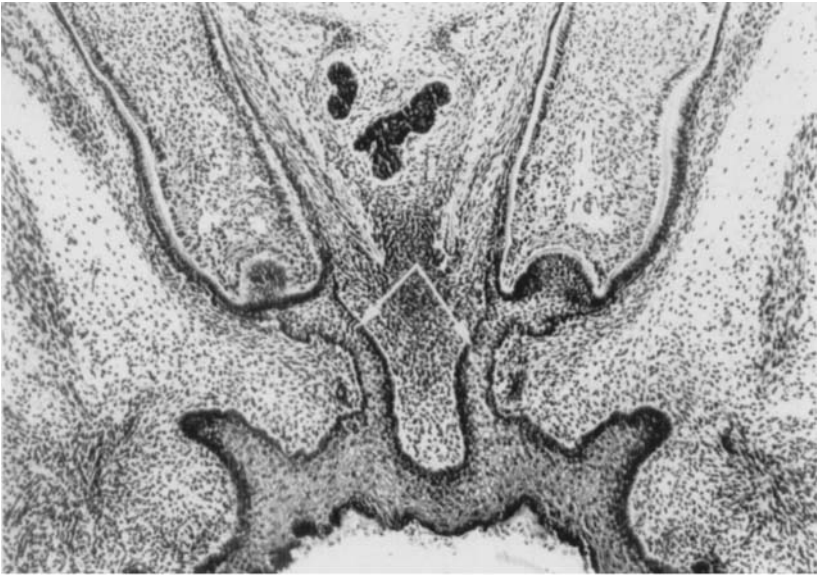*Fig. 4.* Exencephalic mouse embryo (150 d I/3). Frontal section. The shortest distance between the incisor germs is 6 L.U. There is a connection between the oral parts of the enamel organs (arrow). ( $\times 63$ ).



### Plate 3.

*Fig. 5.* Exencephalic mouse embryo (165 d I/2). Frontal section. Shortest distance between the germs is 4 L.U. The stellate reticula and the outer dental epithelia are joined in the oral parts of the enamel organs (arrow). ( $\times 63$ ).

*Fig. 6.* Exencephalic mouse embryo (79 d I/3). Frontal section. The shortest distance between the incisor germs is 2 L.U. The enamel organs are joined in the oral parts (arrow). The angle between the long axes is  $66^\circ$ . ( $\times 63$ ).

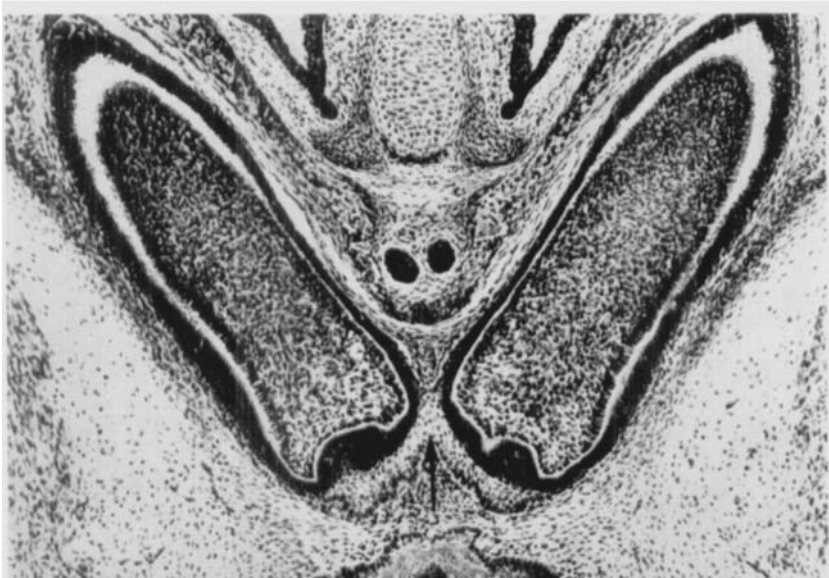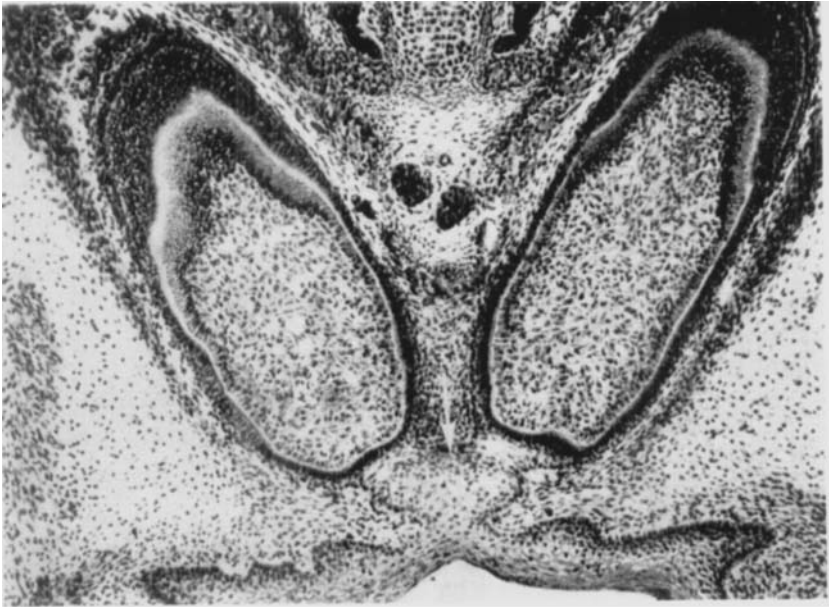


#### Plate 4.

*Fig. 7.* Exencephalic mouse embryo (150 d I/2). Frontal section. The shortest distance between the incisor germs is 1 L.U. The angle between the long axes is  $22^\circ$ . There is no connection between the oral parts of the enamel organs. ( $\times 63$ ).

Figs. 8-10. Exencephalic mouse embryo (180 d I/2). Frontal sections. ( $\times 63$ ).

*Fig. 8.* Contact between the incisor germs anteriorly.

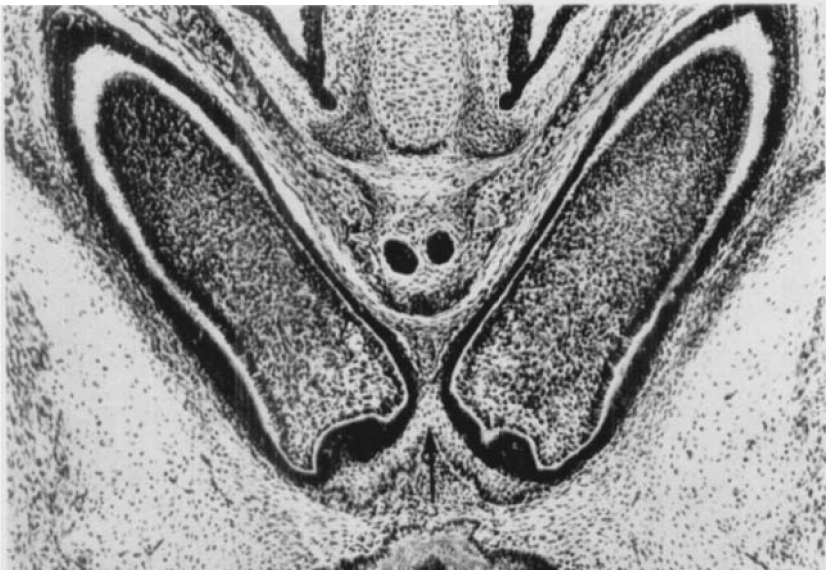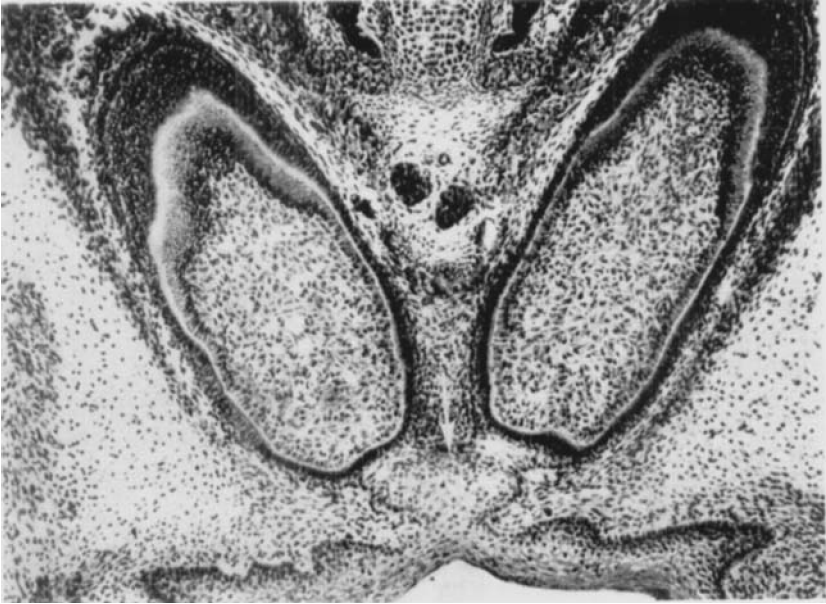


## Plate 5.

Figs. 8-10 (continued)

*Fig. 9.* Contact between the incisor germs centrally. The stellate reticula and outer dental epithelia are common for the oral parts of the enamel organs.

*Fig. 10.* Posteriorly the germs are separated by connective tissue. The stellate reticula and outer dental epithelia are common for the oral parts of the enamel organs.

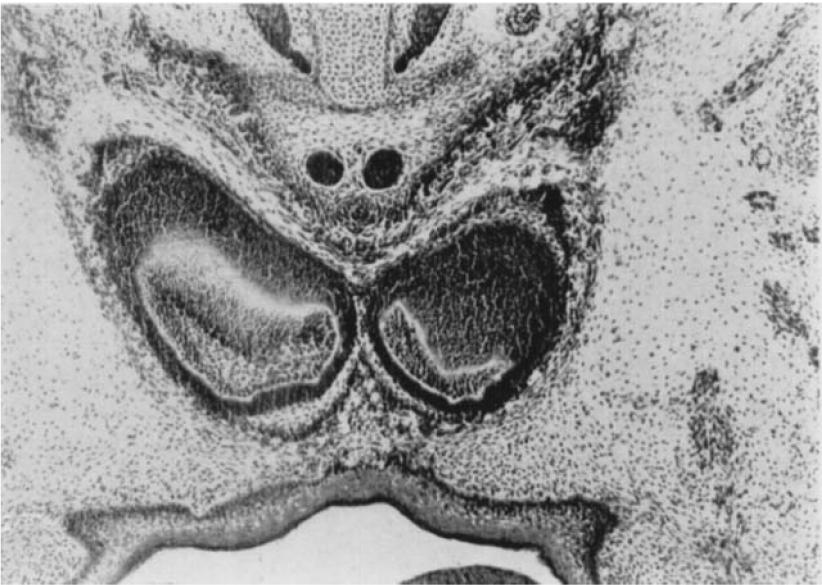
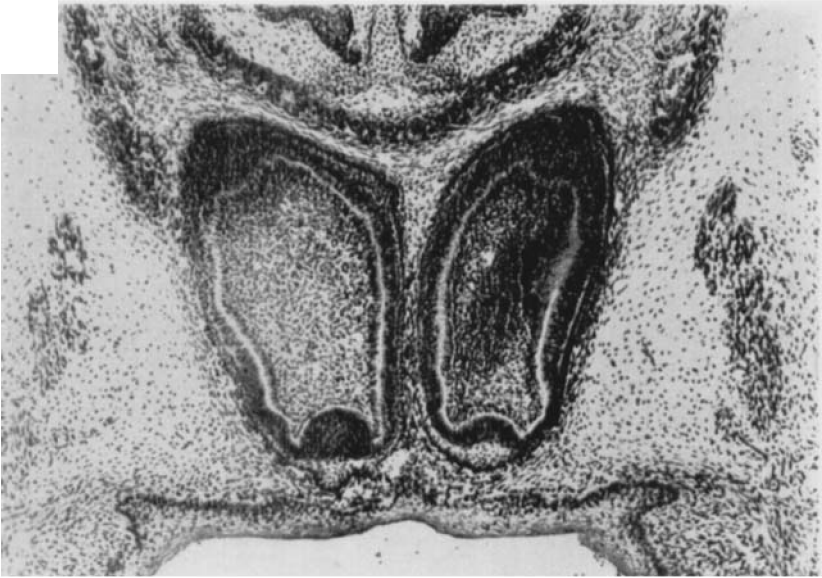

## Plate 6.

Figs. 11-15. Exencephalic mouse embryo (66 d I/3). Frontal sections. The shortest distance between the incisor germs is 6 L.U. ( $\times 63$ ).

*Fig. 11.* The two germs are entirely separate.

*Fig. 12.* Incipient connection between the oral portions of the enamel organs with the enclosure of a recess (arrow).

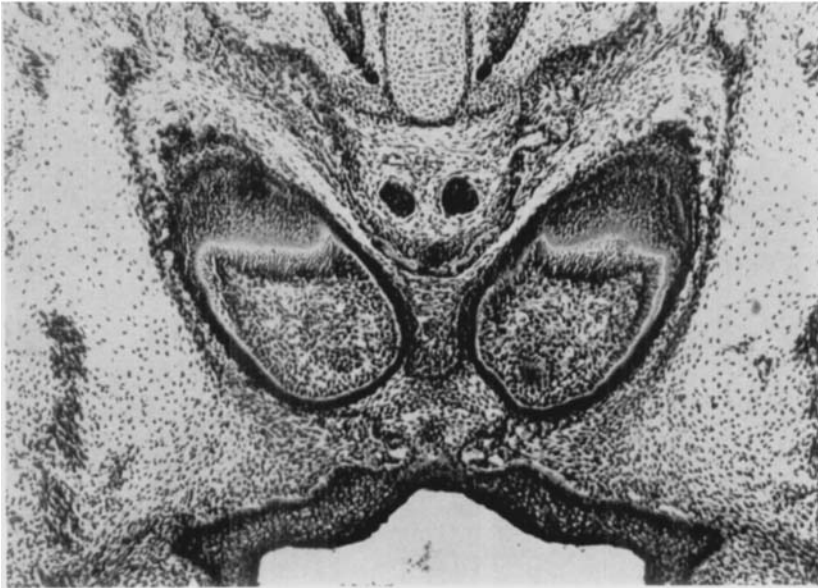
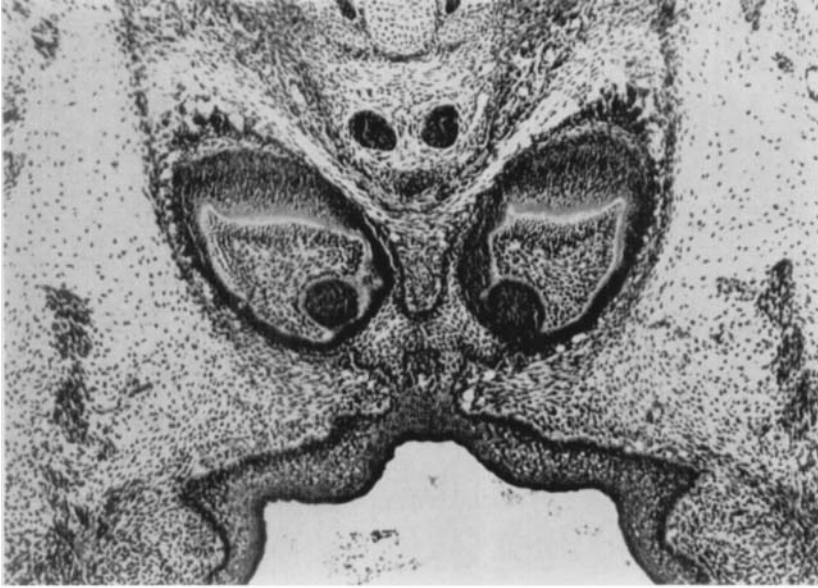


## Plate 7.

Figs. 11-15 (continued)

*Fig. 13.* Broad connection between the stellate reticula of the two sides. The recess is reduced.

*Fig. 14.* The stellate reticulum and the outer dental epithelium form a Y-shaped connection between the two germs and the oral epithelium.



## Plate 8.

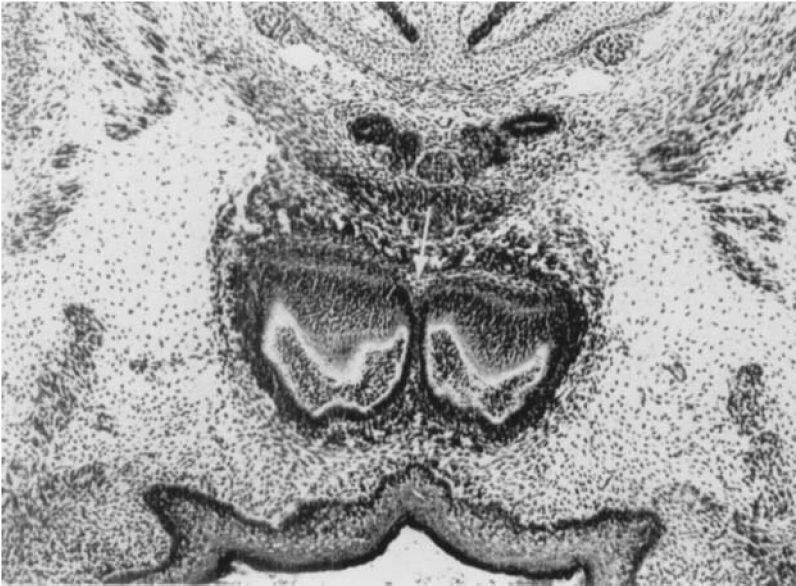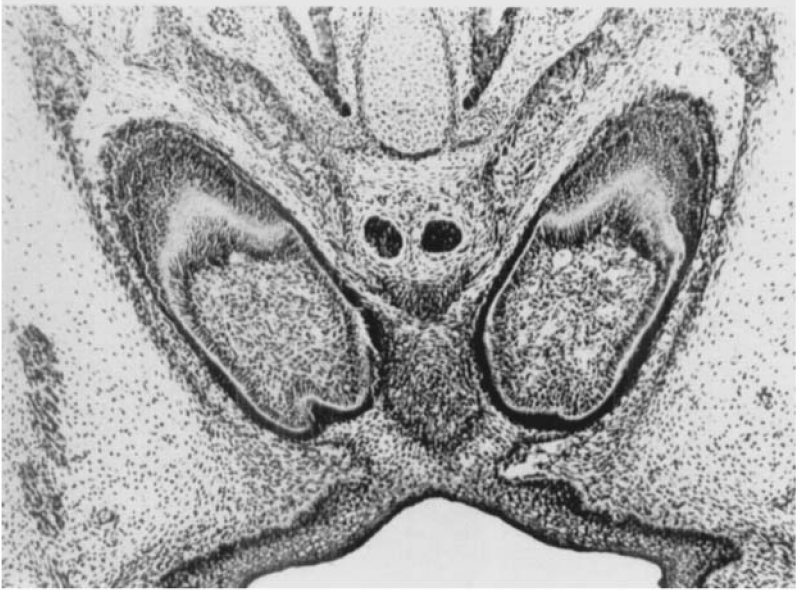Figs. 11-15 (continued)

*Fig. 15.* The stellate reticulum and the outer dental epithelium form a V-shaped connection between the two germs and the oral epithelium.

Figs. 16-22. Exencephalic mouse embryo (166 d 1/3). Frontal sections. ( $\times 63$ ).

### FUSIO PARTIALIS

*Fig. 16.* The stellate reticulum and the outer dental epithelium cross the midline (seen nasally) (arrow). The two ameloblast layers are in 'contact'.

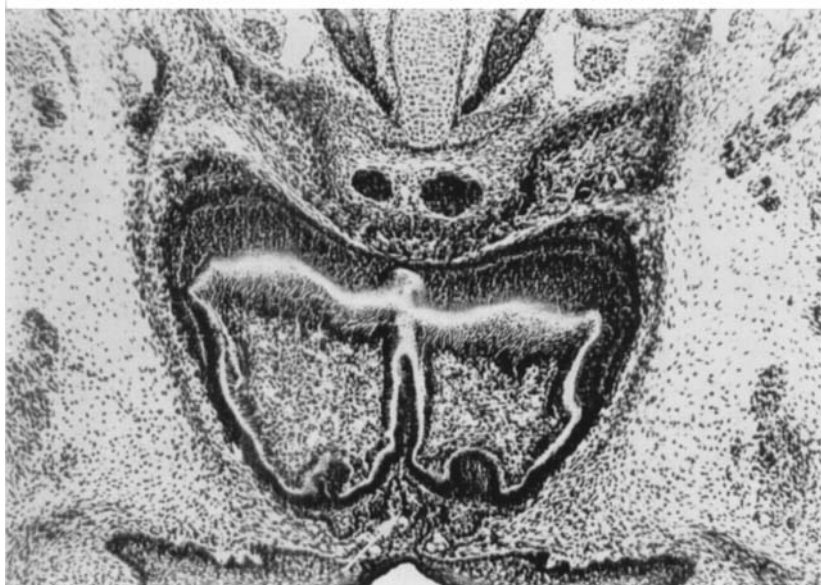
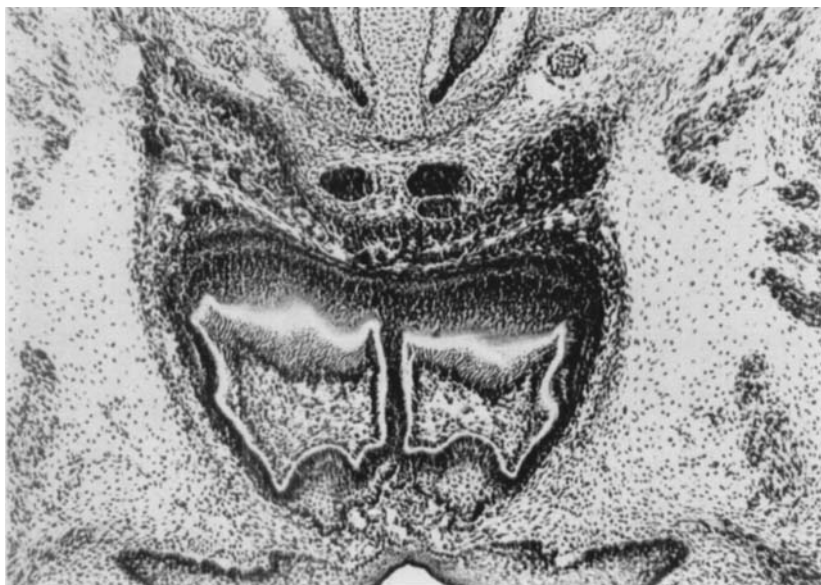

**Plate 9.**

Figs. 16-22 (continued)

*Fig. 17.* Connection between the ameloblasts in the nasal part of the germ.

*Fig. 18.* The dentine layer crosses the mid-line. Recess (arrow).

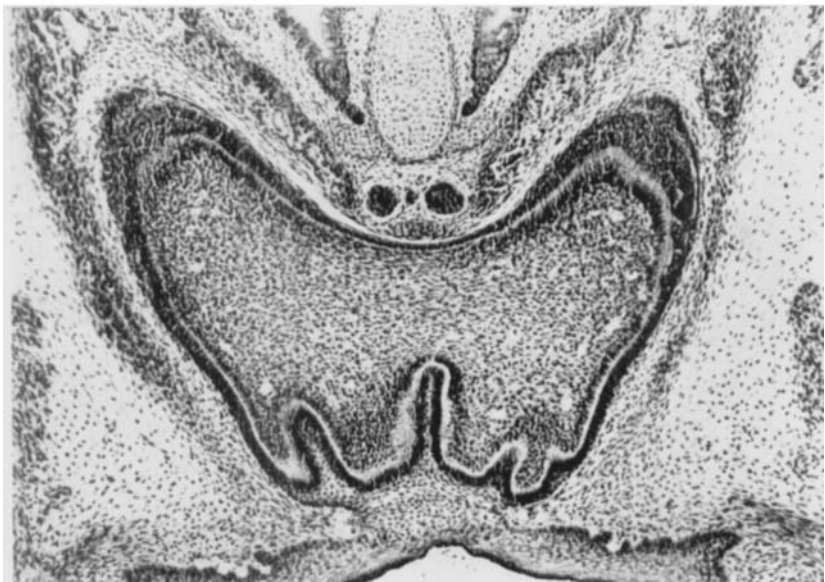
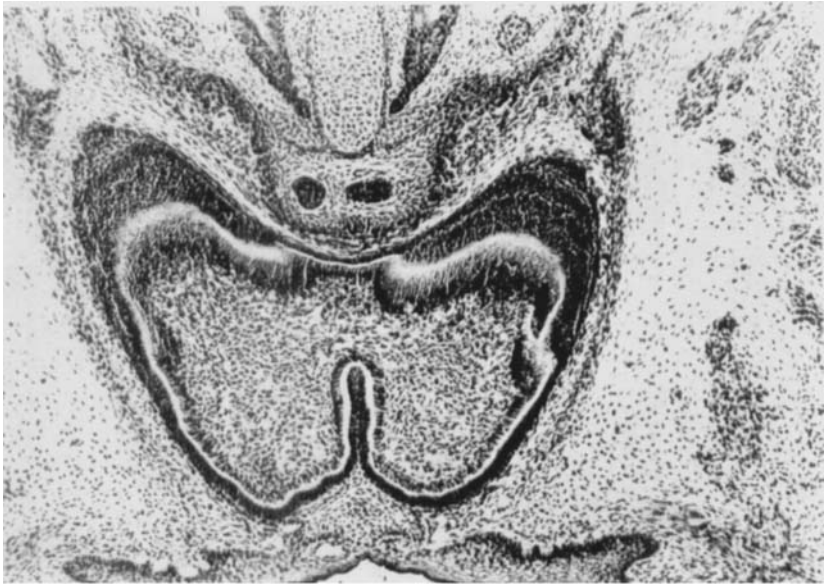


## **Plate 10.**

Figs. 16-22 (continued)

*Fig. 19.* The pulp with odontoblasts crosses the mid-line.

*Fig. 20.* A broad 'pulp bridge' and uneven dentine border orally.

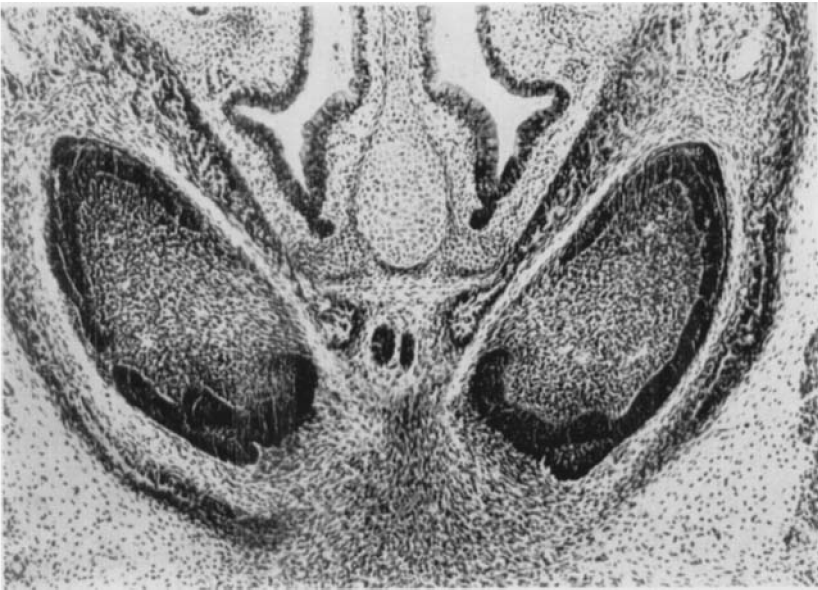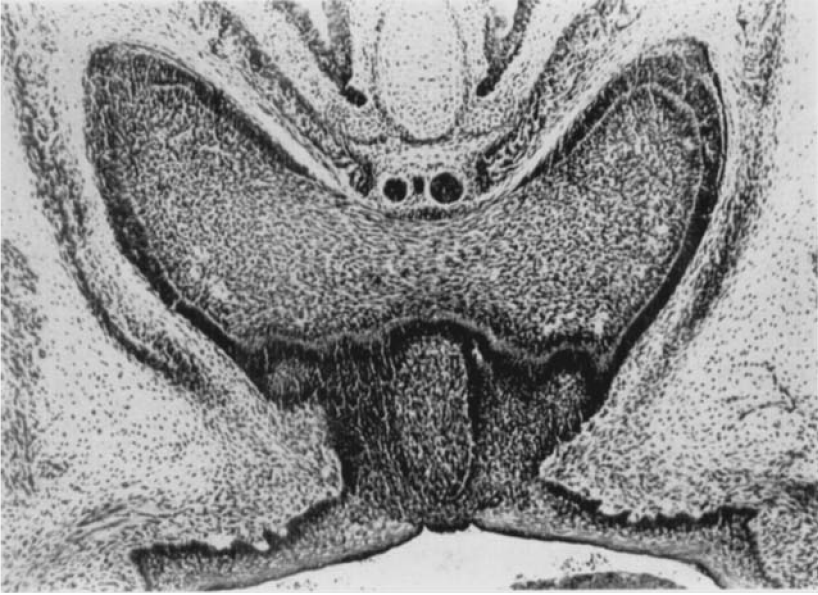


## Plate 11.

Figs. 16-22 (continued)

*Fig. 21.* The ameloblast layer is lacking in the middle portion of the germ on the nasal side. Connective tissue recess orally.

*Fig. 22.* The two parts of the germ are separated.



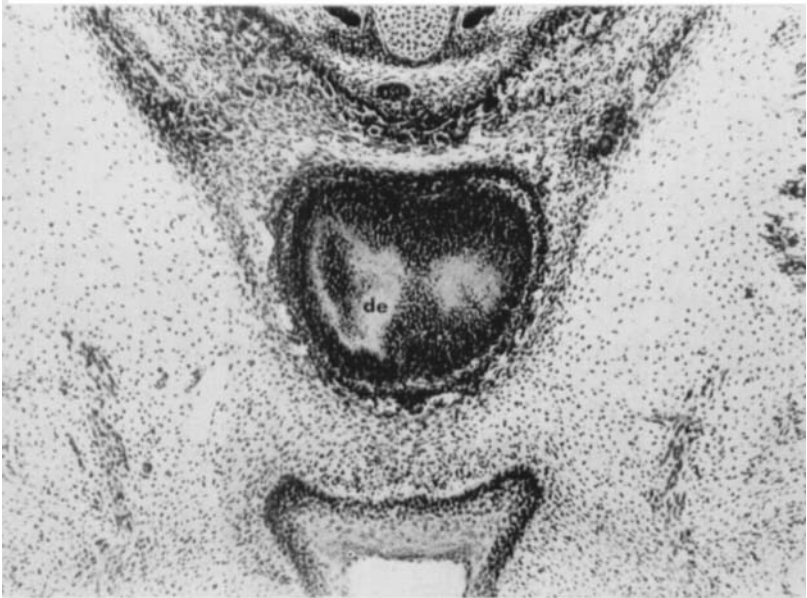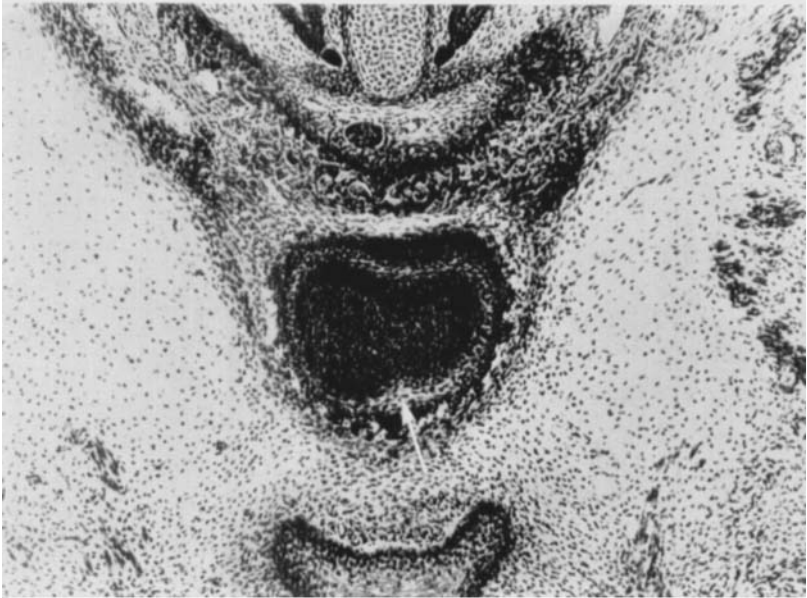## Plate 12.

Figs. 23-29. Exencephalic mouse embryo (189 d I/2). Frontal sections. ( $\times 63$ ).

FUSIO TOTALIS.

*Fig. 23.* Tangential section through the anterior portion of the germ. The stellate reticulum is seen right around the germ (arrow).

*Fig. 24.* Tangential section of the dentine layer (de).

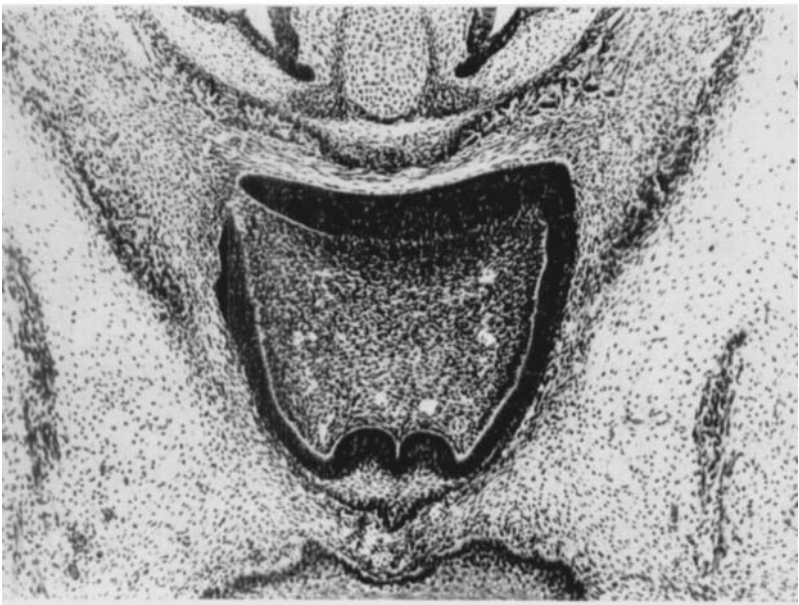
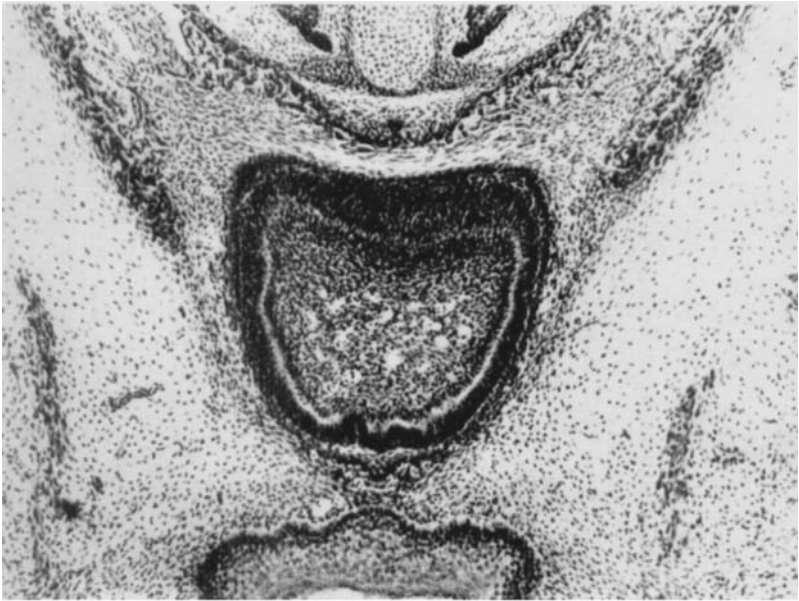


## **Plate 13.**

Figs. 23-29 (continued)

*Fig. 25.* All the layers of the germ are visible. The enamel organ has no connection with the oral epithelium.

*Fig. 26.* Incipient apical opening.

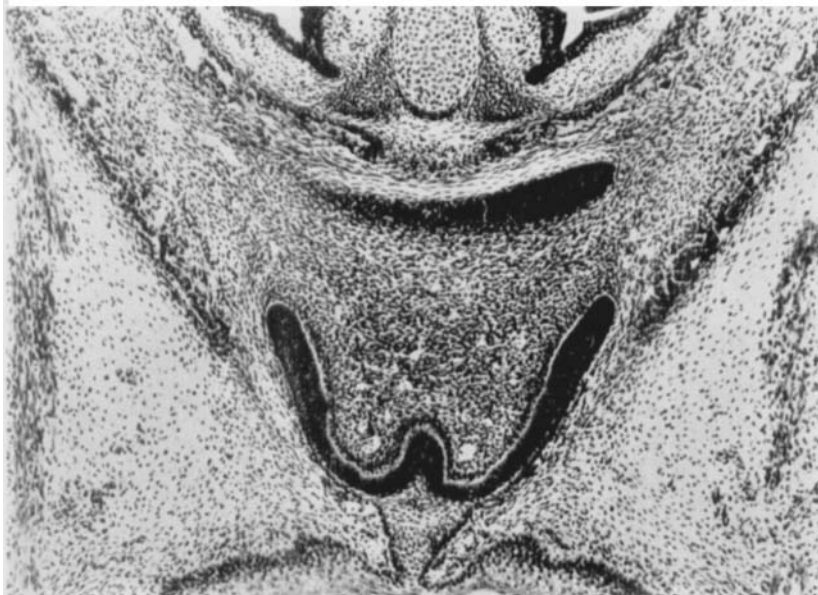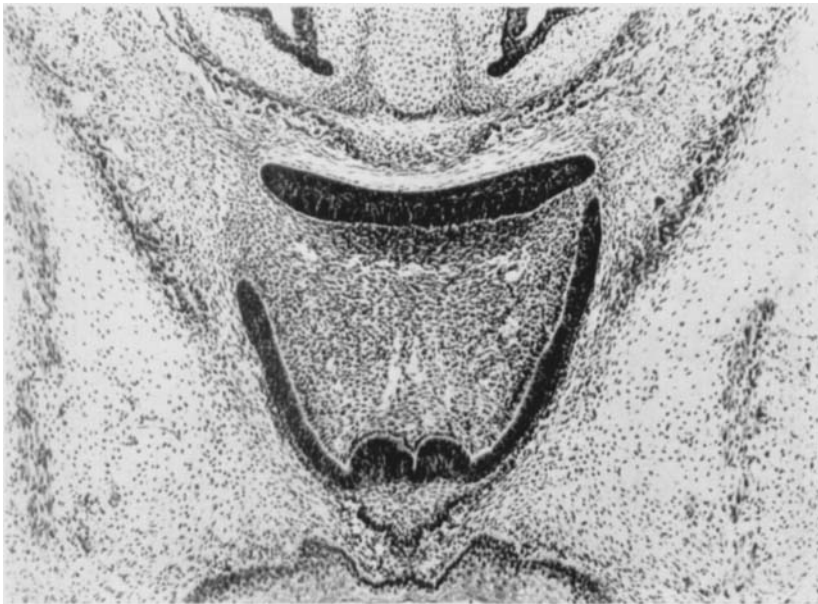


**Plate 14.**

Figs. 23-29 (continued)

*Fig. 27.* Apical opening visible on both sides.

*Fig. 28.* Large apical opening. The enamel organ has a broad connection with the oral epithelium.

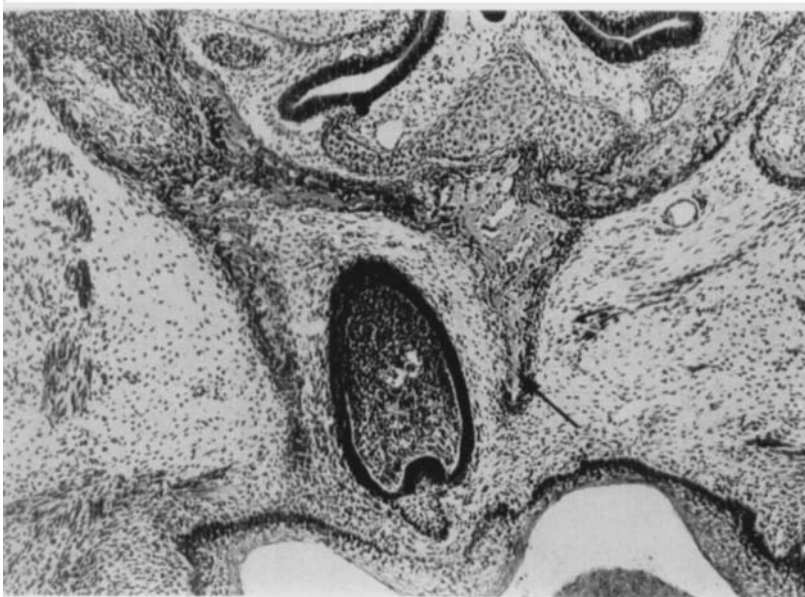
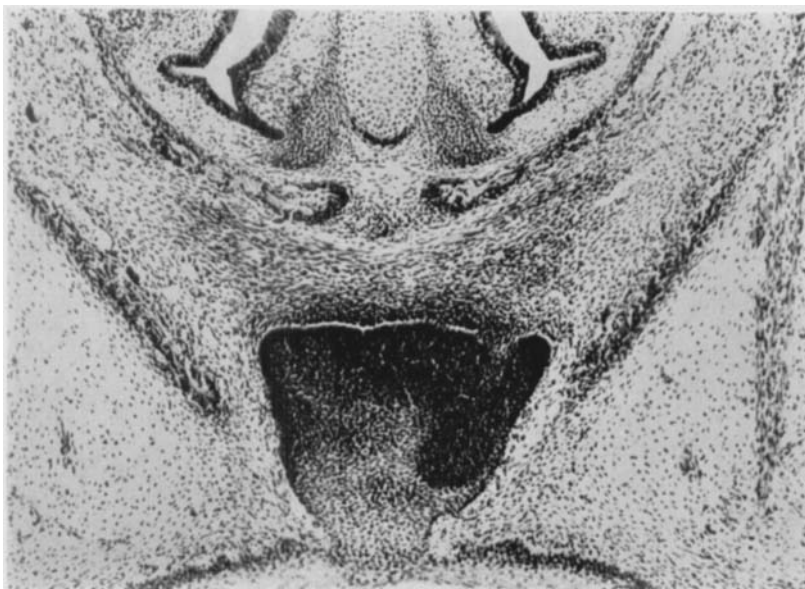
**Plate 15.**

Figs. 23-29 (continued)

*Fig. 29.* Tangential section through the posterior part of the incisor germ.

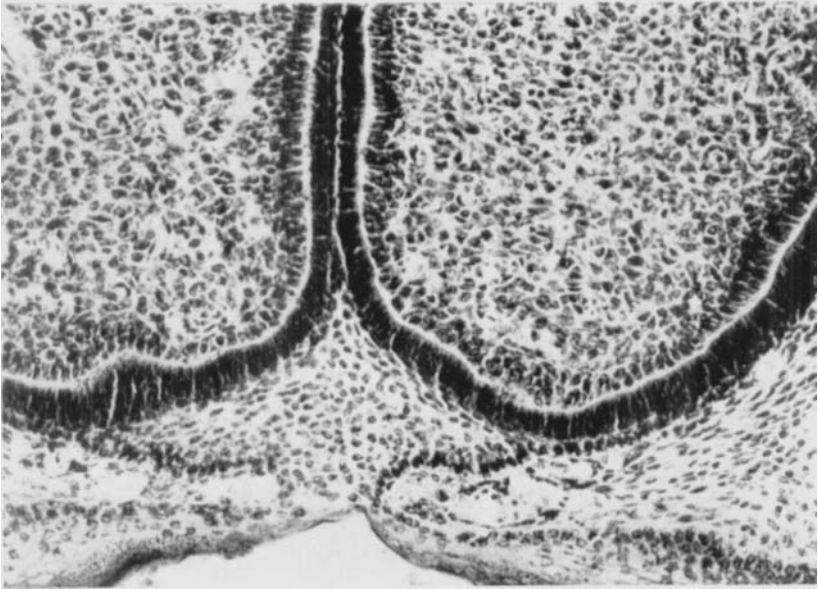
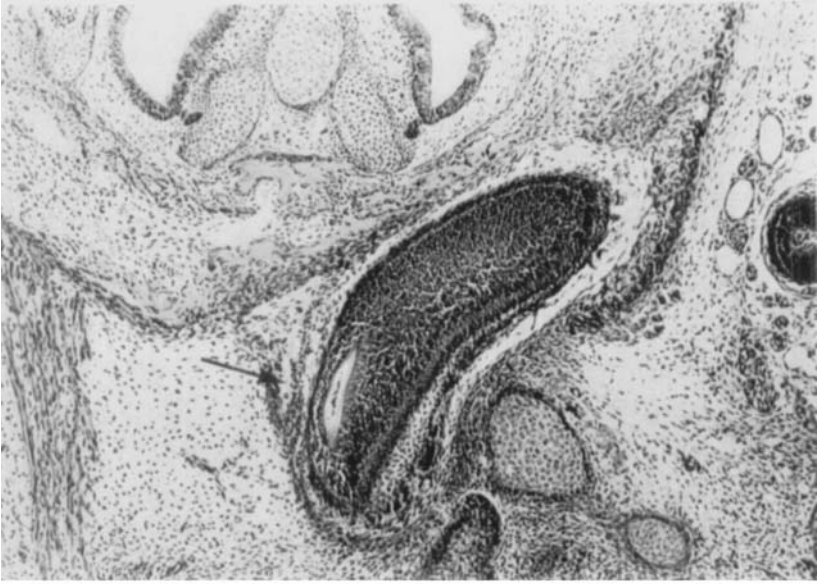*Fig. 30.* Exencephalic mouse embryo (93 d I/2). Frontal section. ( $\times 63$ ). Unilateral agenesis. Mesial bone lamina (arrow).



**Plate 16.**

*Fig. 31.* Exencephalic mouse embryo (143 d 1/3). Frontal section. Unilateral agenesis. Mesial bone lamina (arrow). ( $\times 63$ ).

*Fig. 32.* Exencephalic mouse embryo (180 d 1/2). Frontal section. Part of the contact area between the incisor germs, shown in Fig. 9. ( $\times 160$ ).





- Movat, H. Z.*, 1955: Demonstration of all connective tissue elements in a single section. *Arch. Path.* *60*: 289—295.
- Pourtois, M.*, 1961: Contribution à l'étude des Bourgeons dentaires chez la Souris. I. Périodes d'Induction et de Morphodifférenciation. *Arch. Biol. (Belge)*, *72*: 17—95.
- Via, W. F. & J. A. Churchill*, 1957: Relationship of cerebral disorders to faults in dental enamel. *Amer. J. Dis. Child.* *94*: 137—142.

Address: *Aarhus Tandlægehøjskole*  
*Vennelyst Boulevard,*  
*Aarhus C, Denmark*