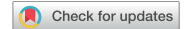


RESEARCH ARTICLE



## Features of Dental Anomaly Patterns in Finnish children as seen in panoramic radiographs at the late mixed stage

Jenni Ristaniemi<sup>a</sup>, Kati Kujasalo<sup>a</sup>, Eelis Rytkönen<sup>a</sup>, Eeva Melaluoto<sup>a</sup>, Jenni Iivari<sup>a</sup>, Paula Pesonen<sup>b</sup> and Raija Lähdesmäki<sup>a,c</sup> 

<sup>a</sup>Oral Development and Orthodontics, Research Unit of Population Health, Faculty of Medicine, University of Oulu, Oulu, Finland;

<sup>b</sup>Infrastructure for Population Studies, Faculty of Medicine, University of Oulu, Oulu, Finland; <sup>c</sup>Oral and Maxillofacial Department, Medical Research Center Oulu (MRC Oulu), Oulu University Hospital, Oulu, Finland

### ABSTRACT

**Objective:** To describe the prevalence of the developmental abnormalities involved in Dental Anomaly Patterns (DAP) and investigate their co-occurrence in an age cohort of children with late mixed dentition.

**Material and Methods:** Retrospective, register-based study focused on 1315 panoramic radiographs of children aged 8.5–10.5 years. The features examined were absent teeth, peg-shaped maxillary lateral incisor, delayed dental age, infraocclusion of primary molars, transposition and distal angulation of unerupted mandibular second premolar.

**Results:** Feature involved in DAP was detected in 29.8% of the children, most common being infraocclusion of primary molars (17.5%), followed by absent teeth (8.4%), delayed dental age (7.6%), distal angulation of unerupted mandibular second premolar (7.3%), peg-shaped maxillary lateral incisor (2.4%) and transposition (0.5%). Two DAP features occurred together in 4.7% of children, while three occurred in 0.7%. Infraocclusion ( $p=.040$ ) and absent teeth ( $p=.001$ ) occurred more commonly in girls. Phenotypic variations in maxillary lateral incisor more often occurred together ( $p=.004$ ). Absent teeth, peg-shaped maxillary lateral incisor and delayed dental age more often occurred together ( $p<.01$ ) as did transposition and absent teeth ( $p=.016$ ).

**Conclusion:** Almost third of the children had dental developmental abnormalities involved in DAP. Absent teeth, peg-shaped lateral incisors and delayed dental age more often occurred together.

### ARTICLE HISTORY

Received 10 March 2023

Revised 30 May 2023

Accepted 27 June 2023

### KEYWORDS

Developing dentition; human; panoramic radiograph; permanent tooth

## Introduction

The development of the human dentition is a multistage, complex process allowing for numerous abnormalities, and many developmental abnormalities in the dentition have been reported to occur together more often than can be explained by chance alone [1,2]. It has been suggested earlier that certain dental developmental abnormalities run in families [3,4], and that these may express a pleiotropic effect [5]. It was Peck who first described the concept of Dental Anomaly Patterns (DAP) [2,6–13], and our focus here is on reporting the dental developmental abnormalities recorded among DAP.

The absence of a permanent tooth is a common congenital condition in the human dentition, and it usually involves 1–2 permanent teeth, most often mandibular second premolar [14–16]. Absent or peg-shaped maxillary lateral incisor have been shown to occur more often together in families, due to the same genetic background [3,4], and closely related to palatally displaced maxillary canines [7,17,18]. Children with absent teeth more often have delayed dental development [19–21] and infraocclusion of the primary molars

[1,12,22], as well as peg-shaped lateral incisors and distal angulation of unerupted mandibular second premolars [12].

Infraocclusion of the primary molars has been shown to be related to other dental abnormalities such as peg-shaped maxillary lateral incisor, displaced maxillary canines [5,13], absent teeth, distal angulation of unerupted mandibular second premolar [13] and delayed dental age [5]. Transposition is a rare condition in which two developing permanent teeth, most commonly canines, change position in the dental arch [23]. The transposition of a canine and a first premolar in the maxilla or a canine and lateral incisor in the mandible has been shown to occur more often in combination with absent teeth and peg-shaped maxillary lateral incisor [6,8,24]. An unerupted mandibular second premolar has been shown to be more distally tilted if there was agenesis of its antimere [10,20]. Distal angulation of mandibular second premolar has been related to a palatally displaced maxillary canine [25,26].

A panoramic radiograph is a basic examination for diagnosing features of the late mixed dentition that are involved in DAP (Table 1). One purpose of this study was to describe the prevalence of developmental abnormalities involved in

**Table 1.** Features related to Dental Anomaly Patterns (DAP) by Peck [2].

Clinical feature
Absent teeth
Microform teeth (e.g. peg-shaped lateral incisor)
Tooth-size reduction (generalized or localized)
Delay in tooth formation and eruption (generalized or localized)
Infraocclusion (most often of primary teeth)
Palatal displacement of a canine
Maxillary canine and first premolar transposition (Mx.C.P1)
Mandibular lateral incisor and canine transposition (Mn.I2.C)
Distal angulation of an unerupted mandibular second premolar

DAP in Finnish children and to note gender differences among the features studied, and second purpose was to investigate co-occurrences of DAP features in these children. Our hypothesis was that features of DAP are found together more often than can be explained by chance alone when seen in a late mixed dentition panoramic radiograph.

## Materials and methods

### Study material

This cross-sectional, register-based research is based on 1454 panoramic radiographs (PTGs) of the developing permanent dentition obtained from an age cohort of third-year primary school children of Finnish ancestry in a municipality in Eastern Finland born between 1980 and 1996. The PTGs had been taken by the Health Centre's radiological department in response to referrals during annual oral check-ups to examine the development of the permanent dentition. The research was conducted retrospectively from data gathered from clinical dental records. The PTGs were copied digitally by RL and TK. Background information on the subjects was collected, including name, gender, date of birth and the date of the PTG. According to Finnish legislation, permission for collecting information was given by the keeper of that register. The personal information was coded for the analyses to prevent identification.

### Variables

The variables used here follow DAP features introduced by Peck [2] (Table 1).

#### Absent teeth

Absent teeth were visually assessed from PTGs by ER and in cases of rare absences (maxillary canine, mandibular incisor and second molar) confirmed by JR. A permanent tooth was congenitally absent if the subject of its follicle was not visible in the PTG. Third molar absences were excluded.

#### Microform teeth (peg-shaped maxillary lateral incisors)

Peg-shaped maxillary lateral incisors (peg-shaped MxI2) were assessed from the PTGs by JR, and in undecided cases a consensus opinion was sought by JR and RL. Peg-shaped lateral incisors were detected visually, as the mesiodistal width of the crown is smaller than mesiodistal width of the cervical part of the tooth [27], the anatomical shape of the crown is

pointed in form and the root may be small [28]. The exclusion criteria were unreadable area of the lateral incisor due to rotated tooth or artifact in the PTG. Calibration was performed by JR in the PTG material and discussing selected borderline cases ( $n=14$ ) with RL.

#### Delay in tooth formation and eruption (generalized)

Delays in tooth formation and eruption were ascribed to delayed dental age. Dental age was analyzed from the PTGs by EM and JI using the seven teeth dental maturity method of Demirjian [29, 30] and assessed by reference to Finnish maturity curves [31]. The exclusion criteria for this variable were a missing tooth (no counterpart) or poor quality of the PTG. To test the accuracy of the assessments, the two examiners assessed the same set of 30 PTGs two times. Dental age was grouped as normal (early/normal;  $DA > -1$  year) and delayed ( $DA \leq -1$  year) relative to the chronological age.

#### Infraocclusion (of primary molars)

Infraocclusion of primary molars (infraocclusion) was assessed from the PTGs by JR and calibrated with RL. The primary molars were viewed visually by comparing them to the occlusal plane and the marginal ridges of the adjacent teeth, and the PTGs were categorized as showing no visible infraocclusion or visible infraocclusion in at least one primary molar in the maxilla or mandible. The exclusion criteria for this variable were an absent primary molar and no infraocclusion in the others, failure to determine the occlusal plane reliably, significant loss of crown morphology in the primary molars, an orthodontic appliance around the primary molar, or poor quality of the PTG. Repeatability was estimated by measuring 146 PTGs twice.

#### Transposition

Transpositions of permanent teeth were visually assessed from the PTGs by KK and confirmed by JR. Canine and first premolar transpositions in the maxilla (Mx.C.P1) and canine and lateral incisor transpositions in the mandible (Mn.I2.C) were included. Two adjacent teeth were classified as transpositioned if their crowns had crossed each other in the PTG and were erupting towards the wrong position despite the presence of adequate space in the dental arch.

#### Distal angulation of unerupted mandibular second premolars

Distal angulation of unerupted mandibular second premolars (distal angulation of MnP2) was digitally determined from the PTGs by KK and later JR. The mandibular second premolar was classified by KK as distally displaced if the long axis of the developing premolar intersected with the mesial border of the neighboring mandibular first molar (modified from Baccetti et al. [26]). The exclusion criteria confirmed by JR were an emerged mandibular second premolar, mandibular second premolar root development that had not yet started, or absence of the mandibular first molar.

### The inclusion criteria

- chronological age 8.5–10.5 years at the time of the PTG
- dentition in the mixed stage
- no syndromes or clefts

### Statistics

The prevalence of features involved in DAP was described in terms of frequencies and percentages. Comparisons between the genders were performed using Pearson's Chi-square test or Fisher's exact test, and those between all the studied DAP features with Pearson's Chi-square test or Fisher's exact test, as also between DAP features and absent teeth in the subgroups. The normality of the chronological and dental ages was assessed visually using histograms. Mean chronological and dental ages were analyzed with the independent samples t-test. The statistical analyses were performed by JR and PP using IBM SPSS Statistics (version 28.0). P-values < .05 were considered statistically significant. The repeatability of the assessments of dental age and infraocclusion was assessed using Cohen's kappa or intra-class correlation (ICC).

### Results

#### Reliability

Inter-rater reliability for dental age showed almost perfect agreement (ICC =.871), while intra-rater reliability showed substantial agreement (ICC =.789) and almost perfect agreement (ICC = .945). The intra-rater reliability showed almost perfect agreement for infraocclusion ( $\kappa = .837$ ).

#### Descriptive statistics

The material consisted of 1315 panoramic radiographs for 619 girls and 696 boys aged 8.5–10.5 years, the mean age of the children concerned at the time of the PTG being 9.4 years (SD 0.4), a figure which did not differ between the genders ( $p = .052$ ).

#### Prevalence of DAP features

The prevalence of the DAP features studied here are presented in Table 2. At least one feature involved in DAP was detected in 29.8% ( $n=392$ ) of the children. Absences of permanent teeth varied from 1 to 8, occurring in 8.4% of children and more often in girls ( $p = .001$ ). The most common absent tooth was mandibular second premolar (Table 3), occurring more often unilaterally (2.9% vs. 2.4%,  $p < .001$ ). Absence of maxillary second premolar occurred more often bilaterally (1.4% vs. 1.0%,  $p < .001$ ). At least one premolar was absent in 6.5% of the children, this being more frequently the case in girls (7.9%,  $p = .043$ ). Maxillary lateral incisor was absent in 1.1%, including nine girls and five boys ( $p = .195$ ). Absence of maxillary lateral incisor occurred more often unilaterally (0.8% vs. 0.2%,  $p < .001$ ).

Table 2. Prevalence of DAP features in the cohort.

	Total material		Girls		Boys		P value <sup>a</sup>
	n	(%)	n	(%)	n	(%)	
<b>Infraocclusion</b>							
Yes	154	(17.5)	80	(20.4)	74	(15.1)	.040 <sup>b</sup>
No	727	(82.5)	312	(79.6)	415	(84.9)	
<b>Absent teeth</b>							
Yes	110	(8.4)	68	(11.0)	42	(6.0)	.001 <sup>b</sup>
No	1205	(91.6)	551	(89.0)	654	(94.0)	
<b>Delayed dental age</b>							
Yes	89	(7.6)	44	(8.0)	45	(7.2)	.565 <sup>b</sup>
No	1087	(89.4)	503	(92.0)	584	(92.8)	
<b>Distal angulation of MnP2</b>							
Yes	81	(7.3)	43	(8.4)	38	(6.3)	.161 <sup>b</sup>
No	1035	(92.7)	466	(91.6)	569	(93.7)	
<b>Peg-shaped MxI2</b>							
Yes	31	(2.4)	12	(1.9)	19	(2.7)	.337 <sup>b</sup>
No	1280	(97.6)	607	(98.1)	673	(97.3)	
<b>Transposition</b>							
Yes	7	(0.5)	3	(0.5)	4	(0.6)	>.999 <sup>c</sup>
No	1308	(99.5)	616	(99.5)	692	(99.4)	

<sup>a</sup>Significances are of gender differences.

<sup>b</sup>Pearson's Chi-square test.

<sup>c</sup>Fisher's exact test.

Table 3. Prevalence of congenitally absent teeth in the cohort.

Children ( $n=1315$ )	n	%
<b>Premolar</b>		
Mandibular second premolar	85	6.5
Maxillary second premolar	70	5.3
Maxillary first premolar	31	2.4
Mandibular first premolar	7	0.5
Mandibular first premolar	5	0.4
<b>Maxillary lateral incisor</b>	14	1.1
<b>Mandibular second molar</b>	10	0.8
<b>Mandibular incisor</b>	5	0.4
<b>Mandibular canine</b>	2	0.2
<b>Maxillary canine</b>	1	0.1

Dental age could be assessed for 1176 children, varying between 6.5 and 13.2 years. Mean dental age was 9.6 years (SD 0.8) for girls and 9.8 years (SD 1.0) for boys ( $p < .001$ ). Grouped dental age was assessed as delayed in 7.6% of children (Table 2).

One or two peg-shaped MxI2 was detected in 2.4% of the children, occurring more often unilaterally (1.7% vs. 0.7%,  $p < .001$ ). Infraocclusion was detected in 17.5%, being more frequent in girls ( $p = .040$ ) (Table 2). Transpositions (Mx.C.P1  $n=5$ , Mn.I2.C  $n=2$ ) were detected in seven children. Distal angulation of MnP2 was detected in 7.3% of children. Both of mandibular second premolars were distally tilted in 14.1% of the children ( $p < .001$ ).

#### Co-occurrence of DAP features

One feature involved in DAP studied here occurred in 24.4% of the children, while two occurred in 4.7% and three in 0.7%. Three children (0.2%) had both maxillary lateral incisor phenotypic variations, occurring more often together ( $p = .004$ ) (Table 4). If a mandibular second premolar was absent, the antimere was not distally angulated any more often (right absent vs. left distally angulated  $p = .397$  and left absent vs. right distally angulated  $p = .470$ ). A peg-shaped MxI2 was found together more often with delayed dental

**Table 4.** Distributions of absent teeth in subgroups among features involved in DAP.

	Delayed dental age				P value <sup>a</sup>	Peg-shaped MxI2				P value <sup>a</sup>	Transposition				P value <sup>a</sup>
	Yes		No			Yes		No			Yes		No		
	n	(%)	n	(%)		n	(%)	n	(%)		n	(%)	n	(%)	
<b>Absent mandibular second premolar</b>															
Yes	4	(4.5)	15	(1.4)	.049	7	(22.6)	63	(4.9)	<.001	2	(28.6)	68	(5.2)	.049
No	85	(95.5)	1072	(98.6)		24	(77.4)	1217	(95.1)		5	(71.4)	1240	(94.8)	
<b>Absent maxillary second premolar</b>															
Yes	5	(5.6)	13	(1.2)	.009	4	(12.9)	27	(2.1)	.005					
No	84	(94.4)	1074	(98.8)		27	(87.1)	1253	(97.9)						
<b>Absent first premolar</b>															
Yes						2	(6.5)	7	(0.5)	.018					
No						29	(93.5)	1273	(99.5)						
<b>Absent maxillary lateral incisor</b>															
Yes						3	(9.7)	11	(0.9)	.004					
No						28	(90.3)	1269	(99.1)						
<b>Absent mandibular incisor</b>															
Yes						2	(6.5)	3	(0.2)	.005					
No						29	(93.5)	1277	(99.8)						

<sup>a</sup>Fisher's exact test.

**Table 5.** Distributions of certain features involved in DAP.

	Delayed dental age				P value <sup>a</sup>	Peg-shaped MxI2				P value <sup>a</sup>	Transposition				P value <sup>a</sup>
	Yes		No			Yes		No			Yes		No		
	n	(%)	n	(%)		n	(%)	n	(%)		n	(%)	n	(%)	
<b>Absent teeth</b>															
Yes	9	(10.1)	39	(3.6)	.008	11	(35.5)	99	(7.7)	<.001	3	(42.9)	107	(8.2)	.016
No	80	(89.9)	1048	(96.4)		20	(64.5)	1181	(92.3)		4	(57.1)	1201	(91.8)	
<b>Peg-shaped MxI2</b>															
Yes	6	(6.8)	18	(1.7)	.007										
No	82	(93.2)	1066	(98.3)											

<sup>a</sup>Fisher's exact test.

age ( $p = .007$ ) and absent teeth ( $p < .001$ ) (Table 5). Delayed dental age and absence of teeth occurred together more often ( $p = .008$ ) (Table 5), especially in the case of the absence of maxillary second premolar ( $p = .009$ ) and mandibular second premolar ( $p = .049$ ) (Table 4). Transposition was found together more often with absent teeth ( $p = .016$ ) (Table 5), especially with the absence of mandibular second premolar ( $p = .049$ ) (Table 4).

## Discussion

In this descriptive study of an age cohort of Finnish children we report the prevalence of various features involved in DAP seen in PTG at the late mixed dentition stage. Almost a third of the children had dental developmental abnormalities involved in DAP to be seen in PTG at this stage, and absence of teeth, peg-shaped maxillary lateral incisor and delayed dental age were more often found together. Phenotype variations in the maxillary lateral incisor more often occurred together. Also, transposition co-occurred with the absence of teeth, especially the absence of mandibular second premolar. We can accept the hypothesis that some DAP features occurred together more often than they would in a normal population.

The most common feature involved in DAP in children aged 8.5-10.5 years with mixed dentition was infraocclusion in the primary molars, which was seen in 17.5% of the children. Kurol [32] has reported the prevalence of infraocclusion to be at its maximum, about 14%, at the age of eight to nine. Infraocclusion occurred more often in

girls, in contrast to earlier findings [32,33]. Children with primary molar infraocclusion did not have other features involved in DAP any more often, thus differing from earlier findings related genetically to other dental abnormalities [1,2,5,13].

Distal angulation of an unerupted mandibular second premolar was detected in 7.3% of these children, which is in line with the earlier report of Baccetti and co-workers [26] (8.2%). In present study, distal angulation occurred more often unilaterally. Also, where enlarged distal angulation of a mandibular second premolar had been found in an earlier study [10] in the absence of its antimere, such distal angulation of a mandibular second premolar was not found together with absence of the antimere in the present material, nor with any other DAP features studied here.

Transpositions (Mx.C.P1 or Mn.C.I2) occurred in seven children, less than half a percent and in line with an earlier report [34]. Transposition occurred equally in the genders, which differed from earlier findings [6,8,24]. Transposition in the maxilla was more common, and transpositions occurred more often with absent teeth, both of which observations are in line with earlier findings [6,8,35].

Congenitally absent permanent teeth occurred in 8.4% of children, being compatible with earlier studies from Finland [36], Denmark [37] and a general European population [15], whereas the results are slightly higher than those reported for other European populations [14,34]. Bilateral occurrence of absent maxillary second premolar was more common, which differed from earlier findings [14]. Absent teeth occurred more often in girls and most affected mandibular

second premolar, both observations being in line with earlier findings [14–16,36]. It is interesting that a mandibular second molar was absent in 0.8%, placing it fourth among the absent teeth. The prevalence was lower (0.1%) in earlier study of Finnish children [36].

Maxillary lateral incisor was absent in one percent, which is lower than has been reported earlier [14], and occurred more often unilaterally, differed from earlier findings [14]. Approximately two-thirds of the absent maxillary lateral incisor cases occurred in girls, which is in line with a recent report from Finland [16] but does not represent a statistically significant difference between the genders. At least another maxillary lateral incisor was detected as peg-shaped in just over 2% of the children, being in line with the review by Hua et al. [38]. Peg-shaped maxillary lateral incisor was detected more often unilaterally and without any gender difference, in contrast to an earlier report [38]. In the present study absent and peg-shaped lateral incisor more often occurred together, as suggested earlier [3,4], although both variations of the phenotype were seen only in three children. A congenitally absent or peg-shaped maxillary lateral incisor is one of the first visible features involved in DAP to be seen in a developing dentition and is an important indication for a follow-up regarding other developmental abnormalities.

Although chronological age was congruent between the genders, the dental age of the boys was earlier at this age cohort, in contrast to previous findings that girls are ahead [31]. Delayed dental age was found together with peg-shaped maxillary lateral incisor and absent teeth, the absence of a second premolar occurring more often in children with delayed dental age, thus confirming the finding of Navarro and co-workers [20]. A relation has been reported earlier between absent teeth and peg-shaped maxillary lateral incisor [1,12,39], as also between absent teeth and delayed dental age [19,20]. The present findings underpin the notion that a delay in dental age, a peg-shaped maxillary lateral incisor and absent teeth are found together more often, and thus form part of the DAP set of features [2].

One limitation of this research is its retrospective design, and another is its cross-sectional character regarding the PTGs. Due to variations in dental development some features of DAP (e.g. infraocclusion or distal angulation of unerupted mandibular second premolar) may have become visible before or after the PTGs had been taken, which must be considered when reflecting on the results. In rare cases a permanent second premolar might develop very much later. Also, the number of children with rare abnormalities (e.g. transposition) was markedly small. In this study, the effect of socioeconomic level and BMI on dental age were considered minimal and not controlled.

In this present description of the prevalence of dental developmental abnormalities in an age cohort of Finnish children with mixed dentition certain features occurred more often together, but mostly only one actual feature involved in DAP per child. If any dental developmental abnormality is diagnosed during the earlier stages of development, a precise follow-up is needed to allow for conditions occurring

later and for early treatment options. The occurrence of dental developmental abnormalities together in families would offer one means of pointing to similarities in genetic background. Thus, the presence of a pleiotropic effect needs more research.

## Conclusion

- At least one dental developmental abnormality involved in DAP was detected in 29.8% of the children.
- One feature involved in DAP occurred in 24.4% of the children, while two occurred in 4.7% and three only in 0.7%.
- The most common features involved in DAP were infraocclusion of primary molars (17.5%) and absent teeth (8.4%), both of which occurred significantly more often in girls.
- Absent teeth, a peg-shaped maxillary lateral incisor and delayed dental age occurred more often together, and co-occurrence of transposition with absent teeth was also found.

## Acknowledgements

We wish to express our gratitude to the oral health care personnel at the Health Centre in the municipality of Lapinlahti for making this study possible. We would also like to thank Terhi Karjalainen (TK) for her work with data collection.

## Disclosure statement

The authors report that there are no competing interests to declare.

## Funding

This study was supported by grants from the Finnish Dental Society Apollonia, the Päivikki and Sakari Sohlberg Foundation, and the University of Oulu Scholarship Foundation.

## ORCID

Raija Lähdesmäki  <http://orcid.org/0000-0003-2375-5222>

## References

- [1] Baccetti T. A controlled study of associated dental anomalies. *Angle Orthod.* 1998;68(3):267–274.
- [2] Peck S. Dental anomaly patterns (DAP). a new way to look at malocclusion. *Angle Orthod.* 2009;79(5):1015–1016. doi: 10.2319/0003-3219-079.005.1015.
- [3] Alvesalo L, Portin P. The inheritance pattern of missing, peg-shaped, and strongly mesio-distally reduced upper lateral incisors. *Acta Odontol Scand.* 1969;27(6):563–575. doi: 10.3109/00016356909026309.
- [4] Arte S, Nieminen P, Apajalahti S, et al. Characteristics of incisor-premolar hypodontia in families. *J Dent Res.* 2001;80(5):1445–1450. doi: 10.1177/00220345010800051201.
- [5] Odeh R, Townsend G, Mihailidis S, et al. Infraocclusion: dental development and associated dental variations in singletons and

- twins. *Arch Oral Biol.* 2015;60(9):1394–1402. doi: [10.1016/j.archoral-bio.2015.06.010](https://doi.org/10.1016/j.archoral-bio.2015.06.010).
- [6] Peck L, Peck S, Attia Y. Maxillary canine-first premolar transposition, associated dental anomalies and genetic basis. *Angle Orthod.* 1993;63(2):99–110.
- [7] Peck S, Peck L, Kataja M. The palatally displaced canine as a dental anomaly of genetic origin. *Angle Orthod.* 1994;64(4):249–256.
- [8] Peck S, Peck L, Kataja M. Mandibular lateral incisor-canine transposition, concomitant dental anomalies, and genetic control. *Angle Orthod.* 1998;68(5):455–466.
- [9] Langberg BJ, Peck S. Tooth-size reduction associated with occurrence of palatal displacement of canines. *Angle Orthod.* 2000;70(2):126–128.
- [10] Shalish M, Peck S, Wasserstein A, et al. Malposition of unerupted mandibular second premolar associated with agenesis of its antimere. *Am J Orthod Dentofacial Orthop.* 2002;121(1):53–56. doi: [10.1067/mod.2002.120399](https://doi.org/10.1067/mod.2002.120399).
- [11] Peck S, Peck L, Kataja M. Concomitant occurrence of canine malposition and tooth agenesis: evidence of orofacial genetic fields. *Am J Orthod Dentofacial Orthop.* 2002;122(6):657–660. doi: [10.1067/mod.2002.129915](https://doi.org/10.1067/mod.2002.129915).
- [12] Garib DG, Peck S, Gomes SC. Increased occurrence of dental anomalies associated with second-premolar agenesis. *Angle Orthod.* 2009;79(3):436–441. doi: [10.2319/021308-87.1](https://doi.org/10.2319/021308-87.1).
- [13] Shalish M, Peck S, Wasserstein A, et al. Increased occurrence of dental anomalies associated with infraocclusion of deciduous molars. *Angle Orthod.* 2010;80(3):440–445. doi: [10.2319/062609-358.1](https://doi.org/10.2319/062609-358.1).
- [14] Polder BJ, Van't Hof MA, Van der Linden FP, et al. A meta-analysis of the prevalence of dental agenesis of permanent teeth. *Community Dent Oral Epidemiol.* 2004;32(3):217–226. doi: [10.1111/j.1600-0528.2004.00158.x](https://doi.org/10.1111/j.1600-0528.2004.00158.x).
- [15] Khalaf K, Miskelly J, Voge E, et al. Prevalence of hypodontia and associated factors: a systematic review and meta-analysis. *J Orthod.* 2014;41(4):299–316. doi: [10.1179/1465313314Y.0000000116](https://doi.org/10.1179/1465313314Y.0000000116).
- [16] Ojala-Alasuutari M, Hassan SJ, Näpänkangas R, et al. Distribution of congenitally missing teeth and treatment options for the lower second premolars in patients referred to special care. *Acta Odontol Scand.* 2022;80(5):382–388. doi: [10.1080/00016357.2021.2021282](https://doi.org/10.1080/00016357.2021.2021282).
- [17] Brin I, Becker A, Shalhav M. Position of the maxillary permanent canine in relation to anomalous or missing lateral incisors: a population study. *Eur J Orthod.* 1986;8(1):12–16. doi: [10.1093/ejo/8.1.12](https://doi.org/10.1093/ejo/8.1.12).
- [18] Mercuri E, Cassetta M, Cavallini C, et al. Dental anomalies and clinical features in patients with maxillary canine impaction. *Angle Orthod.* 2013;83(1):22–28. doi: [10.2319/021712-149.1](https://doi.org/10.2319/021712-149.1).
- [19] Ruiz-Mealin EV, Parekh S, Jones SP, et al. Radiographic study of delayed tooth development in patients with dental agenesis. *Am J Orthod Dentofacial Orthop.* 2012;141(3):307–314. doi: [10.1016/j.ajodo.2011.08.026](https://doi.org/10.1016/j.ajodo.2011.08.026).
- [20] Navarro J, Cavaller M, Luque E, et al. Dental anomaly pattern (DAP): agenesis of mandibular second premolar, distal angulation of its antimere and delayed tooth formation. *Angle Orthod.* 2014;84(1):24–29. doi: [10.2319/030513-183.1](https://doi.org/10.2319/030513-183.1).
- [21] León-Rubio C, Martín-Vacas A, Saavedra-Marbán G, et al. Association between dental agenesis and delay in dental development: a preliminary study in a Spanish paediatric population in relation with dental anomaly pattern (DAP). *BMC Oral Health.* 2022;22(1):468. doi: [10.1186/s12903-022-02522-6](https://doi.org/10.1186/s12903-022-02522-6).
- [22] Bjerklin K, Kuro J, Valentin J. Ectopic eruption of maxillary first permanent molars and association with other tooth and developmental disturbances. *Eur J Orthod.* 1992;14(5):369–375. doi: [10.1093/ejo/14.5.369](https://doi.org/10.1093/ejo/14.5.369).
- [23] Mitchell L. Canines. In: Littlewood SJ, Mitchell L, editors. *An introduction to orthodontics*. 5th ed. Oxford: Oxford University Press; 2019. p. 176–184.
- [24] Shapira Y, Kufnec MM. Maxillary tooth transpositions: characteristic features and accompanying dental anomalies. *Am J Orthod Dentofacial Orthop.* 2001;119(2):127–134. doi: [10.1067/mod.2001.111223](https://doi.org/10.1067/mod.2001.111223).
- [25] Shalish M, Chaushu S, Wasserstein A. Malposition of unerupted mandibular second premolar in children with palatally displaced canines. *Angle Orthod.* 2009;79(4):796–799. doi: [10.2319/081808-435.1](https://doi.org/10.2319/081808-435.1).
- [26] Baccetti T, Leonardi M, Giuntini V. Distally displaced premolars: a dental anomaly associated with palatally displaced canines. *Am J Orthod Dentofacial Orthop.* 2010;138(3):318–322. doi: [10.1016/j.ajodo.2008.09.036](https://doi.org/10.1016/j.ajodo.2008.09.036).
- [27] Grahnén H. Hypodontia in the permanent dentition. *Odontol Revy.* 1956;7:1–100.
- [28] Nelson SJ. Chapter 6, The permanent maxillary incisors. *Wheeler's dental anatomy, physiology and occlusion*. 11th ed. St. Louis (MO): Elsevier; 2019; p. 90–102.
- [29] Demirjian A, Goldstein H, Tanner JM. A new system of dental age assessment. *Hum Biol.* 1973;45(2):211–227.
- [30] Demirjian A, Goldstein H. New systems for dental maturity based on seven and four teeth. *Ann Hum Biol.* 1976;3(5):411–421. doi: [10.1080/03014467600001671](https://doi.org/10.1080/03014467600001671).
- [31] Chaillet N, Nyström M, Kataja M, et al. Dental maturity curves in Finnish children: Demirjian's method revisited and polynomial functions for age estimation. *J Forensic Sci.* 2004;49(6):1–8. doi: [10.1520/JFS2004211](https://doi.org/10.1520/JFS2004211).
- [32] Kuro J. Infraocclusion of primary molars: an epidemiologic and familial study. *Community Dent Oral Epidemiol.* 1981;9(2):94–102. doi: [10.1111/j.1600-0528.1981.tb01037.x](https://doi.org/10.1111/j.1600-0528.1981.tb01037.x).
- [33] Odeh R, Mihailidis S, Townsend G, et al. Prevalence of infraocclusion of primary molars determined using a new 2D image analysis methodology. *Aust Dent J.* 2016;61(2):183–189. doi: [10.1111/adj.12349](https://doi.org/10.1111/adj.12349).
- [34] Thilander B, Myrberg N. The prevalence of malocclusion in Swedish schoolchildren. *Scand J Dent Res.* 1973;81(1):12–21. doi: [10.1111/j.1600-0722.1973.tb01489.x](https://doi.org/10.1111/j.1600-0722.1973.tb01489.x).
- [35] Camilleri S. Maxillary canine anomalies and tooth agenesis. *Eur J Orthod.* 2005;27(5):450–456. doi: [10.1093/ejo/cji040](https://doi.org/10.1093/ejo/cji040).
- [36] Haavikko K. Hypodontia of permanent teeth. An orthopantomographic study. *Suom Hammaslaak Toim.* 1971;67(4):219–225.
- [37] Rølling S, Poulsen S. Agenesis of permanent teeth in 8138 Danish schoolchildren: prevalence and intra-oral distribution according to gender. *Int J Paediatr Dent.* 2009;19(3):172–175. doi: [10.1111/j.1365-263X.2008.00958.x](https://doi.org/10.1111/j.1365-263X.2008.00958.x).
- [38] Hua F, He H, Ngan P, et al. Prevalence of peg-shaped maxillary permanent lateral incisors: a meta-analysis. *Am J Orthod Dentofacial Orthop.* 2013;144(1):97–109. doi: [10.1016/j.ajodo.2013.02.025](https://doi.org/10.1016/j.ajodo.2013.02.025).
- [39] Choi SJ, Lee JW, Song JH. Dental anomaly patterns associated with tooth agenesis. *Acta Odontol Scand.* 2017;75(3):161–165. doi: [10.1080/00016357.2016.1273385](https://doi.org/10.1080/00016357.2016.1273385).