

From:
The Department of Roentgenology,
Institute of Dentistry,
Turku, Finland

CORTICAL RATIO AS AN INDICATOR OF THE MINERAL CONTENT OF HUMAN MANDIBULAR BONES

by

AATOS KIMINKI

ERKKI H. TAMMISALO

INTRODUCTION

Assessment of the density i.e. the mineral content of bone, is of importance when bone changes due to local or systemic conditions are to be analysed. Most of the methods worked out for determining bone density *in vivo* are based on the transmission of polychromatic radiation as estimated by film densitometry. These methods have, however, many pitfalls and they require the use of special and somewhat complicated equipment. Simple thickness measurement of the cortical bone has given results comparable in accuracy with those obtained by densitometric methods and has therefore been the centre of clinical interest in recent years. Several such studies dealing with long limb bones and finger bones have been reported (*Virtama & Mähönen, 1960; Barnett & Nordin, 1960; Virtama & Telkkä, 1962; Bernard & Laval-Jeantet, 1962; Virtama et al., 1963*).

On the bones of the jaws no corresponding studies have so far been reported. These bones would, however, be of special interest as their densities can be expected to undergo considerable changes with decrease of function when the teeth are lost. The structure of upper jaws makes them not suitable for this type of an investigation. The present study was therefore undertaken to determine the relationship between cortical bone thickness and density of mandibular bones.

Received for publication, February 20, 1969.

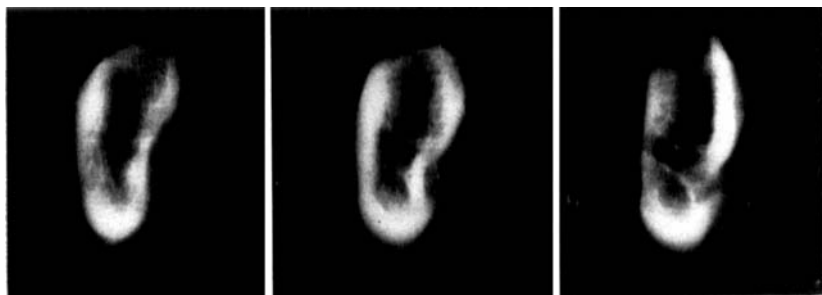

Fig. 1. Three simultaneous tomogram sections of a mandibular body.

MATERIAL AND METHOD

The material comprised ten mandibular bones removed *post mortem*, which, deriving from 7 males and 3 females, aged from 31 to 72 years, represented various degrees of mineralization. The mandibles were macerated, defatted with benzol and sectioned bilaterally into mandibular bodies, rami and condyles. The mandibular bodies and rami were radiographed with a diagnostic X-ray machine by a unilinear tomographic technique. Three transversal sections were simultaneously recorded from each piece of bone (Fig. 1). The distance from the focus to the point of rotation was 85 cm and to the middlemost film 98 cm. The exposure factors were 75 kV and 125–250 mAs. The film used was a Kodak Crystallex fine-grained non-screen X-ray film. The tomograms obtained were magnified by using 4 fold linear enlargement on Kodak radiographic duplicating film. The thickness of the bone cortex was determined and expressed in the manner recommended by *Virtama et al.* (1962, 1963) in which the bone diameters as well as the area of their cortical layers were measured planimetrically from the enlarged images. By dividing the cortical area by the total area of the transverse section of the bone and by multiplying this fraction by ten the cortical ratio was obtained. The arithmetic mean of the cortical ratios, shown by the three simultaneous tomograms of each mandibular body and ramus, was used in the statistical procedures. The accuracy of the planimetric determination of the ratio of the cortical area was studied. Triplicate parallel estimations were made from enlarged images of 10 body and 10 ramus parts chosen at random. The percentual standard error in determining the cortical ratio was about 0.9 %.

The density of the bones was determined as described in a previous paper (*Tammisalo & Kiminki, 1969*) Bone density was considered to be an ex-

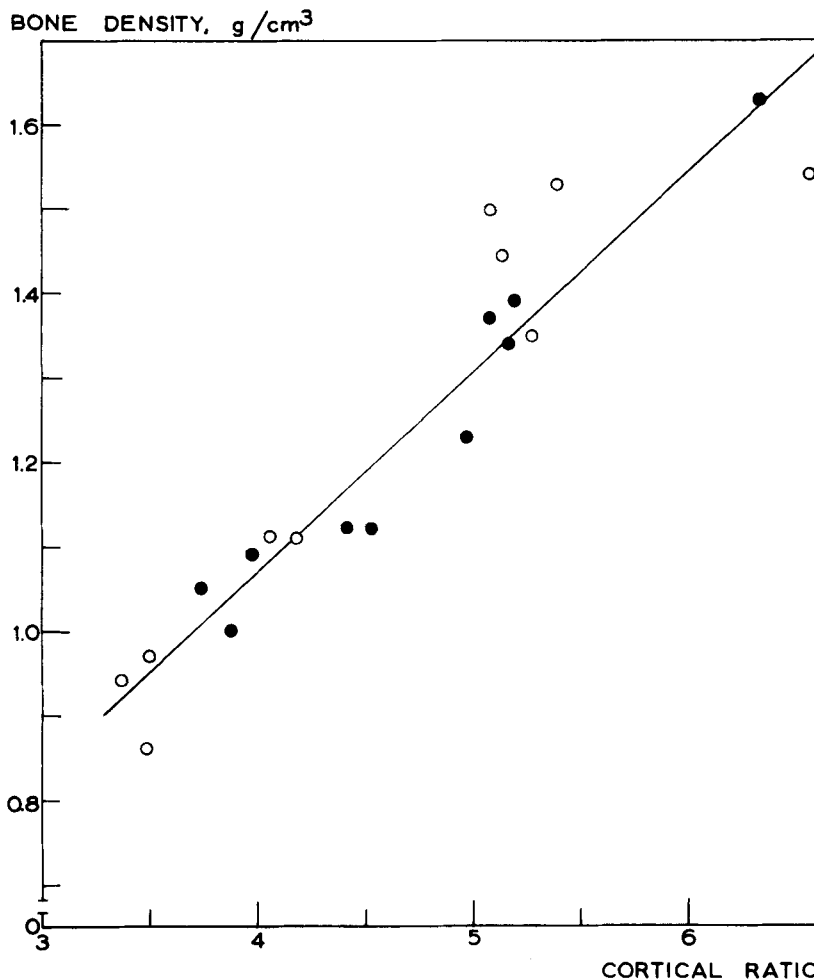


Fig. 2. Scatter diagram showing the correlation between the cortical ratio and the actual density (dry weight per volume) of mandibular bodies.

pression of the weight of the bone per unit volume, not the specific gravity of bone substance, and the volume was considered to be all that which was enclosed by the surface of the bone, including both the bone substance and the marrow and other cavities contained within its surface.

RESULTS

The cortical ratios were plotted against the corresponding bone densities (Figs. 2 and 3). Because the material consisted of ten mandibles only, the

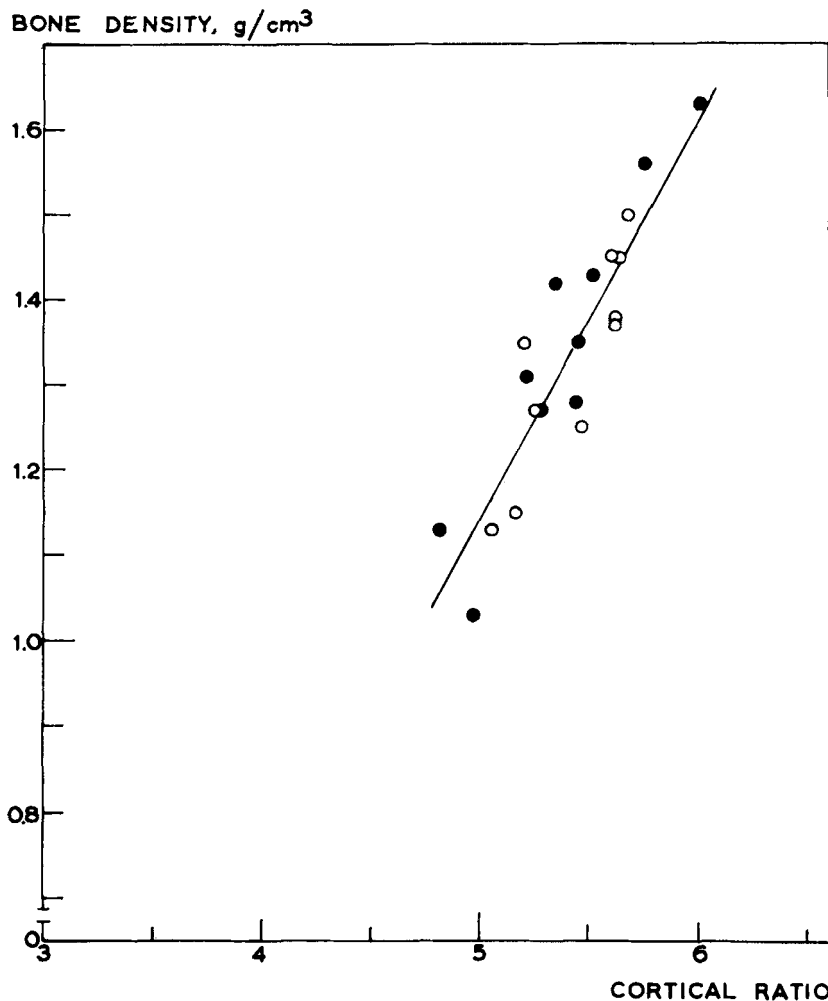


Fig. 3. Scatter diagram showing the correlation between the cortical ratio and the actual density (dry weight per volume) of mandibular rami.

regressions were estimated separately for the left and the right mandibular halves and their combined regression line was then calculated.

The regression equations obtained were as follows:

mandibular body,

$$X = 0.47 (Y - 5.00) + 1.14 \pm 0.07$$

mandibular ramus,

$$X = 0.24 (Y - 4.00) + 1.08 \pm 0.08$$

where X represents bone density and Y the cortical ratio. The constants 5.00 and 4.00 represent the rounded average values of the cortical ratios of mandibular body and ramus. Correlation coefficients were 0.94 and 0.90.

DISCUSSION

The present results show a highly significant correlation at the level of $P < 0.001$ between the cortical ratio and the dry weight divided by the volume of the bone. Furthermore, the results seem to indicate that the cortical ratio of the mandibular bone can be determined with great accuracy by the aid of the tomographic method adopted in this study.

The cortical ratios obtained from mandibles showed considerably higher values than those reported for femora and finger bones. This suggests a relatively greater amount of compact bone in the mandible. A more interesting finding is that equal cortical ratios, not only of mandibular bodies and rami, but also of femora and finger bones, do not correspond to equal bone densities. This is due to a difference in the proportion of cancellous bone in different bones or parts of bones. The cortical ratio of a bone with a dense cancellous pattern is correlated to higher values of bone density than the equal cortical ratio of a bone furnished with a slighter amount of cancellous bone.

As has been stated earlier, the dry weight of bone can be used as an estimate of the true calcium content (*Telkkä et al.*, 1962; *Kiminki & Tammi-salo*, 1969). In fact, a highly significant correlation could also be found between the cortical ratio and the actual mineral content of mandibular bodies and rami. On the other hand, however, the compact bone is not a sensitive indicator of demineralization (*Cooke*, 1955) and the range of individual variations in the cortical ratio in larger populations will probably be considerably wide. Therefore, even if the cortical ratio provides an easy and objective means of assessing the average density of the mandibular bone in groups or relative changes in density of the mandibular bones of same individuals, not too much emphasis should be given to this factor as an indicator of the mineral content of the mandible in single cases.

Acknowledgement. This investigation has been aided by a grant from the Finnish Dental Society.

SUMMARY

For radiographic recording of the thickness of the cortical layer of ten mandibular bodies and rami multisection tomography was used. Three transversal sections were simultaneously recorded at each exposure. The tomograms obtained from the bone samples were enlarged to five times their diameters. The areas of the cortical spheres and the total areas of the transverse sections of the bones were planimetrically measured. The ratio of these areas multiplied by ten was used as cortical ratio of the mandibular bone. A highly significant correlation was found between the cortical ratio and the bone density (dry weight per volyme) of mandibular bodies and rami. The cortical ratio of the mandibular body, however, correlated to higher density values than did the cortical ratio of the mandibular ramus owing to the denser cancellous pattern of the mandibular bodies.

RÉSUMÉ

LE RAPPORT CORTICAL COMME INDICATEUR DE LA TENEUR EN SUBSTANCES MINÉRALES DE L'OS MANDIBULAIRE HUMAIN.

Afin d'enregistrer par radiographies l'épaisseur de la couche corticale du corps de la mandibule et de la branche montante, des tomographies à sections multiples ont été exécutées sur 10 mandibules. Trois coupes transversales ont été enregistrées simultanément lors de chaque prise de cliché. Les tomographies obtenues à partir des spécimens d'os ont été agrandies cinq fois. La surface des sphères corticales et la surface totale des coupes transversales des os ont été mesurées par planimétrie. Le rapport entre ces surfaces, multiplié par 10, a été pris comme rapport cortical de l'os mandibulaire. Une corrélation fortement significative a été trouvée entre le rapport cortical et la densité osseuse (poids sec/volume) des corps de la mandibule et des branches montantes. Le rapport cortical du corps de la mandibule, cependant, était lié à des valeurs de la densité plus élevées que celui de la branche montante, en raison de la structure plus dense de l'os spongieux dans le corps de la mandibule.

ZUSAMMENFASSUNG

DER KORTICALE KNOCHENANTEIL ALS INDICATOR DES MINERALGEHALTS IN DER MENSCHLICHEN MANDIBULA

Für die röntgenographische Aufnahme der Korticalisdicke von zehn Mandibula Körpern und Rami wurde die Multisectionstomographie bewendet. Drei transversale Schnitte wurden simultan bei jeder Belichtung aufge-

nommen. Die Tomogramme der Knochenstücke wurden zu $5\times$ ihrem Durchmesser vergrößert. Die kortikalen und totalen Flächen der transversalen Knochenschnitte wurden planimetrisch ausgemessen. Das Verhältnis dieser Flächen multipliziert mit 10 wurde als kortikale Ratio des Mandibula Körpers bezeichnet. Ein bedeutungsvoller Zusammenhang wurde zwischen dem kortikalen Anteil und der Knochendichte gefunden: (Trockengewicht pro Volumen) der Mandibula Körper und Rami. Der Mandibula Körper war jedoch von grösserer Dichte als der Ramus wegen der dichteren Spongiosastruktur des Mandibula Körpers.

REFERENCES

- Barnett E. & B. E. C. Nordin*, 1960: The radiological diagnosis of osteoporosis: A new approach. *Clin. Radiol.* 11:166.
- Bernard J. & M. Laval-Jeantet*, 1962: L'épaisseur relative de la corticale du tibia application a l'évaluation des ostéoporoses et des ostéoscléroses. *Presse med.* 70:889.
- Tammisalo E. H. & A. Kiminki*, 1969: Density and mineral content of human mandibles. *Acta Odont. Scand.* 27:403.
- Virtama P. & H. Mähönen*, 1960: Thickness of the cortical layer as an estimate of mineral content of human finger bones. *Brit. J. Radiol.* 33:60.
- Virtama P. & A. Telkkä*, 1962: Cortical thickness as an estimate of mineral content of human humerus and femur, *Brit. J. Radiol.* 35:632.
- Virtama P., A. Telkkä & P. Kajanoja*, 1963: Cortical ratio as an estimate of the mineral content of human femur. *Ann. Med. exp. Fenn.* 41:3.

Address:

*Institute of Dentistry,
University of Turku,
Turku 3, Finland*