

Keywords:

Stomatitis
Denture, complete, upper
Tissue conditioning
Denture liners
Denture rebasing

From:

The Department of Prosthetics,
University of Umeå, Sweden

A COMPARISON OF TWO PROSTHETIC METHODS FOR THE TREATMENT OF DENTURE STOMATITIS

KURT Å. OLSSON

BO BERGMAN

In a case series of 30 full denture patients, two prosthetic trauma-eliminating methods recommended for treating inflammation of the mucosa beneath full maxillary dentures, were compared: (A) indirect relining with cold-curing resin; (B) repeated temporary relining with a tissue conditioner.

No significant difference in healing time was found between the two methods, nor when the patients were grouped according to resilience of the anterior alveolar process or denture wearing habits.

The study indicates that the choice between the two methods may be based upon such factors as the time required at the operating chair, access to a dental technician, etc. In certain cases the use of a tissue conditioner may be preferred in order to allow displaced soft tissues to return to normal contour before impression taking.

Patients wearing full dentures often present with denture stomatitis. According to *Nyquist* (1952) and later confirmed by *Bergman, Carlsson & Hedegård* (1964) trauma is the predominant cause of the occurrence of denture stomatitis. Allergic reaction, while rare, cannot be entirely ruled out as an etiologic factor (*Nyquist*, 1952, 1958). The oral bacterial flora, especially *candida albicans*, has also been implicated in the etiology (*Budtz-Jørgensen & Bertram*, 1970 a and b).

The two most commonly used methods for eliminating trauma in the treatment of denture stomatitis are: (1) replacing the old denture with a new denture and (2) indirect relining of the old denture with cold curing acrylic resin and/or grinding to balanced occlusion and articulation. In recent years the so-called *tissue conditioners* have been suggested as reliners for treatment of denture stomatitis before impression taking for new dentures.

Tissue conditioners consist of a polymer powder and an aromatic ester/ethyl alcohol mixture (Braden, 1970). These materials have been widely used in dentistry in recent years. In prosthetics they have been recommended for use in the conditioning of displaced soft tissues of the edentulous areas in preparation for impression taking (Lytle, 1959; Chase 1961). Tissue conditioners have also been used as a diagnostic aid in determining the fit of dentures and as an impression material for edentulous areas (Wilson, Tomlin & Osborne, 1966; Erhardsson & Johansson, 1969, 1970). They have further been suggested as surgical dressings in oral and periodontal surgery (Frisch, Levin & Bhaskar, 1968).

As a new full denture is no guarantee that existing mucosal inflammation will heal (Bergman *et al.*, 1964), the purpose of the present study was to compare two relining methods for the treatment of denture stomatitis before the patients were fitted with new dentures.

- (A) indirect relining with cold curing acrylic resin (impression with zinc oxide and eugenol paste), and
- (B) repeated temporary relining with a tissue conditioner.

Both methods included grinding to balanced occlusion and articulation.

MATERIALS AND METHODS

In this study all persons who, during February and September, 1969, were registered for provision with new complete upper and lower dentures at the Department of Prosthetics, University of Umeå, were examined. In total 118 patients, 76 women and 42 men, were registered during the two periods. With the exception of those with granular inflammation all patients exhibiting inflammatory changes in the mucosa beneath the upper denture were selected. The 25 women (33% of the women in the total material) and 5 men (12%) who exhibited simple localized or simple generalized inflammation beneath their maxillary dentures constituted the experimental series. The sex and age distribution is shown in Table I. For all patients, a complete dental history was taken and a clinical examination including full mouth X-rays, was made. In order to test the principles used for the registration of the various clinical factors the authors together first examined a series of patients not included in the study. In the experimental study the first third of the patient material was examined by the two authors simultaneously. The remaining two thirds were examined by one of the authors. Using a classification system described by Bergman *et al.* (1964) the following factors were recorded:

Table I.

The distribution of the experimental patient material according to age and sex

Age	♂	♀
30—39		1
40—49		5
50—50	1	9
60—69	3	9
70—79	1	1
Total	5	25

Stability of the denture. In order to test its stability, the denture was pressed lightly against the supporting tissues — in the maxilla with two fingers in the centre of the denture base, and in the mandible in the premolar region of the denture — and an attempt was made to tip, rotate and/or displace it horizontally. The stability was assessed as satisfactory when no more than slight movements of the denture were effected. Otherwise the denture was recorded as unstable.

Occlusion. Occlusion was recorded as satisfactory when there was correct intercuspitation without premature contact on repeated habitual closing from a postural rest position and firm intermaxillary contact in the lateral and anterior segments as assessed by examination with a metal spatula. Otherwise occlusion was recorded as unsatisfactory.

Articulation. Articulation was recorded as satisfactory when an examination with a metal spatula demonstrated firm bilateral contact in lateral positions after gliding half the width of a premolar, and bilateral contact in protrusion position after forward gliding about 3 mm. Otherwise articulation was recorded as unsatisfactory.

Oral mucosa. The mucous membrane was recorded as healthy when no clinical signs of inflammation were observed. The mucosa was recorded as being inflamed when local/or general inflammation was observed in the palate or in the mucosa of the alveolar process.

Resilience of alveolar process. An assessment was made of the resilience of the maxillary anterior alveolar process and recorded as:

- Grade 1 if the mucosa was taut over the bone,
- Grade 2 if the top of the ridge was mobile against the bone, or
- Grade 3 if at least one-half the height of the ridge was mobile against the bone or if the alveolar process was absent.

All the upper and some of the lower dentures of the thirty patients fitted poorly and all the dentures showed incorrect occlusion and articulation. The thirty patients were divided into two groups by formal randomization and the groups treated as follows:

Group A: *indirect relining with cold curing acrylic resin.* Using an impression taken in the upper denture with zinc oxide and eugenol paste, the relining was performed in the laboratory by conventional indirect technique. In a few cases the lower dentures were also relined in order to correct the fit. Grinding to balanced occlusion and articulation of the relined dentures was performed directly in the mouth.

Group B: *repeated temporary relining with a tissue conditioner.* The extension of the upper denture was examined and undercuts were removed from the denture base. The denture was cleansed and dried and all surfaces except the denture bearing area were isolated with a lubricant*). The powder and liquid of the tissue conditioner**) were mixed in proper amounts according to the directions of the manufacturer and the mix was allowed to set for 60 seconds. Thereafter the material was poured into the denture which was inserted in the patient's mouth. The patients were asked to gently hold together in occlusion for about four minutes. Thereafter the denture was removed and examined. If any of the denture base material showed through, these areas were relieved and a layer of new mix was added in this region. When a satisfactory uniform layer was achieved, excess material was trimmed away. In some few cases the lower denture, because of its instability, was also temporarily relined. Grinding to balanced occlusion and articulation was performed directly in the mouth.

Each patient was given individual instruction in oral and dental hygiene. All patients were recalled every third to fifth day for control of the status of the oral mucosa. At the same time necessary corrections of occlusion and articulation were undertaken. When further treatment was needed for patients treated with tissue conditioner the entire procedure described in method B was repeated.

Either treatment was deemed to be successful at that visit when clinical healing of the inflammation beneath the upper denture could be demonstrated.

*) Coe Lubricant and

**) Coe Comfort, Coe Laboratories, Inc., Chicago, Ill., U.S.A.

Table II.

The healing time in days for the maxillary mucosa beneath complete upper dentures in the two experimental groups

Treatment		median	range
(A) Relining with cold-curing acrylic resin	(n=15)	14,5	4-70
(B) Temporary relining with tissue conditioner	(n=14)	20	7-34

RESULTS

In group A (relining with cold curing acrylic resin) one patient, a 55 year old woman who presented with a heavy inflammation and persistently complained of severe pain in the oral mucosa did not show any improvement during an observation time of 3 weeks. She was therefore referred for medical examination and was diagnosed as having severe iron deficiency anemia and rheumatic symptoms in combination with Sjögren's conjunctivitis sicca. This patient was thus excluded from the experimental series.

As can be seen from Table II, the median healing time was much the same in the two treatment groups. Using Wilcoxon's rank sum test (*Brownlee, 1965*) no significant difference was found between groups A and B.

In Table III the healing time is given in relation to the degree of resilience of the upper alveolar process. No significant differences were found between the resilience groups with regard to the healing time. Twenty-five of the patients wore their dentures day and night; the remaining four wore their dentures only during the day. No significant difference was found in healing time when the patients were grouped according to their denture wearing habits.

Table III.

The healing time in days in the two experimental groups divided according to the grade of resilience (1-3) of maxillary alveolar process

Treatment	Grade of resilience					
	1		2		3	
	median	range	median	range	median	range
(A) relining with cold-curing acrylic resin	15 n=5	14-17	14 n=9	4-70	—	—
(B) temporary relining with tissue conditioner	20 n=3	8-23	19 n=11	7-34	34 n=1	—

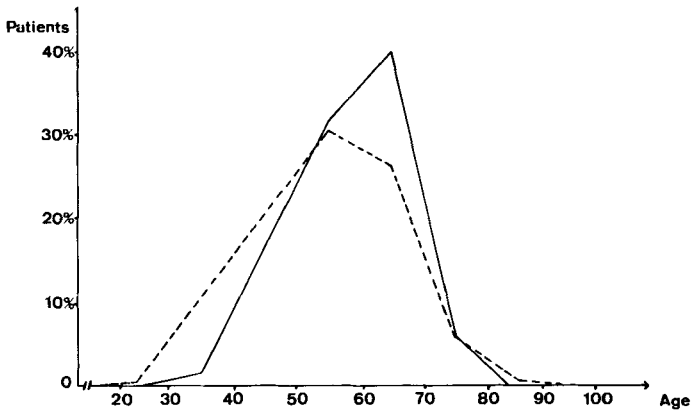


Fig. 1. Age distribution of patients registering for full denture treatment.
 — The present study.
 - - - Study of Bergman *et al.*, 1964 (*loc.cit.*)

DISCUSSION

Of the 118 patients who during two months were registered for new complete upper and lower dentures (preliminary case series) 76 were women (64%) and 42 were men (36%). In Fig. 1 the age distribution of the preliminary patient material in the present study is compared with that of Bergman *et al.* (1964). The distribution according to age and sex is quite similar in the two studies. The present preliminary patient material may therefore from these points of view be regarded as representative for patients treated at the department.

Clinical inflammation is more common beneath maxillary dentures than mandibular dentures (Bergman *et al.*, 1964), and for that reason only patients presenting with denture stomatitis beneath maxillary dentures were included in this study. Of the 118 patients, 33% of the women (25 patients) and 12% of the men (5 patients) presented with denture stomatitis beneath upper dentures. The difference in the frequency between men and women is highly significant ($p < 0.001$, chi-square test) and is in agreement with Nyquist (1952), Neill (1961), Davenport (1970) and Bergman *et al.* (1971). However Bergman *et al.* (1964) could not establish any difference in the frequency of denture stomatitis between men and women.

In 22 of the 30 patients in the experimental groups more than half of the denture covered area was inflamed. For that reason no grouping of the patients was performed according to the extent of the chronic inflammation. As the aim of the present study was to make a comparison between two

prosthetic methods for the treatment of denture stomatitis, patients presenting with granular inflammation were not included. A granular denture stomatitis cannot be healed by prosthetic treatment alone but must be treated with combined prosthetic and surgical measures (*Isaksson, 1970*).

When using a tissue conditioner beneath a denture, grinding to balanced occlusion and articulation must be performed in the mouth. In order to allow for a direct comparison between the two experimental methods, the same grinding procedure was also adapted for the dentures relined with cold curing acrylic resin.

All of the patients in the experimental series presented initially with dentures with poor fit and incorrect occlusion and articulation. By relining and grinding, trauma was eliminated as judged clinically, and the upper mucosa healed in 29 of 30 patients. In the section RESULTS, an account has been given for the patient excluded from the present study. This single case serves as a reminder that systemic disease may influence the tolerance of the oral mucosa and that endogenous factors must be considered in establishing the etiology of denture stomatitis in each individual case (*Reither, 1961; Taege & Ewald, 1969*).

The results obtained in the present study appear to support the opinion that trauma is a predominating etiological factor for denture stomatitis. Contradictory results have been reported regarding the significance of poor oral and denture hygiene for the development of denture stomatitis. *Nyquist (1953)* found that denture hygiene was of minor importance, whereas *Love, Goska & Mixson (1967)*, and *Budtz-Jørgensen & Bertram (1970a)* reported a correlation between poor oral and/or denture hygiene and the incidence of denture stomatitis. In the present study, the patients were given individual instruction and information regarding oral and denture hygiene and, as they were recalled every third to fifth day, they were under continuous supervision. It is therefore possible that their efforts to maintain good oral and denture hygiene may have contributed to the healing results.

According to *Budtz-Jørgensen & Bertram (1970b)* treatment for 6 days with the same tissue conditioner as that used in the present study led to an improved condition of the mucosa in 10 out of 11 patients who did not show hyphal structures in palatal smears prior to treatment. Of 11 patients with a verifiable candida infection prior to treatment, only one showed reduced inflammation. Thus in their study a short-term (6 day) therapeutic effect was noted primarily in patients in whom no candida infection could be verified. In the present study two prosthetic methods for eliminating denture trauma were compared. No attention was paid to the presence or absence of candida, nor was any chemotherapeutic treatment undertaken, unless the

tissue conditioner, which according to the manufacturer contains a fungicidal and bacteriocidal agent, zinc undecylate, exerted such an effect. In contrast to *Budtz-Jørgensen & Bertram* (1970b) the treatment in the present study was not interrupted until clinical healing was observed in all patients. Further comparisons between the two studies are therefore not possible.

The results in the present study did not reveal that the tissue conditioner even with its possible bacteriocidal and fungicidal effect was superior to indirect relining using cold-curing acrylic resin as a method of treatment of inflamed maxillary mucosa. The choice between the two methods may, therefore, be based upon such factors as the time required at the operating chair, access to a dental technician, or whether or not tissue conditioning is deemed necessary. As pointed out by *Bergman et al.* (1964) a new denture is no guarantee that existing mucosal inflammation will heal. The results of the present study indicate that for patients presenting with denture stomatitis beneath old ill-fitting dentures either of the two tested relining methods may be recommended before new dentures are made.

Acknowledgements. Financial support was given by the Swedish Dental Society.

REFERENCES

- Bergman, B., G. E. Carlsson & B. Hedegård*, 1964: A longitudinal two-year study of a number of full denture cases. *Acta odont. Scand.* 22: 3—26.
- Bergman, B., G. E. Carlsson & S. Ericson*, 1971: Effect of differences in habitual use of complete dentures on underlying soft and hard tissues. *Scand. J. dent. Res.* 79: 449—460.
- Braden, M.*, 1970: Tissue conditioners: I. Composition and structure. *J. dent Res.* 49: 145—148.
- Brownlee, K. A.*, 1965: *Statistical theory and methodology in science and engineering.* Wiley, New York 1965.
- Budtz-Jørgensen, E. & U. Bertram*, 1970 a: Denture stomatitis. I. The etiology in relation to trauma and infection. *Acta odont. Scand.* 28: 71—92.
- 1970 b: Denture stomatitis. II. The effect of antifungal and prosthetic treatment. *Acta odont. Scand.* 28: 283—304.
- Chase, W. W.*, 1961: Tissue conditioning utilizing dynamic adaptive stress. *J. Prosth. Dent.* 11: 804—815.
- Davenport, J. C.*, 1970: The oral distribution of candida in denture stomatitis. *Brit. dent. J.* 129: 151—156.
- Erhardson, S. & E. G. Johansson*, 1969: Coe-Comfort som avtrycksmaterial — laboratorieundersökning av två väsentliga egenskaper (with an English summary) *Svensk. tandläk.* — T. 62: 213—225.
- 1970: Jämförande undersökning av Coe-Comfort, Coe-soft och Ivoseal som avtrycksmaterial. (with an English summary) *Svensk tandläk.* — T. 63: 633—645.

- Frisch, J., M. P. Levin, & S. N. Bhaskar*, 1968: Clinical study of fungal growth on tissue conditioners. *J. Am. dent. Ass.* 76: 591—592.
- Isaksson, B.*, 1970: Electrocoagulation in treatment of stomatitis prothetica granulomatosa. *Svensk tandläk.* — T. 63: 551—555.
- Love, W. D., F. A. Goska, & R. J. Mixson*, 1967: The etiology of mucosal inflammation associated with dentures. *J. Prosth. Dent.* 18: 515—527.
- Lytle, R. B.*, 1959: Complete denture construction based on a study of the deformation of the underlying soft tissues. *J. Prosth. Dent.* 9: 539—551.
- Neill, D. J.*, 1961: Denture sore mouth an endocrine influence? *Pent. Dractit.* 11: 199—200.
- Nyquist, G.*, 1952: A study of denture sore mouth. *Acta odont. Scand.* 10: suppl. 9. (Thesis).
—»— 1953: The influence of denture hygiene and the bacterial flora on the condition of the oral mucosa in full denture cases. *Acta odont. Scand.* 11: 24—61.
—»— 1958: Sensitivity to methyl methacrylate. *Transactions of the Royal Schools of Dentistry, Stockholm and Umeå* No. 1 p. 36—51.
- Reither, W.*, 1961: Die Bedeutung endogener Faktoren für die Entstehung von Prothesenstomatopathien. *Dtsch. zahnärztl. Z.* 16: 109—119.
- Taege, F. & M. Ewald*, 1969: Die Häufigkeit der Stomatitis prothetica bei Lebererkrankungen. *Dtsch. Zahn-, Mund- u. Kieferheilk.* 53: 1—10.
- Wilson, H. J., H. R. Tomlin, & J. Osborne*, 1966: Tissue conditioners and functional impression materials. *Brit. dent. J.* 121: 9—16.

Address:

*Department of Prosthetics,
University of Umeå
S-901 87 Umeå, Sweden*