

ORIGINAL ARTICLE

## Restorative treatment strategies for patients with cleidocranial dysplasia

HUAIGUANG CHANG<sup>1</sup>, JIAHUI WEI<sup>1</sup>, YING WANG<sup>1</sup>, JING JIA<sup>1</sup>, XUEMEI GAO<sup>2</sup>,  
XIAOTONG LI<sup>2</sup> & HAILAN FENG<sup>1</sup>

<sup>1</sup>Department of Prosthodontics, and <sup>2</sup>Department of Orthodontics, Peking University School and Hospital of Stomatology, Beijing, China

### Abstract

**Objective.** To develop a suitable treatment strategy for patients with cleidocranial dysplasia (CCD) who miss the optimal early treatment stage. **Materials and methods.** This study enrolled 15 patients with CCD who had all missed the optimal treatment stage and were diagnosed with CCD through clinical examinations and genetic tests. Based on the chief complaints and requirements of the patients, three different therapeutic schedules were devised for these patients. Schedules I (periodontal and endodontic treatments) and II (periodontal, endodontic and prosthodontic treatments) were used for patients with low requirements, whereas Schedule III (multidisciplinary strategy, including periodontal, endodontic, surgical, orthodontic and prosthodontic treatments) was used for patients with high requirements. **Results.** Schedules I, II and III were used in five, seven and three patients, respectively. Schedule III treatments produced the best outcomes in terms of occlusion and esthetics. **Conclusions.** Schedule III based on a comprehensive multidisciplinary therapy is an ideal restorative therapeutic strategy and can achieve good outcomes for patients with CCD who missed the optimal treatment stage.

**Key Words:** *cleidocranial dysplasia, multidisciplinary treatment, RUNX2, supernumerary teeth*

### Introduction

Cleidocranial dysplasia (CCD; OMIM# 119600) is a rare congenital disorder, which usually has an autosomal dominant mode of inheritance. The main causes of CCD are heterozygous mutations (e.g. gene insertions and deletions) in the RUNT-related transcription factor 2 (Cbfa1) gene, which is located on chromosome 6p21 [1]. The clinical manifestations of CCD are mainly related to the bones and teeth. The bone-related manifestations of CCD include clavicular aplasia, pseudarthrosis formation, drooping shoulders, hypermobility of the shoulders, delayed closure or non-closure of the fontanel, broadening of the cranial sutures, distention of the cranial vault, bell-shaped chest, distal phalanx dysplasia (resulting in brachydactyly), broadening of the pubic symphysis (causing pelvic dysplasia) and moderately short stature. The main tooth-related findings are deformity, dysplasia, delayed eruption of permanent teeth, supernumerary teeth and impacted teeth [2]. Overall, the three most common clinical manifestations of

CCD are clavicular dysplasia, delayed closure or non-closure of the fontanel and supernumerary teeth [3]. Among dental defects, supernumerary teeth, retained deciduous teeth and delayed eruption of permanent teeth are the three most common clinical findings of CCD [4]. Patients with these defects often present with masticatory hypofunction and poor esthetics caused by dentition defects or malocclusion.

Generally, the management of CCD mainly involves expectant treatment after symptoms appear. The more severe symptoms require repair surgery, such as skull repair surgery, clavicle repair surgery and orthognathic surgery, but this article only focused on the treatment of dental imperfections found in CCD, which present with a very high incidence (93.5% of patients with CCD) [5]. According to the report by Jensen and Kreiborg [6], the optimal treatment period for CCD patients is between 5–7 years of age, because it should be possible to diagnose supernumerary incisors at this time point and supernumerary canines and premolars a few years later; therefore, early intervention could be undertaken. If this treatment stage is

missed, the gradual formation of tooth roots along with delayed absorption of the roots of deciduous teeth will eventually cause delayed eruption or impaction of permanent teeth, thus increasing both the difficulty in treatment and the patient's suffering. In our study, we have referred to treatment during the optimal treatment period as 'timely treatment' and later treatment as 'restorative treatment'. Several multidisciplinary treatment strategies have been proposed [7] for timely treatment, such as the Toronto–Melbourne approach, the Belfast–Hamburg approach, the Jerusalem approach and the Bronx approach [8–10]. However, most CCD patients seek clinical treatment only after the optimal treatment period; yet no suitable treatment strategy has been devised for these patients, and only individual case reports are available [2,5].

A comprehensive therapeutic strategy that restores masticatory function and esthetics in CCD patients who present after the optimal treatment period must be formulated through the long-term observation of CCD patients. In this study, we assessed 15 CCD patients who were presented after the optimal treatment period and were treated between 2005–2013. Here, we summarize and analyze their treatment outcomes and attempt to use this data to devise a suitable clinical treatment strategy for patients undergoing restorative treatment.

## Materials and methods

### Patient selection

In this study, we retrospectively reviewed the medical data of 15 patients with CCD who underwent restorative treatment at our hospital between 2005–2013. They included six patients from two families and nine patients with sporadic cases of CCD. All study patients were Han nationality. All patients presented with different degrees of deciduous tooth retention and permanent tooth impaction, along with ocular hypertelorism, skull and clavicular aplasia and other symptoms. All patients were clinically diagnosed with CCD according to typical clinical manifestations and

auxillary genetic testing [11]. This study was approved by the ethics committee of Peking University.

### Physical and radiographic examinations

CCD was diagnosed on the basis of typical clinical manifestations in combination with X-ray findings [11]. Oral examination was conducted to record characteristics such as tooth eruption and retention, enamel development state and periodontal and occlusal conditions. Photographs of the intra-oral view, both shoulder joints, head and face were obtained in all patients. In addition, the following X-ray films were acquired to assess bone development: dental panoramic radiograph, lateral view of the head, chest radiograph, extremities radiograph and pelvic radiograph.

### *RUNX2* gene detection

After the patients provided informed consent, they were tested for the *RUNX2* gene [12]. Aliquots of peripheral blood (2 ml) were collected in anticoagulant (EDTA) tubes and used to extract genomic DNA; 1 µl of the extract was subjected to 1.0% agarose gel electrophoresis. Eight pairs of primers (Table I) were used for the polymerase chain reaction (PCR) amplification of eight exons in the *RUNX2* gene. The PCR products were detected and separated on agarose gel electrophoresis, and the target band was recycled for sequencing.

### Treatment strategies

Three different treatment strategies based on the chief complaints and requirements of the patients were used for dental therapy (Table II). Schedule I or II was applied in patients who had fewer dentition imperfections and/or low requirements and only needed periodontal or endodontic treatment, along with prosthodontic treatment when necessary. Patients with greater requirements were treated using a multidisciplinary treatment strategy (Schedule III) that included periodontal, endodontic, surgical, orthodontic and prosthodontic treatments.

Table I. Sequences of the primers used for the eight exons of the *RUNX2* gene.

Exon	Forward primer sequence (3°C→5°C)	Reverse primer sequence (3°C→5°C)	Annealing temperature (°C)
0	ATGGTTAATCTCCGCAGGTCA	GCTATTTGGAAAAGCTAGCAG	58
1	CCAAAGACTCCGGCAAAGAT	AAGGCAGGAGGAGTCTTGGAG	56.5
2	TGGCATCACAAACCATACAC	GTCTACATTTTCATCAAAGGAGC	59
3	AATTTAGAAGAAGGAGTCCTG	AAATATATGCAGATAGCAAAG	59
4	ATTCCTTGCTTAAACTCCCAG	GCCAGCTTTCACAGCTCCAGG	56
5	AACGCTTTGTGCTATTTAAGGCC	CCAGTTGTCATTCCCTTGCCC	61
6	CTCTGGGAAATACTAATGAGGGA	AGTGCCATGATGTGCATTTGTAAT	61
7	GGCTTGCTGTTCCCTTATGG	GGCTGCAAGATCATGACTGA	60

Table II. Chief complaints and requirements of CCD patients and the corresponding therapeutic schedules.

	Chief complaints and requirements of patients	Therapeutic schedules
Schedule I	Only endodontic or periodontal symptoms, few requirements	Periodontal and endodontic treatments
Schedule II	Failed eruption of permanent teeth, dentition defect	Periodontal, endodontic and prosthodontic treatments
Schedule III	Many esthetic requirements, desire for greater utilization of permanent teeth	Comprehensive treatment, including periodontal, endodontic, surgical, orthodontic and prosthodontic treatments

## Results

### Clinical diagnosis

Clinical and radiographic examinations revealed the typical clinical manifestations of CCD [11], such as incomplete closure of the fontanels, clavicular aplasia, deciduous tooth retention, supernumerary teeth, impacted teeth and distal phalanx dysplasia (Figure 1). The most common clinical manifestations included improper development of the clavicles and fontanels, with or without supernumerary teeth (Table III).

There were seven female and eight male patients. Twelve patients were adults at the time of presentation. The other three, patients 01, 04 and 09, were minors, but had missed the optimal treatment stage. As mentioned earlier, six patients (01–04, 10 and 11) were from two families, while the other nine patients had sporadic cases of CCD. Fourteen patients had delayed closure of the fontanelles and one patient did not have delayed closure of the fontanelle. All 15 patients had clavicular aplasia. Twelve patients had supernumerary teeth, including two patients with a history of tooth extraction, while three patients had no supernumerary teeth. Most patients were not tall (<165 cm), with the exception of one male patient who measured 171 cm.

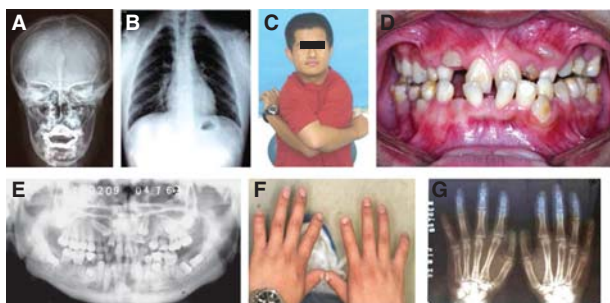


Figure 1. Typical clinical manifestations of CCD: (A) Radiograph showing non-closure of the fontanels, with clearly visible sutural bones. (B) Chest radiograph showing consecutive interruptions in the distal right clavicle, left clavicular aplasia. (C) Hypermobility of both shoulders due to clavicular aplasia. (D) Photograph showing deciduous and supernumerary teeth. (E) Dental panoramic radiograph showing deciduous, supernumerary and impacted teeth. (F and G) Distal phalanx dysplasia.

### Genetic diagnosis

Mutations were detected in the eight exons of the *RUNX2* gene in 13 patients; no *RUNX2* mutations were found in patients 07 and 08. Seven mutations were present in the RUNT domain, which was more than the number of mutations found in the Q/A domain and PST domain. Thus, 13 patients were genetically diagnosed with CCD.

### Therapeutic strategies and outcomes

Three treatment strategies based on the chief complaints and requirements of the patients were used. Schedule I was used for five patients, Schedule II for seven patients and Schedule III for three patients. In all 15 patients, the therapeutic outcomes were assessed on the basis of three aspects: periodontal status, occlusion and esthetics (Table IV). The clinical manifestations and therapeutic strategy in patient 15, who received Schedule III (multidisciplinary) treatment, is briefly described below.

- Patient 15:** This patient presented with poor oral hygiene, three impacted teeth (23, 33 and 34), four supernumerary teeth located (a) on the labial side of 11 and the root of 12, (b) near the middle of the palatal side of 24 and on the palatal side (c) between 25 and 26 and (d) between the roots of 33 and 34, skewing of the center-line of the maxillary teeth 2 mm to the left with a normal center-line of the mandibular teeth, ocular hypertelorism, bridge collapse, flat cranial vault, hypoplastic mid-face, other usual features of the CCD facies, tall and narrow palate vaults, short stature and other symptoms (Figure 2). This patient underwent periodontal, endodontic, surgical, orthodontic and prosthodontic treatments in five departments from 1996–2013 (17 years). The main treatment procedures are shown in Table V.

## Discussion

As Schedule I did not include surgical and orthodontic treatments, the following problems were not resolved in patients treated with this strategy: irregular

Table III. Clinical manifestations of the 15 patients with CCD.

No.	Sex	Age (years)	Type of CCD	Delayed fontanel closure	Clavicular aplasia	Supernumerary teeth	Height (cm)
01 <sup>#</sup>	Female	16	Familial	Y	Y	9	150
02 <sup>#</sup>	Female	39	Familial	N	Y	1*	148
03 <sup>#</sup>	Female	34	Familial	Y	Y	4	146
04 <sup>#</sup>	Male	09	Familial	Y	Y	0	122
05 <sup>#</sup>	Female	42	Sporadic	Y	Y	4	160
06 <sup>#</sup>	Female	28	Sporadic	Y	Y	4	152
07 <sup>#</sup>	Female	28	Sporadic	Y	Y	0	155
08 <sup>#</sup>	Female	19	Sporadic	Y	Y	0	146
09 <sup>#</sup>	Male	15	Sporadic	Y	Y	6	171
10 <sup>#</sup>	Male	24	Familial	Y	Y	2*	158
11 <sup>#</sup>	Male	24	Familial	Y	Y	3	160
12 <sup>#</sup>	Male	26	Sporadic	Y	Y	2	162
13 <sup>#</sup>	Male	41	Sporadic	Y	Y	9	165
14 <sup>#</sup>	Male	29	Sporadic	Y	Y	2	160
15 <sup>#</sup>	Male	46	Sporadic	Y	Y	2	164

Y, present; N, not present.

\*, history of tooth extraction.

dentition, crowded dentition, and double dentition caused by supernumerary teeth. These problems resulted in repeated occurrences of gingivitis, periodontitis, and dental caries. In addition, without denture and prosthodontic treatment, occlusion and esthetics did not improve. In contrast, in patients who were treated using Schedule II, which included prosthodontic treatment, the occlusion and esthetics improved slightly, but malocclusion probably led to repeated episodes of periodontal disease and dental caries, especially when associated with poor oral hygiene [13,14]. Schedule III was an oral multidisciplinary therapeutic strategy incorporating periodontal and endodontic treatment as its foundation. Furthermore, surgical and orthodontic treatments were used to improve malocclusion and, therefore, improve masticatory function and esthetics. In addition, prosthodontic treatment or implant therapy was undertaken for functional and esthetic improvements. Therefore, Schedule III or similar interdisciplinary treatments should be adopted whenever possible.

Since most CCD patients present after the optimal treatment stage, exploring strategies for delayed treatment is of practical importance. In a review of the literature on CCD treatment, we found that almost every author had proposed a treatment strategy that was based solely on the professional field of the author [2,5,15]. As orthodontic treatment is increasingly becoming a key aspect of CCD treatment, almost all recent strategies described in the literature comprise multidisciplinary treatments, regardless of the professional field of the authors [15]. We, therefore, formulated a strategy for the restorative treatment of CCD on the basis of previous treatment schemes [8-10] and our clinical experience (Table VI).

The key point in the application of our treatment strategy is determining which patients required treatment. Although it is not difficult to select the appropriate treatment strategy in patients who are very young or very old, a judgment standard is necessary for patients in between these two groups. In general, the restorative treatment strategy should be adopted

Table IV. Evaluation of the effectiveness of the three therapeutic schedules.

	Quantity of patients	Therapeutic outcomes
Schedule I	5	Repeated recurrences of periodontitis and dental caries; malocclusion, only slight increase in masticatory efficiency; no esthetic improvement
Schedule II	7	Repeated recurrences of periodontitis and dental caries; improvement of occlusal relationships; slight esthetic improvement
Schedule III	3	Reduced recurrence of periodontitis and dental caries; good occlusal relationships; improved masticatory efficiency; improved esthetics



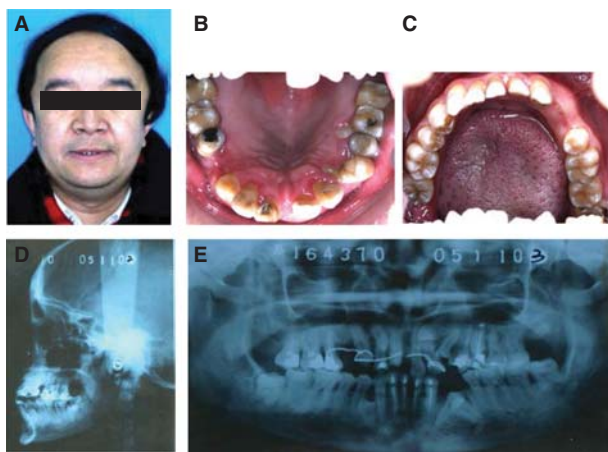


Figure 2. Patient 15 had CCD with four supernumerary teeth (three in the maxilla in the area of the premolars and one in the mandible in the area of the premolars) and three impacted teeth (one in the maxilla in the area of the premolars and two in the mandible in the area of the premolars): (A) Photograph of the patient showing ocular hypertelorism. (B) Photograph of erupted supernumerary teeth in the maxilla. (C) Photograph of the mandible. (D) Skull radiograph showing deformity of the skull, hypoplastic midface and supernumerary teeth. (E) Dental panoramic radiograph, confirming the diagnosis.

in patients who are older than 7 years. However, the exact cut-off should be based on the dental development of the patient. When the length of the roots of the normal permanent teeth has reached about one-third of its final length, the overlying supernumerary teeth should be removed, together with overlying bone and primary teeth. In regions where no supernumerary teeth are formed, tooth eruption may be improved by removal of the primary teeth and surgical exposure of the underlying permanent teeth [6].

During treatment, attention must be paid to the first step and the third step, according to the treatment

steps listed in Table VI. In the first step, it is essential that the diagnosis be made by a multidisciplinary team from the relevant departments after a comprehensive assessment of the deciduous, permanent and supernumerary teeth. Not all deciduous or supernumerary teeth need to be removed. Well-developed supernumerary and even deciduous teeth that are present at ideal locations and will not affect subsequent treatment can be retained. However, some permanent teeth which are dysplastic or ectopic need be removed, as they may cause difficulty in subsequent treatment. On the basis of this comprehensive evaluation, a multidisciplinary treatment plan should be formulated. The third step requires co-operation between surgeons and orthodontic specialists and involves tooth extraction followed by orthodontics or alternates between tooth extraction and orthodontics, depending on the treatment plan devised in the first step. A decision tree is shown in Figure 3. Early diagnosis and treatment should be advocated for CCD patients. Supernumerary teeth should be removed before the root develops completely, so as to facilitate the eruption of permanent teeth in the correct positions. Failure to do so will result in long-term dental health issues for the patients. Unfortunately, there exist some difficulties in the early diagnosis of CCD. First, the majority of patients have only mild systemic symptoms and, by the time they present with dental or esthetic problems, they tend to have missed the optimal treatment stage. In fact, many patients present for the first time after they have had their pubertal 'growth spurt'. This is because easily identifiable symptoms appear only during adolescence [16-19]. Second, about a third of patients have sporadic CCD, i.e. their parents do not have CCD and the clinical manifestations in these patients

Table V. Therapeutic procedures in patient 15.

Time (year)	Multidisciplinary therapy, including periodontal, endodontic, surgical, orthodontic and prosthodontic treatments
1996	Supragingival scaling; filling after root canal therapy at 15
1998	Subgingival scaling; 24, 25 filling
2003	Subgingival scaling; 12, 14 filling, 24, 25 root canal therapy; removal of 14, 15 as well as the supernumerary teeth at the labial side of 12 and lingual side of 24, 25
2004	Subgingival scaling; 31, 16, 17, 33, 42 root canal therapy; removal of 28; removable partial denture in maxilla
2005	Supragingival scaling; gingival excision and boning at 33; orthodontic traction of 33
2006	46, 36-38, 46, 47; 25-27, 15-17 scaling and root planing; 16 filling; 24, 25, 15 cutting crown; orthodontic traction of 34; over-denture in maxilla
2007	Supragingival scaling; maintenance of mandibular teeth
2008	Supragingival scaling; maintenance of maxillary teeth; over-denture in maxilla
2009	Supragingival scaling; 22, 12, 13, 38 filling; 11 laminate veneer
2010	Supragingival scaling; 12-17 scaling and root planning
2011	Supragingival scaling; 36, 38 filling; 37 root canal therapy
2012	Supragingival scaling; 26, 36, 37, 46, 47, 16 scaling and root planing
2013	Supragingival scaling; 37, 38 filling

Table VI. Restorative treatment strategies for patients with CCD.

Step 1	Comprehensive assessment of all teeth; formulation of a treatment plan in consultation with other relevant departments
Step 2	Periodontal and endodontic treatment; oral health education
Step 3	Tooth extraction, orthodontic treatment according to the treatment plan
Step 4	Prosthodontic treatment or implantation therapy for further functional and esthetic improvement

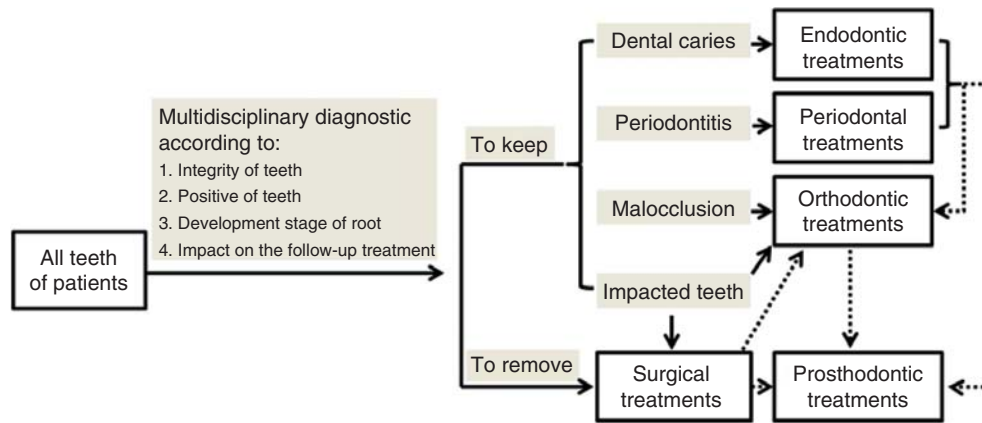


Figure 3. The decision tree. Interdisciplinary doctors comprehensively evaluated all of the teeth of patients with CCD. The integrity and position of teeth, developmental stage of the root and impact on the follow-up treatment were taken in account as reference points to decide which teeth were kept and which were removed. A treatment plan was finally formulated. If teeth that were kept had dental caries, periodontitis or malocclusion, then they underwent endodontic treatments, periodontal treatments or orthodontic treatments, respectively. If teeth that were kept were impacted, a full thickness mucoperiosteal buccal flap was raised, and the crowns of impacted teeth were exposed after the removal of bone covering the unerupted teeth. Orthodontic traction was then initiated with a light orthodontic force. After endodontic treatments and/or periodontal treatments, if necessary, orthodontic treatments and/or prosthodontic treatments were offered. On the other hand, if teeth had been removed according to the plan, orthodontic treatments and/or prosthodontic treatments could be used as follow-up treatments. Solid lines represent necessary treatment processes, while dotted lines represent the non-necessary treatment processes.

may be very mild and difficult to identify [11,12]. Third, the clinical findings of CCD are diverse and need to be differentiated from those of other diseases, making diagnosis based solely on clinical manifestations very difficult. Fourth, not every CCD patient presents with all the symptoms of CCD and some patients have atypical symptoms, which makes the clinical diagnosis of CCD relatively difficult. Finally, although molecular biological detection of *RUNX2* mutations is accurate, only 70% patients were found to have point mutations, 13% had large/contiguous deletions, and the other 17% of patients had unknown mutations [20]. Thus, although the clinical characteristics of CCD are present since birth, the final diagnosis occurs much later, as in the case of the 15 patients in this study.

As increasing numbers of cases of CCD are reported, early diagnosis is becoming possible in patients with the typical clinical manifestations of CCD. If clavicular aplasia, non-closure of the fontanelles and supernumerary embedded teeth are found, the clinical diagnosis of CCD is straightforward, but requires a full understanding of this hereditary disease on the part of the clinician. If many retained deciduous teeth and supernumerary teeth are found on

intra-oral inspection, panoramic radiographs and a thorough family history should be taken to avoid misdiagnosis [21]. In addition, in CCD patients with typical manifestations, the first impression of CCD can be obtained by observing the characteristic facies. All of these can facilitate early diagnosis and help establish a good foundation for subsequent early intervention.

The treatment of the 15 patients in this study was prolonged (lasting for even 17 years in patient 15) and required co-operation between doctors from five departments, which fully illustrates the severe burden of restorative treatment. Therefore, early diagnosis and timely treatment are crucial in CCD. In addition, clinicians should improve the strategies for restorative treatment in order to improve the therapeutic outcomes and reduce the burden borne by the patients. Besides a multidisciplinary therapeutic approach, these patients also require a variety of diagnostic and treatment techniques such as cone-beam computed tomography [22], autogenous tooth transplantation and implant anchorage [23]. Early gene therapy to correct the mutation in the *RUNX2* gene may be the best solution, but the required technology needs to be greatly improved before it can be used clinically.

## Acknowledgments

We thank the patients and their families for their cooperation and enthusiastic support.

**Declaration of interest:** The authors report no conflicts of interest. The authors alone are responsible for the content and writing of the paper.

## References

- [1] McGuire TP, Gomes PP, Lam DK, Sandor GK. Cranioplasty for midline metopic suture defects in adults with cleidocranial dysplasia. *Oral Surg Oral Med Oral Pathol Oral Radiol Endod* 2007;103:175–9.
- [2] Farronato G, Maspero C, Farronato D, Gioventu S. Orthodontic treatment in a patient with cleidocranial dysostosis. *Angle Orthodontist* 2009;79:178–85.
- [3] Tokuc G, Boran P, Boran BO. Cleidocranial dysplasia in a mother and her daughter within the scope of neurosurgery. Report of two cases. *J Neurosurg* 2006;104:290–2.
- [4] Daskalogiannakis J, Piedade L, Lindholm TC, Sandor GK, Carmichael RP. Cleidocranial dysplasia: 2 generations of management. *J Can Dent Assoc* 2006;72:337–42.
- [5] Suba Z, Balaton G, Gyulai-Gaal S, Balaton P, Barabas J, Tarjan I. Cleidocranial dysplasia: diagnostic criteria and combined treatment. *J Craniofac Surg* 2005;16:1122–6.
- [6] Jensen BL, Kreiborg S. Dental treatment strategies in cleidocranial dysplasia. *Br Dent J* 1992;172:243–7.
- [7] Angle AD, Rebellato J. Dental team management for a patient with cleidocranial dysostosis. *Am J Orthod Dentofacial Orthop* 2005;128:110–17.
- [8] Becker A, Shteyer A, Bimstein E, Lustmann J. Cleidocranial dysplasia: Part 2—Treatment protocol for the orthodontic and surgical modality. *Am J Orthod Dentofacial Orthop* 1997;111:173–83.
- [9] Becker A, Lustmann J, Shteyer A. Cleidocranial dysplasia: Part 1—General principles of the orthodontic and surgical treatment modality. *Am J Orthod Dentofacial Orthop* 1997;111:28–33.
- [10] Berg RW, Kurtz KS, Watanabe I, Lambrakos A. Interim prosthetic phase of multidisciplinary management of cleidocranial dysplasia: "the Bronx Approach". *J Prosthodont* 2011;20:S20–5.
- [11] Mundlos S. Cleidocranial dysplasia: clinical and molecular genetics. *J Med Genet* 1999;36:177–82.
- [12] Xuan D, Li S, Zhang X, Hu F, Lin L, Wang C, et al. Mutations in the RUNX2 gene in Chinese patients with cleidocranial dysplasia. *Ann Clin Lab Sci* 2008;38:15–24.
- [13] Helm S, Petersen PE. Causal relation between malocclusion and periodontal health. *Acta Odontol Scand* 1989;47:223–8.
- [14] Stahl F, Grabowski R. Malocclusion and caries prevalence: is there a connection in the primary and mixed dentitions? *Clin Oral Investig* 2004;8:86–90.
- [15] Olszewska A. Dental treatment strategies in a 40-year-old patient with cleidocranial dysplasia. *J Appl Genet* 2006;47:199–201.
- [16] Jarvis JL, Keats TE. Cleidocranial dysostosis. A review of 40 new cases. *Am J Roentgenol Radium Ther Nucl Med* 1974;121:5–16.
- [17] Jensen BL, Kreiborg S. Development of the dentition in cleidocranial dysplasia. *J Oral Pathol Med* 1990;19:89–93.
- [18] Kreiborg S, Jensen BL, Bjork A, Skieller V. Abnormalities of the cranial base in cleidocranial dysostosis. *Am J Orthod* 1981;79:549–57.
- [19] Jarvinen S. Cephalometric findings in three cases of cleidocranial dysostosis. *Am J Orthod* 1981;79:184–91.
- [20] Lee MT, Tsai AC, Chou CH, Sun FM, Huang LC, Yen P, et al. Intragenic microdeletion of RUNX2 is a novel mechanism for cleidocranial dysplasia. *Genomic Med* 2008;2:45–9.
- [21] Quack I, Vonderstrass B, Stock M, Aylsworth AS, Becker A, Brueton L, et al. Mutation analysis of core binding factor A1 in patients with cleidocranial dysplasia. *Am J Hum Genet* 1999;65:1268–78.
- [22] Dalessandri D, Laffranchi L, Tonni I, Zotti F, Piancino MG, Paganelli C, et al. Advantages of cone beam computed tomography (CBCT) in the orthodontic treatment planning of cleidocranial dysplasia patients: a case report. *Head Face Med* 2011;7:6.
- [23] Kuroda S, Yanagita T, Kyung HM, Takano-Yamamoto T. Titanium screw anchorage for traction of many impacted teeth in a patient with cleidocranial dysplasia. *Am J Orthod Dentofacial Orthop* 2007;131:666–9.