

ORIGINAL ARTICLE

Diagnosing the severity of buccal caries lesions in orthodontic patients at de-bonding using digital photographs

NAIF A. ALMOSA,^{1,2} TED LUNDGREN³, ANDREA BRESIN¹, DOWEN BIRKHED⁴ & HEIDRUN KJELLBERG¹

¹Department of Orthodontics, Institute of Odontology, The Sahlgrenska Academy, University of Gothenburg, Göteborg, Sweden, ²Department of Pediatric Dentistry and Orthodontics, College of Dentistry, King Saud University, Saudi Arabia, ³Department of Pedodontics, and ⁴Department of Cariology, Institute of Odontology, The Sahlgrenska Academy, University of Gothenburg, Göteborg, Sweden

Abstract

Objective. The aims of this study were (1) to evaluate the severity of buccal caries lesions according to the International Caries Detection and Assessment System (ICDAS) criteria via scoring buccal caries lesions on digital photographs at the time of de-bonding and (2) to compare this method with clinical examination. **Materials and methods.** In total, 89 patients treated with upper and lower fixed appliances were clinically examined immediately after de-bonding by the first author and buccal caries were scored according to the ICDAS-II. Close-up digital photographs were taken of 245 teeth with different buccal caries lesion scores according to the ICDAS-II. Thirteen postgraduate orthodontics students independently scored the buccal caries lesions in the digital photographs using the modified clinical criteria (ICDAS-II). Intra- and inter-examiner reliabilities were evaluated by calculating the weighted kappa. To evaluate the validity of diagnosing the severity of buccal caries lesions using digital photographs compared to clinical examination, Spearman's correlation coefficient was calculated. **Results.** Intra-examiner reliability and the reliability between each examiner and the clinical examination showed moderate-to-excellent agreement, with kappa values of 0.52–0.83. Scoring buccal caries lesions via clinical examinations and scoring via photographs were well correlated according to the modified ICDAS-II criteria (Spearman's correlation coefficient, 0.76). **Conclusions.** Thus, scoring buccal caries lesions on digital photographs according to ICDAS-II criteria is a reliable and valid method for assessing the severity of buccal caries lesions.

Key Words: de-bonding, human, ICDAS, reliability, white spot lesions

Introduction

Enamel decalcification is a major clinical problem in treatment with fixed orthodontic appliances [1]. Although the prevalence of white spot lesions (WSLs) varies widely, it is disturbingly high [2]. The causes of this variation include different examination methods, local environmental factors such as fluoride administration during treatment and the inclusion or exclusion of developmental enamel lesions [3].

Orthodontic patients are more susceptible to the development of WSLs than untreated patients due to the presence of brackets, bands and arch-wires, which hamper oral hygiene measures and increase plaque-retention sites [4,5]. Such initial enamel

decalcifications can be observed as early as 4 weeks after applying a fixed orthodontic appliance [6]. For the clinician, it is important to detect these lesions in the early phases of orthodontic treatment to avoid further breakdown. Photographs are typically taken before, during and after orthodontic treatment and might be a helpful tool for detecting the progression of WSLs during treatment.

Clinical detection of WSLs is primarily performed using traditional methods, such as visual inspection after air drying and tactile examination by dental probing. However, due to a lack of reproducibility and because only significantly advanced lesions can be detected using this method, several optical devices have been introduced over the past several

decades [7,8]. The International Caries Detection and Assessment System (ICDAS) is a visual classification system that was developed in 2003 to allow standardized data collection with respect to caries lesions [9]. Later, the criteria were modified and the ICDAS-II, which uses a 7-point scoring system to describe the extent of caries lesions, was introduced [10]. Further, measurements of WSLs using different image processing techniques and digitally converted photographs were suggested and various researchers have confirmed the reproducibility and reliability of these methods [11–14]. Comparing polarized vs non-polarized photographs showed that the use of a cross-polarizing filter decreases the accompanying flash reflection on digital images, thereby improving the subjective assessment of demineralized lesions surrounding an orthodontic bracket and enhancing the reproducibility of demineralization area measurements [15].

To our knowledge, researchers have never attempted to diagnose the severity of buccal caries according to the ICDAS-II criteria using visual examination of photographs and have not compared this method with the clinical examination of buccal caries using the same criteria. Thus, the objectives of our study were to (1) evaluate the severity of buccal caries lesions according to the ICDAS-II criteria via scoring buccal caries lesions on digital photographs at the time of fixed orthodontic appliance removal and (2) compare this method with clinical examination. The null hypothesis is that visual examination for assessing the severity of buccal caries lesions on digital photographs is not a reliable and valid method.

Materials and methods

Sample and photographic technique

Photographs were selected from 10 close-up photographs taken for each of 89 patients representing buccal caries lesions with different scores according to the clinical examination criteria (ICDAS-II) (Figure 1). A power analysis was performed to estimate the sample size of photographs. To achieve an accuracy of $80 \pm 5\%$ for detecting different buccal caries lesion scores on digital photographs according to the modified ICDAS-II criteria, a minimum of 245 photographs was required. Photographs including environmental and developmental alterations, such as enamel hypoplasia, fluorosis and stains on the teeth, were excluded.

All patients were free of any caries lesions before receiving orthodontic treatment. The teeth were examined at the time of de-bonding after orthodontic treatment with upper and lower fixed appliances [16]. Immediately after de-bonding and removal of the remaining resin, the teeth were cleaned using a

rubber cup and pumice paste to remove plaque and extrinsic stains. Subsequently, the facial surfaces were dried and clinical registration of buccal caries scores was performed according to the ICDAS-II. The first author (N.A.) performed all the clinical registrations.

Close-up digital photographs were then taken using a digital camera (Nikon D60, Nikon corporation, Japan) with a macro objective lens (105 mm F2.8 DG macro, SIGMA, Japan), a ring flash (EM-140DG, SIGMA, Japan) and a polarizing filter. Additionally, a cross-polarizing technique was applied [15]. The image quality of the camera was set to 'fine' and the ISO sensitivity was set to 200. All images were saved as Joint Photographic Experts Group (JPEG) files. Standardized digital photographs were taken perpendicular to the facial surfaces of the anterior and premolar teeth. A constant distance was always maintained between the tooth surface and the lens by locking the lens and moving the camera until focus was achieved.

Examination of digital photographs

Thirteen postgraduate students with at least 2 years of experience as general practitioners from the Specialist Clinic of Orthodontics, Public Dental Service, Västra Götaland, University Clinics, Odontologen, Gothenburg, Sweden, participated independently in the evaluation of buccal caries lesions in 245 digital photographs using the modified clinical criteria (ICDAS-II). In the original ICDAS-II criteria, the only difference between scores 1 and 2 is whether the tooth is dry or wet and all photographs in this study were taken when the teeth were dry. Thus, scores 1 and 2 were merged and a modified ICDAS-II was used (Figure 1). These 245 photographs were given different scores according to the modified ICDAS-II, where scores 0, 1, 2, 3, 4 and 5 were represented in 40.0%, 30.6%, 12.2%, 12.2%, 4.6% and 0.4% of the photographs, respectively. The photographs were cropped to equal sizes and shown to the 13 examiners in a random order.

A standard protocol was used for evaluating colour digital photographs (showing one tooth/photograph) by applying modified ICDAS-II scores. Calibrated screens in a dark room were used and all observers performed the scoring early in the morning. A lecture was presented before the scoring was performed for calibration purposes and a manual with explanations of the modified ICDAS-II scores combined with a chart was given to each examiner (Figure 2). The examiners were instructed to record the worst score if there were more than two different scores on the same photograph and to record only what they observed, regardless of the number of photographs with the same scores.







| | | |
|--|--|--|
|  |  |  |
| <p>0. Sound tooth surface: there should be no evidence of caries or WSL. staining will be recored as sound.</p> | <p>1. White discoloration without cavitation or shadowing from dentin.</p> | <p>2. Localized enamel breakdown with no visible dentin. there is carious loss of surface integrity without visible dentin.</p> |
|  |  |  |
| <p>3. Underlying dark shadow from dentin with or without localized enamel breakdown. this lesion appears as a shadow of discolored dentin visible through the enamel surface beyond the white or brown spot lesion, which may or may not show signs of localized breakdown. this appearance is a darkening and intrinsic shadow, which may be grey, blue or brown in color.</p> | <p>4. Distinct cavity with visible dentin. cavitation in opaque or discolored enamel exposing the dentin beneath.</p> | <p>5. Extensive distinct cavity with visible dentin. an extensive cavity involves at least half of a tooth surface or possibly reaching the pulp.</p> |

Figure 1. The Modified International Caries Detection and Assessment System (Modified ICDAS-II). All photos were taken by the main author (N.A).

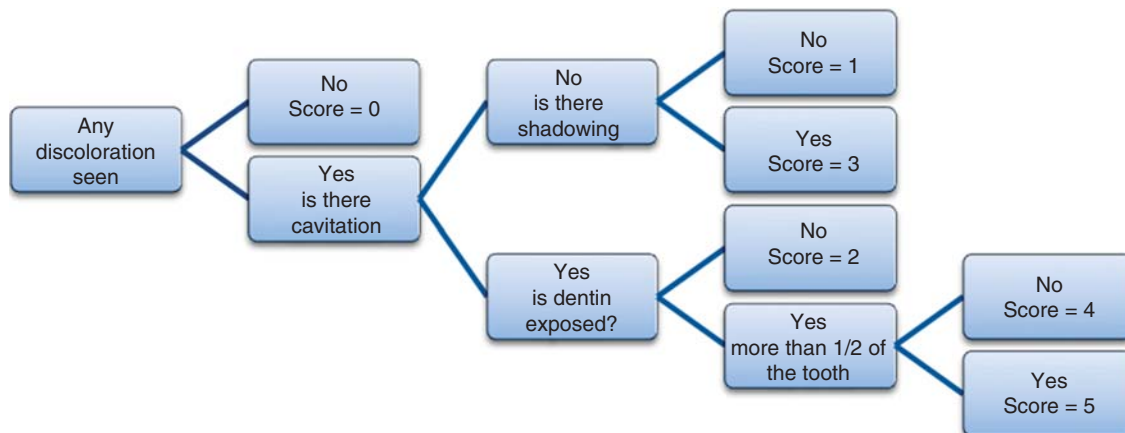


Figure 2. Decision chart for different scores of buccal surface caries.

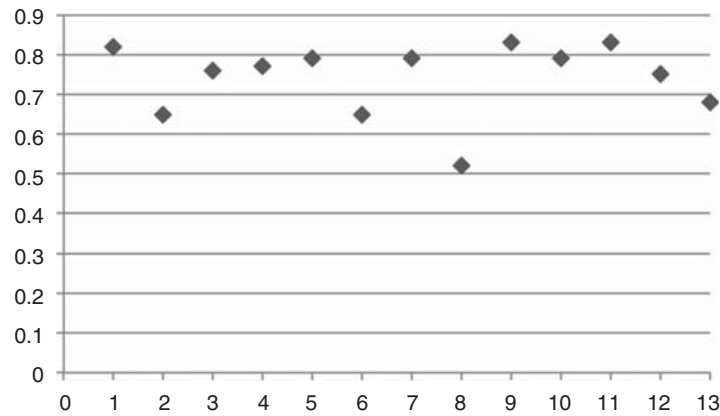


Figure 3. Weighted Kappa values of the intra-examiner reliability for 13 examiners.

To evaluate the intra-examiner reliability, photographs of buccal caries lesions were examined in two sessions with an interval of 2 weeks between the sessions. The reliability for each examiner's observations of photographs and the clinical examination was calculated. To evaluate the validity of diagnosing the severity of buccal caries lesions using digital photographs, the clinical examination was considered as the gold standard. In a previous evaluation, the first author (N.A) showed excellent intra-examiner and inter-examiner reliability with another co-author in the clinical examination using the ICDAS-II criteria, with kappa values of 0.88 and 0.87, respectively [17].

Statistical analysis

All data were analysed using the Statistical Package for the Social Sciences (SPSS), version 20 (IBM, SPSS, Statistics, Chicago). The weighted kappa values were calculated to evaluate the intra-examiner reliability and the reliability between each examiner and the clinical examination. Cross-tabulation was applied to evaluate the correlation between clinical examination of buccal caries lesions and examination of digital photographs of the lesions using the ICDAS-II criteria by calculating Spearman's correlation coefficient.

Results

A total of 6370 observations (3185 in each session) were performed to examine 245 photographs for the presence of buccal caries lesions using the modified ICDAS-II criteria. Figure 3 shows the intra-examiner reliability: The kappa value ranged between 0.52–0.83. When registering the different buccal caries lesion scores on digital photographs according to the modified ICDAS-II criteria, one examiner showed a kappa value of 0.52 (i.e. moderate agreement), whereas the remaining 12 examiners showed kappa values between 0.65–0.83, which represent substantial-to-excellent agreement [18].

To evaluate the reliability between each examiner and the clinical examinations, the first session of scoring using digital photographs was considered. Figure 4 shows the reliability between each examiner and the clinical examinations (gold standard); the kappa value ranged between 0.52–0.80. Only two examiners showed agreement below 65%, whereas the remaining 11 examiners showed agreement between 65–80%, which is classified as being substantial to almost perfect agreement according to Landis and Koch [18].

To study the correlation between the clinical examinations and visual scores using photographs of buccal caries lesions according to the modified ICDAS-II

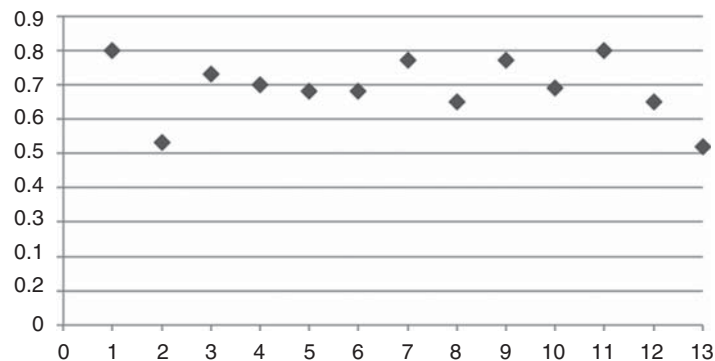


Figure 4. Weighted Kappa values of the reliability between each one of the 13 examiners' observations on photographs and the clinical examination, i.e. the golden standard.

Table I. The cross-tabulation between clinical registration and observations on photographs using modified ICDAS-II, from which Spearman's correlation coefficient was calculated to be 0.76. The correlation is a column percentage to evaluate the agreement of the registration on photographs toward the clinical registration and not vice versa.

| | Score | Clinical registration | | | | | Total | |
|-------------|-------|-----------------------|-----|-----|-----|-----|-------|------|
| | | 0 | 1 | 2 | 3 | 4 | | 5 |
| Photographs | 0 | 1013 | 60 | 32 | 26 | 0 | 0 | 1131 |
| | 1 | 196 | 776 | 128 | 94 | 0 | 0 | 1194 |
| | 2 | 44 | 41 | 145 | 56 | 3 | 0 | 289 |
| | 3 | 21 | 97 | 68 | 191 | 4 | 0 | 381 |
| | 4 | 0 | 1 | 16 | 22 | 135 | 0 | 174 |
| | 5 | 0 | 0 | 1 | 1 | 1 | 13 | 16 |
| | Total | 1274 | 975 | 390 | 390 | 143 | 13 | 3185 |

criteria, the first observations of all examiners were merged and compared to the clinical examination using cross-tabulation (Table I), from which Spearman's correlation coefficient was calculated to be 0.76. The correlation was based on the agreement of the registration on photographs toward the clinical registration, but not vice versa. There was 79.5% agreement between the scoring on digital photographs and the clinical examination with respect to evaluation of healthy teeth as well as teeth with white discoloration without cavitation or shadowing from dentin (scores of 0 and 1). Moreover, this agreement increased when evaluating scores of 4 and 5 (94.4% and 100% agreement, respectively). However, the agreement between the scoring on digital photographs and the clinical examination decreased for scores of 2 and 3, with 37.2% and 49.0% agreement, respectively.

To evaluate whether the teeth were healthy or had lesions regardless of the severity, scores of 1–5 were merged. Using the merged scores, there was a 93.8% chance of detecting buccal caries lesions on photographs compared to the clinical examination (Table II) and Spearman's correlation coefficient was calculated to be 0.76.

Discussion

This study revealed that scoring buccal caries lesions on digital photographs according to ICDAS criteria is

Table II. The cross-tabulation between clinical examination and observations on photographs using modified ICDAS-II to detect whether teeth are healthy or affected by lesion, regardless of the severity of the lesion.

| | Lesions | Clinical registration | | Total |
|-------------|---------|-----------------------|--------------|-------|
| | | No | Yes | |
| Photographs | No | 1013 (79.5%) | 118 (6.2%) | 1131 |
| | Yes | 261 (20.5%) | 1793 (93.8%) | 2054 |
| | Total | 1274 | 1911 | 3185 |

a reliable and valid method for detecting the severity of buccal caries lesions. In this study, special camera settings were applied that might not be the routine procedure when photographs are taken for orthodontic patients; however, the conventional intra-oral photographs taken for orthodontic patients may still be useful for evaluating the incidence and extent of WSLs [19].

The fact that the photographs in our study were taken after de-bonding may facilitate visual examination of the photographs; however, a previous study showed that the presence of brackets did not affect the examination of WSLs on photographs [14]. In addition, the photographs in the current study were taken perpendicular to the facial surfaces because the reliability for measuring WSLs on photographs taken at a 90° angle was found to be better compared with photographs taken at >20° perpendicular to the buccal surface [11,14]. Thirteen calibrated screens were used to ensure that the examiners utilize exactly the same measurements to standardize the method for direct visual examination of photographs. The first session of photograph scoring was utilized for comparison with the clinical examinations; the second session was performed to evaluate the intra-examiner reliability. The second scoring session showed slight improvement with respect to correlation with the clinical examination, with an increase in Spearman's correlation coefficient from 0.76–0.79. This result is to be expected due to the training effect.

The data presented in this study showed very good intra-examiner reliability for visual examination of buccal caries lesions on digital photographs according to the modified ICDAS-II criteria. The majority of the 13 independent examiners showed more than 75% agreement (Figure 3). These findings are in agreement with those of Enaia et al. [20], who showed that intra-examiner reliability ranged between 48–95%. However, Enaia et al. evaluated WSLs using different criteria, and only three independent examiners were involved. According to Landis and Koch [18], intra-examiner

agreement of 41–60% represents moderate agreement, 61–80% represents substantial agreement and greater than 80% represents nearly perfect intra-examiner agreement. Several studies [11–14] have investigated the intra-examiner reliability based on different image-processing software techniques, showing agreement between 81–98%. However, these findings do not apply to our current investigation, which was based on the visual examination of digital photographs.

The present study showed moderate-to-excellent reliability [18] for the scoring of buccal caries on digital photographs for each examiner compared with clinical examinations. These findings are in agreement with those of Chapman et al. [19], who showed excellent agreement between direct clinical examination and visual examination on photographs, with an intra-class correlation coefficient of 0.88. Nevertheless, Chapman et al. did not consider the severity of WSLs, only one examiner investigated the WSLs and the sample included the anterior teeth of only 10 patients.

The current investigation demonstrated good agreement between visual examination of digital photographs and clinical examination of healthy teeth, teeth with white discoloration without cavitation or underlying shadowing and teeth with distinct cavitation with visible dentin (i.e. modified ICDAS-II scores 0, 1, 4 and 5; Figure 1), likely because the detection of sound teeth and teeth with exposed dentin is simple. In addition, the 100% agreement for score 5 lesions may have occurred because this score indicates an obvious lesion in which more than half of the tooth is decayed. However, only one tooth was clinically scored as 5, implying that there was only one photograph in that category.

We found that 10% of score 1 lesions examined clinically were given score 3 on the photographs and that 24% of score 3 lesions examined clinically were given score 1 on the photographs. However, neither of these lesions show cavitation, and most score 3 lesions are accompanied by score 1 lesions. Nonetheless, the examiners were instructed to register the worst score during photograph scoring. The data in this study showed relatively low agreement between clinical examination and photographic scoring with respect to score 2 lesions. However, score 2 lesions show enamel breakdown, which is easier to detect clinically using the dental explorer. Overall, we believe that diagnosing the severity of buccal caries lesions on digital photographs is a valuable diagnostic tool for evaluating the progression of WSLs during orthodontic treatment; further histological studies are needed to confirm this finding.

Conclusion

The null hypothesis was rejected. Scoring buccal caries lesions on digital photographs according to

ICDAS-II criteria is a reliable and valid method for assessing the severity of buccal caries lesions.

Acknowledgements

The authors would like to express their thanks to Dr Tommy Johnsson for his statistical assistance. This study was a part of project supported by a scholarship from the Saudi Ministry of Higher Education.

Declaration of interest: The authors report no conflicts of interest. The authors alone are responsible for the content and writing of the paper.

References

- [1] Øgaard B. White spot lesions during orthodontic treatment: mechanisms and fluoride preventive aspects. *Semin Orthod* 2008;14:183–93.
- [2] Willmot D. White spot lesions: formation, prevention, and treatment. *Semin Orthod* 2008;14:174–82.
- [3] Downer MC, Blinkhorn AS, Holt RD, Wight C, Attwood D. Dental caries experience and defects of dental enamel among 12-year-old children in north London, Edinburgh, Glasgow and Dublin. *Community Dent Oral Epidemiol* 1994;22:283–5.
- [4] Gorelick L, Geiger AM, Gwinnett AJ. Incidence of white spot formation after bonding and banding. *Am J Orthod* 1982;81:93–8.
- [5] Øgaard B. Prevalence of white spot lesions in 19-year-olds: a study on untreated and orthodontically treated persons 5 years after treatment. *Am J Orthod Dentofacial Orthop* 1989;96:423–7.
- [6] Øgaard B, Rølla G, Arends J. Orthodontic appliances and enamel demineralization. Part 1. Lesion development. *Am J Orthod Dentofacial Orthop* 1988;94:68–73.
- [7] ten Bosch JJ, Borsboom PC, ten Cate JM. A nondestructive method for monitoring de- and remineralization of enamel. *Caries Res* 1980;14:90–5.
- [8] de Josselin de Jong E, Sundstrom F, Westerling H, Traanaeus S, ten Bosch JJ, Angmar-Månsson B. A new method for in vivo quantification of changes in initial enamel caries with laser fluorescence. *Caries Res* 1995;29:2–7.
- [9] Pitts N. “ICDAS” – an international system for caries detection and assessment being developed to facilitate caries epidemiology, research and appropriate clinical management. *Community Dent Health* 2004;21:193–8.
- [10] Ismail AI, Sohn W, Tellez M, Amaya A, Sen A, Hasson H, et al. The International Caries Detection and Assessment System (ICDAS): an integrated system for measuring dental caries. *Community Dent Oral Epidemiol* 2007;35:170–8.
- [11] Benson PE, Pender N, Higham SM. Enamel demineralisation assessed by computerised image analysis of clinical photographs. *J Dent* 2000;28:319–26.
- [12] Willmot DR, Benson PE, Pender N, Brook AH. Reproducibility of quantitative measurement of white enamel demineralisation by image analysis. *Caries Res* 2000;34:175–81.
- [13] Benson PE, Pender N, Higham SM. Quantifying enamel demineralization from teeth with orthodontic brackets – a comparison of two methods. Part 1: repeatability and agreement. *Eur J Orthod* 2003;25:149–58.
- [14] Livas C, Kuijpers-Jagtman AM, Bronkhorst E, Derks A, Katsaros C. Quantification of white spot lesions around orthodontic brackets with image analysis. *Angle Orthod* 2008;78:585–90.

- [15] Benson PE, Ali Shah A, Robert Willmot D. Polarized versus nonpolarized digital images for the measurement of demineralization surrounding orthodontic brackets. *Angle Orthod* 2008;78:288–93.
- [16] Almosa NA, Al-Mulla AH, Birkhed D. Caries risk profile using the Cariogram in governmental and private orthodontic patients at de-bonding. *Angle Orthod* 2012;82:267–74.
- [17] Almosa NA, Lundgren T, Aldrees AM, Birkhed D, Kjellberg H. Diagnosing the severity of buccal caries lesions in governmental and private orthodontic patients at debonding, using the ICDAS-II and the DIAGNOdent Pen. *Angle Orthod* 2013;
- [18] Landis JR, Koch GG. The measurement of observer agreement for categorical data. *Biometrics* 1977;33: 159–74.
- [19] Chapman JA, Roberts WE, Eckert GJ, Kula KS, Gonzalez-Cabezas C. Risk factors for incidence and severity of white spot lesions during treatment with fixed orthodontic appliances. *Am J Orthod Dentofacial Orthop* 2010;138: 188–94.
- [20] Enaia M, Bock N, Ruf S. White-spot lesions during multibracket appliance treatment: a challenge for clinical excellence. *Am J Orthod Dentofacial Orthop* 2011;140: e17–24.