

Analysis of tooth marks in a homicide case

Observations by means of visual description, stereo-photography, scanning electron microscopy and stereometric graphic plotting

GISLE BANG

The Gade Institute, Department of Pathology, University of Bergen, Norway

Bang, G. Analysis of tooth marks in a homicide case. Observations by means of visual description, stereophotography, scanning electron microscopy and stereometric graphic plotting. *Acta Odont. Scand.* 34, 1—11, 1976.

In 1957 a woman was murdered in Oslo. Her left breast exhibited tooth marks. A man was arrested and sentenced to life imprisonment partly because of the dental evidence. He never admitted guilt and filed a petition for retrial. The present author was appointed as new dental expert. The material consisted of the fixed breast, models of the bite mark and models of the teeth of the convict, and several photographs. By means of visual examination, a magnifying glass, a lens stereoscope and a stereomicroscope characteristic details were noted. Stereoscopic picture pairs were taken, the material was studied by means of scanning electron microscopy and a stereometric-graphic plotting method permitting the outline of the tooth mark or the biting edge of a tooth to be registered in great detail in all three dimensions in the form of a contour map. This method has not previously been applied in the analysis of tooth marks in human skin. These examinations revealed no discrepancies but showed many corresponding characteristic features between the tooth marks and the teeth of the convict, resulting in the conclusion that it is highly probable that the tooth marks in the breast were made by the teeth of the convict.

Key-words: Forensic dentistry; homicide

Gisle Bang, Gades Institutt, 5000 Bergen, Norway

In the literature, many case reports, experimental investigations and textbook chapters have dealt with the analysis of tooth marks (*Sorup*, 1924; *Buhtz & Erhardt*, 1938; *Morgen*, 1943; *Korkhaus*, 1955; *Sebata*, 1963; *Strøm*, 1963a, *Gustafsson*, 1966, *Camps*, 1968; *Furness*, 1968; *Cameron & Sims*, 1974; *Ruddick*, 1974) and with various methods of comparison and evaluation. No one particular technique has proved to be adequate in every case and obviously a great deal of further work in this important field within forensic odontology is needed.

In the present case a detailed description of the tooth marks on the victim and the incisal edges of the front teeth of the suspect, as well as stereomicroscopy, scanning electron microscopy and stereometric-graphic plotting have been carried out.

Case report

The actual case dates back to December of 1957 when a young woman was found murdered in the entrance of a cellar in an old apartment house in Oslo. She had been seen alive about 2½ hours previously.

Her left breast exhibited several tooth marks, Fig. 1.*

A young man was arrested and held as a suspect. The two expert witnesses appointed to examine the bite mark and the teeth of the suspect both concluded that it was highly probable that the tooth marks in the breast were caused by the teeth of the suspect. One of the two even stated: »From a scientific point of view it is highly probable that the bite marks in the breast of R.J. are made by the suspect F.T. Based on my own experience, well aware of my responsibility, I consider the bite marks left in the breast of R.J. as produced by teeth which are identical with the teeth of the suspect F.T.».

The suspect was sentenced to life imprisonment for attempted rape, premeditated murder and arson.

The case was appealed and tried in the Supreme court in 1957, but the verdict was upheld. A detailed description of this case has been given by *Strøm* (1963b). The man has never admitted guilt. After 16 years of imprisonment he was recently released from jail and he has now filed petition for a retrial. Before reaching a decision on this point the court wanted the tooth marks reexamined and the present author was appointed as a dental expert.

MATERIAL AND METHODS

The following material was available from the examinations in 1957: the breast with the tooth marks fixed in Kaiserlings solution (*Romeis*, 1948), an impression of the

tooth marks in plaster of Paris and models of the convict's teeth in plaster of Paris. A series of photographs: from the scene of the crime, of the breast with the tooth marks, of the plaster cast of the tooth marks and of the plaster casts of the convict's teeth, were also available.

For the present investigation a number of new impressions were taken of the tooth marks in the breast, of the plaster cast of the tooth marks and of the plaster casts of the convict's teeth using elastomeric impression materials (Silopren® K1, Xantopren® blue and Optosil®). From these impressions models were produced in Xantopren blue and hard plaster of Paris (vel-Mix Stone, Kerr). This material served as working models. By means of visual examination, a magnifying glass ($\times 4.5$), a lens stereoscope and a stereomicroscope (Zeiss 4), characteristic details of the tooth marks and the incisal edges of the front teeth of the convict were noted.

Casts of the incisal edges of the convict's teeth and of the tooth marks were mounted to correspond to each other, and stereoscopic picture pairs were taken (Zeiss 4 stereomicroscope equipped with a sliding photo tube).

Prior to examination in the scanning electron microscope the casts were glued on aluminum stubs and coated with a thin conductive film of gold (approximately 300–400Å). The three-dimensional topography of the surface of the casts was studied in a Cambridge stereoscan S4 microscope operated at 10 to 20 kV.

The stereometric-graphic plotting was carried out in a photogrammetrical stereo-instrument, autograph A7 Wild. The method has been described in detail by *Torlegård*, 1966; *Frykholm, Victorin & Torlegård*, 1970 and *Jonason, Frykholm & Frykholm*, 1974.

* Each tooth mark is numbered according to the corresponding tooth and the teeth are designated according to the Two digit system adopted by the International Dental Federation (FDI), Appendix I, FDI Chronicle of the 58th Annual Session, 1970.

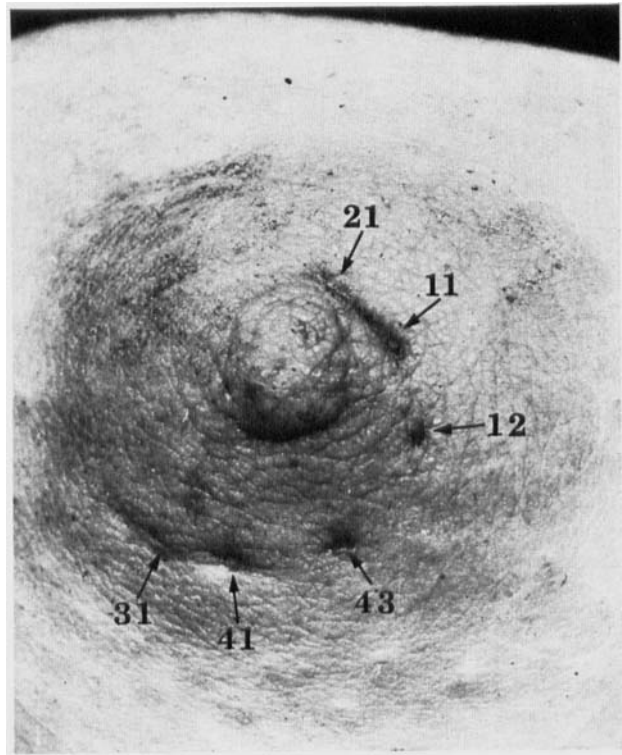


Fig. 1. Left breast with tooth marks. $\times 1.7$. See footnote page 2. (Courtesy of Dr. F. Strøm, Dental Faculty, University of Oslo, Norway).

RESULTS

1. Visual examination

a) The tooth marks in the breast.

Six tooth marks are clearly seen, Fig. 1. Two marks, 21 and 11, above the nipple, and two marks, 41 and 31, below the nipple, have a configuration compatible with being caused by human front teeth. The other two marks are not so characteristic and cannot be referred to particular teeth by visual examination alone. The following description is based on casts of the tooth marks, Figs. 2 and 3.

Tooth mark 21: It is localized at one o'clock in relation to the nipple. The mesio-distal width is relatively large and the mark has a distinct mesio-distal furrow towards the lingual side. Both the mark itself and the furrow are widest in the distal part.

Tooth mark 11: It is localized at two o'clock in relation to the nipple. The mesio-distal width is relatively large and a thin furrow is seen parallel with and close to the lingual side. The labial part is highest in the middle tapering down on both sides and most pronounced in the distal third.

Tooth mark 12: It is localized at four o'clock in relation to the nipple and has the form of a small non-characteristic elevation.

Tooth mark 43: It is localized at five to six o'clock in relation to the nipple and has the form of a small non-characteristic elevation.

Between tooth marks 43 and 41 a small platou-like elevation is seen mesially.

Tooth mark 41: It is localized at six to seven o'clock in relation to the nipple.

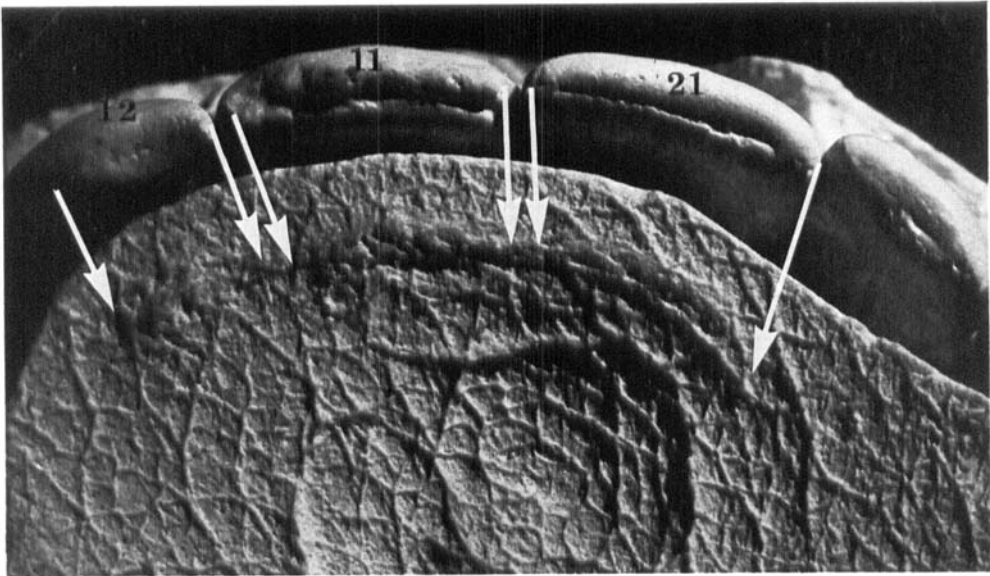


Fig. 2. Cast of the upper front teeth of the convict mounted to correspond (suggested by arrows) to cast of the tooth marks. $\times 4.8$.

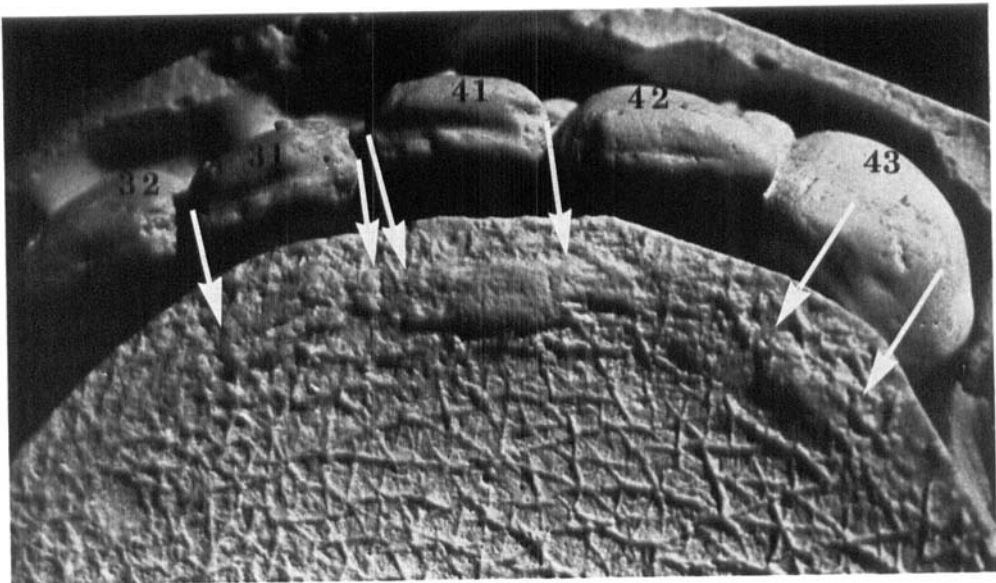


Fig. 3. Cast of the lower front teeth of the convict mounted to correspond (suggested by arrows) to cast of the tooth marks. $\times 4.8$.

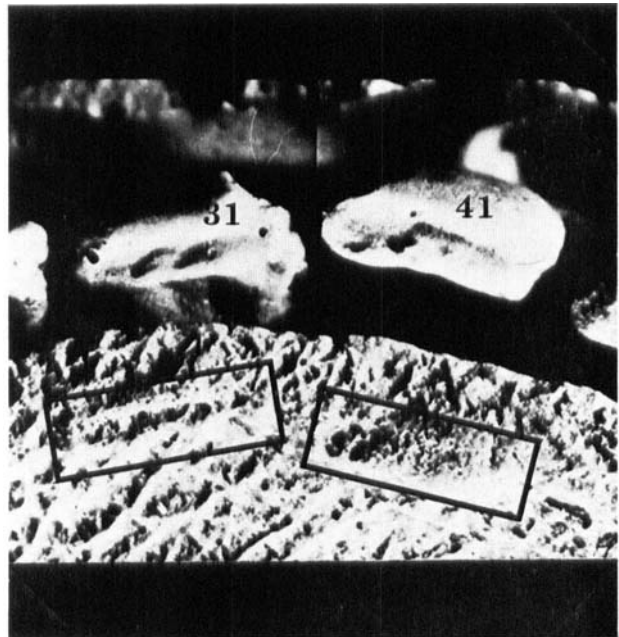


Fig. 4A. Cast of the lower central incisors of the convict mounted to correspond to cast of the tooth marks (framed areas). See Fig. 4B.

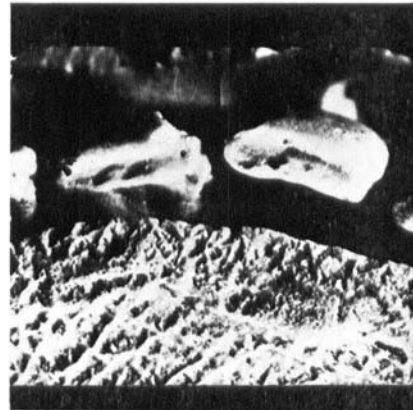
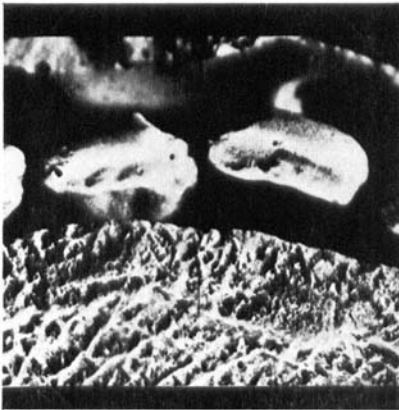

Fig. 4B. Stereoscopic picture pair mounted to be viewed in a lens stereoscope. For orientation see Fig. 4A.

The mesio-distal width is much less than that of marks 11 and 21, but the labio-lingual width is larger. A shallow medio-distal furrow with a small expansion mesially is present. Both the mesial and distal part of the mark is less pronounced than the middle part and the former is platou-like at a lower level than the rest of the mark.

Tooth mark 31: It is localized at seven to eight o'clock in relation to the nipple. The configuration is similar to mark 41. A shallow mesio-distal furrow is also seen and the mesial part of the mark is tapering downwards.

b) The teeth of the convict.

The front teeth exhibit partial edge to

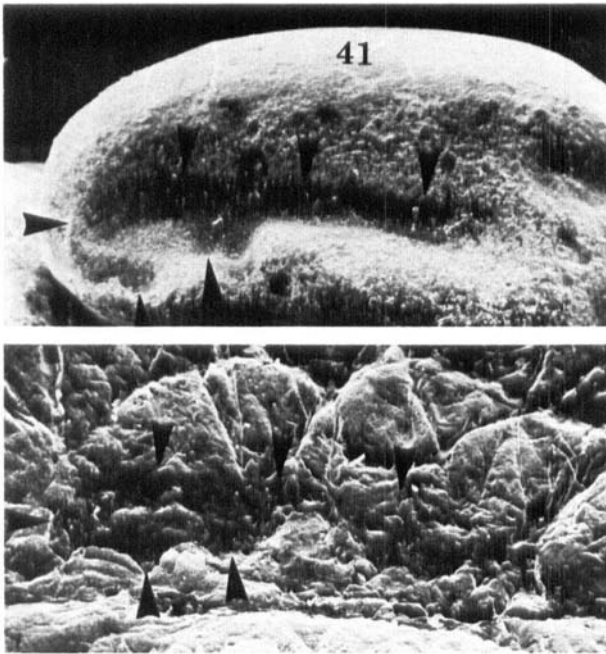


Fig. 5A. Scanning electron micrograph of the convict's right lower incisor (tooth 41) and a section of the bite mark, mounted to allow comparison. Areas to be viewed in Fig. 5B outlined by arrow heads. Approx. $\times 25$.

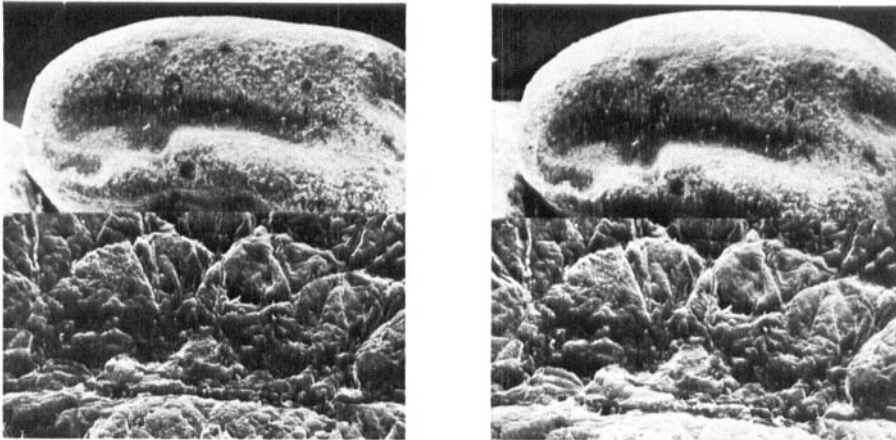


Fig. 5B. Stereoscopic scanning electron micrograph pair mounted to be viewed in a lens stereoscope. For orientation see Fig. 5A. Approx. $\times 20$.

edge bite and the incisal edges are markedly worn, Figs. 2 and 3.

Tooth 21: The incisal edge has a mesio-distal furrow towards the lingual side. The furrow is widest in the distal third.

Tooth 11: The incisal edge has a mesio-distal furrow towards the lingual side. The distal corner is fractured and the labial part is highest in the middle.

Tooth 12: The highest point of the incisal edge is located towards the distal part.

Tooth 43: The incisal edge is worn distally, so that the highest point is located in the mesial part.

Tooth 42: Slightly rotated with the distal corner labially. The highest part of the incisal edge is located mesially.

Tooth 41: The incisal edge has a furrow which is widest in the mesial part. The labial part of the incisal edge is higher than the lingual part. Both corners exhibit small fractures.

Tooth 31: The incisal edge has a mesio-distal furrow towards the lingual side. The labial part of the incisal edge is higher than the lingual part. The mesial corner is fractured.

The relatively large distance between marks 11 and 12 can be explained by the fact that the distal corner of tooth 11 is fractured and the highest point of the incisal edge of tooth 12 is located distally. Between marks 43 and 41 there is only a small elevation mesially indicating that the tooth has left a partial mark only. This is probably due to the slight rotation and inclination of the incisal edge of tooth 42.

A comparison based on the description made above brings about no discrepancies but shows a very good correlation between the teeth 21, 11, 41, 31 and the tooth marks 21, 11, 41, 31, respectively.

2. Stereoscopic examination

The stereometric pictures of the casts of the tooth marks and the incisal edges of the teeth mounted to correspond to each other showed good correlation in details, especially for the lower central incisors, Fig. 4B. For orientation see Fig. 4A.

3. Scanning electron microscopy

Scanning electron microscopy showed no discrepancies between the tooth marks and the teeth. On the contrary the characteristic configuration of the furrow in the incisal edge of the right lower incisor (tooth 41) was clearly reproduced in the scanning electron micrograph of the corresponding tooth mark, Fig. 5A. A

stereoscopic reproduction of this scanning electron micrograph, Fig. 5B, demonstrates the same correspondance.

4. Stereometric-graphic examination

The contour map of the breast with the tooth marks, produced by the stereometric method, is shown in Fig. 6. More detailed contour maps of the breast with the tooth marks and of the teeth in question in a larger scale are depicted in Figs. 7, 8, 9 and 10. There are many similarities in characteristic details both in the longitudinal and cross sections, Figs. 11 and 12. In addition to the marks already described, Fig. 1, configurations suggestive of tooth marks were seen in the areas 42, 32 and 33, Fig. 8.

5. Conclusion

Based on these results it is concluded that it is highly probable that the tooth marks in the breast are made by the teeth of the convict.

DISCUSSION

In the original hearing of this case, the bite mark evidence came to be considered of the utmost importance, since the whole case proved to rest on circumstantial evidence alone.

In the present examination the detailed visual descriptions revealed no discrepancies but showed many corresponding characteristic features between the central incisors of the convict and the tooth marks in the breast and resulted in the relatively strong conclusion.

Both the direct examination of the tooth marks in the breast and the incisal edges of the teeth in the casts by means of a lens stereoscope, as well as viewing the stereoscopic picture pairs, proved of great

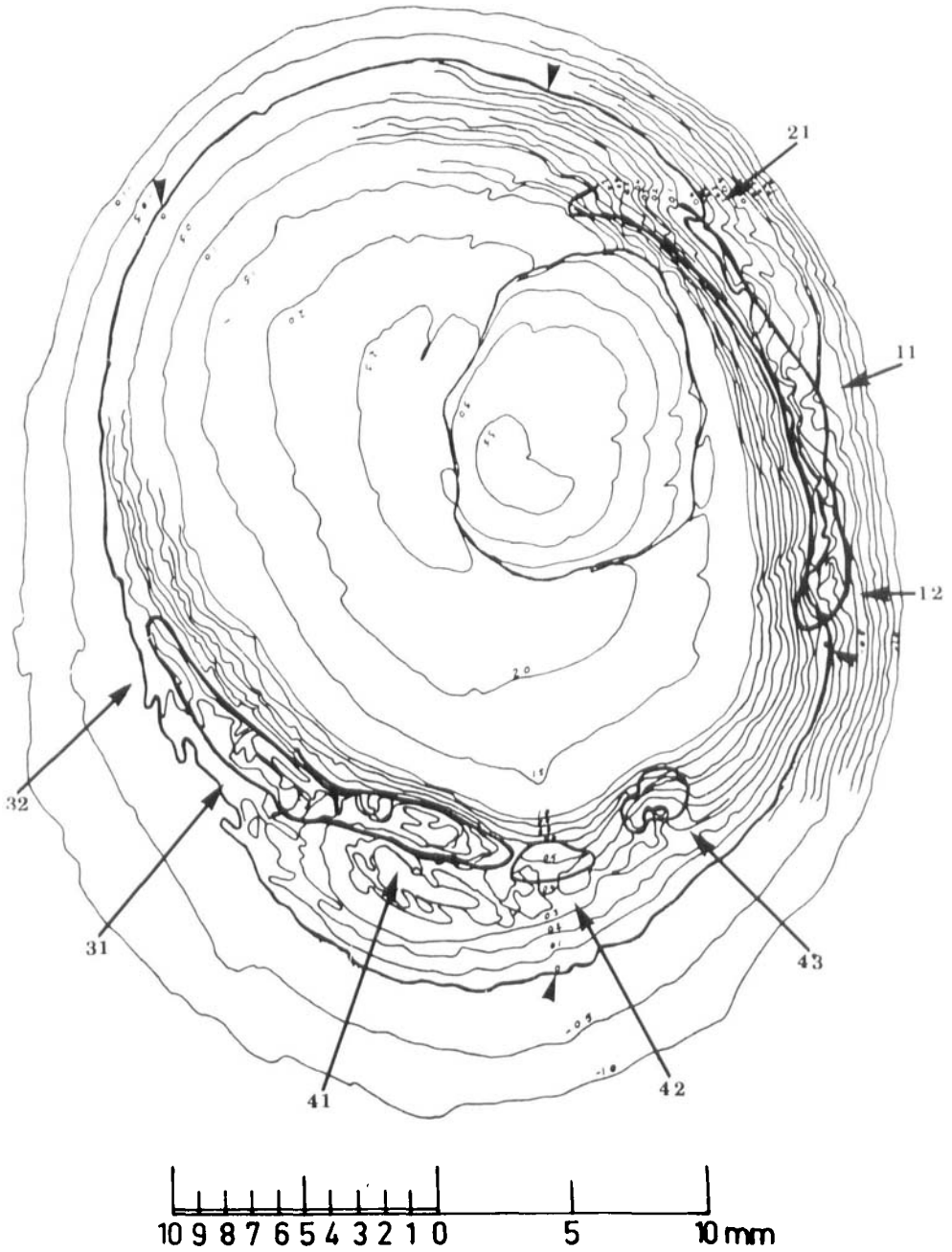


Fig. 6. Contour map of the breast with the tooth marks. Scale 5.7 : 1. Contour intervals are drawn at 0.1 mm or 0.5 mm. The zero-height plane is outlined by arrow heads. In addition to the marks seen in Fig. 1 configurations suggestive of tooth marks are outlined in areas 32 and 42.

Fig. 7. Contour map of the breast with the tooth marks caused by the upper central incisors and right lateral incisor. Scale 11.4 : 1. Contour intervals are drawn at 0.1 mm. Longitudinal sections, A1—E1 (tooth mark 12), A2—H2 (mark 11), A3—G3 (mark 21) and cross sections A, B, C etc. are outlined.

Fig. 8. Contour map of the breast with the tooth marks caused by the lower front teeth. Scale 11.4 : 1. Contour intervals are drawn at 0.1 mm. Longitudinal and cross sections similar to those shown in Fig. 7 are outlined. In addition to the marks seen in Fig. 1 configurations suggestive of tooth marks are seen in areas 32, 33 and 42.

Fig. 9. Reversed picture of the incisal edges of the upper front teeth in question. Scale 11.4 : 1. Longitudinal and cross sections corresponding to those outlined for the tooth marks, Fig. 7 are drawn.




Fig. 10. Reversed picture of the incisal edges of the lower front teeth in question. Scale 11.4 : 1. Longitudinal and cross sections corresponding to those outlined for the tooth marks, Fig. 8, are drawn.

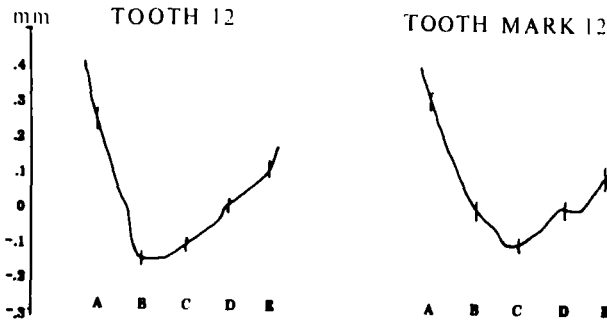


Fig. 11. The longitudinal sections for tooth 12, see Fig. 9, and tooth mark 12, see Fig. 7. In spite of the enlargement, approx. 50 : 1, there is good correlation between the corresponding profiles.

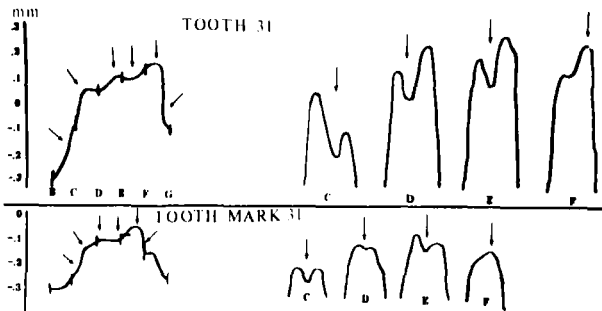


Fig. 12. Longitudinal (left) and cross sections (right) for tooth 31, see Fig. 10, and tooth mark 31, see Fig. 8. In spite of the enlargement, approx. 50 : 1, there is good correlation between the corresponding profiles.

value in visualizing small characteristic details.

The benefit of utilizing scanning electron microscopy in the examination of tooth marks is also demonstrated by the present case although it is felt that further studies along these lines are desirable.

Stereometric-graphic plotting has previously not been applied in the analysis of tooth marks in human skin. It is an objective method permitting the outline of a tooth mark or the biting edge of a tooth to be recorded in great detail in all three dimensions in the form of a contour map. It is felt, therefore, that this method will prove of great value in future cases involving the examination of tooth marks. As pointed out by *Frykholm, Wictorin & Torlegård* (1970), the determination of the position of the various reference points is of vital importance when longitudinal and cross-sections are to be drawn, consequently the investigator must be well trained and familiar with this technique. Also the method is time consuming and relatively expensive.

The evaluation of tooth marks is difficult and considerable caution is required when conclusions regarding such evidence are to be drawn in criminal cases. The value of the evidence is greatly enhanced if comparable results are obtained by using several different methods.

Acknowledgements. The valuable help and technical assistance of H. Dalen, P. Flood, K. O. Frykholm, C-O. Jonason, S. Keiser-Nielsen, I. Kranz and T. Solheim is greatly appreciated.

REFERENCES

- Buhtz & Erhardt*, 1938. Die Identifikation von Bisswunden. (Experimentelle Untersuchungen). Dtsch. Z. ges. gerichtl. Med. 29, 453—469
- Cameron, J. M. & Sims, B. G.* 1974. *Forensic Dentistry*. Churchill Livingstone, Edinburgh and London, pp 129—145
- Camps, F. E.* 1968. Identification by the teeth and jaws, and other aspects of forensic odontology. *Gradwohl's legal medicine*. Bristol: John Wright & Sons Ltd. pp 155—166
- Frykholm, K. O., Wictorin, L. & Torlegård, K.* 1970. Analysis of teeth-marks with stereometric reproduction. Svensk tandläk.-T. 63, 205—217
- Furness, J.* 1968. A new method for the identification of teeth marks in cases of assault and homicide. Brit. Dent. J. 124, 261—267
- Gustafson, G.* 1966. *Forensic odontology*. American Elsevier Publishing Company Inc. New York. pp 140—165
- Jonason, C-O., Frykholm, K. O. & Frykholm, A.* 1974. Three dimensional measurement of tooth impression of criminological investigation. Int. J. Forens. Dent. 2, 70—78
- Korkhaus, G.* 1955. Die Identifizierung von Bissspuren durch den Zahnarzt. Dtsch. Zahnärztl. Z. 10, 1769—1778
- Morgen, H.* 1943. Zahnärztl. Rdsch. 52, 791—796
- Romeis, B.* 1948. *Mikroskopische Technik*. Leibniz Verlag, München, p 200
- Ruddick, R. F.* 1974. A technique for recording bite marks for forensic studies. Med. Biol. III. 24, 128—129
- Sebata, M.* 1963. Medico-Legal studies on bite marks. The Bull. Tokyo Dent. Coll. 4, 83—98
- Ström, F.* 1963a. Investigation of bite marks. J. Dent. Res. 42, 312—316
- Ström, F.* 1963b. Identification by bite-marks — A murder case. Third International Meeting in Forensic Immunology, Medicine, Pathology and Toxicology. International Congress Series, No. 80. Amsterdam: Excerpta Medica Foundation
- Sørup, A.* 1924. Odontoskopie. Ein zahnärztlicher Beitrag zur gerichtlichen Medizin. Vischr. Zahnheilk. 40, 385—393
- Torlegård, K.* 1966. Rymdmärke ger noggranna mått. Teknisk Informasjon no. 10