

Denture stomatitis

Relapse tendency and removal of acquired discolourations in long-term denture disinfection with chlorhexidine

INGAR OLSEN

Department of Oral Surgery and Oral Medicine & Institute of Pharmacology, University of Oslo, Norway

Olsen, I. Denture stomatitis. Relapse tendency and removal of acquired discolourations in long-term denture disinfection with chlorhexidine. *Acta Odont. Scand.* 33, 111—114, 1975.

Five patients with denture stomatitis were initially treated for 14 days with a combination of amphotericin B lozenges and denture soaking in 0.2 % chlorhexidine. To prevent recurrence the dentures were then kept overnight in 0.2 % chlorhexidine during five months. No relapse occurred, but the dentures (all-acrylic) became heavily discoloured by chlorhexidine. During this period fungi could not be grown either on palatal or on maxillar denture agar models, and clinical signs and symptoms were reduced further. At the end of treatment hypochlorite was used to remove chlorhexidine-induced denture stain. Brushing and soaking (0.16 %) proved more efficient than brushing alone, and when a 0.60 % solution was used, the stains were generally eliminated in two hours. Hypochlorites in the prevention and removal of chlorhexidine discolourations deserve further attention.

Key-words: Stomatitis; chlorhexidine; amphotericin B

Ingar Olsen, Institute of Pharmacology, University of Oslo, Blindern, Oslo 3, Norway

Relapse is a frequent problem following antifungal treatment of denture stomatitis (Zegarelli *et al.*, 1961; Kutscher *et al.*, 1964; Budtz-Jørgensen & Bertram, 1970 b; Budtz-Jørgensen & Løe, 1972; Olsen, 1975 a, b). Since dentures covering inflamed palates frequently are overgrown with yeast-like fungi (Olsen, 1974), prevention of fungi from recolonizing the denture might prevent relapse. Chlorhexidine has been found useful as a denture disinfectant in short-term clinical trials on denture stomatitis (Heyden *et al.*, 1971; Budtz-Jørgensen & Løe, 1972; Olsen, 1975 a, b). The present study deals with how long-term denture disinfection in chlorhexidine

may affect (1) the patient, (2) the mycotic flora and (3) the denture.

Chlorhexidine as a soaking agent may discolour acrylic dentures (Budtz-Jørgensen & Løe, 1972; Olsen, 1975 b) and has therefore been considered unfitted for routine cleansing (Budtz-Jørgensen, 1974). However, one patient not included in the present series, learned that diluted Klorin[®], a household cleanser with sodium hypochlorite as the active ingredient, efficiently removed chlorhexidine denture stain. The present trial was conducted to test the concentration of hypochlorite used by this patient (0.60 %) and that (0.16 %) usually recommended for denture soaking

(Kutscher, Zegarelli & Hyman, 1964), on stains appearing on dentures routinely immersed in chlorhexidine.

MATERIAL AND METHODS

Patients. Five females (mean age 68 years, range 61—78) with generalized simple or granular inflammation in the palate were included. Complete upper and lower acrylic dentures were worn by four patients. One participant had a complete maxillary acrylic denture opposing natural lower teeth.

Treatment. A 14-day treatment with amphotericin B (Fungizone®) lozenges (10 mg × 4) combined with denture immersion in 0.2 % chlorhexidine digluconate (Hibitane®) was given initially (Olsen, 1975 a). At the completion of this period the patients were instructed to keep their dentures in a fresh solution of 0.2 % chlorhexidine digluconate each night during five months.

Appointments were at the same hour the day before treatment, the 15th day after its onset, and then two, four and five months thereafter.

Fungal cultures obtained from agar models of the palate and the maxillary denture were quantitated and identified as described previously (Olsen, 1974).

Smears were taken from palate, tongue, rhagades, and the fitting surface of the upper denture and evaluated blindly after the experiment (Olsen, 1974).

Clinical signs and symptoms. The degree of inflammatory reaction in palate, tongue and mouth angles and associated subjective symptoms were rated (Olsen, 1975 b).

Side effects were registered by clinical and photographic examination and by inquiring the patients.

Removal of denture stain

0.60 % hypochlorite (diluted Klorin®). Two patients with heavy chlorhexidine stains after final treatment (two full upper, two full lower dentures) used Klorin (Lilleborg A/S, Norway) diluted in water to a solution containing 0.60 % sodium hypochlorite, pH 11.7. The dentures were steeped for two hours and brushed occasionally with a standard brush (K 45 Denture Brush®, G. B. Kent & Sons Ltd., London, England).

0.16 % hypochlorite. After final treatment three patients with heavy chlorhexidine discolourations on their dentures (three full upper, two full lower) were supplied with sodium hypochlorite (BDH Chemicals Ltd., Poole, England) diluted with water to a 0.16 % solution, pH 11.1. People usually spend no more than 15—20 seconds on their denture hygiene (Theilade, 1958), but presently the patients were instructed to brush each denture for three minutes twice a day. The efficiency of the cleansing procedure was registered after two, five and seven days. For the next seven days brushing was supplemented with overnight denture soaking in the hypochlorite solution.

At each sitting the denture stains were plotted on diagrams. Colour slides were also produced.

RESULTS

Fungal cultures. Yeasts were cultivated on both palatal and denture models of all five patients before treatment. The species were: *Candida albicans* in four participants and *C. parapsilosis* and *Torulopsis glabrata* in the 5th. After the 14-day period of treatment positive cultures could not be obtained.

Smears. Before treatment all smears contained blastospores. Hyphae were

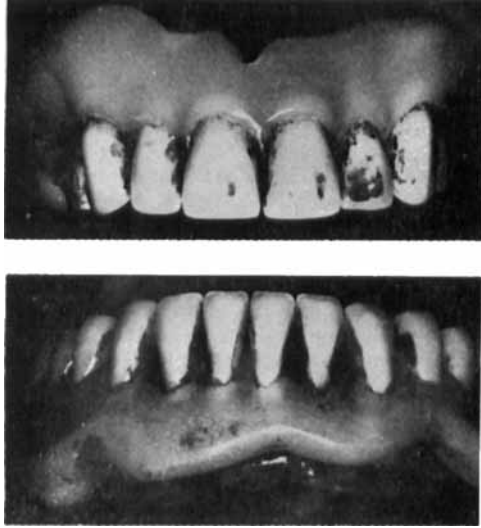


Fig. 1 a. Discolouration of dentures after regular soaking in 0.2 % aqueous chlorhexidine digluconate for 5½ months.

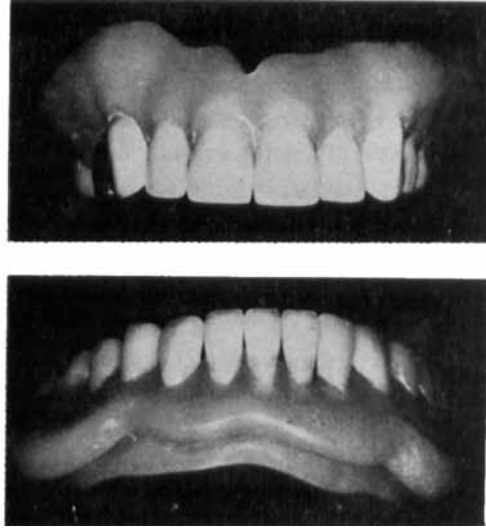


Fig. 1 b. The same dentures after treating the discolourations with 0.16 % aqueous sodium hypochlorite for 14 days.

present in all smears except in the palatal ones from two patients. After 14 days of treatment blastospores had disappeared from the palatal scrapings of two patients. Hyphae were now seen only in denture smears, although in reduced quantities. After treatment for 5½ months blastospores had vanished from the palatal scrapings of another two patients, but persisted in all tongue and denture smears. Hyphae were still present on one denture. Many of the remaining yeast-like cells from this denture demonstrated changes in their staining quality and morphology similar to those observed after 14 days of treatment (Olsen, 1975 a).

Clinical signs and symptoms were definitely reduced after 14 days. Further improvement occurred during the period of all-night soaking. Two tongues became discoloured.

Denture stain. All dentures were heavily discoloured after regular soaking in chlorhexidine for 5½ months (Fig. 1 a). The

effects of the cleansing procedures were as follows:

0.60 % hypochlorite (diluted Klorin). Stains were completely eliminated from three dentures. Approximal spots, hard to reach with the brush, remained in the frontal arch of one lower denture.

0.16 % hypochlorite. After seven days of brushing the stain on all five dentures had been slightly reduced. Addition of nocturnal denture soaking yielded a considerable reduction of stainings in two patients with complete sets of dentures (Fig. 1 b). Minor deposits still persisted in the sulcus between artificial teeth and denture base and on approximal tooth surfaces. More extended deposits remained on one maxillary denture.

DISCUSSION

All participants of this study had relapsed after a previous 14-day period of anti-fungal treatment (Olsen, 1975 b). When in the present study this treatment was

followed by nocturnal denture soaking in chlorhexidine, fungal cultures from palate and denture remained negative, and recurrence was prevented. There was no indication of development of fungal resistance towards chlorhexidine. A slight erythema persisting in one of the cases was of the localized type ascribed to denture trauma (*Budtz-Jørgensen & Bertram, 1970 a*).

The heavy denture discolourations were the main reason for not including more patients and for not prolonging the trial. Chlorhexidine should not be recommended as a soaking agent for long-term use unless stains can be prevented or easily removed.

Alkaline hypochlorite is an effective cleanser against tea and tobacco stain (*Langwell, 1955*). The present study suggests that it is efficient against chlorhexidine discolourations as well. A combined brush and soaking procedure was more efficient than brushing alone. Brush-on application is the most common method of using denture cleansers among the public (*MacCallum et al., 1968*). For speedy removal of stain it would appear reasonable to use the highest of the tested concentrations. Prevention of stain, however, could perhaps be obtained by regular exposure to the weakest solution. Hypochlorites were for some time discredited as denture cleansers because of disadvantages such as bleaching, corrosion and odour (*MacCallum et al., 1968*). Most of these, however, are now probably overcome as modern products with anti-corrosive substances and pleasant odours have been formulated (*Langwell, 1955; Neill, 1968; Hutchins & Parker, 1973*).

The results of this preliminary trial suggest that hypochlorites in the prevention and removal of chlorhexidine discolourations deserve further attention.

REFERENCES

- Budtz-Jørgensen, E.* 1974. *The significance of Candida albicans in denture stomatitis*. Thesis. Scand. J. Dent. Res. 82, 151—190
- Budtz-Jørgensen, E. & Bertram, U.* 1970a. Denture stomatitis. I. The etiology in relation to trauma and infection. Acta Odont. Scand. 28, 71—92
- Budtz-Jørgensen, E. & Bertram, U.* 1970b. Denture stomatitis. II. The effect of anti-fungal and prosthetic treatment. Acta Odont. Scand. 28, 283—304
- Budtz-Jørgensen, E. & Løe, H.* 1972. Chlorhexidine as a denture disinfectant in the treatment of denture stomatitis. Scand. J. Dent. Res. 80, 457—464
- Heyden, G., Widmalm, S.-E., Arwill, T. & Hedegård, B.* 1971. The effects of chlorhexidine on the oral mucosa in patients with partial or complete dentures. Twelve case reports. Sven. Tandlaek. Tidskr. 64, 239—246
- Hutchins, D. W. & Parker, W. A.* 1973. A clinical evaluation of the ability of denture cleaning solutions to remove dental plaque from prosthetic devices. N.Y. State Dent. J. 39, 363—367
- Kutscher, A. H., Zegarelli, E. V., Herlands, R. E. & Silvers, H. F.* 1964. Amphotericin B in the treatment of oral monilial infections. Oral Surg. 17, 31—35
- Kutscher, A. H., Zegarelli, E. V. & Hyman, G. A.* 1964. *Pharmacotherapeutics of oral disease*. McGraw-Hill Book Co., New York, Toronto, London. Epitome, p 5
- Langwell, W. H.* 1955. The cleansing of artificial dentures. Br. Dent. J. 99, 337—339
- MacCallum, M., Stafford, G. D., MacCulloch, W. T. & Combe, E. C.* 1968. Which cleanser? A report on a survey of denture cleansing routine and the development of a new denture cleanser. Dent. Practit. Dent. Rec. 19, 83—89
- Neill, D. J.* 1968. A study of materials and methods employed in cleaning dentures. Br. Dent. J. 124, 107—115
- Olsen, I.* 1974. Denture stomatitis. Occurrence and distribution of fungi. Acta Odont. Scand. 32, 329—333
- Olsen, I.* 1975 a. Denture stomatitis. Effects of chlorhexidine and amphotericin B on the mycotic flora. Acta Odont. Scand. 33, 41—46
- Olsen, I.* 1975 b. Denture stomatitis. The clinical effects of chlorhexidine and amphotericin B. Acta Odont. Scand. 33, 47—54
- Theilade, J.* 1958. Om rengøring af proteser. Tandlaegebladet 62, 41—44
- Zegarelli, E. V., Kutscher, A. H., Herlands, R. E., Lucca, J. J. & Silvers, H. F.* 1961. Oral lesions of interest to the prosthodontist. Part I. Denture stomatitis. J. Prosthet. Dent. 11, 617—620