

ORIGINAL ARTICLE

A multidisciplinary approach for the diagnosis of hypocalcified amelogenesis imperfecta in two Chilean families

BLANCA URZÚA¹, ANA ORTEGA-PINTO², DANIELA ADORNO FARIAS²,
EUGENIA FRANCO², IRENE MORALES-BOZO¹, GUSTAVO MONCADA³,
NICOLÁS ESCOBAR-PEZOA⁴, URSULA SCHOLZ⁵ & VÍCTOR CIFUENTES⁶

¹Department of Physical and Chemical Sciences, ²Department of Oral Pathology, ³Department of Restorative Dentistry, ⁴Department of Prosthesis at the Faculty of Dentistry, University of Chile, Santiago de Chile, Chile, ⁵Private Practice, and ⁶Department of Ecological Sciences, Faculty of Sciences, University of Chile, Santiago de Chile, Chile

Abstract

Objective. The purpose of this study was to conduct a multidisciplinary analysis of a specific type of tooth enamel disturbance (amelogenesis imperfecta) affecting two Chilean families to obtain a precise diagnosis and to investigate possible underlying mutations. **Materials and methods.** Two non-related families affected with amelogenesis imperfecta were evaluated with clinical, radiographic and histopathological methods. Furthermore, pedigrees of both families were constructed and the presence of eight mutations in the enamelin gene (*ENAM*) and three mutations in the enamelysin gene (*MMP-20*) were investigated by PCR and direct sequencing. **Results.** In the two affected patients, the dental malformation presented as soft and easily disintegrated enamel and exposed dark dentin. Neither of the affected individuals presented with a dental and skeletal open bite. Histologically, a high level of an organic matrix with prismatic organization was found. Genetic analysis indicated that the condition is autosomal recessive in one family and either autosomal recessive or due to a new mutation in the other family. Molecular mutational analysis revealed that none of the eight mutations previously described in the *ENAM* gene or the three mutations in the *MMP-20* gene were present in the probands. **Conclusion.** A multidisciplinary analysis allowed for a diagnosis of hypocalcified amelogenesis imperfecta, Witkop type III, which was unrelated to previously described mutations in the *ENAM* or *MMP-20* genes.

Key Words: *amelogenesis imperfecta, enamel malformation, hypocalcified enamel*

Introduction

Inherited defects in enamel development that affect the amount, structure and/or composition of enamel are collectively called amelogenesis imperfecta (AI). These defects may or may not be associated with other ectodermal or systemic diseases [1,2].

Amelogenesis imperfecta is clinically heterogeneous because the enamel malformations show a variety of phenotypes, which are grouped according to the thickness and hardness of the enamel layer [1,2]. These are described as: hypoplastic, hypocalcified and hypomaturational AI. In the same way, AI is a genetically heterogeneous disorder because autosomal dominant, autosomal recessive and X-linked recessive forms have been reported. Based upon the

enamel phenotype and mode of inheritance, 14 clinical sub-types of AI have been recognized [1].

Currently, mutations in six genes are known to have causal roles in the genetic etiology of AI: *AMELX* (amelogenin) [3–5], *ENAM* (enamelin) [6–8], *MMP-20* (enamelysin) [9–11], *KLK4* (kallikrein-4) [12], *DLX3* (distal less) [13,14] and *FAM83H* (family with sequence similarity 83) [15–19].

The purpose of this investigation was to analyze clinically, radiographically and histologically two Chilean families affected with an alteration of enamel structure. Additionally, pedigrees of both families were constructed. We hypothesized that the patients analyzed in this study were affected by autosomal recessive hypocalcified AI. In order to decide on which genes to analyze, we used the Aldred et al. [2] classification,

which considers the mode of inheritance as the first criterion. However, given the persistent organic matrix observed in the histological analysis and the report of Takagi et al. [20], which observed that teeth with hypocalcified AI display amelogenin peptides at early stages of processing, we hypothesized that the causative mutations would be those previously described in genes coding for enamelin (*ENAM*) and enamelysin (*MMP-20*). Therefore, we analyzed the presence of eight mutations in *ENAM* and three mutations in *MMP-20*. Although mutations on *FAM83H* have been described for autosomal dominant hypocalcified AI [15–19], this is not the case for autosomal recessive autosomal hypocalcified AI.

Materials and methods

This study was approved by the ethics committee of the Dental School at the University of Chile. The characteristics and objectives of the study were explained to all participants, who provided written consent. The investigation was conducted in full accordance with ethical principles, including the World Medical Association Declaration of Helsinki (version, 2002) and local regulations.

Patients and AI diagnosis

We investigated two separate Chilean families in the Faculty of Dentistry of the University of Chile with clinical manifestations consistent with a diagnosis of AI according to the classification of Witkop [1], which considers mainly the clinical, radiographic and genetic history, as described below.

Clinical analysis

The participants were asked about systemic illnesses, drug treatments such as tetracycline, fluoride consumption or any other information that could affect the dentition structure during development. Questions about toothaches in response to thermal or chemical stimuli were also asked. Data were collected on the anterior open bite and distortions in the form and color of the dentition, hardness of enamel, loss of contact points and distortions in the enamel surface, excessive wear of enamel and detachment thereof from the underlying dentin. Affected and unaffected individuals were also evaluated clinically for the presence of skin, hair, fingernail and osseous abnormalities known to be a sign of systemic or syndromic conditions that could be associated with AI.

Radiographic analysis

Periapical X rays were taken (Heliodont DS, Siemens, Germany) of all of the analyzed individuals for

detection of enamel and dentine radiopacity, contrast between enamel and dentin, enamel thickness and for evaluation of taurodontism. Left lateral radiographs (Orthophos DS, Siemens, Germany) were obtained from the affected patient in each family and cephalometric analyses with Björk-Jarabak and Steiner's SNA and SNB traces (Quick Ceph 2.0) were conducted for both probands to detect possible skeletal open bites. Once developed, the radiographs were analyzed with a conventional negatoscope.

Genetic and mutational analysis

Family histories were evaluated and pedigrees were constructed for both families using Progeny software. Genomic DNA from affected family members and non-related control individuals was isolated from the peripheral whole blood using the method described by Miller et al. [21]. The exons and exon/intron boundaries of the enamelin and enamelysin genes, with the eight and three reported mutations, respectively, were amplified by PCR using previously described primers [6–11] and additional primers designed with the *Primer3* software. The amplicons of interest were extracted using the Wizard SV Gel and PCR Clean-Up System of Promega. The purified fragments were sequenced in both directions using an ABI PRISM 3100-Avant genetic analyzer. The sequencing reaction used an Amersham Biosciences DYEnamic ET Terminator Cycle Sequencing kit. Comparative sequence analysis was performed using reference sequences (AY167999 for *ENAM* and *MMP-20* from the NC_000011.8 contig) and Invitrogen Vector NTI software, version 10.0.

Histological analysis

One exfoliated deciduous first molar from the affected patient in the family FAI2SR and one permanent third molar from the proband in the family FAI5MH were processed. Each tooth was demineralized in 10% EDTA for 3 weeks and 4 weeks, respectively, processed by a routine histopathological technique, stained with hematoxylin and eosin and observed by light microscopy (Olympus CX 21). Control deciduous and permanent teeth received the same treatment.

Results

Clinical findings

The FAI2SR family index case was examined for the first time when she was 10 years old because she presented with severe discoloration and opacity of all the erupted teeth, in deciduous and permanent dentitions (Figure 1A). These teeth presented with dentin hypersensitivity to thermal and chemical

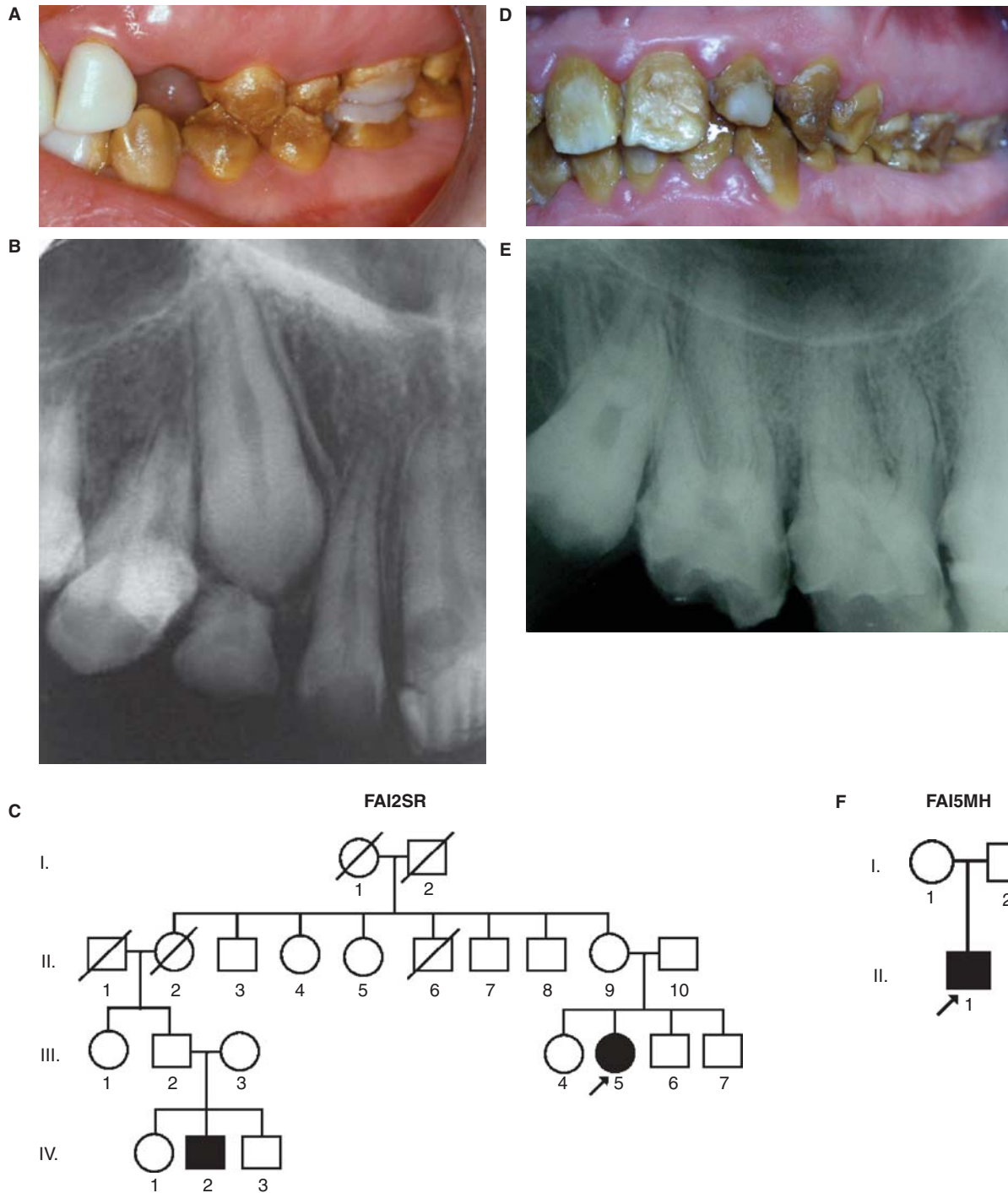


Figure 1. Clinical photos, radiographs and pedigrees of the patients affected with hypocalcified AI from the families FAI2SR (A, B, C, subject III.5) and FAI5MH (E, F, G, individual II.1).

stimulation, which disappeared immediately after the stimulus. The permanent dentition was more affected and had a dark yellowish-brown discoloration, with many irregularities and porosities on the enamel surface of all the teeth, and very soft enamel that was easily lost through wear, especially in the occlusal and middle thirds, while remaining relatively better preserved in the enamel of the cervical third. Chronic marginal gingivitis was present because the rough surface was favorable for plaque accumulation.

Retarded eruption in both dentitions was also observed. Parents and brothers of the patient did not present with alterations in enamel color, hardness or thickness or with clinical abnormalities involving skin, hair, fingernails or other systems that would suggest a syndrome-associated dental malformation.

The 17-year-old male proband of family FAI5MH presented with yellowish-brown permanent teeth that needed dental restoration treatment. All the teeth of the permanent dentition were affected (Figure 1D).

The teeth presented with dentin sensitivity to thermal and chemical stimulation. The enamel appeared dark yellowish-brown in color and was soft and readily lost through daily wear. The enamel in the cervical portion maintained its thickness and presented a yellowish-brown color that was lighter than in the coronary and middle thirds. In this patient, a good vertical overlap of the incisors and occlusion of the posterior teeth was observed. Due to dental plaque accumulation, the patient presented with chronic marginal gingivitis (Figure 1D). He reported that his parents do not have affected teeth, skin, nails or apparently any other system.

Radiographic and cephalometric examination

In the proband of family FAI2SR (III.5), the unerupted maxillary canines showed normal enamel shape and thickness but no contrast differences between enamel and dentine (Figure 1B). Erupted teeth had similar enamel radiodensities. The enamel appeared thin, with an irregular surface that was attributed to loss of enamel through wear. The Björk-Jarabak cephalometric analysis showed almost normal parameters in the sum of the posterior angles of the Björk polygon (S-N-Ar-Go-Gn: 399°), in the goniac angle (130° ; norm $123 \pm 7^\circ$) and in the ratio of posterior face height (S-Go) to anterior face height (N-Gn), which had a value of 64%. The patient presented skeletal facial balance with a mesofacial pattern (Figure 2A).

In the radiograph of the affected man of family FAI5MH (II.1), the enamel of all of the erupted teeth appeared thin, with a radiopacity similar to that of dentin and an irregular surface that was attributed to loss of enamel through wear (Figure 1E). Both upper third molars presented taurodontism (Figure 1E). The Björk-Jarabak cephalometric analysis showed increased values in the sum of the posterior angles of the Björk polygon (S-N-Ar-Go-Gn: 401°), in the goniac angle (135° ; norm $123 \pm 7^\circ$) and in the ratio of posterior face height (S-Go) to anterior face height (N-Gn), which had a value of 55%. This suggests a moderate trend to the face and mandibular vertical growth (dolico-facial pattern trend; Figure 2D).

Genetic and mutational analysis

In the FAI2SR family, the genealogy shown in Figure 1C is consistent with an autosomal recessive mode of inheritance. In the FAI5MH family, the pedigree analysis in Figure 1F shows that the proband's parents were not affected. Thus, the condition could also correspond to a pattern of recessive inheritance or could be a sporadic case due to a new mutation. Sequence analysis of amplified enamelin and enamelysin gene fragments containing numerous previously described AI loci revealed that neither of the probands had any of the eight known *ENAM*

gene mutations or the three known *MMP-20* gene mutations.

Histopathological examination

In decalcified sections of the exfoliated deciduous second molar from individual III.5 of family FAI2SR (Figure 2B), a significant amount of enamel organic matrix persisted after decalcification. This organic matrix presented an organized prism structure with enamel rods of varying widths (Figure 2C). Regarding the permanent third molar of the patient II.1 of family FAI5MH (Figure 2E), a high percentage of enamel organic matrix persisted after decalcification, in which a prismatic structure of enamel was also observed (Figure 2F). In both types of teeth, the enamel matrix was detached from the dentin and was observed floating freely in the EDTA solution, appearing as a fine lacy network of organic material with a delicate appearance (black arrow in Figure 2E). In control teeth at the same time of decalcification, the enamel structure persisted, whereas after a prolonged decalcification (7–9 weeks) no enamel organic matrix was observed.

Diagnosis based on multidisciplinary analysis

Medical history allowed us to rule out fluorosis, tetracycline staining and other environmental conditions that affect tooth development. Clinical, radiographic, genetic and histopathological analysis in both families showed that the enamel of all the teeth of the patients was a softer consistency than normal, yellowish-brown color with enamel loss in the middle and occlusal thirds. At the same time, the patients complained of sensitivity to thermal and chemical stimuli. Radiographic examination revealed a lack of contrast between enamel and dentin, normal thickness of enamel before the eruption of teeth and wear of the enamel in the middle and occlusal thirds of the erupted teeth. In both cases, the histopathological analysis showed that after decalcification of the teeth the organic matrix of enamel is preserved, thus allowing the observation of a clear pattern of enamel rods, which is fully absent in normal teeth after decalcification.

Moreover, the analysis of pedigrees suggested the autosomal recessive as the most probable pattern of inheritance of the condition in both cases. The analysis of all this information led us to the diagnosis of hypocalcified AI type IIIB in the FAI2SR family and hypocalcified AI type IIIA or IIIB in the FAI5MH family, according to the Witkop's classification.

Treatment evolution

During the mixed dentition phase of the FAI2SR family proband, the permanent teeth had caries that

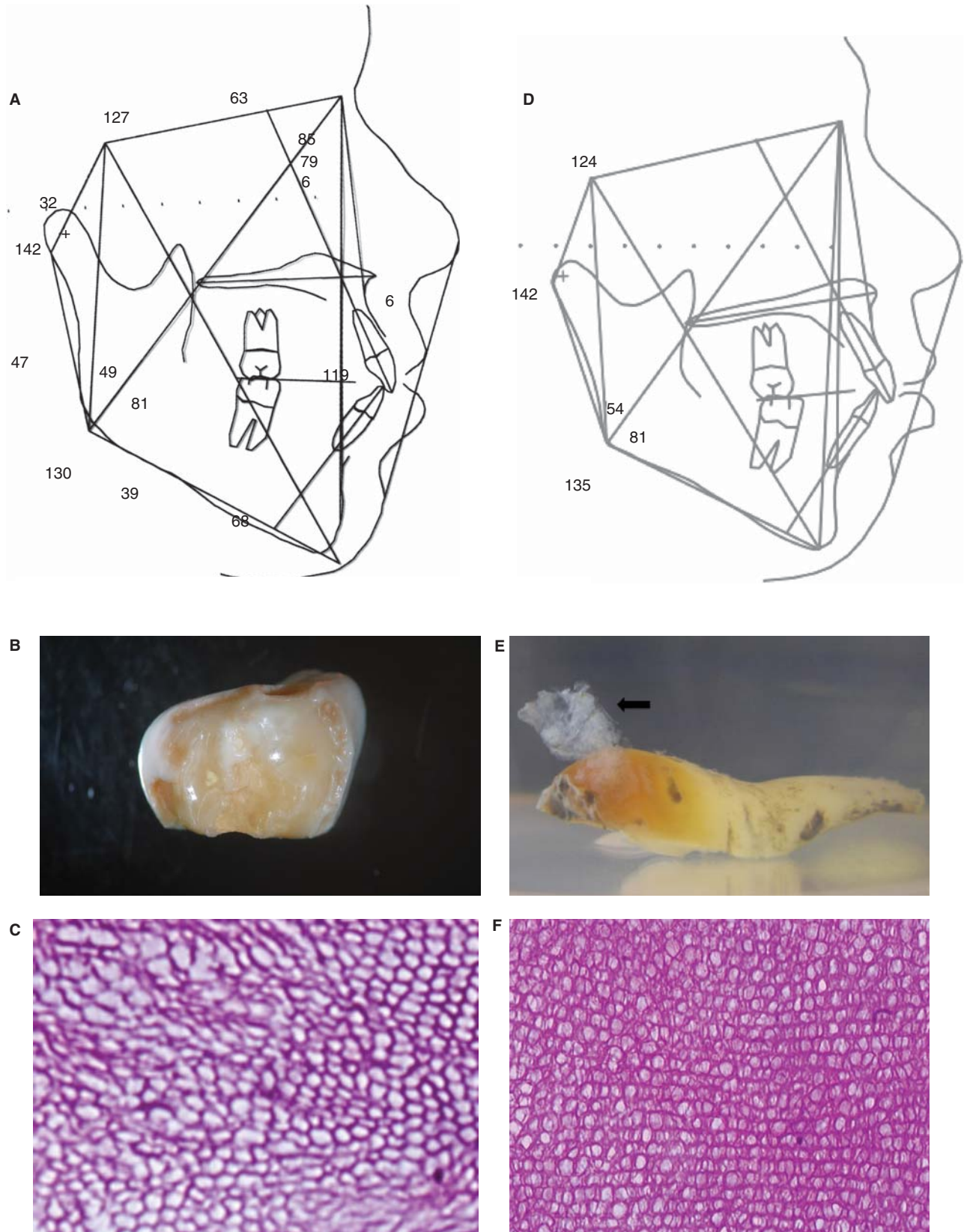


Figure 2. Cephalometric analysis, macroscopic photographs and decalcified histological sections of dental pieces of the patients affected with hypocalcified AI from family AI2SR (A, B, C, subject III.5) and family AI5MH (D, E, F, individual II.1). Black arrow in (E) indicates organic matrix detached.

were removed and the teeth were rebuilt with resin-based composites and glass ionomer cements. The adhesive procedures presented early failures and were frequently repaired and replaced. For generalized gingivitis, the patient received continuous motivation for plaque removal during the deciduous, mixed and permanent dentition phases. The definitive treatment was performed at 21 years of age, when bone growth and development were completed. The final rehabilitation included crowns on all vital teeth, porcelain on upper and lower incisors, canines and premolars and porcelain fused to metal crowns on molars.

The other patient, individual II.1 of the FAI5MH family, presented chronic generalized gingivitis and traces of composite restorations in some teeth, which became detached or fractured shortly after the restoration. For the treatment of gingivitis, the patient received oral hygiene instructions. The final restoration was done when the patient was 19 years old and consisted of 28 ceramic metal-free crowns that were cemented with adhesive techniques. The patient maintained the vitality of 27 teeth and only one premolar required endodontic treatment due to severe pulpalgia. The four third molars were extracted due to eruption complications. After treatment, both patients showed a remarkable improvement in their oral hygiene, which dramatically increased their self perception and psychosocial behavior. The dental treatments show acceptable aesthetic, biological and functional conditions after 4 years.

Discussion

In this study, two unrelated Chilean families with a very similar clinical phenotype were analyzed. The appearance of the teeth in the affected patients was compatible with a preliminary diagnosis of hypocalcified AI (Figures 1A and D). Nevertheless, due to the clinical and genetic heterogeneity of this enamel pathology and for the benefit of the affected patients (and their families), an exhaustive multidisciplinary study was conducted to establish a precise diagnosis. The principal objective of this study was to analyze two AI probands from different families using clinical, radiographic, genetic, histopathological and molecular methods.

In family FAI2SR, the radiographic exams and the clinical and genetic analyses of parents and brothers revealed that only the proband was affected. Non-consanguinity was identified. In family FAI5MH, the affected patient reported that neither the father nor the mother was affected; hence, it could not be determined whether the condition was autosomal recessive or due to a new mutation, as reported for one of the families in the report of Takagi et al. [20].

The clinical classification of Witkop [1] is still the most frequently used and most practical classification system for AI. In the present work, the clinical

diagnosis in both cases corresponded to Type III hypocalcified AI, which is characterized by enamel with a normal shape before eruption, a light contrast between enamel and dentin in radiographs and a very soft enamel that is easily lost after eruption. The yellow-brown appearance of the teeth was very similar to that reported by Nusier et al. [22] and to that observed in patient AI1 in the report of Takagi et al. [20], in which the pattern of inheritance was autosomal recessive.

In the histopathological analysis, the decalcified primary and permanent teeth showed a high level of organic matrix with a prismatic organization that persisted after decalcification. This could correspond to the lack of translucency observed by Nusier et al. [22] in ground sections. This markedly reduced mineral content in hypocalcified AI has been reported by Wright et al. [23] and Gjørup et al. [24]. Enamel affected by hypocalcified AI is characterized clinically by a yellow-brown to orange color with normal thickness, but a radiopacity almost similar to that of dentin in radiographs. This is because AI enamel has a marked reduction in mineral content per volume and exhibits severe ultrastructural irregularities in the enamel crystallite morphology [23,24]. Nonetheless, in both histologically analyzed teeth, the prismatic structure was relatively normal and had high organic contents. Takagi et al. [20] and Wright et al. [23] reported that this matrix specifically retains amelogenin peptides [24]. The large amount of organic matrix observed in the histological enamel preparations (Figures 2C and F) indicates that the protein content was not enzymatically degraded.

In this investigation, a molecular analysis was also conducted. Direct sequencing of PCR-amplified fragments was performed to assess the presence or absence of eight mutations described in the *ENAM* gene and three mutations reported in the *MMP-20* gene. The genetic analysis led us to think that both cases of hypocalcified AI were likely to be inherited in an autosomal recessive manner, indicating that the enamelin gene was one of the most probable candidates. Additionally, some biochemical studies have demonstrated that the enamel in hypocalcified AI retains peptides of amelogenin in early stages of processing, thus suggesting that, in these cases, the defect in the process of enamel synthesis could be an early amelogenin degradation event, possibly during the secretory stage [20]. However, the histopathological study corroborated the persistence of a large amount of organic matrix in the teeth of both affected subjects. Because the metalloproteinase enamelysin is predominant in the secretory stage and its function is reported to be the degradation of amelogenin [9–11,25], we hypothesized that the enamelysin gene may harbor mutations underlying the observed clinical phenotype. Nevertheless, the molecular analysis revealed that the probands of both families

were negative for all the 11 known mutations that were investigated. The absence of known mutations in these patients supports the genetic heterogeneity of this pathology, which is widely described in the literature [26–30]. In addition, other studies of mutational analyses of AI kindred failed to identify pathogenic mutations correlating with the clinical phenotype that cause a predicted loss of protein function [27–29].

Several research groups have reported 15 mutations in the *FAM83H* gene in patients affected with hypocalcified AI from different countries [15–19]. However, all of these patients presented an autosomal dominant pattern of inheritance and, until now, no mutations in this gene have been described in patients with autosomal recessive hypocalcified AI, including the two patients in this report. Recently, Ding et al. [31] observed that the Fam83h protein is associated with intracellular vesicles in the perinuclear region. Those authors speculated that hypocalcification of enamel due to mutations in this gene would have a dominant negative effect caused by the expressed truncated Fam83h proteins that interfere with the function of the wild protein [31]. Therefore, the product of the gene *FAM83H* would fulfill a role that is more structural than enzymatic and mutations in some of the alleles of this gene could affect the critical levels of the protein and would make an autosomal dominant inheritance much more likely. In this context, it is unlikely that this gene may be involved in forms of AI that are inherited in an autosomal recessive pattern, although this cannot be ruled out.

Another possible explanation for our results is that the molecular analysis of the *ENAM* and *MMP20* genes was done only for previously described gene mutations. Thus, most of the coding and regulatory sequences of these genes have not been reviewed and we cannot discount the possibility of mutations in other regions of these genes, in other causal genes (*KLK4*, *FAM83H*, *DLX3*), in other candidate genes (*AMBN*, *TUFT*, *AMTN*) or in genes that are still unknown.

Toward the end of this investigation, a new mutation in the *ENAM* gene has been reported and this mutation was not included in our study [8]. Undoubtedly, this mutation should be analyzed in these families. To date, our earlier study [32], the studies of Santos et al. [29], Mendoza et al. [30], Gutiérrez et al. [7] and the present investigation are the only studies that included patients of South America (Chile, Brazil and Colombia) and that conducted molecular analyses of genes involved in AI. Our investigation is also the first multidisciplinary investigation in Chile and the second in this region of the world with a molecular analysis of genes that cause AI [32]. This study thus contributes genetic-epidemiological data on the absence of 11 mutations in subjects affected with autosomal recessive

hypocalcified AI, a clinical entity with a genetic etiology that still has not been explained.

The resolution of aesthetic problems in AI patients is a very important factor because of their marked impact on the psychosocial health of these patients [33]. In the present study, partially erupted teeth in patient III.5 received composite restorations until they were mature enough to receive porcelain crowns. Patient II.1 received composite restorations with poor results because of the detachment of most of the composites. High failure rates with adhesive restorations in patients with AI have been described, especially with hypocalcified AI [34]. In this type of AI, the enamel has a higher protein content, which might reduce the bonding of restorations [23,24]. Although deproteinization in hypocalcified AI has been reported to enhance the bonding of composite restorations [35], the recent study by Sönmez et al. [36] concluded that the procedure of deproteinization had no significant effect on the success of the adhesive restorations.

Although AI is a genetic condition with a low prevalence, affected patients suffer a great number of clinical problems that affect their quality-of-life. Independent of the type of AI, the patients have a poor self-image and unsatisfactory aesthetics. In most cases, the partial or total absence of enamel is associated with pain caused by thermal and chemical stimuli. Due to the reduced size of the tooth crown caused by attrition and/or incomplete eruption, affected patients may have reductions in both masticatory function and occlusal vertical dimension. Considering the associated clinical complications, psychosocial effects, high economic cost of treatment and the possible association with other conditions, a timely and precise diagnosis of the type of AI for every patient is necessary.

Acknowledgements

This study was supported by the project PRI-ODO 07/3, which is sponsored by a fellowship from the School of Postgraduate Studies of the Faculty of Dentistry, and by the project FIOUCh 09-01 of Faculty of Dentistry, University of Chile. The economic costs of DNA sequencing services were contributed by the Centre of Biotechnology of the Faculty of Sciences of the University of Chile.

Declaration of interest: The authors report no conflicts of interest. The authors alone are responsible for the content and writing of the paper.

References

- [1] Witkop CJ. Amelogenesis imperfecta, dentinogenesis imperfecta and dentin dysplasia revisited: problems in classification. *J Oral Pathol* 1989;17:547–53.

- [2] Aldred MJ, Savarirayan R, Crawford PJM. Amelogenesis imperfecta: a classification and catalogue for the 21st century. *Oral Dis* 2003;9:19–23.
- [3] Wright JT, Hart PS, Aldred MJ, Seow K, Crawford PJM, Hong SP, et al. Relationship of phenotype and genotype in X-linked amelogenesis imperfecta. *Connect Tissue Res* 2003;44(Suppl):72–8.
- [4] Kim JW, Simmer JP, Hu YY, Lin BPL, Boyd C, Wright JT, et al. Amelogenin p.M1T and p.W4S mutations underlying hypoplastic X-linked amelogenesis imperfecta. *J Dent Res* 2004;83:378–83.
- [5] Kida M, Sakiyama Y, Matsuda A, Takabayashi S, Ochi H, Sekiguchi H, et al. A novel missense mutation (p.P52R) in amelogenin gene causing X-linked amelogenesis imperfecta. *J Dent Res* 2007;86:69–72.
- [6] Ozdemir D, Hart PS, Firatli E, Aren G, Ryu OH, Hart TC. Phenotype of ENAM mutations is dosage-dependent. *J Dent Res* 2005;84:1036–41.
- [7] Gutiérrez SJ, Chaves M, Torres DM, Briceño I. Identification of a novel mutation in the amelogenin gene in a family with autosomal-dominant amelogenesis imperfecta. *Arch Oral Biol* 2007;52:503–6.
- [8] Kang HY, Seymen F, Lee SK, Yildirim M, Bahar Tuna E, Patir A, et al. Candidate gene strategy reveals ENAM mutations. *J Dent Res* 2009;88:266–9.
- [9] Kim JW, Simmer JP, Hart TC, Hart PS, Ramaswami MD, Bartlett JD, et al. MMP-20 mutation in autosomal recessive pigmented hypomaturation amelogenesis imperfecta. *J Med Genet* 2005;42:271–5.
- [10] Ozdemir D, Hart PS, Ryu OH, Choi SJ, Ozdemir-Karatas M, Firatli E, et al. MMP20 active-site mutation in hypomaturation amelogenesis imperfecta. *J Dent Res* 2005;84:1031–5.
- [11] Papagerakis P, Lin HK, Lee KY, Hu Y, Simmer JP, Bartlett JD, et al. Premature stop codon in MMP20 causing amelogenesis imperfecta. *J Dent Res* 2008;87:56–9.
- [12] Hart PS, Hart TC, Michalec MD, Ryu OH, Simmons D, Hong S, et al. Mutation in kallikrein 4 causes autosomal recessive hypomaturation amelogenesis imperfecta. *J Med Genet* 2004;41:545–9.
- [13] Dong J, Amor D, Aldred MJ, Gu T, Escamilla M, MacDougall M. DLX3 mutation associated with autosomal dominant amelogenesis imperfecta with taurodontism. *Am J Med Genet A* 2005;133A:138–41.
- [14] Lee SK, Lee ZH, Lee SJ, Ahn BD, Kim YJ, Lee SH, et al. DLX3 mutation in a new family and its phenotypic variations. *J Dent Res* 2008;87:354–7.
- [15] Kim JW, Lee SK, Lee ZH, Park JC, Lee KE, Lee MH, et al. FAM83H mutations in families with autosomal-dominant hypocalcified amelogenesis imperfecta. *Am J Hum Genet* 2008;82:489–94.
- [16] Lee SK, Hu JC, Bartlett JD, Lee KE, Lin B, Simmer JP, et al. Mutational spectrum of FAM83H: the C-terminal portion is required for tooth enamel calcification. *Hum Mutat* 2008;29:95–9.
- [17] Hart PS, Becerik S, Cogulu D, Emingil G, Ozdemir-Ozenen D, Han ST, et al. Novel FAM83H mutations in Turkish families with autosomal dominant hypocalcified amelogenesis imperfecta. *Clin Genet* 2009;75:401–4.
- [18] Wright JT, Frazier-Bowers S, Simmons D, Alexander K, Crawford P, Han ST, et al. Phenotypic variation in FAM83H-associated amelogenesis imperfecta. *J Dent Res* 2009;88:356–60.
- [19] Hyun HK, Lee SK, Lee KE, Kang HY, Kim EJ, Choung PH, et al. Identification of a novel FAM83H mutation and microhardness of an affected molar in autosomal dominant hypocalcified amelogenesis imperfecta. *Int Endodon J* 2009;42:1039–43.
- [20] Takagi Y, Fujita H, Katano H, Shimokawa H, Kuroda T. Immunochemical and biochemical characteristics of enamel proteins in hypocalcified amelogenesis imperfecta. *Oral Surg Oral Med Oral Pathol Oral Radiol Endod* 1998;85:424–30.
- [21] Miller SA, Dykes DD, Polesky HF. A simple salting out procedure for extracting DNA from human nucleated cells. *Nucleic Acids Res* 1988;16:1215.
- [22] Nusier M, Yassin O, Hart TC, Samimi A, Wright JT. Phenotypic diversity and revision of the nomenclature for autosomal recessive amelogenesis imperfecta. *Oral Surg Oral Med Oral Pathol Oral Radiol Endod* 2004;97:220–30.
- [23] Wright JT, Duggal MS, Robinson C, Kirkham J, Shore R. The mineral composition and enamel ultrastructure of hypocalcified amelogenesis imperfecta. *J Craniofac Genet Dev Biol* 1993;13:117–26.
- [24] Gjørup H, Haubek D, Hintze H, Haukali G, Lovschall H, Hertz JM, et al. Hypocalcified type of amelogenesis imperfecta in a large family: clinical, radiographic, and histological findings, associated dento-facial anomalies, and resulting treatment load. *Acta Odontol Scand* 2009;67:240–7.
- [25] Bartlett JD, Simmer JP. Proteinases in developing dental enamel. *Crit Rev Oral Biol Med* 1999;10:425–41.
- [26] Wright JT. The molecular etiologies and associated phenotypes of Amelogenesis Imperfecta. *Am J Med Genet A* 2006;140:2547–55.
- [27] Hart PS, Wright JT, Savage M, Kang G, Bensen J, Gorry M, et al. Exclusion of candidate genes in two families with autosomal dominant hypocalcified amelogenesis imperfecta. *Eur J Oral Sci* 2003;111:326–31.
- [28] Kim JW, Simmer JP, Lin BPL, Seymen F, Bartlett JD, Hu JCC. Mutational analysis of candidate genes in 24 amelogenesis imperfecta families. *Eur J Oral Sci* 2006;114(Suppl 1):3–12.
- [29] Santos M, Hart PS, Ramaswami M, Kanno C, Hart TC, Line S. Exclusion of known gene for enamel development in two Brazilian families with amelogenesis imperfecta. *Head Face Med* 2007;3:8–15.
- [30] Mendoza G, Pemberton TJ, Lee K, Scarel-Caminaga R, Shai RM, González-Quevedo C, et al. A new locus for autosomal dominant amelogenesis imperfecta on chromosome 8q24.3. *Hum Genet* 2007;120:653–62.
- [31] Ding Y, Estrella MRP, Hu YY, Chan HL, Zhang HD, Kim JW, et al. Fam83h is associated with intracellular vesicles and ADHCAI. *J Dent Res* 2009;88:991–6.
- [32] Urzúa OB, Ortega PA, Rodríguez ML, Morales BI. Genetic, clinical and molecular analysis of a family affected by amelogenesis imperfecta. *Rev Med Chile* 2005;133:1331–40.
- [33] Coffield K, Phillips C, Brady M, Roberts M, Strauss R, Wright JT. The psychosocial impact of developmental dental defects in people with hereditary amelogenesis imperfecta. *JADA* 2005;136:620–30.
- [34] Seow K, Amaratunge A. The effects of acid-etching on enamel from different clinical variants of amelogenesis imperfecta: an SEM study. *Pediatr Dent* 1998;20:37–42.
- [35] Şaroğlu I, Aras Ş, Öztaş D. Effect of deproteinization on composite bond strength in hypocalcified amelogenesis imperfecta. *Oral Dis* 2006;12:305–8.
- [36] Sönmez I, Aras S, Tunc E, Küçükşenmen C. Clinical success of deproteinization in hypocalcified amelogenesis imperfecta. *Quintessence Int* 2009;40:113–18.