

A combined clinical, mycological and histological study of denture stomatitis

Tom Bergendal and Göran Isacsson

Departments of Prosthetic Dentistry and Oral Pathology,
Karolinska Institute, Stockholm, Sweden

Bergendal, T. & Isacsson, G. A combined clinical, mycological and histological study of denture stomatitis. *Acta Odontol. Scand.* 1983, 41, 33–44. Oslo. ISSN 0001-6357.

The clinical and histological appearance of the different types of denture stomatitis are in many respects very similar and confluent. In order to study the correlation between clinical and histological appearance and amount of yeasts, 48 patients with denture stomatitis and 24 with a healthy palatal mucosa were examined. The terms atrophic and hyperplastic denture stomatitis were introduced. The intensity of the palatal erythema and the growth of yeasts were most prominent among patients with hyperplastic lesions. Dryness and soreness of the mouth, angular cheilitis, spontaneous hemorrhage, glossitis and leukoplakias were found to a varying extent. No statistical evidence of correlation between the intensity of clinical erythema, amount of yeasts and grade of subepithelial inflammation could be found. The disease has most certainly a background other than solely increased growth of yeasts. □
Denture stomatitis; histopathology; oral mucosa; prosthetics; yeast

Tom Bergendal, Department of Prosthetic Dentistry, Karolinska Institute, Box 4064, S-141 04 Huddinge, Sweden

Removable dentures may induce inflammatory reactions in the underlying mucosa. These changes are usually called denture sore mouth (17), stomatitis prothetica (8) or denture stomatitis (19) but several other names have been suggested. With regard to the clinical appearance, Östlund (35) distinguished between 'local inflammation', 'diffuse reddening' and the 'granulated' type of stomatitis.

Local inflammation appeared with red spots usually around the small palatal minor salivary glands. Budtz-Jørgensen & Bertram (14) used the term 'localized simple inflammation' including both pinpoint hyperemia and diffuse inflammation of a limited area of the palatal mucosa. This lesion has been reported to be associated with trauma from the dentures (15, 34).

Diffuse reddening appeared with a diffuse hyperemic, smooth and atrophic mucosa extending over the entire denture bearing area. This lesion has also been called chronic atrophic palatitis, stomatitis prothetica nudata and generalized simple inflammation of the palate (14, 18, 42). Increased growth of yeasts has among other factors been associated with this lesion (17, 18). Lehner (27) therefore suggested the names chronic

atrophic candidiasis later changed to chronic atrophic candidosis (28). Jensen & Holst (25) introduced the name candidosis chronica mucosae oris localisata. The WHO definition of denture stomatitis (ICD-DA 528. 91) does not include subgroups of the disease but *Candida*-induced denture stomatitis was referred to as candidosis (IDC-DA 112.X1) (46).

The granulated type of denture stomatitis is characterized by a hyperemic mucosa with nodular appearance mostly covering the central part of the palate. This lesion is in the English literature referred to by the name inflammatory papillary hyperplasia of the palate (22). However, papillomatosis, granular inflammation, hyperplastic denture stomatitis and multiple papillomas of the palate are some of the synonyms used (14, 38, 42). Furthermore, three variants of hyperplastic denture stomatitis are described; one nodular, one diffuse papillary and one mossy form (24, 26). A combination of trauma and *Candida* infection has been suggested as etiological factors (15, 22). The clinical and histological appearance of the different types of denture stomatitis are in many respects very similar and confluent (6, 7).

The purpose of this paper was to evaluate the correlation between clinical and histological appearance of the oral mucosa and the yeast score in order to improve the characterization of the disease.

Materials and method

Forty-eight patients with palatal denture stomatitis and 24 full denture wearers without any signs of denture stomatitis, included as a reference group, were all selected from the list of patients asking for new dentures.

Those who exhibited palatal generalized simple and granular inflammation (clinical criteria detailed by Budtz-Jørgensen & Bertram (14)) were included. In this article the former will be referred to as atrophic denture stomatitis and the latter as hyperplastic denture stomatitis. The distribution of the patients with regard to diagnosis, sex and age is listed in Table 1. All persons were examined and treated in the same way.

Clinical registration

All patients with atrophic stomatitis showed a smooth erythematous palatal mucosa without any sign of hyperplastic granules. The erythema of the denture bearing mucosa was graded in a scale ranging from 0 to 3 according to Bergendal & Isacson (7). Furthermore, other mucosal lesions such as angular cheilitis, glossitis and leukoplakia were registered as well as spontaneous bleeding from the palatal mucosa. The subjective symptoms of soreness and dryness of the mouth were recorded.

Mycological sampling and registration

For sampling of fungal cultures from the palate and the fitting surface of the upper denture a modification of the culture technique developed by Bahn et al. (3) was used. The colony forming units of yeasts were quantitated and graded in a scale ranging from 0 to 3 according to Budtz-Jørgensen & Bertram (14).

Biopsy procedure and histological evaluation

From all persons included in the study one punch biopsy (diameter 3.9 mm) was taken under local analgesia from a representative part of affected palatal mucosa (7). The tissue was immediately fixed in 10% neutral buffered formalin. The specimens were embedded in paraffin, cut in 4 µm thick sections and stained with hematoxylin-eosin, hematoxylin/van Gieson and PAS by the method of McManus. The specimens were microscopically evaluated and graded with regard to the different features as follows:

Epithelial keratinization, such as orthokeratosis, parakeratosis and absent keratin formation.

Thickness of epithelium. Normal thickness = 0; slight to moderate atrophy and/or slight to moderate acanthosis = 1; pronounced atrophy and/or pronounced acanthosis = 2.

Intraepithelial changes. No intraepithelial

Table 1. Distribution of the material regarding diagnosis, sex, and age

	Male	Female	Age		Σ
			Range	Mean	
Reference group	13	11	45-77	61.4	24
Atrophic denture stomatitis group	3	16	47-80	63.9	19
Hyperplastic denture stomatitis group	15	14	32-79	60.4	29

edema = 0; slight to moderate inter- and intra-cellular edema = 1; pronounced inter- and intra-cellular edema = 2.

Epithelial leukocyte penetration. No visible leukocytes = 0; slight appearance = 1; moderate appearance = 2; pronounced appearance = 3.

Subepithelial inflammation. No reaction = 0; slight reaction = 1; moderate reaction = 2; pronounced reaction = 3.

Statistical methods

The chi-square test and Fisher's exact test were used to study statistical evidence of correlation between the different graded clinical, mycological and histological features. The scores of the different features were dichotomized into low and high groups. A p value of 0.01 or less was regarded as significant.

Results

The reference groups showed a pale healthy mucosa, five cases exhibiting a few small spots of erythema around the orifices of minor salivary glands (Fig. 1). Five patients reported dryness of the mouth and soreness

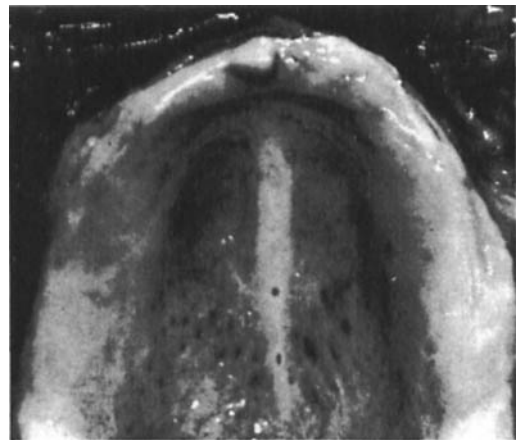


Fig. 1. Small spots of erythema around the orifices of minor salivary glands were occasionally found in an otherwise healthy palatal mucosa.

of the tongue. Occasionally glossitis and angular cheilitis were seen (Table 2).

No growth of yeasts was registered on the denture base in 17 nor on the palatal mucosa in 20 cases (for details see Table 4).

An orthokeratotic epithelium with a distinct stratum granulosum (Fig. 2) or a well-defined parakeratosis was found histologically. The rete pegs showed a regular wave pattern sharply separated from a dense collagenous lamina propria. Slight intra-

Table 2. Anamnestic and clinical findings in patients with atrophic and hyperplastic denture stomatitis as well as in a reference group

	Reference group (n = 24) No. (%)	Atrophic denture stomatitis group (n = 19) No. (%)	Hyperplastic denture stomatitis group (n = 29) No. (%)
Dryness of the mouth	5 (20.8)	5 (26.3)	8 (27.6)
Bleeding	0	2 (10.5)	3 (10.3)
Soreness†	2 (8.3)	7 (36.8)	9 (31.0)
Palatal mucosa	0	2	7
Tongue	2	0	0
Angles of the mouth	0	5	2
Angular cheilitis†	2 (8.3)	6 (31.6)	10 (34.5)
Unilateral	1	1	2
Bilateral	1	5	8
Glossitis	2 (8.3)	7 *(36.8)	6 (20.7)
Leukoplakia	0	0	3 (10.3)

* Including one case with lingua geografica.

† Denture stomatitis group versus reference group; both p < 0.05.

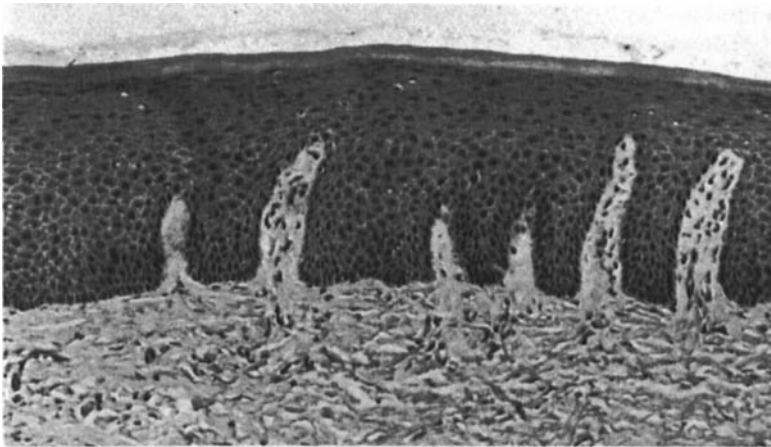


Fig. 2. The palatal mucosa from a case in the reference group showing orthokeratosis, regular wave pattern of the rete pegs and a dense collagenous lamina propria. ($\times 70$.)

epithelial changes, leukocyte penetration and a slight subepithelial inflammatory reaction were sometimes seen (Table 5).

Atrophic denture stomatitis was clinically characterized by a smooth erythematous and edematous atrophic mucosa involving most of the denture bearing palatal mucosa (Fig. 3). Most patients exhibited a slight or moderate degree of erythema (for details see Table 3). Three patients also exhibited denture stomatitis in the lower jaw. The incidence of dryness and soreness of mouth and clinical findings are listed in Table 2.

In the atrophic group the growth of yeasts was most prominent on the denture base, nine cases showing high yeast scores (for details see Table 4). Histologically the atrophic denture stomatitis often shows a mucosa generally covered with a non-keratinized epithelium with deeply penetrating rete pegs alternating with areas of atrophy (Fig. 4). Intraepithelial changes appeared preferentially in the lower spinosum layer as

an intracellular edema. In the presence of wide, long rete pegs a marked intercellular edema and acantholysis were found (Fig. 5) sometimes with narrow deep crypt formations (Fig. 6). There was no association between minor salivary glands of the palate, its excretory ducts and the crypts.

Microabscess formations were occasionally found but the amount of penetrating leukocytes varied widely.

Drop-shaped rete pegs, keratin pearl formation, basal cell hyperplasia and large hyperchromatic nuclei were commonly found in the epithelium. However, when applied to the definitions given by the WHO Collaboration Centre for Oral Precancerous

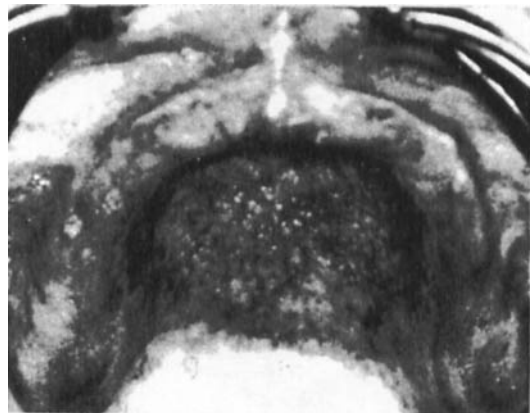


Fig. 3. Atrophic denture stomatitis with a smooth erythematous and atrophic mucosa involving most areas of the denture-bearing palatal mucosa.

Table 3. Distribution of erythema scores in patients with atrophic and hyperplastic denture stomatitis (For explanation of the scales, see text)

	Erythema scores			
	0	1	2	3
Atrophic denture stomatitis group (n = 19)	0	7	10	2
Hyperplastic denture stomatitis group (n = 29)	0	5	8	16

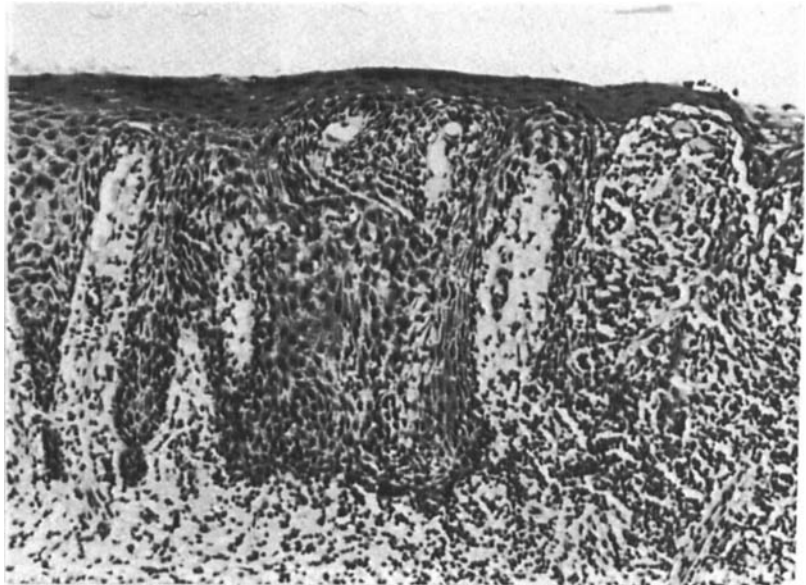


Fig. 4. Atrophic denture stomatitis with non-keratinized epithelium and deeply penetrating rete pegs alternating with areas of atrophy. The connective tissue is replaced by an inflamed granulation tissue. ($\times 75$.)

Table 4. Distribution of yeast scores of palatal mucosa (P) and denture base (D) graded from 0 to 3 in relation to reference group and denture stomatitis groups

	Yeast scores							
	0		1		2		3	
	P	D	P	D	P	D	P	D
Reference group (n = 24)	20	17	4	3	0	3	0	1
Atrophic denture stomatitis group (n = 19)	3	2	11	4	1	4	4	9
Hyperplastic denture stomatitis group (n = 29)	4	1	16	5	4	8	5	15

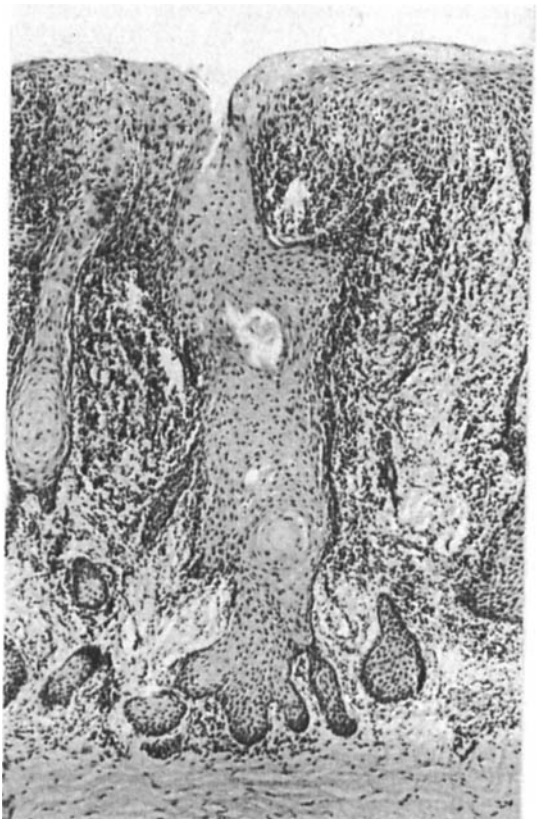


Fig. 5. Atrophic denture stomatitis with wide, long rete pegs and a marked intercellular edema acantholysis, keratin pearl formations and 'budding'. ($\times 75$.)

Lesions (47), no epithelial dysplasia was registered.

In the subepithelial connective tissue, lymphocytes and plasma cells were located in a narrow zone close to the epithelium (Fig. 4). Sometimes a very intense inflammatory reaction appeared (Table 5) and the connective tissue was replaced by granulation tissue. On a few cases this dense inflammatory reaction extended deep into the lamina propria (Fig. 7). A small number of histiocytes appeared but eosinophils were only occasionally found. The covering epithelium

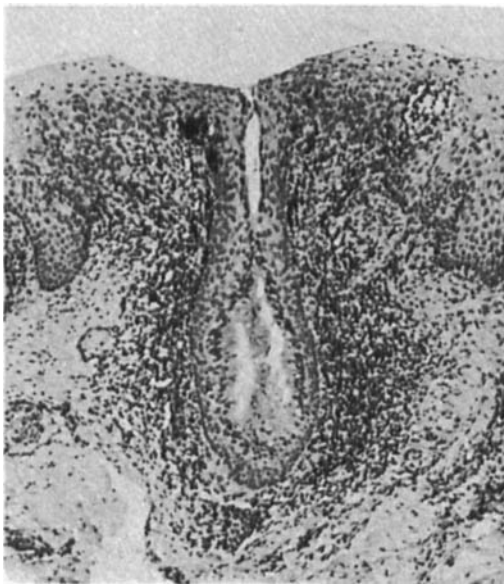


Fig. 6. Atrophic stomatitis where the epithelium exhibits a narrow deep crypt formation. ($\times 70$.)

consisted often only of a few epithelial cell layers when a moderate to severe sub-epithelial inflammatory reaction appeared. The grading of histological features is listed in Table 5.

Table 5. Distribution of histological scores in persons with atrophic (ADS) and hyperplastic denture stomatitis (HDS) as well as in a reference group (RG). For further explanation of scales, see text

	Scores			
	0	1	2	3
Thickness of epithelium				
RG*	19	5	0	—
ADS	6	6	7	—
HDS	2	10	17	—
Intraepithelial changes				
RG*	12	11	0	—
ADS	2	9	8	—
HDS	4	19	6	—
Epithelial leukocyte penetration				
RG*	13	10	0	0
ADS	0	8	8	3
HDS	0	11	12	6
Subepithelial inflammation				
RG*	19	4	0	0
ADS	0	12	2	5
HDS	0	14	7	8

* One specimen was obliquely cut and some features could not be read accurately.

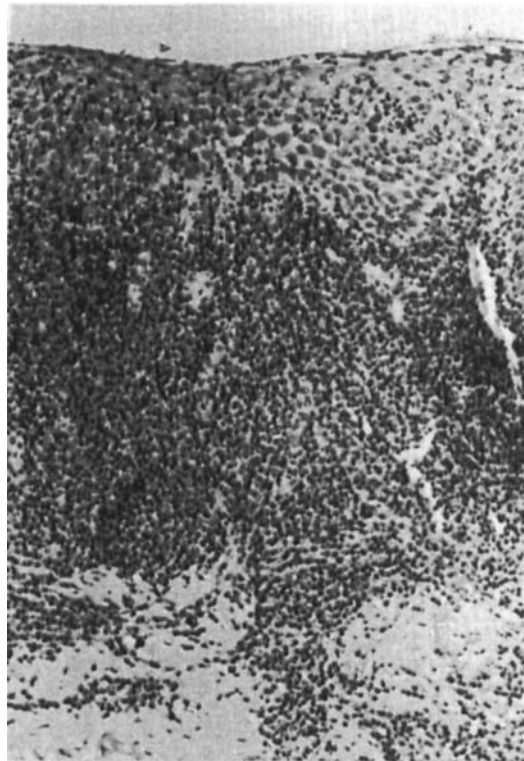
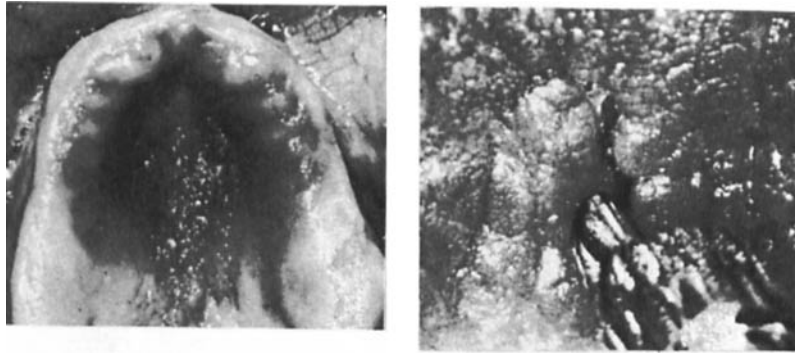
Fig. 7. In a few cases of atrophic denture stomatitis a dense inflammatory reaction extended deep into the lamina propria. ($\times 70$.)

The hyperplastic denture stomatitis exhibited numerous papillary projections sometimes with a mossy structure, or with nodular formations, in shape simulating roe-grains. The lesions were mainly located in the central part of the hard palate (Fig. 8). However, in some cases the papillary projections extended to the top of the alveolar ridge. The depth of the clefts between the papillary projections varied from 1 to 7 mm. The deepest clefts appeared in the midline of the palate and the shallowest on the alveolar ridge. The erythema of the palatal mucosa in this group was usually more prominent than in the atrophic group (see Table 3). Six patients exhibited denture stomatitis in the lower jaw. Areas with papillary projections were sometimes mixed with areas having an atrophic, smooth and erythematous appearance.

Dryness of the mouth, soreness of the

Fig. 8. Hyperplastic denture stomatitis with the palate covered by erythematous papillary projections which can be separated by a blast of air.



palatal mucosa and in the corners of the mouth, angular cheilitis, spontaneous hemorrhage when removing the dentures, glossitis (Fig. 9) and leukoplakias close to commissures (Fig. 10) were found to a varying extent (for details see Table 2).

Patients with hyperplastic denture stomatitis showed a profound growth of yeasts on the denture base and on the mucosa in 15 and 5 cases respectively.

The hyperplastic denture stomatitis showed in general the same histological reactions as described for the atrophic group (see Table 5) with the exception of the papillary projections in the former group. The papillary buds were built up of either a marked hyperplastic epithelium with a narrow core of connective tissue (Fig. 11) or of a hyperplastic connective tissue with covering epithelium of almost normal thickness (Fig. 12). In the latter cases the subepithelial inflammatory reactions were generally absent, but sometimes the core of the papillary projections was built up of heavily inflamed granulation tissue. The epithelial thickness was then only 2-3 cell layers (Fig. 13). Debris composed of bacterial plaque, desquamated epithelial cells and leukocytes was found in a varying degree on the epi-

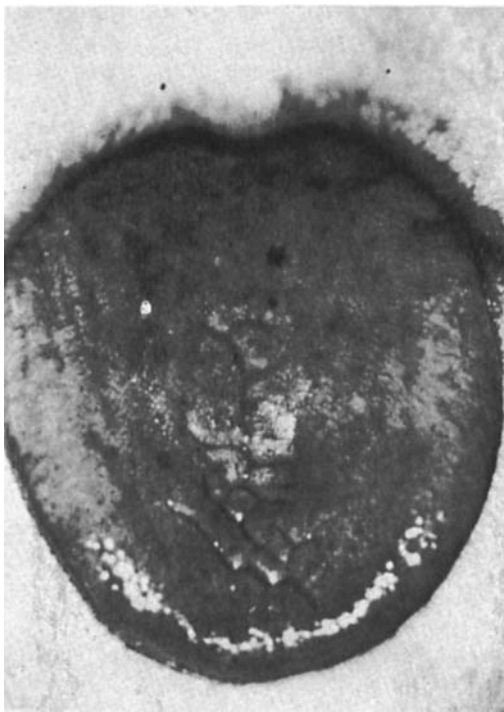

Fig. 9. Glossitis was found in 20.7% of patients with hyperplastic denture stomatitis.

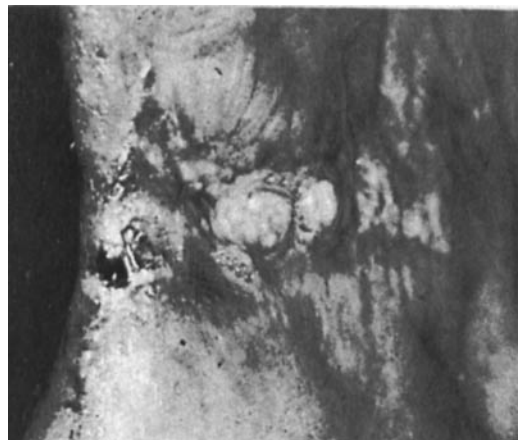

Fig. 10. Hyperplastic leukoplakias at the commissure were found in three patients.

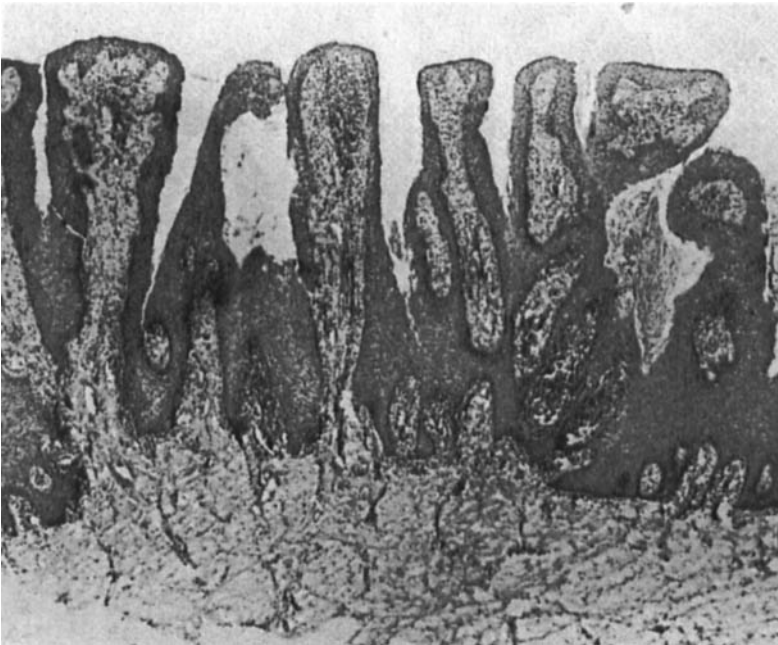


Fig. 11. Papillary projections built up of a marked hyperplastic epithelium and a core of connective tissue. ($\times 40$.)

thelial surface and within the crypts. For details of the histological findings the reader is referred to Table 5.

Hyphae or blastospores of yeasts in the mucosa were never discovered histologically in any of the groups examined.

The statistical analyses of dichotomized data showed evidence of correlation for subepithelial inflammation and epithelial thickness ($p < 0.01$) in the hyperplastic

group and when atrophic and hyperplastic cases were pooled ($p < 0.001$). Statistical evidence of correlation for the scores of leukocyte penetration and clinical erythema was found in the atrophic group and in the group including both atrophic and hyperplastic cases ($p < 0.01$). All other combinations of the score of clinical erythema, yeasts and histological parameters showed a p value of more than 0.05.

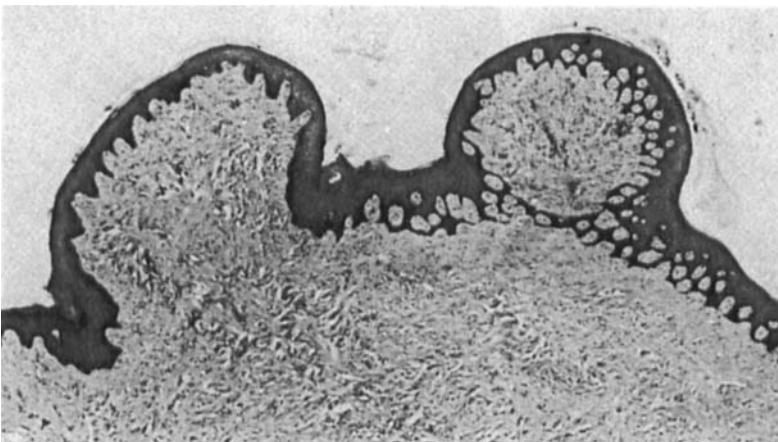
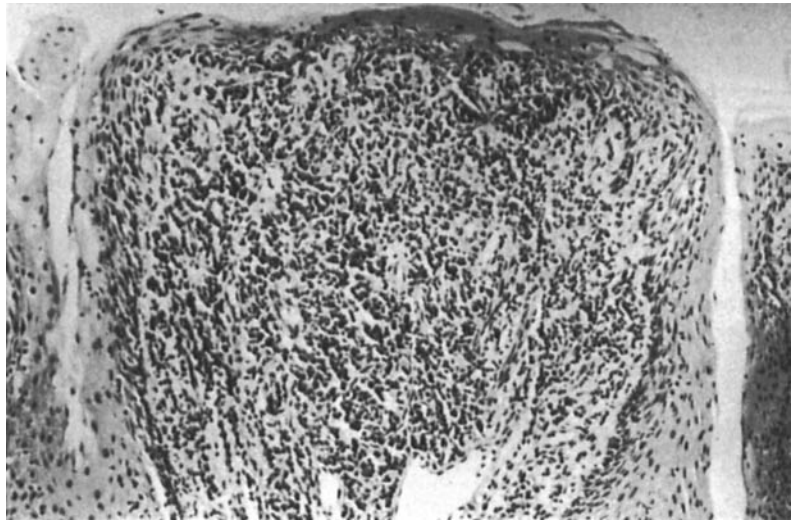


Fig. 12. The papillary projections occasionally showed an epithelium of almost normal thickness and with a hyperplastic connective tissue. ($\times 40$.)

Fig. 13. The core of the papillary projections built up of a heavily inflamed granulation tissue covered by an atrophic epithelium. ($\times 130$.)



Discussion

The present investigation comprised a clinical, mycological and histological study of atrophic and hyperplastic denture stomatitis with special reference to measurable coinciding features. The disease has a complex background with many etiological and predisposing factors, which could explain the lack of statistical evidence for correlation between many of the measured features.

In the present study the yeast score was not correlated with the intensity of the palatal erythema and subepithelial inflammation. This might be due to the fact that the impression technique is not very exact for quantitative registration (1). The quantity of yeasts, i.e. *Candida albicans* is reported to be important for tissue damage (30, 45). However, McKendrich et al. (32) maintained that a quantitative increase of *Candida* does not necessarily increase the susceptibility to *Candida* infections. Further, it is not known whether heavy growth of yeasts is the causal factor or a secondary effect of a primary bacterial infection with or without associated local or general predisposing factors (40). However, it cannot be disregarded that plaque from the fitting surface of dentures without associated stomatitis only con-

tains minimal amounts of yeasts (16), in contrast to the increase of yeasts associated with denture stomatitis (41). On the other hand, it is documented that nystatin treatment does not cure denture stomatitis, and there is a quick recolonization of yeasts after the end of treatment (5, 7). Other factors such as bacterial toxins seem to be involved (43). Denture stomatitis may in rare cases be found without increased growth of yeasts, and these cases are defined by WHO (47) as denture stomatitis. However, WHO nomenclature in ICA-DA (46) states that 'denture stomatitis associated with growth of candida will be referred to candidosis'. This is an unfortunate statement since the microbiological component includes both yeasts and bacteria.

Angular cheilitis appears more frequently among patients with denture stomatitis than in persons with a healthy palatal denture bearing mucosa. The results of the present study confirms those of Mäkilä (31) and Ritchie et al. (37), who reported an incidence of 37% and 41%, respectively, of angular cheilitis among patients with denture stomatitis. The direct cause of the high incidence of angular cheilitis might be infection by yeasts or bacteria (4, 29) when the infection is secondary to a local or a systemic

predisposing factor (for review see Budtz-Jørgensen (13)).

Leukoplakia of the oral mucosa is a lesion appearing among patients with hyperplastic denture stomatitis; in our study it was found in three patients. Leukoplakia formations might be favored by growth of the yeasts both at the angle of the mouth and on the denture base (21). These lesions are probably examples of hyperplastic candidosis and need adequate diagnosis and treatment.

Soreness of the palatal mucosa and at the angles of the mouth in combination with denture stomatitis is reported to be rare (20, 37), which is in contrast to the results of the present study, in which every third patient reported soreness. A decreased salivary flow rate in combination with infections in an acute phase manifested as erythema and glossitis may be the explanation of sore mouth (9, 12).

Histologically the atrophic and hyperplastic stomatitis showed epithelial atrophy interchanged with hyperplastic rete pegs, but surprisingly many cases, especially in the atrophic group, exhibited a normal epithelial thickness, a finding in this study which supports that of Budtz-Jørgensen (11). This may explain why the majority of the atrophic lesions did not show so many cases of severe erythema. The clinical erythema registered may be explained by the fact that the more or less inflamed and edematous subepithelial area contains numerous superficial, enlarged capillaries where the color of the blood is visible through the non-keratinized epithelium.

The higher intensity of palatal erythema in patients with hyperplastic than with atrophic lesions is probably due to the fact that the former retain much debris and plaque within the crypts, which support an inflammatory reaction. Heavy accumulations of yeasts are also more prominent among persons with hyperplastic denture stomatitis than in those with atrophic lesions.

The growth of yeasts often gives rise to increased numbers of atypical cells and frequently *Candida* leukoplakia is associated with dysplasia (36). In spite of the presence of yeasts denture stomatitis should not be regarded as dysplasia, since the epithelial

reaction differs from that seen in *Candida* leukoplakia. A pseudoepitheliomatous hyperplasia is a more adequate term (10). Cases of associated malignant alterations have been reported (23, 44) and therefore extirpated tissue should always be examined histologically when surgical procedures are carried out (6).

It is obvious that the atrophic and hyperplastic denture stomatitis are intimately correlated to each other. Clinically the atrophic areas often appear in association with hyperplastic lesions (13). As reported in the present study, intraepithelial acantholysis and crypt formations are features also in the atrophic group. Depending on the type and time of tissue fixation, changes or loss of intercellular space may have appeared in our material (33, 39). However, the denture-bearing palatal mucosa of non-diseased subjects did not show the intraepithelial changes found in the stomatitis affected mucosa. Therefore the acantholysis must be a true tissue reaction characteristic of the disease and not an artefact. The local crypt formations may increase in size and confluence and in that way start the papillary formation.

According to common pathological terminology and with regard to the microscopical and clinical findings in the present study, the name hyperplastic denture stomatitis is warranted to describe the papillary variant of denture stomatitis. The term 'papillary hyperplasia' should in our opinion be reserved for a lesion characterized by papillary projections from the palate without any association with dentures. Papillary hyperplasia, which appears only in 0.03% of the Swedish population (2), has an etiology obviously differing from the hyperplastic denture stomatitis. Consequently, the name atrophic denture stomatitis should be used for a condition showing an erythematous, smooth and atrophic mucosa without papillary projections.

The lesions referred to as local inflammation and pinpoint hyperemia are conditions with a background and behavior quite different from that of atrophic and hyperplastic denture stomatitis (14, 35). Therefore these lesions, in our opinion, will not fall under the heading of denture stomatitis.

Acknowledgements.—The authors are most grateful to Dr. Kenneth Holmberg, Head of the Mycology Section, National Bacteriological Laboratory, Stockholm, for technical assistance and valuable advice. This study was supported by grants from the Faculty of Odontology, Karolinska Institute, and from the Swedish Dental Society.

References

1. Arendorf, T. M. & Walker, D. M. Oral candidal populations in health and disease. *Br. Dent. J.* 1979, 147, 267–272
2. Axell, T. A prevalence study of oral mucosal lesions in an adult Swedish population. *Odontol. Rev.* 1976, 27, suppl. 36, 1–103
3. Bahn, A. N., Quillam, P. D. & Kendrick, F. J. Intraoral localization of micro-organisms. *J. Dent. Res.* 1962, 41, 715
4. Bergendal, T. Status and treatment of denture stomatitis patients: a 1-year follow-up study. *Scand. J. Dent. Res.* 1982, 90, 227–238
5. Bergendal, T., Holmberg, K. & Nord, C.-E. Yeast colonization in the oral cavity and feces in patients with denture stomatitis. *Acta Odontol. Scand.* 1978, 37, 37–45
6. Bergendal, T., Heimdahl, A. & Isacson G. Surgery in the treatment on denture-related inflammatory papillary hyperplasia of the palate. *Int. J. Oral Surg.* 1980, 9, 312–319
7. Bergendal, T. & Isacson, G. The effect of nystatin in the treatment of denture stomatitis. *Scand. J. Dent. Res.* 1980, 88, 446–454
8. Bergman, B., Carlsson, G. E. & Hedegård, B. Longitudinal two-year study of a number of full denture cases. *Acta Odontol. Scand.* 1964, 22, 3–26
9. Bertram, U. Xerostomia, clinical aspects, pathology and pathogenesis. *Acta Odontol. Scand.* 1967, 25, suppl. 49
10. Bhaskar, S. N. Synopsis of oral pathology, 5th ed. C. W. Mosby, New York, London, 1977, pp. 456–458
11. Budtz-Jørgensen, E. Denture stomatitis. III. Histopathology of trauma- and candida-induced inflammatory lesions of the palatal mucosa. *Acta Odontol. Scand.* 1970, 28, 551–579
12. Budtz-Jørgensen, E. Clinical aspect of candida infection in denture wearers. *J. Am. Dent. Assoc.* 1978, 96, 474–479
13. Budtz-Jørgensen, E. Oral mucosal lesions associated with the wearing of removable dentures. *J. Oral Pathol.* 1981, 10, 65–80
14. Budtz-Jørgensen, E. & Bertram, U. Denture stomatitis. I. The etiology in relation to trauma and infection. *Acta Odontol. Scand.* 1970, 28, 71–92
15. Budtz-Jørgensen, E. & Bertram, U. Denture stomatitis. II. The effect of antifungal and prosthetic treatment. *Acta Odontol. Scand.* 1970, 28, 283–304
16. Budtz-Jørgensen, E., Theilade, E., Theilade, J. & Zander, H. A. Method for studying the development, structure and microflora of denture plaque. *Scand. J. Dent. Res.* 1981, 89, 149–156
17. Cahn, L. R. The denture sore mouth. *Ann. Dent.* 1936, 3, 33–36
18. Cawson, R. A. Denture sore mouth and angular cheilitis. *Br. Dent. J.* 1963, 115, 441–449
19. Cawson, R. A. Symposium on denture sore mouth. II. The role of *Candida*. *Dent. Pract. Dent. Rec.* 1965, 16, 138–142
20. Cawson, R. A. Chronic oral candidosis, denture stomatitis, and chronic hyperplastic candidosis. In: eds. Winner, H. I. & Hurley, R. Symposium on candida infections. E. & S. Livingstone Ltd., Edinburgh and London, 1966, pp. 138–152
21. Cernea, P., Crepy C., Kutter, R., Mascaro, J. M., Badillet, G. & Marie J.-L. Aspects peu connus de candidoses buccale. Les candidoses a foyers multiples de la cavité buccale. *Rev. Stomatol.* 1965, 16, 103–138
22. Ettinger, R. L. The etiology of inflammatory papillary hyperplasia. *J. Prosthet. Dent.* 1975, 34, 254–261
23. Eyre, J. & Nally, F. F. Oral candidosis and carcinoma. *Br. J. Dermatol.* 1971, 85, 73–75
24. Guernsey L. H. Reactive inflammatory papillary hyperplasia of the palate. *Oral Surg.* 1965, 20, 814–827
25. Jensen, P. S. & Holst, E. Candidosis oralis. *Ugeskr. Laeger* 1969, 131, 1229–1239
26. Lambson, G. O. Papillary hyperplasia of the palate. *J. Prosthet. Dent.* 1966, 16, 636–645
27. Lehner, T. Symposium on denture sore mouth. III. Immunofluorescent investigation of *Candida*. *Dent. Pract. Dent. Rec.* 1965, 16, 142–146
28. Lehner, T. Oral candidosis. *Dent. Pract. Dent. Rec.* 1967, 17, 209–216
29. MacFarlane, T. W. & Helnarska, S. J. The microbiology of angular cheilitis. *Br. Dent. J.* 1976, 140, 403–406
30. Maibach, H. I. & Kligman, A. M. The biology of experimental human cutaneous moniliasis (*Candida albicans*). *Arch. Dermatol.* 1962, 85, 233–257
31. Mäkilä, E. Prevalence of angular stomatitis. Correlation with composition of food and metabolism of vitamins and iron. *Acta Odontol. Scand.* 1969, 27, 655–680
32. McKendrik, A. J. W., Wilson, M. I. & Main, D. M. G. Oral *Candida* and long term tetracycline therapy. *Arch. Oral Biol.* 1967, 12, 281–290
33. Müller, W. & Schroeder, H. E. Differentiation of the epithelium of the human hard palate. *Cell Tissue Res.* 1980, 209, 295–313
34. Newton, A. V. Denture sore mouth. *Br. Dent. J.* 1962, 112, 357–360
35. Östlund, S. G. The effect of complete dentures on the gum tissues. *Acta Odontol. Scand.* 1958, 16, 1–43
36. Pindborg, J. J. Atlas of diseases of the oral mucosa, 3rd ed. Munksgaard, Copenhagen, 1980, p. 54

37. Ritchie, G. M., Fletcher, A. M., Main, D. M. G. & Prophet, A. S. The etiology, exfoliative cytology and treatment of denture stomatitis. *J. Prosthet. Dent.* 1969, 22, 185-200
38. Shafer, W. G., Hine M. K. & Levy, B. M. A Textbook of Oral Pathology. 3rd ed. W. B. Saunders, Philadelphia, 1974
39. Squier, C. A., Waterhouse, J. P. & Kraucunas, E. The application of stereological methods for studying the effects of differing fixative osmolalities on the intercellular space of oral epithelium. I. Normal epithelium. *J. Oral Pathol.* 1973, 2, 127-135
40. Stohler, C. S. & Geering, A. H. The aetiology of denture stomatitis. In: The proceedings of the European Prosthodontic Association. Third annual meeting, Örenäs, Sweden, 1979, pp. 68-71
41. Theilade, J. & Budtz-Jørgensen, E. Electron microscopic study of denture plaque. *J. Biol. Buccale* 1980, 8, 287-297
42. Waldron, C. A. Oral epithelial tumours. In: Gorlin, R. J. & Goldman, H. M., eds. *Thomas oral pathology*, 6th ed. 1970, pp. 804-805
43. Van Reenen, J. F. Microbiologic studies on denture stomatitis. *J. Prosthet. Dent.* 1973, 30, 493-505
44. Williamson, D. M. Chronic hyperplastic candidiasis and squamous carcinoma. *Br. J. Dermatol.* 1969, 81, 125-127
45. Winner, H. I. An experimental approach to the study of infections by yeast-like organisms. *Proc. R. Soc. Med.* 1958, 51, 496-499
46. WHO. Application of the International Classification of Diseases to Dentistry and Stomatology (ICD-DA), 2nd ed. World Health Organization, Geneva, 1978
47. WHO. Collaborating Centre for Oral Precancerous Lesions. Definition of leukoplakia and related lesions: an aid to studies on oral precancer. *Oral Surg.* 1978, 46, 518-539

Received for publication 21 September 1981