

# Oral malignant and premalignant changes in 'Shammah'-users from the Gizan region, Saudi Arabia

Gamil Salem, Ruth Juhl and Torben Schiødt

King Fahd Central Hospital, Departments of Dentistry and Histopathology, Gizan, Saudi Arabia

Salem G, Juhl R, Schiødt T. Oral malignant and premalignant changes in 'Shammah'-users from the Gizan region, Saudi Arabia. *Acta Odontol Scand* 1984;42:41-45. Oslo. ISSN 0001-6357.

A survey of the oral mucosa in 661 of the people living in various geographical locations of the Gizan region has been carried out. Mucosal lesions compatible with 'oral leukoplakia' have been found to affect approximately 68% of the users of the native snuff known as 'Shammah'. The lesions were almost always at the site where 'Shammah' was habitually held. Histological examination of biopsy specimens obtained from 29 different individuals revealed squamous cell carcinoma in 7 cases and carcinoma in situ in 2 cases, whereas the remaining specimens showed ortho- and para-hyperkeratosis, some of which also had premalignant changes. The results of this study point to a possible causal relationship between the use of 'Shammah' and the development of oral premalignant and malignant lesions among snuff-dippers in the Gizan region. □ *Leukoplakia; snuff; squamous cell carcinoma; tobacco*

Ruth Juhl, Rebæk Søpark 3, DK-2650 Hvidovre, Denmark

Oral cancer is a major health problem, responsible for a large number of cases of death and infirmity. It has been estimated that 24,000 cases of oral cancer were diagnosed in the United States in 1974 and that 7600 Americans die of the disease each year (1). On the other hand, many of those who survive remain crippled or disabled in spite of the recent advances in medical sciences. The literature on the significance of some oral mucosal lesions for development of mouth cancer (2) reveals sufficient evidence of the contribution of leukoplakia, erythroplakia, and related lesions in the pathogenesis of oral malignancy.

Epidemiologic studies (3-6) have shown a widespread incidence of oral cancer and premalignant lesions in some geographic localities, especially in India, Southeast Asia, Papua and New Guinea. Also reported was the positive correlation between the development of such lesions and the adoption of certain habits, particularly betel nut chewing and the consumption of tobacco in various forms.

Clinical observations by one of the authors (G. Salem) over a period of 2 years in the Gizan region revealed the widespread incidence of carcinoma of the mouth and tongue

in that area. Some recent reports (7, 8) point to the same observations and try to connect it with the popular use of a local snuff or 'Shammah'. 'Shammah' is the native name for a type of snuff used by the population in some parts of the southern region of Saudi Arabia. It is prepared by mixing the powdered tobacco leaves with hydrated sodium carbonates (7) in certain proportions. The material, a greenish yellow powder, is placed in the buccal or lower labial vestibule of the mouth for various periods to allow the active ingredients to be absorbed through the oral mucosa. 'Shammah' dipping is a socially accepted habit in this region of Saudi Arabia. Although prohibited by law, it is widely practiced by both males and females from early adolescence. It has also been reported that the diagnosed cases of oral cancer in Saudi Arabia were very advanced to a degree that made effective treatment problematic (8).

In the USA and in Europe the patient normally presents for treatment at an earlier stage of the disease than the patient in Saudi Arabia (8). It is therefore theoretically and practically possible, within the framework of present-day knowledge, to improve the survival rate and prevent much of the morbidity in Saudi Arabia caused by oral

cancer through early diagnosis and detection of premalignant lesions in the oral cavity.

The purpose of this study was to survey the oral mucosa of the population in two geographically different locations in the Gizan region for the detection of any pre-malignant and malignant oral mucosal lesions.

## Materials and methods

A total of 661 individuals were examined in two geographically different locations of the Gizan region. Five hundred and thirty-eight individuals of the study sample lived on Farassan Island, about 70 km to the southwest of the main city of Gizan, and 123 lived in the villages of Al-Ahad and Samta districts, in the southern sector near the Yemini frontiers. The study was performed along with a comprehensive health survey of Farassan Island and the southern sector of the Gizan region. The authors joined the health campaign in these districts, and the examination was carried out along with the Oral Health Survey. Only individuals who were 15 years or more were included in this study.

Examination of the oral mucosa was made in daylight with the aid of a pair of mouth mirrors (Martin No. 4). All examinations were done by the same person (G. Salem). Well-demarcated, elevated white patches of 5 mm or more on the oral mucosa which could not be scraped off, in accordance with the definition of WHO Collaborating Center for Oral Precancerous Lesions, Definition of Leukoplakia and Related Lesions and Aid to Studies on Oral Precancer (9), were identified. The presence of mucosal lesions and their location were recorded with the aid of the diagram presented by Roed-Petersen & Renstrup (10) for the topography of the oral mucosa. After examination was completed and the results of inspection of the oral mucosa were recorded, the individuals were questioned by another person about their habits with regard to the use of tobacco or other materials in the oral cavity, and the results were recorded.

In addition to these, 10 male and female individuals who had been referred from The

Southern Region to the Dental Department, King Fahd Central Hospital, with oral mucosal lesion (7 with carcinoma) were also included in the study and were examined in the same manner. Thirty biopsy specimens representing lesions from different anatomical locations were obtained from 30 different individuals after their permission had been obtained. The specimens were obtained with the subjects under local anesthesia, using 3% prilocaine (Citanest®) with octapressin.

The biopsy specimens were fixed in 10% formalin solution, embedded in paraffin, and sectioned at 3 µm. The sections were all stained with hematoxylin-eosin and with van Gieson-Hansen stain for connective tissue. Some sections were stained with orcein for elastic tissue. Dysplastic changes were defined as by WHO (9).

## Results

### *Clinical findings*

Oral mucosal lesions that have been diagnosed clinically as 'leukoplakia' (Fig. 1) were observed in 78 individuals or 15% of the

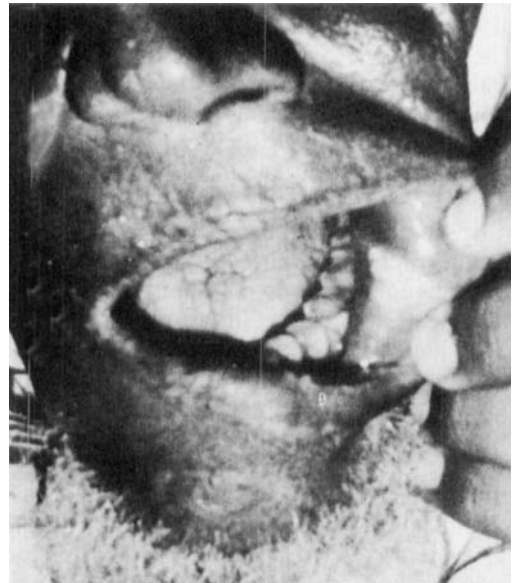

Fig. 1. Leukoplakia on cheek. Man, 60 years old.

Table 1. 'Shammah' use and lesions in different age groups examined in the southern sector and the Farassan Island

Region	Age group (years)	'Shammah' users		Non-'Shammah' users		Total	
		-Lesions	+Lesions	-Lesions	+Lesions	-Lesions	+Lesions
Southern sector	15-39	11	3	27	0	38	3
	40-59	5	26	15	0	20	26
	≥60	8	22	6	0	14	22
	Total	24	51	48	0	123	
Farassan Island	15-39	16	32	258	0	274	32
	40-59	12	38	99	0	111	38
	≥60	6	8	69	0	75	8
	Total	34	78	426	0	538	

Table 2. Sex and age distribution of oral mucosal lesions among 'Shammah' users in two different regions

Region	Sex	Age group (years)			Total
		15-39	49-59	≥60	
Southern Sector (Samtah and Al-Ahad)	Male	0	16	15	51
	Female	3	10	7	
Farassan Island	Male	17	17	8	78
	Female	15	21	0	

Table 3. Correlation between placing of 'Shammah' and location of lesion in 129 persons

Lesion present	'Shammah' powder placed in			Total
	Left side	Right side	Left and right side	
Left cheek or lower lip	68	0	3	71
Right cheek or lower lip	0	41	1	42
Left and right	0	0	9	9
Others (mouth floor, tongue)	4	2	1	7

population examined on Farassan Island and in 51 or 42% in the southern sector. The age and sex distribution of the lesions are shown in Tables 1 and 2. There was a statistically significant higher frequency of lesions in the older age group ( $p < 0.05$ , Mann-Whitney

test). When the findings were compared with tobacco habits, it was found that almost all the individuals with oral mucosal lesions had been using 'Shammah' persistently for more than 5 years, whereas none of those who only smoked cigarettes developed a lesion.

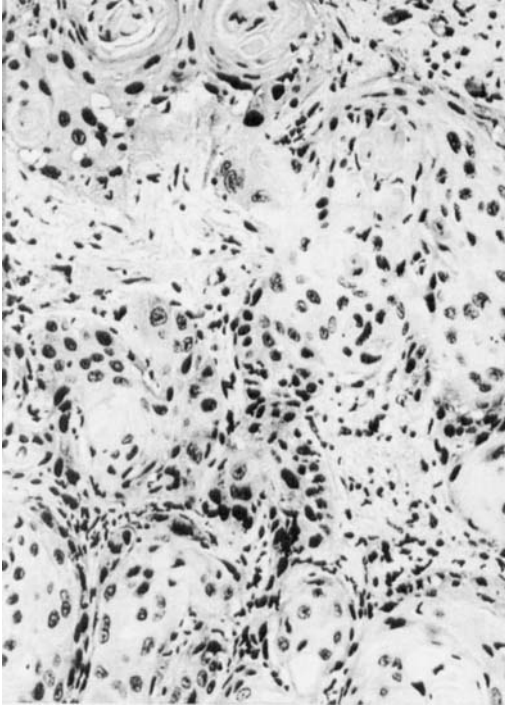


Fig. 2. Squamous cell carcinoma of moderate differentiation. (H&E,  $\times 184$ .)

The location of the lesions varied among individuals, but the majority of the lesions occupied the lower labial mucosa or the buccal mucosa. Because some patients devel-

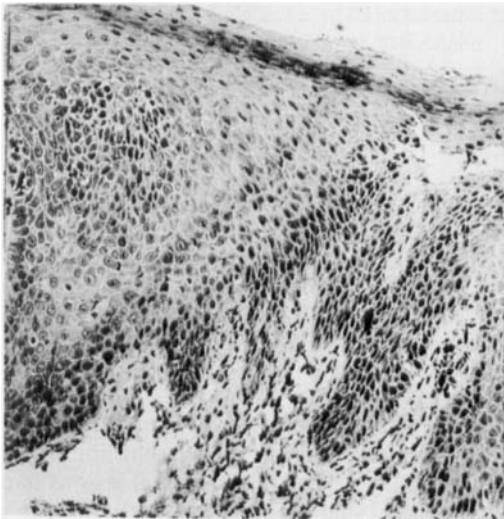


Fig. 3. Oral mucosa with parakeratosis and dysplasia of mild grade. (H&E,  $\times 184$ .)

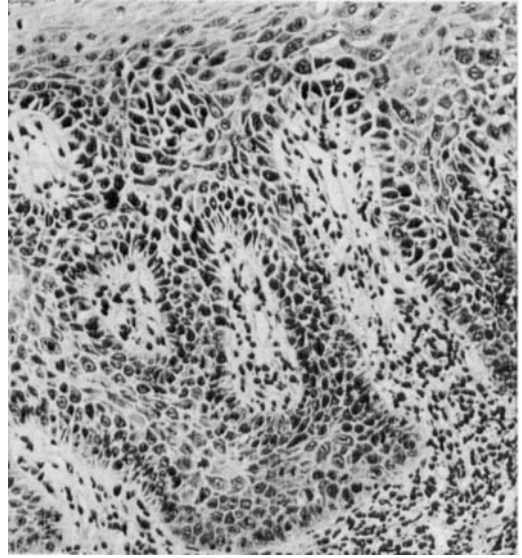


Fig. 4. Oral mucosa with dysplasia of moderate grade. (H&E,  $\times 184$ .)

oped more than one lesion in different locations of the oral cavity, the number of lesions by far exceeded the number of the individuals examined. The mucosal lesions were found always to be present at the site where 'Shammah' was habitually held (Table 3). The surface of the lesion was frequently stained yellow to brown, at times with remnants of 'Shammah' still in place. When the lesion affected the lower labial mucosa, prominence of the minor salivary glands in this region with the development of red-point spots corresponding to the openings of these glands was a common observation. The teeth were usually stained dark brown with severe recession of the gums and consequently with marked mobility or loss of the teeth. The occlusal surfaces were always the site of severe attrition.

The seven referred carcinoma cases are patients who all had used 'Shammah' for many years. Only one patient had a remote metastasis to the lung.

#### *Histopathological findings*

Thirty biopsy specimens were obtained from 30 patients. Most of the specimens were obtained from male individuals, since it has

been difficult to obtain permission to take specimens from females. One of the specimens was for technical reasons unfit for histological examination. Seven specimens, all from referred hospital patients, displayed squamous cell carcinoma, most of which were moderate or highly differentiated (Fig. 2). Two cases showed carcinoma in situ changes, both from the Al-Ahad-Samta region, but one of them had also cancer of the tongue with a large metastasis to the neck. The histological changes in the 22 leukoplakia patients, including the 2 with severe dysplasia—that is, carcinoma in situ—comprised hyperparakeratosis as the most constant finding, in most cases combined with epithelial hyperplasia. Atrophy was demonstrated in four specimens, and severe fibrosis of the submucosa in four specimens as well, one of which showed atrophy and two of which showed dysplasia in addition. Most of the cases with dysplastic changes showed a mild dysplasia only (Fig. 3). The higher grades of dysplasia (Fig. 4) were found in the older age group.

## Discussion

Our hypothesis was that a causal relation exists between the use of 'Shammah' and the mucosal lesions found in the oral cavity. The present results support our hypothesis.

Our view is based not only on the high correlations we found between 'Shammah' use and oral lesions, since a correlation only cannot be considered as proof. We have also presented other evidence to support the hypothesis; that is, the lesions were mostly located at the site where 'Shammah' powder was placed. This finding would not be expected if a causal relation was not present. Furthermore, no relation between smoking habits and presence of lesions was found, but the figures concerning this point are rather small.

Mucosal lesions were even found in young people, but in 'Shammah'-users only. This might be due to a higher susceptibility to 'Shammah' in some individuals. However,

it should be emphasized that we have no intention of proving that all lesions are caused by the use of 'Shammah'. Generally we found a statistically higher frequency of lesions in the older age group, which can be interpreted as a relation between frequency of lesions and duration of 'Shammah' use. No explanation can be offered to explain the finding that the frequency of oral lesions among 'Shammah'-users is less on the Farassan Island than in the southern region.

On the basis of the present findings, it is concluded that a causal relation exists between the use of 'Shammah' and the development of lesions of the oral mucosa. It is recommended that the population in the area should stop using 'Shammah'.

## References

1. American Cancer Society. Oral Cancer Statistics. *J Oral Surg* 1973;31:495-498.
2. Pindborg JJ, Metha FS, Daftary DK. Incidence of oral cancer among 30,000 villagers in India in a 7-year follow-up study of oral precancerous lesions. *Community Dent Oral Epidemiol* 1975;3(2):86-88.
3. Goldblott LI. Leukoplakia & erythroplakia—early oral cancer. *J Indiana Dent Assoc* 1978;57:18-29.
4. Peacock EE Jr, Greenberg BG, Brawley BW. The effect of snuff and tobacco on the production of oral carcinoma: an experimental and epidemiological study. *Ann Surg* 1960;151:542-550.
5. Pindborg JJ, Barmes D, Roed-Petersen B. Epidemiology and histology of oral leukoplakia and leukodema among Papuans and New Guineans. *Cancer* 1968;22:379-384.
6. Renstrup G. Leukoplakia of the oral cavity. *Acta Odontol Scand* 1958;16:99-111.
7. Ageel AM, Salem GM. The relation between local effects of 'Shammah' storage in the buccal cavity and malignancy. 1981. Paper presented to 8th International Congress for Pharmacology, Tokyo, Japan, 1980.
8. Zahran FM, Jamjoom AM, Eed MD. Surgery of advanced cancer of head and neck. *University Book, Secaucus, New Jersey*, 1981.
9. WHO Collaborating Reference Centre for Oral Precancerous Lesions. Definition of leukoplakia and related lesions: an aid to studies on oral precancer. *Oral Surg* 1978;46:518-539.
10. Roed-Petersen B, Renstrup G. A topographical classification of the oral mucosa suitable for electronic data processing. Its application to 560 leukoplakias. *Acta Odontol Scand* 1969;27:681-895.