

Bilateral degenerative changes and deviation in form of temporomandibular joints

An autopsy study of elderly individuals

Sigvard Åkerman, Madeleine Rohlin and Sigvard Kopp

Department of Stomatognathic Physiology and Department of Oral Radiology, School of Dentistry, University of Lund, Malmö, Sweden

Åkerman S, Rohlin M, Kopp S. Bilateral degenerative changes and deviation in form of temporomandibular joints. An autopsy study of elderly individuals. *Acta Odontol Scand* 1984;42:205–214. Oslo. ISSN 0001–6357.

The right and left temporomandibular joints were removed as blocks from the skulls of 22 individuals in the 60–89-year-old age group at autopsy. The skulls were examined to determine the number and position of teeth and dentures. The articular surfaces of the joints were examined macroscopically for topographical distribution and degree of degenerative changes and topographical distribution of deviation in form. Indices of degenerative changes and of deviation in form were proposed. Correlations were found between the right and left joints with respect to both indices for degenerative changes and deviation in form. The indices were also correlated with each other within the same joint. A sex difference was found for degenerative changes and deviation in form, with the most advanced changes in the joints of women. It was concluded that degenerative changes and deviation in form in this age group were correlated between right and left joints and within the same joint. □ *Osteoarthritis; temporomandibular joint syndrome*

Sigvard Åkerman, Department of Stomatognathic Physiology, School of Dentistry, Carl Gustavs väg 34, S-214 21 Malmö, Sweden

Investigations concerning normal and pathologic anatomy of the human temporomandibular joint (TMJ) have shown that degenerative changes and deviation in form are fairly common, particularly above 40 years of age (1–3). Degenerative changes and deviation in form in the TMJ are suggested to be caused mainly by mechanical overloading of the joint, e.g. loss of molar support (2–4). According to Wright (5) there is evidence from examination of other joints to suggest that, while age changes of cartilage are indistinguishable from degenerative changes, there may be a difference in the extent of their progression. Exposure of underlying bone might be a characteristic and important feature of degenerative changes but may not be attributed to changes in age. Thus, Byers et al. (6) found that the progressive degenerative lesions affected only 4% of a Caucasian population, whereas the non-progressive lesions affected 80% of this population in the 7th decade. This probably has implications also for degenerative

changes of the TMJ, and it would be helpful if degenerative changes would be described in greater detail and, if possible, subdivided into non-progressive and progressive degenerative changes.

Most of the hitherto presented autopsy studies of articular surfaces of the TMJ have been concerned with unilateral analysis. There is thus a minimum amount of information about the relationship between the two TM joints in the same individual.

The specific aim of this study was to investigate the *intraindividual* relationships between degenerative changes and deviation in form of the articular surfaces of the TMJs and their degree and topographical distributions.

Materials and methods

The right and left TMJs were removed from 22 individuals, 9 women (mean age, 77 years) and 13 men (mean age, 74 years), who before

Table 1. Distribution of age, sex, complete dentures, number of teeth, index of degenerative changes (DC_i) and index of deviation in form (DIF_i) in the 22 individuals

Age, years	Sex	Complete dentures upper/lower*	No. of remaining teeth	No. of occluding pairs of molars	DC _i	DIF _i
60	M		23	1	1	21
66	M		26	3	6	17
68	M	+/	9		7	30
70	M		17	1	5	12
71	M	+/+	0		15	38
73	M	+/+	0		43	45
74	M	+/-	0		15	39
75	M		20	2	6	8
76	M	+/+	0		4	22
77	M		7	†	11	45
80	M		21	2	3	20
80	M	-/-	0		4	41
86	M		16		66	40
67	F	+/+	0		143	76
67	F		24	1	300	100
70	F	+/+	0		135	57
71	F	+/+	0		12	6
78	F	-/-	0		131	85
81	F		22		187	72
83	F		≥12‡	≥0‡	86	68
85	F	+/	6		48	53
88	F		11		43	54

* + = present; - = not present.

† Not possible to record due to extensive caries.

‡ Only right half of the jaws available for dental examination.

death had donated their bodies to research (Table 1). Information of TMJ symptoms before death were not available. The TMJ specimens were fixed in a 10% neutralized buffered formalin solution.

Examination of dental status

The visual examination comprised recording of the number and position of teeth, dentures, and occluding pairs of teeth.

Dissection

In the first five individuals the condyle with attached disc was removed separately from the temporal component, which then was removed. The joints were removed as blocks in the remaining 17 individuals. The joint components were then separated by opening the lower and upper joint compartments laterally, anteriorly, and medially.

The posterior attachment of the disc thus remained intact.

Macroscopic analysis

The articular surface was examined for degenerative changes and deviation in form of sufficient severity to be readily visible to naked-eye examination.

The position and extent of both degenerative changes and deviation in form were recorded on a premade map of the condyle, disc, and temporal component. Degenerative changes and deviation in form were recorded in those areas presented in Table 2.

Degenerative changes

Degenerative changes in the condyle, disc, and temporal component were classified into four stages in accordance with a modification

Table 2. The percentage of degenerative changes in the recorded areas of the TMJ of 22 individuals. Number of recorded areas are also given

Areas	Lateral			Central			Medial			Total									
	Stage			Stage			Stage			Stage									
	No. of recorded areas	0	1	2	3	No. of recorded areas	0	1	2	3	No. of recorded areas	0	1	2	3				
Condyle																			
Anterior	44	68	7	9	16	44	75	7	7	11	44	73	5	9	14	72	6	8	14
Superior	44	66	0	14	20	44	64	2	16	18	44	75	0	7	18	68	1	12	19
Posterior	43	74	0	9	16	44	80	0	11	9	43	79	0	7	14	78	0	9	13
Total	131	69	2	11	18	132	73	3	11	13	131	76	2	8	15	73	2	10	15
Disc																			
Anterior dense	44	89	0	5	7	44	86	0	7	7	44	91	0	5	5	89	0	5	6
Middle dense	44	68	0	14	18	44	77	0	11	11	44	84	0	7	9	77	0	11	13
Posterior dense	44	70	0	11	18	44	77	7	7	9	44	80	5	7	9	76	4	8	12
Posterior soft	10	0	0	20	80	8	0	0	25	75	4	0	0	0	100	0	0	18	82
Total	142	70	0	11	19	140	76	2	9	13	136	82	1	6	10	76	1	9	14
Temporal component																			
Anterior slope	39	74	13	0	13	40	75	12	0	12	40	85	5	0	10	78	10	0	12
Inferior part	43	58	19	2	21	44	73	9	5	14	44	86	5	0	9	73	11	2	15
Posterior slope	43	63	14	2	21	44	75	7	7	11	44	86	5	0	9	75	8	3	14
Roof of fossa	41	83	0	2	15	43	81	2	2	14	43	86	0	2	12	83	1	2	13
Wall of fossa	15	80	0	0	20	15	80	0	0	20	16	75	0	6	19	78	0	2	20
Total	181	70	10	2	18	186	76	7	3	13	187	85	3	1	11	77	7	2	14

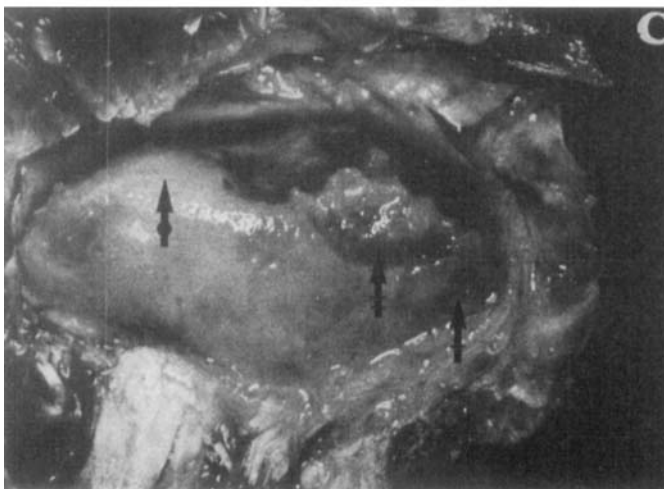
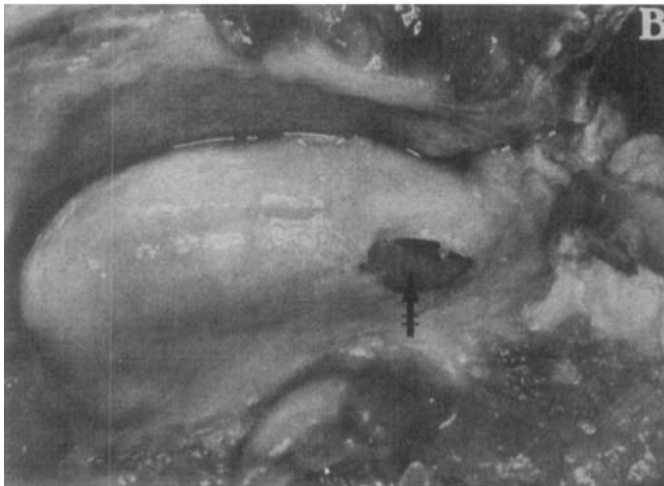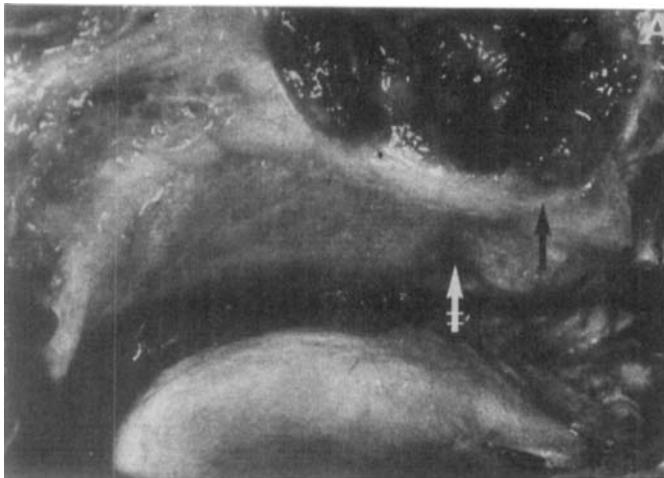


Fig. 1. Degenerative changes and deviation in the form of the temporal component (A), disc (B), and condyle (C) in the left TMJ of an 81-year-old individual. Degenerative changes of stage 1 are indicated by \rightarrow , of stage 2 by \leftrightarrow , of stage 3 by $\leftrightarrow\leftrightarrow$, and deviation in form by \blacklozenge .

of the principles of Byers et al. (6) (Fig. 1A–1C): 0 = no changes of the type described below; 1 = superficial flaking or fraying; 2 = local reduction of soft tissue layer; and 3 = total loss of soft tissue with bone exposed, or perforation of the disc.

An index for degenerative changes (DC_i) was calculated by the following formula:

$$DC_i = \frac{\text{sum of changes stages 1-3}}{\text{total no. of areas recorded}} \times 100.$$

Deviation in form

In accordance with the principles of Öberg et al. (3) deviation in form was defined as local, marked irregularities of form of the articular surface. The presence of deviation in form was recorded in the condyle and the temporal component (Fig. 1C).

An index for deviation in form (DIF_i) was calculated by the following formula:

$$DIF_i = \frac{\text{no. of areas with deviation in form}}{\text{total no. of areas recorded}} \times 100.$$

Size of joint components

The size of the joint components was

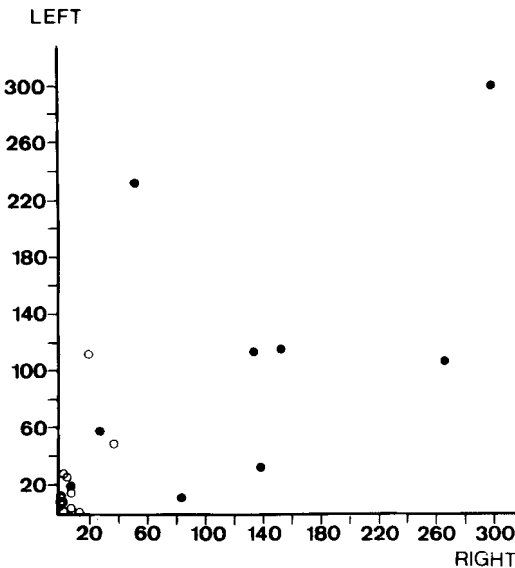


Table 3. Topographical distribution of disc perforations in 16 discs from 11 individuals

Side	Posterior soft	Posterior dense	Middle dense	Anterior dense
Right		LCM		
Left	LCM			
Right	LC	M		
Left		L	M	
Right		LC	LC	L
Left	L	L		
Right			LCM	
Left			L	
Right	LCM	LCM	LCM	LCM
Left	LCM	LCM	LCM	LCM
Right	LC	L	L	
Right			LC	
Right	L			
Right			L	
Left	LCM			
Left		L		

L = lateral third of disc; C = central third of disc; and M = medial third of disc.

Perforation of the disc was seen in 16 joints out of 44 (36%), and the topographical distribution is shown in Table 3.

Deviation in form

Deviation in form was found in 400 out of 949 areas (42%) in 42 out of 44 joints

Table 4. Topographical distribution of deviation in form in different areas of the TMJ of 22 individuals, expressed in percentage of the total number of recorded areas

	Lateral	Central	Medial	Total
Condyle				
Anterior	55	43	34	44
Superior	71	64	52	62
Posterior	56	43	42	47
Total	60	50	43	51
Temporal component				
Anterior slope	41	58	35	45
Inferior part	49	57	39	48
Posterior slope	44	34	34	37
Roof of fossa	17	16	16	16
Wall of fossa	27	27	31	28
Total	37	40	31	36

(96%). The topographical distribution of deviation in form is shown in Table 4. Of all recorded areas on the condyle 51% were deviated in form, compared with 36% for the temporal component. Deviation in form of the condyle was most frequently found on the superior surface of the lateral and central thirds. In the temporal component, the central and lateral thirds of the interior part of the eminence and the central third of the anterior slope of the eminence most frequently showed deviation in form. The correlation between the indices for deviation in form of the right and left joints was statistically significant ($r_s = 0.61$, $p < 0.01$) (Fig. 3).

Sex distribution

There were statistically significant differences ($p < 0.001$) between men and women with regard to both the index for degenerative changes and deviation in form. The most advanced changes were thereby found in the joints of women (Table 1, Figs. 2-4).

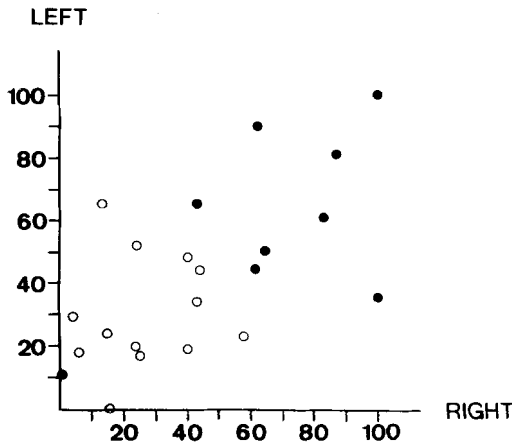


Fig. 3. Distribution of index of deviation in form between the right and left TMJ (no. = 22, $r_s = 0.61$, $p < 0.01$; (○) = men, (●) = women).

Dental status

The number of teeth and occluding pairs of molars and the presence of dentures are shown in Table 1. Nine individuals were edentulous. In one individual it was not pos-

sible to evaluate the number of occluding pairs of teeth owing to extensive caries.

Correlations between degenerative changes and deviation in form

The indices for degenerative changes and deviation in form were correlated to each other ($r_s = 0.83$, $p < 0.001$) (Fig. 4). Out of 714 areas without degenerative changes on the condyle and the temporal component, only 185 (26%) were deviated in form. Degenerative changes and deviation in form were both most frequently seen on the superior surface of the lateral and central thirds of the condyle. Out of 48 areas with stage-1 degenerative changes on the condyle and temporal component 38 (79%) were deviated in form, out of 50 areas of stage-2 changes 46 (92%) were deviated, and out of 137 areas of stage-3 changes 132 (96%) were deviated.

Size of joint components

The mean value of the mediolateral dimension of the condyle was 20.5 mm (range, 12.5–26.2) and of the mandibular fossa 24.0 mm (range, 19.6–29.4). The anteroposterior dimension of the condyle was laterally 7.9 mm (range, 5.0–11.6), centrally 9.2 mm (range, 7.0–15.0), and medially 7.8 mm (range, 4.2–13.2). The difference in size between the mediolateral dimension of the mandibular fossa and the condyle of the individual joints (mean, 2.8 mm; range, -0.2–8.6) did not correlate significantly with the index of degenerative changes or the index of deviation in form.

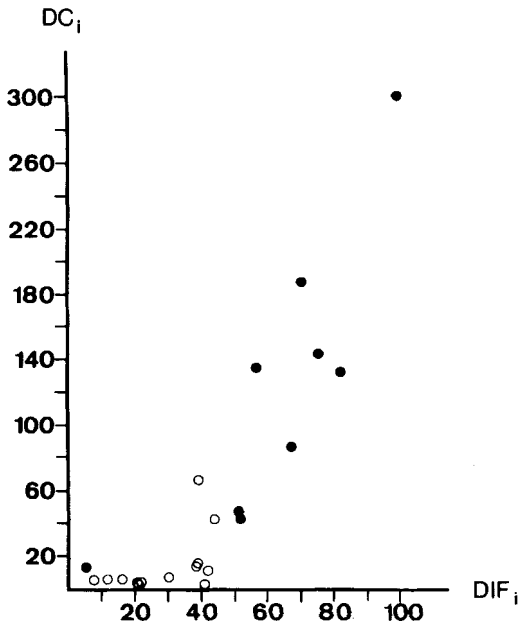


Fig. 4. Correlation between index of degenerative changes (DC_i) and deviation in form (DIF_i) (no. = 22, $r_s = 0.83$, $p < 0.001$; (○) = men, (●) = women).

Discussion

The reproducibility of evaluation of degenerative changes in accordance with a similar grading system has been investigated previously for the TMJ (8). Repeated evaluation of 10 TMJs in 3 components were in complete agreement for 28 out of 30 double determinations, whereas 2 differed by 1 grade. Visual judgement of the appearance of the articular surface therefore has an

acceptable reproducibility when a similar grading system is applied.

The correlation between the right and left TMJs concerning indices for degenerative changes and deviation in form indicates that both degenerative changes and deviation in form often are bilateral in advanced age, although symptoms often develop unilaterally (9). Reasons for this correlation could be genetic, or it could be that the loading conditions had been similar on both sides. The right and left condyles are part of the same movable mandible. The TMJ of one side thus cannot function without movement and loading of the contralateral joint (10).

Since the topographical distribution of superficial flaking or fraying and the local reduction of the soft tissue layer has not previously been reported separately in studies of TMJ autopsy specimens, it is impossible to compare the detailed frequency of degenerative changes in this study with the figures of previous studies. However, in this study, joints with degenerative changes were more numerous (84%) than in previous studies of joints from individuals aged 60 years and above. Öberg et al. (3) reported a frequency of arthrotic changes in the TMJ of 24%, and Westesson & Rohlin (11) a frequency of 42%. Previous autopsy studies imply that only a few individuals avoid degenerative changes in the hip and knee joints (6, 12, 13). To judge from the present study, the same condition seems to prevail also for the TMJ. Considering only the frequency of joints with bone exposure and/or perforation of the disc, our figures were similar to those of Westesson & Rohlin (11) (43% as compared with 42%).

In our study the degenerative changes were evenly distributed in the condyle, disc, and temporal component, in contrast to the study by Öberg et al. (3), in which the disc and temporal component were most frequently involved. Our findings thus do not support the suggestion that degeneration usually first involves the disc and then the temporal component (3).

In the TMJ the topographical distribution of superficial flaking and fraying has not previously been studied separately, whereas this phenomenon, also called fibrillation, has

been mapped out for several other joints (6, 14–16). In other joints certain cartilage fibrillation is non-progressive (17). Byers et al. (6) and Meachim & Emery (16) pointed out that there is probably a difference between non-progressive and progressive cartilage fibrillation. This distinction was impossible to make in the present study. However, changes of stages 2 and 3 implicate loss of articular tissue and therefore might represent progressive lesions, whereas stage-1 changes may be partly non-progressive alterations. Goodfellow & Bullough (18) have pointed out that areas of the articular surface in the knee joint, which ordinarily carry little load, acquire degenerative changes but that they rarely advance beyond overt fibrillation.

The finding that bone exposure and perforation of the disc occurred oftener in the lateral third than in the central and medial thirds of the joint is in accordance with previous studies (3, 10, 11), although the predominance of these lateral changes was not that pronounced in this study except for the disc. Perforation of the disc was never seen separately in the central or medial thirds but always occurred with lateral perforation. In this study perforations were found in the posterior soft part of the disc just as often as in the posterior and middle dense parts, in contradiction to the study by Öberg et al. (3), in which the disc never was perforated in the posterior part. This difference in distribution might depend on different ways in dissecting the joint—for example, the preservation of the posterior attachment in the present study.

Deviation in form was more frequent in the condyle than in the temporal component, as has been shown earlier by Blackwood (1), Öberg et al. (3), and Carlsson & Öberg (19). Deviation in form was, however, found more frequently in the present study, 51% of recorded areas on condyle and 36% on the temporal component as compared with 42% and 23%, respectively, in the study by Öberg et al. (3). In the present study deviation in form was recorded separately from degenerative changes, resulting in a higher frequency of deviation in form. Degenerative changes and deviation in form were found to be

strongly and positively correlated to each other, which corroborates the results of Öberg et al. (3) and Carlsson & Öberg (19). One probable explanation of this correlation is that the two conditions have etiologic factors in common, such as age and changed functional loading conditions. Similar to the present study, degenerative changes of TMJs of women were more frequent also in the studies of autopsy specimens by Blackwood (1) and Öberg et al. (3). Deviation in form in this study was more frequent in joints of women, which was not the case in the study by Öberg et al. (3). In an interview survey of the Swedish population and a review of previous studies Bjelle (20) found that the prevalence of osteoarthritis among women after 65 years of age was higher than among men, whereas the prevalence figures for men and women were similar before this age. The sex difference with regard to degenerative changes might be attributable to inherent sex differences in articular cartilage, as proposed by Freeman & Meachim (21)—for example, different fatigue failure of collagen fibre network for men and women.

The average size of the joint components was similar to those reported by Yale et al. (22) and Öberg et al. (3) for individuals above 60 years of age. The anteroposterior dimension of the condyle found centrally in this study corroborates the findings by Öberg et al. (3), who measured the largest anteroposterior diameter of the condyle. It could not be shown that discrepancies in size of the condyle and temporal component—that is, that the temporal component is either too wide or too narrow for the condyle—are correlated to degenerative changes or deviation in form of the joint.

It can be concluded from the results that degenerative changes and deviation in form of the TMJ in this age group are correlated between right and left joints and also that degenerative changes and deviation in form are correlated within the same joint.

Acknowledgements.—The autopsy material was kindly put at our disposal by the Department of Anatomy, University of Lund. This investigation was supported by grants from the Faculty of Odontology, University of Lund, Malmö, Sweden.

References

1. Blackwood HJJ. Arthritis of the mandibular joint. *Br Dent J* 1963;115:317–326.
2. Kopp S. Topographical distribution of sulfated glycosaminoglycans in the surface layers of the human temporomandibular joint. A histochemical study of an autopsy material. *J Oral Pathol* 1978;7:283–294.
3. Öberg T, Carlsson GE, Fajers CM. The temporomandibular joint. A morphologic study on a human autopsy material. *Acta Odontol Scand* 1971; 29:349–384.
4. Mongini F. Remodelling of the mandibular condyle in the adult and its relationship to the condition of the dental arches. *Acta Anat* 1972;82:437–453.
5. Wright V. The management of degenerative joint disease—an introduction. *Scand J Rheum* 1980(suppl 43):7–11.
6. Byers PD, Contepomi CA, Farkas TA. A post mortem study of the hip joint. Including the prevalence of the features of the right side. *Ann Rheum Dis* 1970;29:15–31.
7. Siegel S. *Nonparametric statistics for the behavioral sciences*. Tokyo: McGraw-Hill Kogakusha Ltd, 1956.
8. Kopp S, Carlsson GE, Hansson T, Öberg T. Degenerative disease in the temporomandibular, metatarsophalangeal and sternoclavicular joints. An autopsy study. *Acta Odontol Scand* 1976;34:23–32.
9. Carlsson GE, Svärdröm G. Ett bettfysiologiskt patientmaterial. *Swed Dent J* 1971;64:889–899.
10. Du Brul EL. The craniomandibular articulation. In: Sicher, ed. *Oral anatomy*. St Louis: C V Mosby Co., 1980; Chapter 4, 174–209.
11. Westesson PL, Rohlin M. Internal derangement related to osteoarthritis in temporomandibular joint autopsy specimens. *Oral Surg* 1984;57:17–22.
12. Meachim G. The state of knee meniscal fibrocartilage in Liverpool necropsies. *J Pathol* 1976; 119:167–173.
13. Stankovic A, Mitrovic D, Ryckewaert A. Prevalence of the degenerative lesions in articular cartilage of the human knee joint. Relationship with age. In: Peyron JG, ed. *Epidemiology of osteoarthritis*. Rueil-Malmaison: Geigy, 1981;94.
14. Meachim G. Light microscopy of indian ink preparations of fibrillated cartilage. *Ann Rheum Dis* 1972;31:457–464.
15. Meachim G. Age-related degeneration of patellar articular cartilage. *J Anat* 1982;134:365–371.
16. Meachim G, Emery IH. Cartilage fibrillation in shoulder and hip joints in Liverpool necropsies. *J Anat* 1973;116:161–179.
17. Radin EL. The physiology and degeneration of joints. *Semin Arthritis Rheum* 1972–73;2:245–257.
18. Goodfellow JW, Bullough PG. The pattern of ageing of the articular cartilage of the elbow joint. *J Bone Jt Surg* 1967;49B:175–181.
19. Carlsson GE, Öberg T. Remodelling of the temporomandibular joints. *Oral Sci Rev* 1974;6:53–86.
20. Bjelle A. Epidemiological aspects of osteoarthritis—an interview survey of the Swedish popu-

- lation and a review of previous studies. *Scand J Rheum* 1980 (suppl 43); 35-48.
21. Freeman MAR, Meachim G. Ageing and degeneration. In: Freeman MAR, ed. *Adult articular cartilage*, 2nd ed. London: Pitman, 1979;487-543.
 22. Yale SH, Allison BD, Hauptfuehrer JD. An epidemiological assessment of mandibular condyle morphology. *Oral Surg* 1966;21:169-177.

Received for publication 25 May 1983