

ORIGINAL ARTICLE

## Tooth display and lip position during spontaneous and posed smiling in adults

PIETER VAN DER GELD<sup>1</sup>, PAUL OOSTERVELD<sup>1</sup>, STEFAAN J. BERGÉ<sup>2</sup> & ANNE M. KUIJPERS-JAGTMAN<sup>1</sup>

<sup>1</sup>Department of Orthodontics and Oral Biology, Radboud University Nijmegen Medical Centre, Nijmegen, The Netherlands and <sup>2</sup>Department of Oral and Maxillofacial Surgery, Radboud University Nijmegen Medical Centre, Nijmegen, The Netherlands

### Abstract

**Objective.** To analyze differences in tooth display, lip-line height, and smile width between the posed smiling record, traditionally produced for orthodontic diagnosis, and the spontaneous (Duchenne) smile of joy. **Material and methods.** The faces of 122 male participants were each filmed during spontaneous and posed smiling. Spontaneous smiles were elicited through the participants watching a comical movie. Maxillary and mandibular lip-line heights, tooth display, and smile width were measured using a digital videographic method for smile analysis. Paired sample *t*-tests were used to compare measurements of posed and spontaneous smiling. **Results.** Maxillary lip-line heights during spontaneous smiling were significantly higher than during posed smiling. Compared to spontaneous smiling, tooth display in the (pre)molar area during posed smiling decreased by up to 30%, along with a significant reduction of smile width. During posed smiling, also mandibular lip-line heights changed and the teeth were more covered by the lower lip than during spontaneous smiling. **Conclusions.** Reduced lip-line heights, tooth display, and smile width on a posed smiling record can have implications for the diagnostics of lip-line height, smile arc, buccal corridors, and plane of occlusion. Spontaneous smiling records next to posed smiling records are therefore recommended for diagnostic purposes. Because of the dynamic nature of spontaneous smiling, it is proposed to switch to dynamic video recording of the smile.

**Key Words:** Dental esthetics, dental photography, diagnosis, facial expression, orthodontics

### Introduction

Dentofacial and smile esthetics have become important factors in a patient's motivation for orthodontic therapy [1]. From a dental point of view, an esthetically attractive smile is a harmonious entity of oral components in which the lip-tooth relationships are crucial factors [2,3], and to evaluate these relationships, a smiling record of the patient is required. Traditionally, photography is used for an orthodontic record [4], but new videographic and computer technologies have enabled other diagnostic assessments. Several authors have described a face analysis based on digital videography in which visual constructs such as buccal corridors and smile arc are important in orthodontic treatment planning [5–7]. Most articles are descriptive and therefore do not represent new discoveries compelling orthodon-

tists to apply these methods for better treatments. Studies evaluating the use of digital videography for developing criteria to aid specifically in orthodontic diagnosis are rare [3,8,9].

In the dental field, Tarantili et al. [10] studied lip movements during spontaneous smiling in a sample of children. A videographic method was used. Their findings about the dynamics of the spontaneous smile raised concern about the validity of a single photographic capture for esthetic assessment. With the photographic methods available in the past, however, only the posed smile was considered reproducible [11,12]. The simple and reproducible registration of a social smile is an advantage of the posed smile record. A disadvantage is that posed smiling can be influenced in its expression by the individual's social skills and emotional background

Correspondence: Anne M. Kuijpers-Jagtman, Department of Orthodontics and Oral Biology, Radboud University Nijmegen Medical Centre, 309 Tandheelkunde, P.O. Box 9101, 6500 HB Nijmegen, The Netherlands. Tel: +31 (0)24 361 4005. Fax: +31 (0)24 354 0631. E-mail: orthodontics@dent.umcn.nl

(Received 9 January 2008; accepted 17 March 2008)

ISSN 0001-6357 print/ISSN 1502-3850 online © 2008 Informa UK Ltd. (Informa Healthcare, Taylor & Francis As)  
DOI: 10.1080/00016350802060617

[13]. This can result in an unnatural or asymmetric smile. Examples of emotional factors influencing the posed smile are: shame with one's oral appearance or embarrassment about phobic dental anxiety [14,15]. Those patients can show a learned smile or inhibited smiling by hiding with the lips, hands, or changing the head position. Other examples of interfering emotional factors on posed smiling are feelings of shame from victims of non-disclosed childhood sexual abuse or negative self-esteem of cleft lip and palate patients [16,17].

From the starting point that the spontaneous smile is an authentic emotion compared to posed smiling and therefore a logical focus point in smile diagnostics, a digital videographic measurement method was tested by Van der Geld et al. [18] for reliability during both spontaneous and posed smiling. Central ideas behind this technique were that a spontaneous smile of joy must be recorded precisely at the exact moment, and that recording it should be done with minimal patient interference. The faces of participants were filmed individually during spontaneous and posed smiling. Spontaneous smiles were elicited with the participants watching a comical movie. Lip-line heights and tooth display were measured using a digital videographic method for smile analysis. This measurement method showed high reliability; not just posed smiles but also spontaneous smiles were measured reproducibly. Based on these results, further study was suggested into the relevance of this video technology for practical diagnostic concerns. The question remains whether videographic spontaneous smiling records are complementary to posed smiling records for orthodontic diagnosis. In an evaluation of lip-tooth characteristics during speech and posed smiling in adolescents, Ackerman et al. [8] proposed viewing the dynamics of anterior tooth display as a continuum delineated by the time-points of rest, speech, posed social smile, and the spontaneous smile. However, since no data are available on differences between adult lip-tooth relationships during spontaneous and posed smiling, the aim of this study was to analyze differences in tooth and gingival display and lip-line heights between the spontaneous smile of joy and the posed social smile.

## Material and methods

### Participants

Of 1069 military men at an airforce base, 122 were randomly selected from three age cohorts (20–25 years; 35–40 years; 50–55 years). Inclusion criteria were full maxillary and mandibular dental arches up to and including the 1st molar and Caucasian race. The research proposal was approved by the ethics committee of the Academic Centre of Dentistry in Amsterdam. Informed consent was obtained from

the participants in accordance with the guidelines of that institution.

### Videographic measurement of spontaneous smiling and posed smiling

A digital videographic measurement method was used to capture records of a spontaneous smile of joy and a posed social smile (Figure 1). This method had been extensively tested for measuring tooth display and lip position during spontaneous and posed smiling, showing intra-class coefficients ranging from 0.99 to 0.80 [18]. In addition, a full dentition record with the aid of cheek retractors was made.

On the full dentition record, tooth length was measured to obtain the actual length of tooth crowns. On the spontaneous and posed smiling records, the display of the teeth and gingiva was measured. In the maxilla and mandible, a central and lateral incisor, a canine, a 1st and 2nd premolar, and a 1st molar were measured. The most incisal points of each tooth (line 1) and the lip edge (line 2) were marked with a digital horizontal line parallel to the pupil line (Figure 2). The vertical distance between these lines was measured (Figure 2).

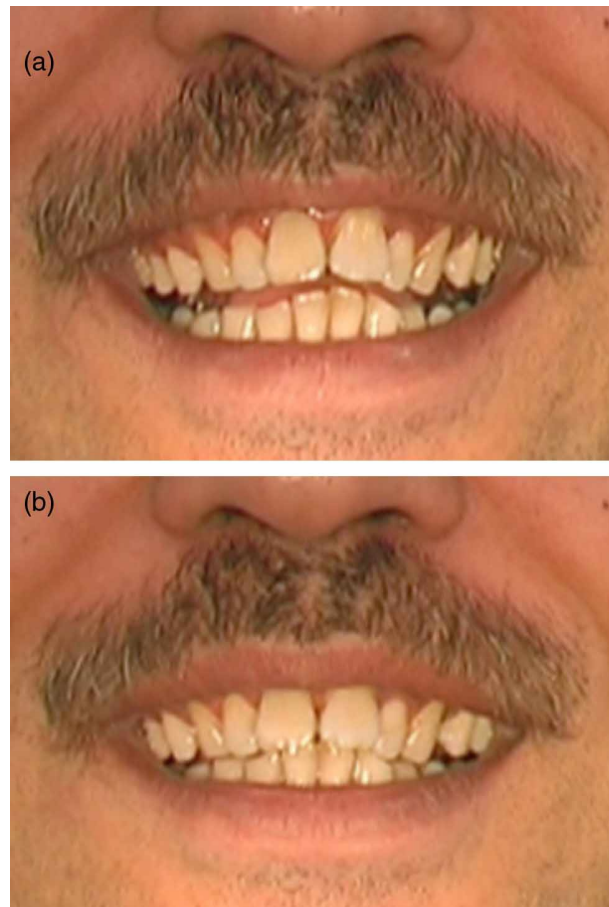

Figure 1. Examples of (a) a spontaneous smile and (b) a posed smile.

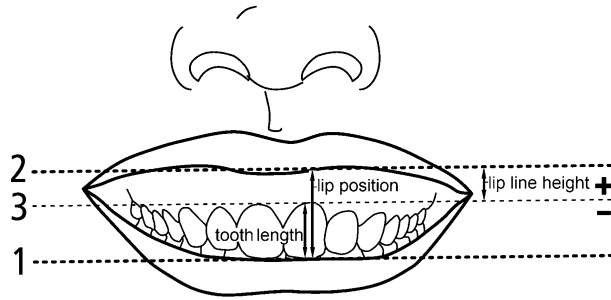


Figure 2. Measurement of the lip-line height. Line 1: marking of the most incisal point of the central incisor. Line 2: marking of the lip edge on the central incisor. Line 3: cervical gingival margin of the central incisor. Lip-line height is lip position minus tooth length. When the gingival margin is displayed, lip-line height has positive values. When the teeth are partly covered, lip-line height has negative values.

Following Peck & Peck [19], lip-line height was expressed relative to the gingival margin (line 3) and is thus a measure of both tooth and gingival visibility (Figure 2). Lip-line height was calculated as the difference between lip position and tooth length (Figure 2). When the gingival margin was displayed, positive values were given in both the maxilla and mandible. When the teeth remained partly covered, negative values were given. Sometimes the upper and lower lips covered both the gingival margin and incisal point, in which case lip-line height was denoted as not measurable. If a tooth was not visible, lip-line height was coded as missing.

Next to lip-line height, the percentages of tooth display during spontaneous and posed smiling were calculated for each tooth. The amount of tooth display was expressed as the percentage of the actual length of the tooth crown. If a tooth was not visible, the percentage of tooth display was zero.

On the records of spontaneous smiling and posed smiling, the corners of the mouth were marked with a vertical line. The horizontal distance between the corners of the mouth was measured as the inter-commissure distance (smile width).

#### Data analysis

Paired sample *t*-tests were used to compare lip-line heights and percentage tooth display during spontaneous and posed smiling for each tooth. The paired sample *t*-test was performed on each tooth separately, because the number of teeth displayed varied between situations, barring a multivariate approach. The same procedure was used for the inter-commissure distances.

#### Results

In Figure 3 and 4, both mean lip-line heights and mean percentages of tooth display during spontaneous and posed smiling are shown for the maxilla and mandible, respectively. The graphs of lip-line

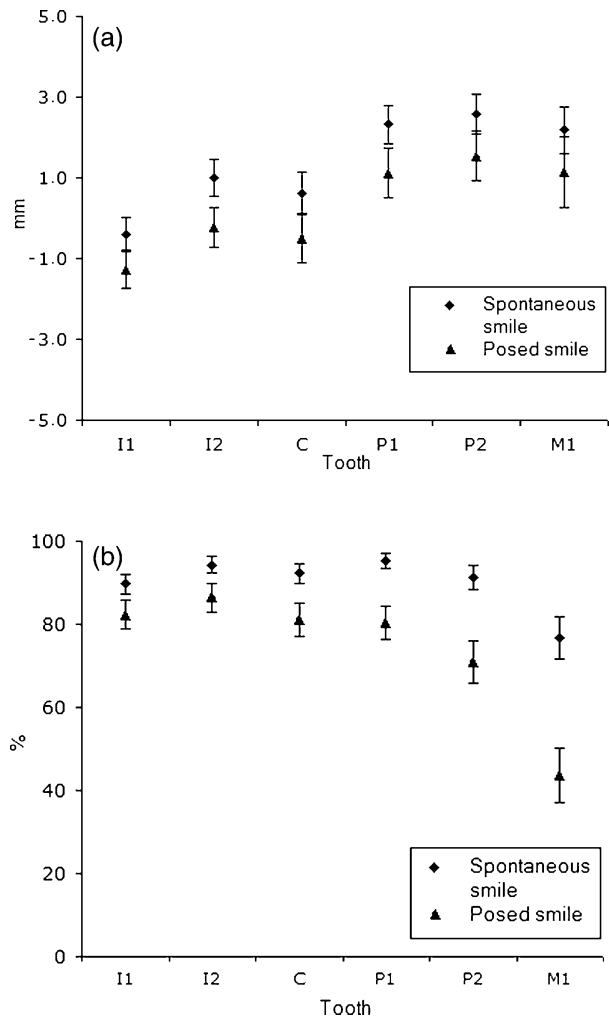


Figure 3. (a) Means of maxillary lip-line heights in millimetres relative to the gingival margin for upper incisors, canine, premolars and 1st molar, and (b) means of percentage maxillary tooth display for upper incisors, canine, premolars, and 1st molar. The vertical bars represent the 95% confidence intervals.

heights include the displayed teeth during smiling. The graphs of percentage tooth display also include not showing teeth with zero percent display.

Figure 3a indicates that maxillary lip-line heights during spontaneous smiling are higher than during posed smiling. The course of both graphs is comparable and the interspaces remain relatively stable. In Figure 3b, the graphs of tooth display for the maxillary anterior teeth follow the same pattern as those of lip-line height (Figure 3a). In the (pre)molar area the interspaces between the tooth display graphs increase towards the posterior: tooth display during posed smiling is decreased considerably compared to spontaneous smiling.

The graphs of lip-line height in Figure 4a show that during posed smiling the mandibular teeth are more covered by the lower lip than during spontaneous smiling. The graphs of tooth display in Figure 4b show fewer interspaces in the posterior area, where tooth display is relatively low in both situations, i.e. varying between 19% and 1%.

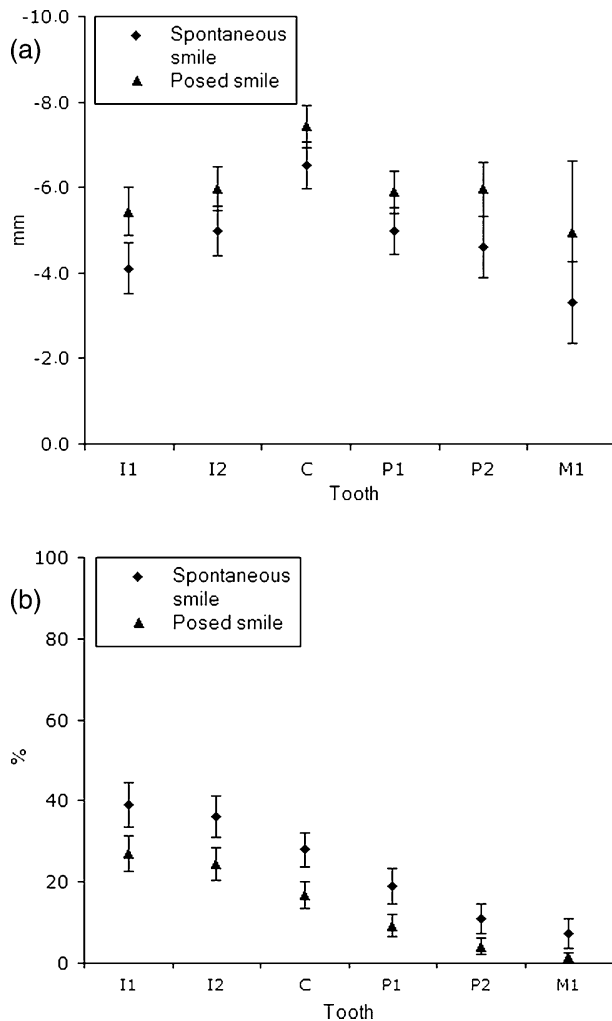


Figure 4. (a) Means of mandibular lip-line heights in millimetres relative to the gingival margin for upper incisors, canine, premolars, and 1st molar, and (b) means of percentage mandibular tooth display for upper incisors, canine, premolars, and 1st molar. The vertical bars represent the 95% confidence intervals.

The results of the paired samples *t*-tests for lip-line heights during spontaneous and posed smiling are given in Table I. For all maxillary teeth and mandibular incisors, canine, and 1st premolar, the significant *p*-values strongly support the assumption

of structural differences in lip-line heights between spontaneous and posed smiling.

The results for the paired samples *t*-tests for percentage tooth display during spontaneous and posed smiling are given in Table II. Tooth display in all teeth showed significant differences between spontaneous and posed smiling.

The paired samples *t*-test was also used to determine differences in inter-commissure distances during spontaneous and posed smiling. During spontaneous smiling, the mean inter-commissure distance was 68.2 mm, and for posed smiling 65.8 mm. The mean difference was 2.4 mm, and the assumption of a structural difference was strongly supported by the significant *p*-value (diff. SD = 3.1 mm,  $t = 8.4$ , d.f. = 121,  $p < 0.001$ ).

## Discussion

With the traditional photographic techniques, only a posed smile was considered adequate to obtain a reproducible diagnostic record [11,12]. A study with contemporary available digital videography has shown that also a spontaneous smile of joy is measurable with a more observational and less patient-interfering approach [18]. With this videographic method, spontaneous smiling and posed smiling were captured reproducibly. The central question in this study is whether the use of a posed smile rather than a spontaneous smile is sufficient as a diagnostic record for facial esthetics and, more specifically, lip-tooth relationships. Besides, the spontaneous smile is a more relevant emotion than a photographic posed smile and approaches the way patients are perceived by their social environment. For most patients, the outcome of orthodontic therapy is directly related to visible improved dento-facial attractiveness and not so much to the more invisible occlusal relationships according to scientific standards. This ambivalence is experienced by some orthodontists, who consider orthodontics as much an art as a science [7,20]. Nevertheless, diagnosis

Table I. Paired samples *t*-tests of lip-line heights during spontaneous and posed smiling in the maxilla and mandible.

	I1	I2	C	P1	P2	M1
<b>Maxilla</b>						
Mean diff. (mm)	0.9	1.2	1.4	1.5	1.6	1.5
SD diff. (mm)	1.1	1.2	1.4	1.7	1.7	1.8
<i>t</i>	8.8	11.1	10.1	9.0	8.3	5.3
d.f.	115	117	90	94	77	41
<i>p</i> -value	$p < 0.001$	$p < 0.001$	$p < 0.001$	$p < 0.001$	$p < 0.001$	$p < 0.001$
<b>Mandible</b>						
Mean diff. (mm)	1.1	1.0	1.0	1.0	1.0	1.1
SD diff. (mm)	1.7	1.7	1.7	1.4	1.6	2.3
<i>t</i>	4.4	3.8	3.7	3.4	1.8	0.8
d.f.	45	42	40	21	8	2
<i>p</i> -value	$p < 0.001$	$p < 0.001$	$p < 0.001$	$p < 0.001$	0.103	0.502

Table II. Paired samples *t*-tests of tooth display (in percent) during spontaneous and posed smiling in the maxilla and mandible.

	I1	I2	C	P1	P2	M1
Maxilla						
Mean diff (%)	7.5	7.9	11.2	15.0	20.2	33.1
SD diff (%)	13.2	13.7	16.5	20.9	26.9	35.2
<i>t</i>	6.3	6.4	7.5	7.9	8.3	10.4
d.f.	121	121	121	121	121	121
<i>p</i> -value	<i>p</i> < 0.001	<i>p</i> < 0.001	<i>p</i> < 0.001	<i>p</i> < 0.001	<i>p</i> < 0.001	<i>p</i> < 0.001
Mandible						
Mean diff. (%)	12.2	11.7	11.0	9.6	6.8	6.0
SD diff. (%)	21.6	20.8	18.7	20.5	17.1	18.7
<i>t</i>	6.2	6.2	6.5	5.2	4.4	3.5
d.f.	121	121	121	121	121	121
<i>p</i> -value	<i>p</i> < 0.001	<i>p</i> < 0.001	<i>p</i> < 0.001	<i>p</i> < 0.001	<i>p</i> < 0.001	<i>p</i> < 0.01

should be both valid and reliable and should not just consider the brief intervals involving active treatments. The profound changes from natural aging on the relations between soft tissue and dentition should also be included in orthodontic diagnosis and treatment planning [21]. An effect of age resulting in a significant reduction of maxillary lip-line heights was quantified in a recent study [9].

The present study shows significantly higher lip-line heights for spontaneous smiling compared to posed smiling (Figure 3a, 4a and Table I). The mean reductions in maxillary lip-line height during posed smiling varied between about 1 mm in the anterior area and 1.5 mm in the posterior area. This, however, is only relevant when lip-line heights are displayed and measurable. The maxillary anterior teeth and 1st premolar could be measured in more than three-quarters of the sample, but at the 1st molar measurable lip-line heights were restricted to a third of the sample. Therefore, in this study design, also tooth display percentages were used to quantify differences between spontaneous and posed smiling. These differences are especially explicit in Figure 3b, where tooth display differences in the posterior maxillary teeth between spontaneous and posed smiling increase to 30%. This means that during spontaneous smiling the 2nd premolar and 1st molar are much more visible than during posed smiling. This is supported by the significant reduction in inter-commissure distance (smile width) of posed smiling compared to spontaneous smiling.

In the mandible, the mean differences for lip-line heights remained stable at around 1 mm. The graphs of tooth display (Figure 4b) show that from an esthetic point of view the differences between spontaneous and posed smiling are most relevant for the mandibular anterior teeth.

Significance testing in this study involved multiple *t*-tests, because a multivariate approach was not possible due to a varying number of observations per tooth. The significance level for multiple tests, however, is not identical to the significance level for each separate test. There is an increased risk of unjustified rejection of the null hypothesis, which

can be countered with the Bonferroni procedure. This involves dividing the desired overall alpha by the number of tests performed. Adopting this, rather conservative, approach for the data in Table I and II and adopting a significance level of  $p = 0.0083$  ( $0.05/12$ ) would result in the same pattern of rejecting or not rejecting the null hypotheses.

The results of this study demonstrate that a posed smiling record differs from a spontaneous smiling record in several essential aspects. Therefore the traditionally used posed smiling record is a starting point that may involve a number of risks for the diagnosis and predictability of the orthodontic treatment plan, but also for a combined orthodontic–surgical approach. Firstly, the lip-line height, which is reduced during posed smiling, can be assessed too low on a posed smiling record. Particularly in the case of gummy smile patients, who have the muscular ability to raise the upper lip significantly higher than average on smiling [19], underestimation of the lip-line height can seriously influence treatment outcome. Lip-line height is also a dominating factor in the combined orthodontic and restorative-implantology approach (e.g. in cases of trauma or oligodontia), where the esthetic risk of the therapy increases when the lip line reveals more of the teeth and gingival area. A natural looking implant restoration, including correct shape of the alveolar bone, a harmonious gingival line, and an inter-proximal dental papilla to the contact point, is not always achievable in clinical practice. In that case, the height of the lip line is decisive whether the esthetic shortcomings of the combined therapy are masked by the lip or just revealed [22].

Not only is lip-line height reduced during posed smiling, also the posterior teeth can be considerably less displayed in combination with reduced smile width. This can lead to insufficient and inadequate diagnostics regarding arch width and buccal corridors, smile arc and transversal occlusal plane, and (pre)molar lip-line height. Since minimal buccal corridors are a preferred esthetic feature in both men and women, large buccal corridors are considered a serious problem that has to be included in the

problem list during orthodontic diagnosis [23]. However, as a result of reduced smile width during posed smiling, the buccal corridors can be underestimated and upper arch widening not deemed to be needed during orthodontic or surgical treatment.

In relation to the maxillary arch width, the curve of the smile arc is also considered an important part of oral esthetics [5,24]. The curve of the smile arc is established in relation to the curve of the lower lip. This is complicated by the reduced visibility of the maxillary (pre)molar area on a posed smiling record. During posed smiling, the upper lip is less elevated and the mouth less open. As a result, the cervical parts of the (pre)molars are more covered by the upper lip and the incisal parts by the lower lip, especially near the commissurae. When the incisal line through the cusps is covered, only information regarding the smile arc in the anterior teeth is available for the diagnosis. In that case, control is lacking over an esthetic sagittal alignment of the posterior teeth, for which the cephalogram gives insufficient hold. Moreover, the smaller smile width during posed smiling can readily result in a flatter curve of the lower lip at the risk of a flat smile arc also in the anterior teeth during spontaneous smiling.

Next to spontaneous smiling, a videographic analysis can easily be extended to other frequently used functional expressions. Lip-tooth relationships during speech and at rest can be captured and analyzed according to the classic ‘dynesthetic’ principles forthcoming from prosthodontics [25]. Attention can then be given to the ‘speaking line’, the displayed incisal length of the maxillary anterior teeth during speech and to tooth display at rest. When speaking, the lateral incisors should be partly shown. At rest, a few millimeters of the maxillary anterior teeth should be displayed depending on gender and age of the patient. During speech, a larger number of mandibular teeth are in view and are also more exposed than during smiling [9]. In this way, more information is obtained for an harmonious mandibular tooth positioning and curvature through the incisal edges and cusps. Whether additional videography of speech and at rest leads to another orthodontic treatment strategy remains to be seen, but in a recent study it was demonstrated that there is a significant individual coherence for upper lip positions at the maxillary anterior teeth during spontaneous smiling, speech, and at rest [9].

The results show, without doubt, that spontaneous and posed smiling are different. Not surprisingly, as Duchenne de Boulogne observed already in 1862, spontaneous and posed smiles exhibit physiognomic differences [26]. Next to the zygomaticus major muscle, contracting the corners of the mouth, the spontaneous “Duchenne” smile also involves the orbicularis oculi pars lateralis muscle. Contraction of this muscle results in “crow’s feet” at the outer corners of the eye, which cannot be done voluntarily

[27]. Further psychophysiological research has found more asymmetries in posed smiles than in spontaneous smiles and different dynamic time patterns [28,29].

Spontaneous smiling should be the logical focus point for the esthetic diagnosis of lip-tooth relationship during smiling. The fast onset and fading out of a spontaneous smile makes it impossible to capture in the right moment with a static photograph. Therefore it is proposed to switch from static to dynamic videorecording of the smile for diagnostic purposes. Experiences of plastic surgeons [30,31], oral and maxillofacial surgeons [32], and orthodontists [7] show that (digital) video registration in clinical practice is feasible.

**Declaration of interest:** The authors report no conflicts of interest. The authors alone are responsible for the content and writing of the paper.

## References

- [1] Berg R. Orthodontic treatment – yes or no? A difficult decision in some cases. A contribution to the discussion. *J Orofac Orthop* 2001;62:410–21.
- [2] Kokich VO Jr, Kiyak HA, Shapiro PA. Comparing the perception of dentists and lay people to altered dental esthetics. *J Esthet Dent* 1999;11:311–24.
- [3] van der Geld P, Oosterveld P, van Heck G, Kuijpers-Jagtman AM. Smile attractiveness: self-perception and influence on personality. *Angle Orthod* 2007;77:759–65.
- [4] Ritter DE, Gandini LG Jr, dos Santos Pinto A, Ravelli DB, Locks A. Analysis of the smile photograph. *World J Orthod* 2006;7:279–85.
- [5] Sarver DM. The importance of incisor positioning in the esthetic smile: the smile arc. *Am J Orthod Dentofacial Orthop* 2001;120:98–111.
- [6] Ackerman MB, Ackerman JL. Smile analysis and design in the digital era. *J Clin Orthod* 2002;36:221–36.
- [7] Sarver DM, Ackerman MB. Dynamic smile visualization and quantification. Part 1: Evolution of the concept and dynamic records for smile capture. *Am J Orthod Dentofacial Orthop* 2003;124:4–12.
- [8] Ackerman MB, Brensinger C, Landis JR. An evaluation of dynamic lip-tooth characteristics during speech and smile in adolescents. *Angle Orthod* 2004;74:43–50.
- [9] van der Geld P, Oosterveld P, Kuijpers-Jagtman AM. Age-related changes of the dental aesthetic zone during spontaneous smiling and speech. *Eur J Orthod* 2008. In press.
- [10] Tarantili VV, Halazonetis DJ, Spyropoulos MN. The spontaneous smile in dynamic motion. *Am J Orthod Dentofacial Orthop* 2005;128:8–15.
- [11] Rigsbee OH 3rd, Sperry TP, BeGole EA. The influence of facial animation on smile characteristics. *Int J Adult Orthodon Orthognath Surg* 1988;3:233–9.
- [12] Ackerman JL, Ackerman MB, Brensinger CM, Landis JR. A morphometric analysis of the posed smile. *Clin Orthod Res* 1998;1:2–11.
- [13] Ekman P. Facial expressions of emotion: an old controversy and new findings. *Phil Trans R Soc Lond B Biol Sci* 1992;335:63–9.
- [14] Allen E, Bell W. Enhancing facial esthetics through gingival surgery. In: Bell WH, editors. *Modern practice in orthognathic and reconstructive surgery*. Philadelphia: Saunders; 1992. p. 235–51.

- [15] Moore R, Brødsgaard I, Rosenberg N. The contribution of embarrassment to phobic dental anxiety: a qualitative research study. *BMC Psychiatry* 2004;4:10.
- [16] Bonanno GA, Keltner D, Noll JG, Putnam FW, Trickett PK, LeJeune J, et al. When the face reveals what words do not: facial expressions of emotion, smiling, and the willingness to disclose childhood sexual abuse. *J Pers Soc Psychol* 2002; 83:94–110.
- [17] Adachi T, Kochi S, Yamaguchi T. Characteristics of non-verbal behavior in patients with cleft lip and palate during interpersonal communication. *Cleft Palate Craniofac J* 2003; 40:310–16.
- [18] van der Geld PA, Oosterveld P, van Waas MA, Kuijpers-Jagtman AM. Digital videographic measurement of tooth display and lip position in smiling and speech: reliability and clinical application. *Am J Orthod Dentofacial Orthop* 2007; 131:301.e1–e8.
- [19] Peck S, Peck L. Selected aspects of the art and science of facial esthetics. *Semin Orthod* 1995;1:105–26.
- [20] Mackley RJ. “Animated” orthodontic treatment planning. *J Clin Orthod* 1993;27:361–5.
- [21] Zachrisson BU. Esthetic factors involved in anterior tooth display and the smile: vertical dimension. *J Clin Orthod* 1998;23:432–45.
- [22] Cune MS, Meijer GJ, Koole R. Anterior tooth replacement with implants in grafted alveolar cleft sites: a case series. *Clin Oral Implant Res* 2004;15:616–24.
- [23] Moore T, Southard KA, Casco JS, Qian F, Southard TE. Buccal corridors and smile esthetics. *Am J Orthod Dentofacial Orthop* 2005;127:208–13.
- [24] Parekh S, Fields HW, Beck FM, Rosenstiel SF. The acceptability of variations in smile arc and buccal corridor space. *Orthod Craniofacial Res* 2007;10:15–21.
- [25] Frush JP, Fisher RD. The dynesthetic interpretation of the dentogenic concept. *J Prosthet Dent* 1958;8:558–81.
- [26] Ekman P, Davidson RJ, Friesen WV. The Duchenne smile: emotional expression and brain physiology. II. *J Pers Soc Psychol* 1990;58:342–53.
- [27] Hess U, Kappas A, McHugo GJ, Kleck RE, Lanzetta JT. An analysis of the encoding and decoding of spontaneous and posed smiles: the use of facial electromyography. *J Nonverbal Behav* 1989;13:121–37.
- [28] Skinner M, Mullen B. Facial asymmetry in emotional expression: a meta-analysis of research. *Br J Soc Psychol* 1991;30:113–24.
- [29] Hess U, Kleck RE. Differentiating emotion elicited and deliberate emotional facial expressions. *Eur J Soc Psychol* 1990;20:369–85.
- [30] Frey M, Giovanoli P, Gerber H, Slameczka M, Stüssi E. Three-dimensional video analysis of facial movements: a new method to assess the quantity and quality of the smile. *Plast Reconstr Surg* 1999;104:2032–9.
- [31] Kang YS, Bae YC, Hwang SM, Nam SB. A simple and quantitative method for three-dimensional measurement of normal smiles. *Ann Plast Surg* 2005;54:379–83.
- [32] Nooreyazdan M, Trotman CA, Faraway JJ. Modeling facial movement. II. A dynamic analysis of differences caused by orthognathic surgery. *J Oral Maxillofac Surg* 2004;62: 1380–6.