

CASE REPORT

Treatment of gustatory sweating with low-dose botulinum toxin A: A case report

MERETE BAKKE¹, NIELS MAX THORSEN¹, ALLAN BARDOW¹, TORBEN DALAGER²,
CARSTEN ECKHART THOMSEN¹ & LISBETH REGEUR²

¹Department of Oral Medicine, Clinical Oral Physiology, Oral Pathology & Anatomy, School of Dentistry, Faculty of Health Sciences, University of Copenhagen, Copenhagen, Denmark, and ²Departments of Neurology and Clinical Neurophysiology, Bispebjerg Hospital, University of Copenhagen, Copenhagen, Denmark

Abstract

Frey's syndrome, gustatory sweating in the preauricular area, is an unpleasant phenomenon occurring during meals after surgery on the parotid gland. Recently, botulinum toxin A (BTX) has been shown to reduce the symptoms, but the variation in the reported doses is large. **Objective.** To quantify the effect of treatment with low-dose BTX in a case of Frey's syndrome over a period of 6 months. **Material and methods.** A 56-year-old woman was treated with 10 U Botox given as 20 single, intracutaneous injections of 0.5 U, one for each cm², 3 years after resection of the parotid gland. Before treatment and repeatedly during the 6-month period, the sweating was rated subjectively on a 100-mm visual analog scale (VAS) and by a severity index, and objectively by assessment of the extent of the involved skin area using Minor's iodine-starch test, staining the area of sweating dark. **Results.** The treatment decreased the involved area from 20 to 5 cm² and the VAS ratings from 98 to 8 mm. The index showed that treatment affected the sweating intensity, not the frequency. After the 6-month period the patient was still satisfied, but the involved skin area had increased; however, not entirely to pretreatment values. **Conclusions.** The effect of BTX injections for gustatory sweating obtained in this case was comparable to results reported using higher doses. Low doses of BTX can therefore be used in the treatment of Frey's syndrome, but studies to clarify the dose–response relationship, in terms of both time–course and obtained effect, are needed.

Key Words: Frey's syndrome, Minor's iodine-starch test, parotid gland, parotid resection

Introduction

Localized, cervico-facial gustatory sweating and flushing in the preauricular area is known as Frey's syndrome after the Polish neurologist Lucja Frey, who described the disorder in 1923. It is an unpleasant phenomenon occurring after injuries and surgical procedures on the parotid gland, after cervical or upper thoracic sympathectomies, or in connection with diabetes [1]. Frey's syndrome is most likely caused by misdirected regeneration of cut or damaged parasympathetic fibers producing new "salivary" reflex arches activating sweat glands and small subcutaneous blood vessels instead of salivary gland tissue [2]. Thus, sweating and vasodilatation appear in the reinnervated area when salivation is induced upon cholinergic stimulation from gustatory and masticatory stimuli, especially during meals.

The clinical incidence of Frey's syndrome after parotidectomy has been reported to be as high as 53%, and in most cases the symptoms appear from 2 weeks to 2 years postoperatively [3]. After surgical management of pleomorphic adenoma of the parotid gland, the incidence on the operated side has been reported to be between 5% and 30% [2,4].

Frey's syndrome may be very unpleasant as well as socially disabling when intense sweating and the subsequent wetting of clothes prevents the patient from dining with guests. Therefore, a large variety of treatments have been suggested to reduce the clinical symptoms, but have been associated either with poor results or severe side effects [5].

Recently, intracutaneous injections of botulinum toxin A (BTX) have been shown to be clinically effective against gustatory sweating [5–7]. BTX is a potent biological neurotoxin acting by long-lasting

inhibition of the presynaptic release of acetylcholine, resulting in marked reduction of symptoms and no systemic side effects. In previous reports using Botox, a commercially available preparation of BTX, the total, injected dose has varied between 25 and 175 U for treatment of involved skin areas of 16–175 cm², corresponding to 0.5–10 U per cm², and improvement has been reported to last 1–30 months [5,6].

To avoid adverse effects such as slight or partial weakness of the upper lip that have been reported in patients undergoing BTX treatment for recurrent gustatory sweating [6], it is advisable that (a) the injections takes place intracutaneously, i.e. not too deep, and (b) the dose and volume per injection are small and given at closely separated skin locations. Another reason for keeping the dose low is that no clear dose–response relationship has been shown [5].

The aim of the present work was to describe and quantify the effect of treatment with low-dose BTX of a total of only 10 U in a woman with considerable, recurrent gustatory sweating by assessing the severity of the sweating and the extent of the involved facial skin area over a follow-up period of 6 months.

Material and methods

A 56-year-old female patient was treated with BTX after informed consent had been obtained. Her right-sided Frey's syndrome first occurred after resection of the parotid gland 3 years earlier due to a pleomorphic adenoma. Apart from moderate symptoms from a disk displacement with reduction in her left temporomandibular joint, she was otherwise healthy.

The patient's main complaint of Frey's syndrome was excessive focal sweating causing wetting of clothes, but she also experienced slight flushing and a feeling of warmth and tingling in the pre-auricular skin during every meal and while consuming fruits and sweets. In addition, she had a subjective feeling of dry mouth. To ensure that the secreted fluid was not of salivary origin, a substantial sample was collected onto a Whatman filter paper, which, after rehydration in millipore water, was subjected to the Phadebas amylase test. As the test showed no sign of amylase activity the fluid could be characterized as comprised of sweat only. Although a post-surgical leakage of saliva is rare, this test also helped to assure the patient that she was not drooling from the cheek.

Standardized assessments of the condition in terms of subjective and objective evaluation were performed immediately before treatment (time 0), and 1 week, 1½ month, 3 months, and 6 months after BTX treatment.

Self-assessment of gustatory sweating

Before treatment and at each control session the patient rated her sweating globally on a visual analog scale (VAS), i.e. a 100-mm horizontal scale with the left endpoint (0 mm) indicating “no gustatory sweating during meals” and the right endpoint (100 mm) “worst possible gustatory sweating during meals”. In addition, an index for severity of the gustatory sweating (0–7) was developed from a drooling index [8] and rated the combined frequency (0 = no sweating, 1 = occasional sweating – not every day, 2 = frequent sweating – every day, 3 = almost constant sweating) and intensity (0 = dry – no sweating, 1 = mild – only wet on the cheek, 2 = moderate – wet on cheek and neck, 3 = severe – wet on cheek, neck and shirt/blouse, 4 = extreme – also wetting of surroundings) by adding the two score values.

Objective assessment of gustatory sweating

Minor's iodine-starch test was used to localize and assess the extent of involved skin area shortly before treatment and at each control session. An iodine solution (Castor oil mixed with 2% iodine alcohol solution 1:9) was applied on the skin of the right cheek and dried for 0.5 min. After application, potato flour was sprinkled over the affected area until it was homogeneously covered. The patient then chewed slices of apple for 5 min. In the presence of sweat, a chemical reaction takes place between iodine and starch, after which the beads of perspiration and thereby the zones with sweating appear darkish brown, almost black. The surplus flour was gently removed using compressed air and suction. Finally, the involved skin area was photographed with a digital camera (DSC-U50; Sony, Tokyo, Japan).

The iodine-starch test performed shortly before treatment was also used to assess the circumference of the involved, stained area. This was transferred to an acetate template with anatomical landmarks corresponding to ear, eye, and mouth, and the circumscribed area was excised (Figure 1). An acetate grid with perforations for every centimeter was fixed to the template over the excised area to guide treatment.

BTX treatment

Topical anesthetics (EMLA cream, 2.5% lidocaine and 2.5% prilocaine; AstraZeneca, Albertslund, Denmark) were applied to the involved skin and covered with an occlusive dressing 45 min before BTX treatment. To assist the injections, the template was replaced and markings were made through the holes in the grid to divide the area (Figure 1). The skin was then disinfected with alcohol, and intracutaneous injections were performed with a 0.45 mm

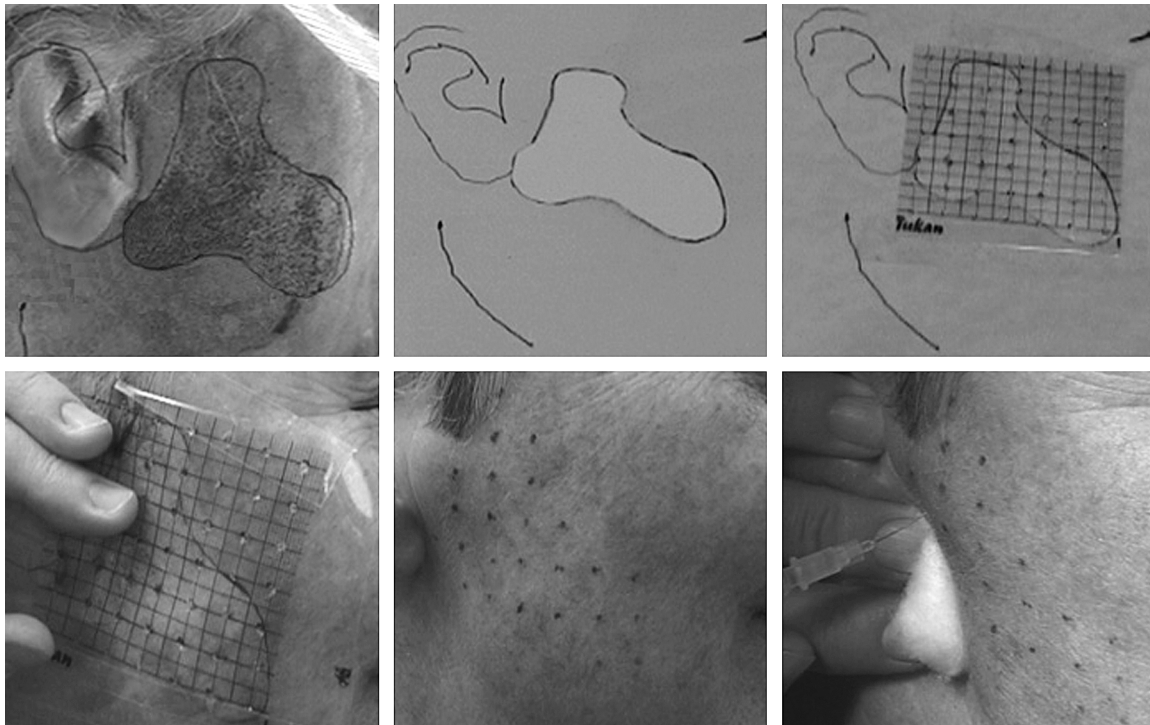


Figure 1. Guidance of intracutaneous injections of botulinum toxin for Frey's syndrome. *Upper gallery*: The area with gustatory sweating stained after Minor's iodine-starch test before treatment and transferred to an acetate template. Excision of the circumscribed area on the template. An acetate grid with perforations for every centimeter fixed to the template over the excised area. *Lower gallery*: The template with the grid positioned corresponding to the anatomical landmarks and markings made on the skin through the holes. The intracutaneous injections of 0.5 U Botox per cm^2 performed as single injections at 1-cm intervals given between the markings.

cannula at 1-cm distance, i.e. one single injection per 1 cm^2 . For each injection, 0.5 U Botox (Allergan, Irvine, Calif., USA) reconstituted with 0.9% sterile saline to a concentration of 2.5 U per 0.1 ml was used. For this particular case the corresponding total dose for the treatment was 10 U (~ 20 injections).

Data analyses

The digital images before treatment and at each control were adjusted and analyzed on a personal computer using standard image-processing software (Photoshop, version 8.0; Adobe, San Jose, Calif., USA). Each of the images was rotated and scaled in true pixels/cm, based on the anatomical landmarks at the ear, eye, and mouth, and a ruler included in the last image after 6 months. Only the skin areas covered with iodine solution were included in the further processing (Figure 2). The Photoshop tool "magic wand" was used to select areas of similar luminosity; in this case the area with iodine-starch reaction. By combining repetitive use of the "magic wand" and "histogram" tools it was possible to select the stained zones and measure the involved skin area in pixels. Based on the calibrated true pixels/cm scale for each image, the area in pixels was converted to cm^2 .

The relationship between the global assessment of gustatory sweating and the area of involved skin was analyzed with Pearson's correlation analysis (r) with

a level of significance of 5% (Statistica version 5.0; StatSoft, Tulsa, Ok., USA).

Results

The effect of the intracutaneous injections of Botox was marked and the patient was satisfied with the treatment. With the exception of slight pain during the intracutaneous injections of Botox, no side effects or complications were seen. The extent of the involved skin area before treatment was 20.0 cm^2 . It was markedly reduced (4.6 cm^2) already after 1 week and was still low (5.0 cm^2) after 6 weeks (Figure 2). After 3 months the area had increased (8.3 cm^2), and more so after 6 months (18.0 cm^2), but still not quite back to pretreatment value.

There was a significant and positive relation between the area of the involved skin and the VAS scores ($r=0.69$, $p<0.05$). Before treatment, the patient's score for gustatory sweating on the 100-mm VAS was 98 mm, decreasing after 1 week (32 mm), and lowest after 1.5 months (8 mm). The scores increased gradually at the controls after 3 months (16 mm) and after 6 months (24 mm). The total score in the index for severity of the gustatory sweating (range 0–7) was 5 before treatment, decreasing to and remaining at 3 in all control sessions. In addition, the index revealed that only intensity was influenced by the treatment (from score 3: severe – wet on cheek, neck and shirt/

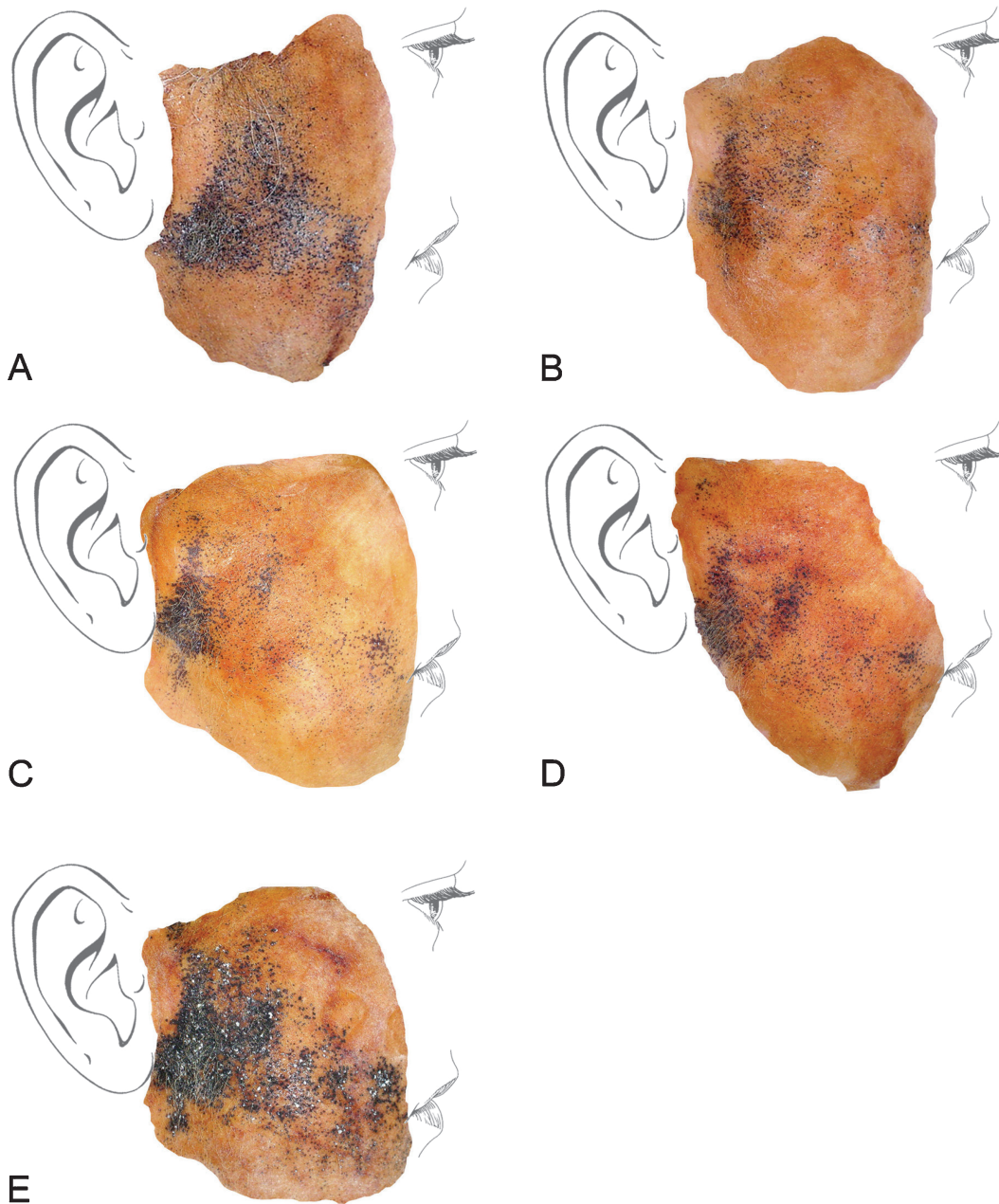


Figure 2. Demonstration of gustatory sweating in Frey's syndrome by Minor's iodine-starch test. The area of involved skin immediately before treatment with botulinum toxin (A: 20.0 cm²) and at controls after 1 week (B: 4.6 cm²), 1.5 months (C: 5.0 cm²), 3 months (D: 8.3 cm²), and 6 months (E: 18.0 cm²). The zones of sweating appear darkish brown as the beads of perspiration become visible as small dark spots after the chemical reaction between iodine and starch in the presence of sweat.

blouse before treatment to score 1: mild – only wet on the cheek), and not the frequency of the gustatory sweating (score 2: frequent sweating – every day both before and after treatment). The flushing and the feelings of warmth and slight tingling in the preauricular skin preceding the episodes of sweating were only slightly improved by the treatment.

Discussion

Frey's syndrome is a common and unpleasant complication after parotid surgery, the most prominent symptom being gustatory sweating. This was the greatest problem for the patient in the present

report. Even with a very low dose of BTX it was possible to get a 75–90% reduction in gustatory sweating in the present, severe case, i.e. an improvement corresponding to previous studies using higher doses. However, in accordance with the general effect in other reports the treatment did not stop sweating entirely. The sweating was equally frequent, but extent and intensity were greatly diminished. Interestingly, the subjective and objective data on the gustatory sweating were significantly correlated and the time-course of the patient's VAS scores for sweating mimicked the corresponding extent of the involved skin area over time. The flushing was only slightly reduced, probably because the injection sites

were adjusted according to the patient's main complaint, i.e. the recurrent gustatory sweating.

At the end of the observation time 6 months after treatment, i.e. longer than the effect of BTX on the muscles in the treatment of dystonia [9], the effect of the treatment was still present. Although the sweating area as assessed by Minor's iodine-starch test had increased to 90% of the pretreatment value, the patient still felt an improvement and was satisfied with the result.

In conclusion, the effect of low-dose BTX injections (20 single injections of 0.5 U Botox, one per cm²) for Frey's syndrome in the present case was comparable with the higher doses used in earlier studies. Therefore, low doses of BTX may be sufficient, but more studies are needed to clarify the dose-response relationship, in terms of both time-course and extent of the effect, and with respect to the gustatory sweating and flushing.

Acknowledgments

We are grateful to Joan Lykkeaa for technical laboratory assistance in the Minor's iodine-starch tests.

References

- [1] Restivo DA, Lanza S, Patti F, Giuffrida S, Marchese-Ragona R, Bramanti P, et al. Improvement of diabetic autonomic gustatory sweating by botulinum toxin type A. *Neurology* 2002;59:1971-3.
- [2] Luna-Ortiz K, Sanson-Riofrio JA, Mosqueda-Taylor A. Frey syndrome. A proposal for evaluating severity. *Oral Oncol* 2004;40:501-5.
- [3] Malatskey S, Rabinovich I, Fradis M, Peled M. Frey syndrome - delayed clinical onset: a case report. *Oral Surg Oral Med Oral Pathol Oral Radiol Endod* 2002;94:338-40.
- [4] Papadogeorgakis N, Skouteris CA, Mylonas AI, Angelopoulos AP. Superficial parotidectomy: technical modifications based on tumour characteristics. *J Craniomaxillofac Surg* 2004;32:350-3.
- [5] Eckhardt A, Kuettner C. Treatment of gustatory sweating (Frey's syndrome) with botulinum toxin A. *Head Neck* 2003;25:624-8.
- [6] Laccourreye O, Garcia D. Recurrent gustatory sweating (Frey syndrome) after intracutaneous injections of botulinum toxin type A: incidence, management, and outcome. *Arch Otolaryngol Head Neck Surg* 1999;125:283-6.
- [7] Beerens AJF, Snow GB. Botulinum toxin A in the treatment of patients with Frey syndrome. *Br J Surg* 2002;89:116-19.
- [8] Thomas-Stonell N, Greenberg J. Three treatment approaches and clinical factors in the reduction of drooling. *Dysphagia* 1988;3:73-8.
- [9] Jankovic J, Schwartz K, Donovan DT. Botulinum toxin treatment of cranial-cervical dystonia, spasmodic dysphonia, other focal dystonias and hemifacial spasm. *J Neurol Neurosurg Psychiatry* 1990;53:633-9.

Acta

Odontologica

Scandinavica

Awards

Excellent contribution to dental research

Professor Mogens Kilian has been selected by the Prize Committee as the 2006 recipient of the Acta Odontologica Scandinavica Award for his excellent contributions to dental research. The award, NOK 50,000, will be presented to Professor Kilian at the IADR/PEF Meeting in Dublin on 13-16 September 2006. The Prize Committee, appointed by the Board of the Acta Odontologica Scandinavica, comprised Drs Helena Forss, Ellen Frandsen, Lars Matsson, Niels Skaug, and the Editor-in-Chief Folke Lagerlöf.

The best article

As the best article published in Acta Odontologica Scandinavica in 2005 the Prize Committee selected 'Oral and salivary parameters in patients with rheumatic diseases', published in Acta Odontologica Scandinavica 2005;63(5):284-94 and authored by Miia Helenius, Jukka Meurman, Ilkka Helenius, Kirsti Kari, Jarkko Hietanen, Riitta Suuronen, Hannu Kautiainen, Marjatta Leirisalo-Repo and Christian Lindqvist. The award, NOK 10,000, will be presented at the IADR/PEF Meeting in Dublin on 13-16 September 2006. The Prize Committee, appointed by the Board of Acta Odontologica Scandinavica, comprised Drs Karin Heyeraas, Palle Holmstrup, Peter Holbrook, Pentti Kirveskari, Thomas Modéer, and the Editor-in-Chief Folke Lagerlöf.