

# A comparison of habitual jaw movements and articulator function

Duncan R. McMillan and Anne S. McMillan

Department of Prosthetic Dentistry, Faculty of Odontology, University of Lund, Malmö, Sweden, and Department of Prosthetic Dentistry, Faculty of Dentistry, Prince Philip Dental Hospital, University of Hong Kong, Hong Kong

McMillan DR, McMillan AS. A comparison of habitual jaw movements and articulator function. *Acta Odontol Scand* 1986;44:291–299. Oslo. ISSN 0001–6357.

Inherent in adjustable articulators are errors related either to recordings from the patient or to adjustments to the instrument, or both. Furthermore, the validity of the geometric concepts on which the design of these instruments is based, stressing the dominant role of the temporomandibular joints in mandibular movements, is open to question. Microchip technology now makes it possible to view jaw movements in three dimensions while impeding physiological activity minimally. Using a kinesiograph, young dentate Swedish and Chinese adults were examined on two occasions, and the magnitude and direction of some jaw movements were recorded. The results showed that voluntary opening and closing excursions of the mandible frequently followed disparate paths and that closure from the rest position to occlusion was three-dimensional, a lateral component of movement being usual. Retruded contact position was both uncomfortable and unstable. These findings suggest that current procedures for designing and refining occlusal schemes on articulators are invalid. □ *Articulators; dental occlusion; prosthetics*

*Duncan R. McMillan, Department of Prosthetic Dentistry, School of Dentistry, Carl Gustafs väg 34, S-214 21 Malmö, Sweden*

The literature on rehabilitative dentistry is rich in techniques for designing, building, modifying, and refining occlusion and articulation on articulators. The average dentist usually confines his application of articulators to the one with which he became familiar at dental school (1). A survey of dental schools in the USA and Canada showed that, in the responding institutions, semiajustable models of Denar, Dentatus, Hanau, and Whip-Mix machines were usually used (2). A similar finding might also apply in other geographical locations.

All these articulators have in common a single intercondylar axis, having been conceived on the premise that there is but one transverse axis of mandibular rotation (3), and all are geometrically based on triangles, a notion bequeathed by Bonwill (4). With each, the face-bow is usually applied to orientate the maxillary cast to the intercondylar axis in the same relationship as the maxilla bears to the rotational axis of the mandible. McCollum (5), having developed the only positive method for locating the hinge axis, thus added credence to the ration-

ale initiated by Gilmore and implemented by Snow (6).

In his review of the literature concerning the hinge axis Winstanley (7) showed that the sheer weight of paper printed in support of the concept far outweighed that devoted to a contrary opinion. Nonetheless, a contrary view does exist, and if it proved to be correct, the application of articulator techniques to dental occlusion would have to be reappraised.

Condylar concentricity enabling hinge movement of 20–30 mm of opening has been cited from the literature by Brekke (3) as 'adequate proof' of the existence of hinge rotation in non-functional border movements at the condyle, supplied by Posselt (8) and others, including Ulrich (9). However, Ulrich did not find any evidence that there was a single axis. Brekke (10) proceeded to show that, because of the asymmetry of the mandible and the different planes of orientation of the condyles, there must be independently orientated transverse axes, and movement taking place, not on point centers of rotation but about line centers. This sug-

gests that the weight of literature may be an inappropriate criterion on which to base judgement.

From an anatomical viewpoint, Koski (11) has suggested that, a priori, the evidence shows that 'no stationary hinge axis exists for the vertically moving mandible during unstrained movements' and that during small vertical movements the axis may be located briefly in the mastoid process region, from which it will shift depending on patient position and the magnitude of the jaw movement.

Although it requires information with six degrees of freedom to specify the position of a body in space, few jaw location studies have met this requirement. Most have tracked only one, usually an anterior point for which the minimum of three degrees of freedom are required to locate its position (12). However, since the jaw point, the teeth, and the condyles are in a fixed spatial relationship to each other, a jaw-point movement must be accompanied by jaw movement (13). If the paired mandibular condyles constitute a hinge axis and merely rotate in space, then movement at the incisal point, viewed in the median sagittal plane, is on the arc of a circle in both opening and closing movements (14). The radius of this circle is centered on the intercondylar axis and passes to the incisal point (Fig. 1). The same movement, viewed in the frontal plane would appear as a vertical line (14). By virtue of the rotational movement of the mandible,

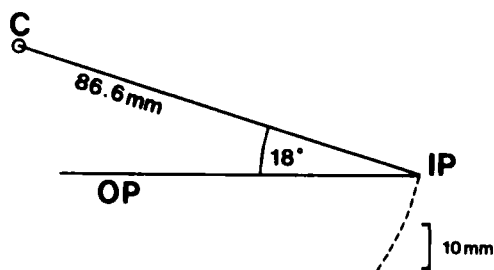


Fig. 1. A projection on the median sagittal plane of Bonwill's triangle (height, 86.6 mm) and Balkwill's angle ( $18^\circ$ ). IP = incisal point; OP = occlusal plane; and C = center of rotation of the mandible at the intercondylar axis. Opening/closing mandibular excursions represented at the incisal point describe an arc of radius C-IP.

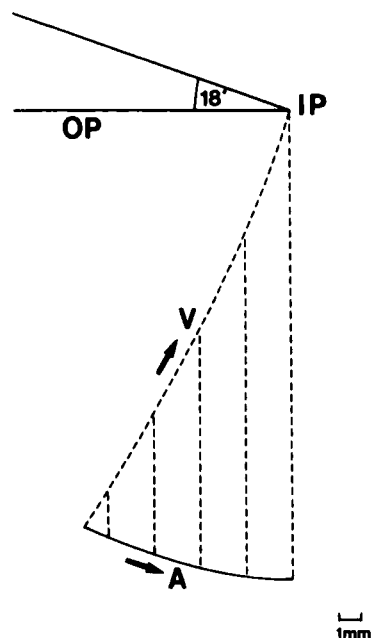


Fig. 2. On closure about a hinge axis, the arc traced by the incisal point can be described by a ratio of anteroposterior to vertical movement (A/V ratio). In this geometric construction  $A/V = 0.5$  for any degree of opening.

the incisal point, viewed sagittally, describes the arc of a circle. Therefore, for each unit of vertical movement during closure there must be an equivalent anterior component of movement—a positive antero-posterior/vertical (A/V) ratio (Fig. 2).

This investigation was undertaken to verify the presence of a fixed hinge movement of the mandible during function, by visualizing the movement of an incisal point during habitual opening and closing tasks and closure from a rest position (RP) to intercuspal position (ICP).

## Materials and methods

Ten southern (Hong Kong) Chinese subjects, five men aged 24–25 years and five women aged 22–24 years, were selected from amongst the staff and students of the Prince Philip Dental Hospital in Hong Kong. Six male Swedish dental students aged 22–25

years were selected from those at the Faculty of Dentistry, University of Lund, at Malmö. The subjects in both schools had complete natural dentitions and reported no history of disorders of the masticatory system.

Habitual opening and closing movements of the mandible and unguided closures from RP to ICP were monitored at two sessions 1 week apart, using a mandibular kinesiograph (model K5AR in Hong Kong and model K6 in Malmö; both by Myo-tronics Research Inc., Seattle, Wash., USA). Representative traces of these movement patterns at each of the two sessions were recorded (oscilloscope camera C-5C, Tektronix Inc., Beaverton, Ore., USA, and Polaroid 667 film, Polaroid (UK) Ltd., St. Albans, Herts., with K5AR and Imagewriter, Apple Computer Inc., Cupertino, Calif., for K6, operating on Program 1.6A, Myotronics Research Inc.). The Swedish subjects, in addition to open/close tasks and closure through the interocclusal distance from RP to ICP, performed additional habitual open/close maneuvers, voluntary retrusions to retruded contact position (RCP), and protrusive mandibular excursions.

The magnitude of movements photographed with the K5AR kinesiograph were quantified by direct measurement. Measurements were taken from the traces printed from the K6 version, for which the analysis program did not supply the requisite data, or from the analysis print-out, for which it did. The kinesiographic measurement method has been described by Jankelson (15), and the instrument error has been documented by both Jankelson (15) and Hannam et al. (16).

A lateral cephalometric radiograph was taken for each subject in an upright head position with the Frankfurt plane horizontal. The radiographs were traced by the method of Björk (17). In cases of double projection, the mid-point was used. Measuring points were situated on the median sagittal plane or were projected onto that plane. The traces were digitized (Hipad Digitizer, Bausch and Lomb, Houston Instrument Division, Austin, Tex., USA) to a computer (Zenith model Z-100, Zenith Data Systems Corp., Franklin Park, Ill., USA) programed to com-

pute lines, angles, and distances (Syd Data Plotting Program, Lund, Sweden). From an analysis of these data, the distance from incision inferior (ii) to condylion (cd) and the angle formed by that line with the occlusal line inferior (OLi) were abstracted.

Geometric constructions were drawn on the basis of data pertaining to the height of Bonwill's triangle and Balkwill's angle (18–20), and the arcs of theoretical open/close excursions of the incisal point, centered on hypothetical axes were scribed. By measurement, A/V ratios were computed for the appropriate heights and angles. Since the kinesiograph monitors the movement of a magnet fixed to the mandibular teeth, inferior to the incisal point, the drawings were modified when radiographic data from the test subjects became available. The theoretical incisal point was carried 10 mm inferior to ii, an estimated distance from ii to the center of the magnet with its layer of adhesive. On this modified construction A/V ratios were again calculated and compared with the clinical data generated on the kinesiographs.

### Methods

Some of the errors inherent in the clinical method were investigated by means of a custom-made stereotaxic micromanipulator by means of which the magnet could be moved in relation to the magnetometer array in three orthogonal planes, *in vitro*. The device was installed in a location approximately the same as that occupied by the test subjects and could thus be expected to be exposed to a similar electromagnetic environment. The mechanically generated movements could be read on vernier gauges to an accuracy of 0.1 mm.

With the K6 in sweep mode, vertical movements representing closing excursions were made on the micromanipulator. The vertical movement of the magnet was estimated to the nearest 0.1 mm, the movement represented on the K6 was analyzed, and the tracings together with their analyses were printed before the information was stored on disc. The results showed that in a range of vertical movement between 0.4 and 2.7 mm

Table 1. A/V ratios for different groups examined. In mandibular closure there is a relationship between anteroposterior and vertical movement (A/V ratio). The A/V ratios ranged from minus, indicating posterior movement, through zero ratios, indicating vertical movement with no anteroposterior component, to those higher than the range that would fall within hinge axis movements

	Swedish men	Chinese men	Chinese women
Mean	0.50	0.23	0.16
SD	0.22	0.32	0.38
Maximum	0.86	0.80	0.83
Minimum	-0.33	-0.20	-0.25
Calculated range	0.55-0.62	0.58-0.63	0.59-0.70

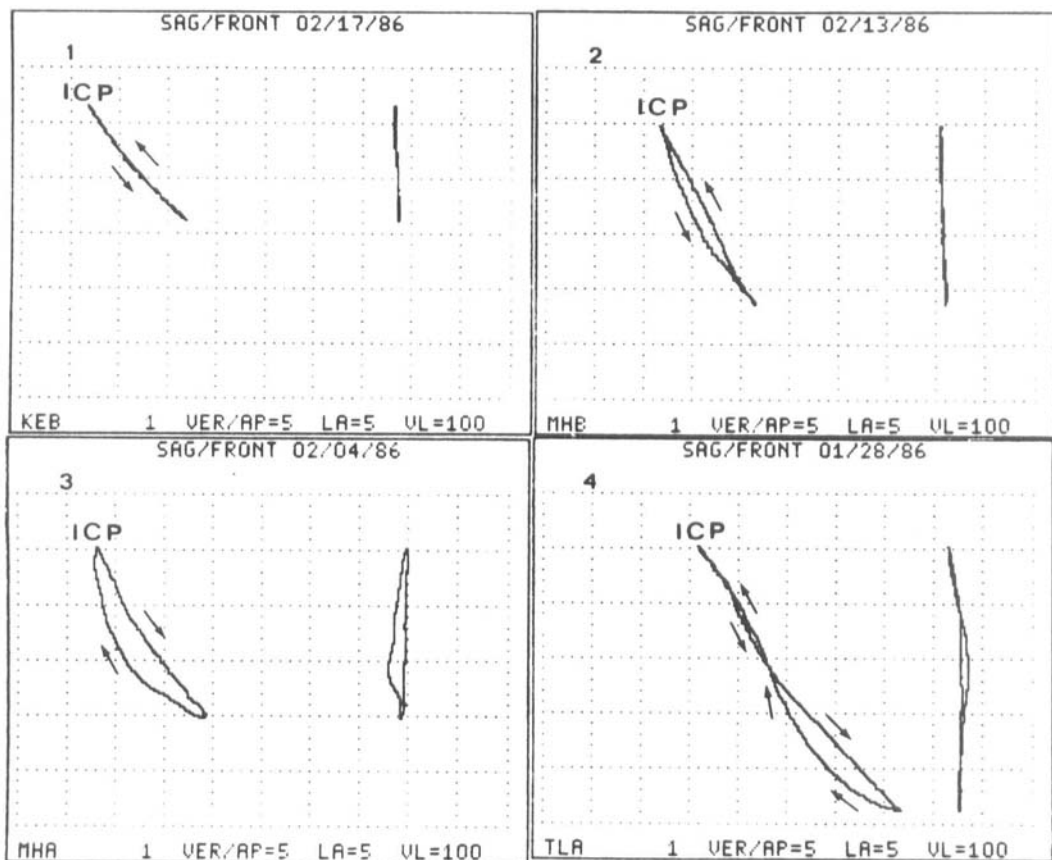


Fig. 3. Examples of the four categories of open/close trajectories variously described by an incisal point viewed simultaneously in the sagittal (left) and frontal (right) planes. ICP = intercuspal position, the position from which motion is initiated. Part 1: coincident opening and closing paths (C); part 2: the closing trajectory is posterior to that on opening (CP); part 3: the closing trace is anterior (CA); and part 4: the closing trajectory, initially anterior, crosses to complete closure posteriorly (X). Viewed frontally, all four examples show some deviation.



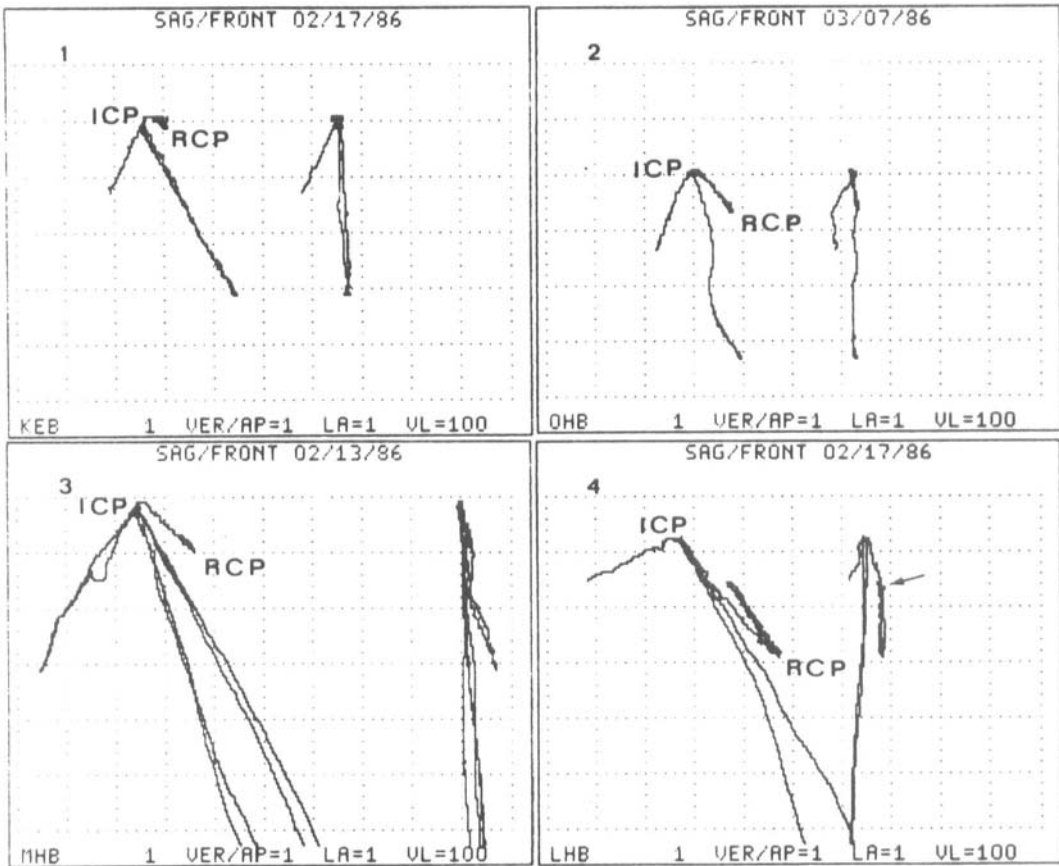


Fig. 4. Sagittal and frontal traces, including retrusive excursions from ICP to retruded contact position (RCP) and anterior guidance from ICP. Part 1 shows posterior movement horizontally of 0.5 mm to RCP, where the mandible wavered in three dimensions, ca. 0.3 mm<sup>3</sup>. Part 2 shows an S-shaped sagittal path of closure from rest position to ICP and a posteroinferior excursion of 0.8 × 0.7 mm to RCP, where slight tremor was evident while the position was maintained. Part 3 shows retrusion of 1.1 mm with a downwards movement of 0.9 mm to RCP, which could be held with minimal wavering. Part 4 shows a translation from ICP to RCP 2.1 mm posterior and 2.3 mm inferior to ICP, which was followed immediately by rebound to a position 0.9 mm posterior and 0.8 mm inferior to ICP, where the incisal point wavered in an area 0.4 mm to the patient's left (arrow on frontal trace). The frontal traces show that anterior guidance was associated with lateral components of movement to the right parts (1, 2, and 4) and to the left (part 3).

recorded on 34 out of 40 occasions. An absence of lateral movement was seen in the remaining six instances. Only one subject showed no lateral movement during either of the recording sessions, and in this he was absolutely consistent. Those who did show lateral components of movement showed a strong bias for one side, change of side being seen in only two instances. The range of lateral movements was 0.0–0.9 mm.

Opening and closing excursions viewed sagittally showed four distinct patterns of

closure: coincident (C), closing posteriorly (CP), closing anteriorly (CA), and crossover (X) (Fig. 3). The distribution of these patterns in this investigation showed that for most subjects their movement patterns were consistent, although some change did occur occasionally (Table 2 (section A)). In the Swedish subjects, when the number of open/close tasks was increased and interspersed among the other required maneuvers, the results showed that consistency throughout one session was confined to one individual

Table 3. Analysis of lateral cephalometric radiographs showing the equivalent to Balkwill's angle (ii-cd/OLi) in three groups studied, together with the approximate height for Bonwill's triangle (ii-cd) uncorrected for projection error (8.3% in Malmö and 8.75% in Hong Kong)

	Swedish men	Chinese men	Chinese women
Angle OLi/cd			
Mean	25.43	25.64	27.40
SD	0.93	1.48	3.66
Maximum	27.92	26.51	31.96
Minimum	25.57	23.43	22.84
Length ii-cd, mm			
Mean	107.35	101.49	100.84
SD	4.29	5.70	4.59
Maximum	111.55	108.36	108.42
Minimum	102.14	94.72	97.22

and that two or three different patterns were made by one subject during one recording session (Table 2 (section B)).

Voluntary mandibular retrusion to RCP viewed sagittally showed the maneuver to be three-dimensional and the retruded position to be unstable (Fig. 4). The extent of the posterior component had a mean value of  $1.10 \pm 0.69$  mm within the range 0.6–2.7 mm. Downwards movement was between 0.1 and 2.3 mm ( $\bar{x} = 1.08 \pm 0.92$  mm). Lateral deviation was between 0.2 and 0.4 mm to the right (Fig. 4, part 1) or left (Fig. 4, parts 2, 3, and 4).

Two subjects could not make voluntary retrusive excursions. One who could and did (Fig. 4, part 1), having closed from RP to ICP and then pulled back to his RCP, showed that his mandible, represented at an incisal point, wavered vertically, horizontally, and laterally within an area of approximately  $0.3 \text{ mm}^3$ . The sagittal/frontal traces in Fig. 4, part 2, show closure from RP to ICP along an S-shaped trajectory in the sagittal plane and retrusion to an unstable RCP, where the mandible quivered. The subject represented in Fig. 4, part 3, could hold his retruded position with minimal movement. Fig. 4, part 4, shows that this subject's mandible, having attained its most retruded position 2.1 mm posterior and 2.3 mm inferior to ICP, immediately rebounded upwards and forwards to a position 0.9 mm posterior, 0.8 mm inferior, and 0.4 mm to the left of ICP, where it wavered.

Protrusive excursions from ICP were also three-dimensional, having lateral motion in addition to the vertical and anterior movements.

The results of the analysis of the radiographs are shown in Table 3. This shows the distance between the incisal point and condyle (ii-cd) and the angles formed by this line with the occlusal plane line (OLi/cd) in the different groupings of test subjects. These measurements were applied to make drawings with allowance for magnet placement and the range of theoretical A/V ratios for the three groups of test subjects was calculated. They were found not to fit with the clinical performance (Table 1).

## Discussion

Identification of errors in the recording of the direction and magnitude of movements of an incisal point by the kinesiograph does not detract from its utility or importance as an instrument by means of which movements of the mandible can be visualized qualitatively and quantitatively in three orthogonal planes. This is particularly the case in relation to three-dimensional movements that occur in close proximity to the intercuspal position, where the instrument error is minimal.

Prosthetic teaching practice commonly includes recording of centric jaw relation and its transfer to the articulator by face-

bow for cast mounting. In connection with the delivery of a prosthesis, an articulator remount is used routinely (2). In the performance of this procedure, the articulator is closed on a hinge by the amount it was opened by the interocclusal remounting record, and the occlusion and articulation adjusted to this revised centric jaw relationship.

The geometry of the rigid articulator and the movements it can execute do not appear to be related to the highly variable and complex three-dimensional movements made by the functioning mandible, even in the zone close to the occlusal position. As has been shown by our data, during closure from RP to ICP the mandible may have, in addition to the vertical component of movement, some anterior movement; alternatively, it may move posteriorly. Neither vertical movement without any horizontal component nor vertical/posterior closure is compatible with the existence of a hinge axis but indicates translatory motion about an instantaneous center of rotation. The observation that closure through the interocclusal space is associated with translation is in agreement with the findings of Tallgren (22), in whose normal subjects it was in the range of  $-1.8$  to  $3.3$  mm. Similar findings were made by Posselt (8), Nevakari (23), and Sarnäs (24).

As Posselt (25) observed, prosthodontists are interested in centric jaw relation because of its reproducibility in recording procedures even though it is not a position used by 88% of subjects in function. Not only is it non-functional, it is also a position of strain. As data from our small sample of Swedish students showed, for those who could make retrusive mandibular excursions, it was usually a position that they could hold but briefly. The effort was accompanied by tremor or rebound to a more superior and anterior position still distal to ICP, where tremor was again evident. In its 'Glossary of prosthodontic terms' (26) the Academy of Denture Prosthetics gives three definitions for centric jaw relation. The second is 'The most posterior relation of the mandible to the maxillae at the established vertical dimension'. Our young dentate subjects generally found the most posterior relation of the mandible to the maxillae to be one they

could attain but could not retain without acute discomfort, which raises questions both of physiology and semantics, not to mention the implications for the utility of the hinge axis for the delivered occlusion. Brill et al. (27) noted the relief and enhanced comfort experienced by complete denture wearers when their occlusions were adjusted by grinding to locate the intercuspal position more anteriorly. However, this was not done by means of an articulator but was executed in the mouth. This would appear to be the only manner in which to promote harmony in the stomatognathic apparatus, since articulators cannot distinguish the small, crucial three-dimensional translatory movements required.

### Conclusions

No evidence emerged to suggest that the mandibular movements executed by the subjects in this study occurred about a single, fixed hinge axis. The occlusal terminus for movements was at the intercuspal position. Motion from RP to ICP involved a lateral component of movement in addition to those in vertical and horizontal directions. Voluntary retrusive movement from ICP to RCP also incorporated a lateral component, as did protrusive movements. Retruded contact position was both strained and unstable. Whereas articulators are useful in tooth setting and in designing of occlusal schemes for fixed prostheses, their use in diagnosis and the ultimate refinement of occlusion may introduce errors rather than facilitate their removal, since they cannot mimic the crucial three-dimensional movements required.

*Acknowledgements.*—Dr. Alvar Svensson, Faculty of Dentistry, University of Lund, designed and constructed the micromanipulator and Drs. Anders Winnberg and Ken Hansen supervised and assisted with the tracing of radiographs and performed the computer analyses. For their invaluable assistance, our sincere thanks. To those who submitted to being subjects in this study, our thanks for making it possible. We also wish to acknowledge the staff of the Dental Illustrations Unit, University of Hong Kong, who produced the drawings. This study was supported in part by a grant from the Faculty of Dentistry, University of Hong Kong.

## References

1. Paraskis C. Criteria for selecting an articulator to occlude and articulate teeth for full denture construction. *Dent Clin North Am* 1964;629-37.
2. Levin B, Sanders J. Results of a survey of complete denture procedures taught in American and Canadian dental schools: an up-date. *J Prosthet Dent* 1985;54:302-6.
3. Brekke C. Jaw function. I. Hinge rotation. *J Prosthet Dent* 1959;9:600-6.
4. Bonwill W. The scientific articulation of the human teeth as founded on geometrical, mathematical and mechanical laws. *Dent Items* 1899;21:617-36.
5. McCollum B. Fundamentals involved in prescribing restorative dental remedies. *Dent Items* 1939; 61:521-35.
6. Kingery R. Recording postural relations of the jaws. Articulators. In: Anthony L, ed. *The American textbook of prosthetic dentistry*. Philadelphia: Lea and Febiger, 1942;239.
7. Winstanley R. The hinge axis: a review of the literature. *J Oral Rehabil* 1985;12:135-59.
8. Posselt U. Studies in mobility of the human mandible [Thesis]. *Acta Odontol Scand* 1952;10(suppl 10).
9. Ulrich J. Undersøgelser over kaebeleddet hos mennesket med saerligt hensyn til de mekaniske forhold [Dissertation]. Copenhagen: Jacob Lunds Boghandel (Baldur Borgen), 1896.
10. Brekke C. Jaw function. II. Hinge axis, hinge axes. *J Prosthet Dent* 1959;9:936-40.
11. Koski K. Axis of the opening of the mandible. *J Prosthet Dent* 1962;12:888-94.
12. Gillings B, Graham C, Duckmanton N. Jaw movements in young adult men during chewing. *J Prosthet Dent* 1973;29:616-27.
13. Gillings B. Photoelectric mandibulograph: a technique for studying jaw movements. *J Prosthet Dent* 1967;17:109-21.
14. Shanahan T, Leff A. Mandibular and articulator movements. *J Prosthet Dent* 1959;9:941-5.
15. Jankelson B. Measurement accuracy of the mandibular kinesiograph—a computerized study. *J Prosthet Dent* 1980;44:656-66.
16. Hannam A, De Cou RE, Scott JD, Wood WW. The kinesiographic measurement of jaw displacement. *J Prosthet Dent* 1980;44:88-93.
17. Björk A. Kaebernes relation til det øvrige kranium. In: Lundström A, ed. *Nordisk lärobok i ortodonti*. Stockholm: Sveriges Tandläkarförbunds Förlagsförening, 1971;131-68.
18. Bergström G. On the reproduction of dental articulation by means of articulators. A kinematic investigation [Thesis]. *Acta Odontol Scand* 1950;9(suppl 4).
19. Christensen FT. The effect of Bonwill's triangle on complete dentures. *J Prosthet Dent* 1959;9:791-6.
20. Christensen FT. Balkwill's angle for complete dentures. *J Prosthet Dent* 1960;10:95-8.
21. Hickey T, Zarb B, Bolender C. Biological considerations of jaw relations and jaw movements. In: Boucher's prosthodontic treatment for edentulous patients. St Louis: The C.V. Mosby Co., 1985;243-6.
22. Tallgren A. Changes in adult face height due to ageing, wear and loss of teeth and prosthetic treatment. A roentgencephalometric study mainly on Finnish women [Thesis]. *Acta Odontol Scand* 1957;15(suppl 24).
23. Nevakari K. An analysis of the mandibular movement from rest to occlusal position. A roentgenographic-cephalometric investigation [Thesis]. *Acta Odontol Scand* 1956;14(suppl 19).
24. Sarnäs K. Inter- and intra-family variations in facial profile. An X-ray cephalometric investigation on young adult male sibs [Thesis]. *Odontol Rev* 1959;10(suppl 4).
25. Posselt U. Hinge opening axis of the mandible. *Acta Odontol Scand* 1956;14:49-63.
26. Glossary of prosthodontic terms. *J Prosthet Dent* 1977;38:66-109.
27. Brill N, Schübeler S, Tryde G. Influence of occlusal patterns on movements of the mandible. *J Prosthet Dent* 1962;12:255-61.