

# The effect of maxillary protraction on front occlusion and facial morphology

Per Johan Wisth, Aueporn Tritrapunt, Per Rygh, Olav E. Bøe and Kjartan Norderval

Department of Orthodontics and Facial Orthopedics, School of Dentistry, University of Bergen, Bergen, Norway

Wisth PJ, Tritrapunt A, Rygh P, Bøe OE, Norderval K. The effect of maxillary protraction on front occlusion and facial morphology. *Acta Odontol Scand* 1987;45:227-237. Oslo. ISSN 0001-6357.

The intention of this work was to study the dentoalveolar and basal jaw changes in a group of children (aged 5-10 years) with nonforced anterior crossbite treated with maxillary protraction from a face mask and to compare the changes with those found in a control group with normal dentoalveolar and basal maxillomandibular relationship. The data were obtained from lateral cephalograms of 22 children taken before treatment, after a treatment period of 3-12 months, and after an observation period of 6-48 months. A group of children ( $n = 40$ ) with normal maxillomandibular relationship served as controls. During treatment the mandibular prognathism was reduced, and a positive overjet was established in 18 children. The changes during the observation period were generally comparable to those found in the control group, and thus indicated a very small relapse tendency. The posttreatment comparison of the groups showed fewer significant differences than before treatment, indicating that the treatment had a normalizing effect not only on the negative overjet but also on the general face morphology. □ *Maxilla; morphology; occlusion; protraction*

*Per Johan Wisth, Department of Orthodontics and Facial Orthopedics, School of Dentistry, University of Bergen, Årstadveien 17, N-5009 Bergen, Norway*

Posteriorly directed forces have been used for decades to restrict anterior growth of the maxilla and to distalize the maxillary dentition, and the effect on both the position of the maxilla and adjacent bones and on the dentition is well described (1-5).

The effect of maxillary protraction forces has received much less attention. Animal experiments (6-9) have shown that the maxillary structures may be moved anteriorly but also that there is a relapse tendency after the active force application.

Protraction forces in humans have been used occasionally throughout the years (10-12). The theoretical basis for the treatment and an understanding of the morphologic response were given in the works of Delaire et al. (13, 14). They showed not only that the protraction forces resulted in a forward movement of the maxilla and a mesial shift of the maxillary dentition but also that they resulted in a posterior movement of the mandible. Thus protraction of the maxilla by elastics attached to a face mask may be an

alternative to other types of early treatment of class III malocclusion.

The intention of this work was to study the dentoalveolar and basal jaw changes in a group of children with nonforced anterior crossbite treated with maxillary protraction and to compare the changes with those found in a control group with normal dentoalveolar and basal maxillomandibular relationship.

## Materials and methods

The material comprised 22 children (15 girls and 7 boys) with a negative overjet. The age of the patients at the start of treatment varied from 5 to 10 years. An experienced orthodontist diagnosed that the anterior crossbite was not a result of an anterior forced bite.

A Quad-Helix expansion device was attached to the second deciduous molars and canines with hooks for elastic bands in the canine area (Fig. 1). It was activated for expansion only in children with a crossbite

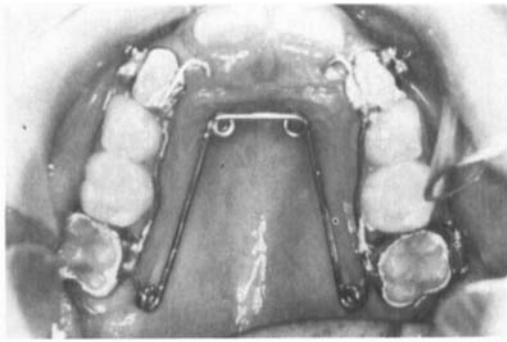


Fig. 1. The Quad Helix expansion device.

in the lateral segments. The face mask was adjusted to rest against the middle part of the forehead and as far down on the chin as possible (Fig. 2). The elastic bands from the canine area to the mask gave a force of about 300 g on each side, and were adjusted 15° downward in relation to the upper occlusal

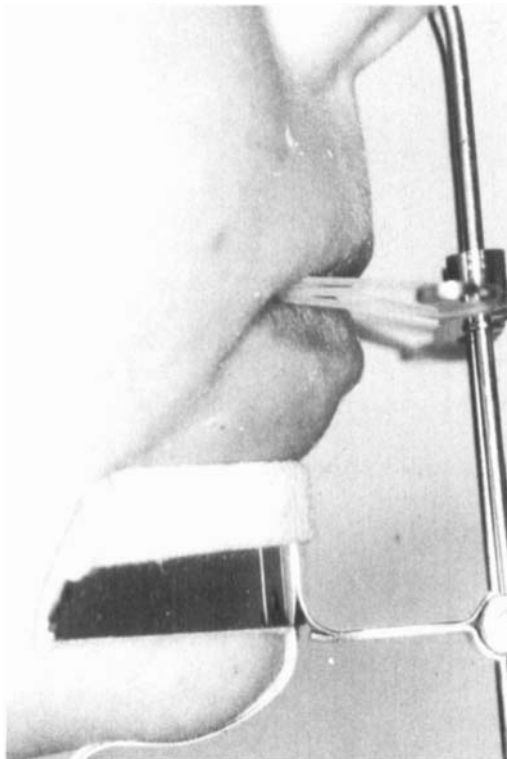


Fig. 2. Face mask with elastic bands attached to hooks in the canine area.

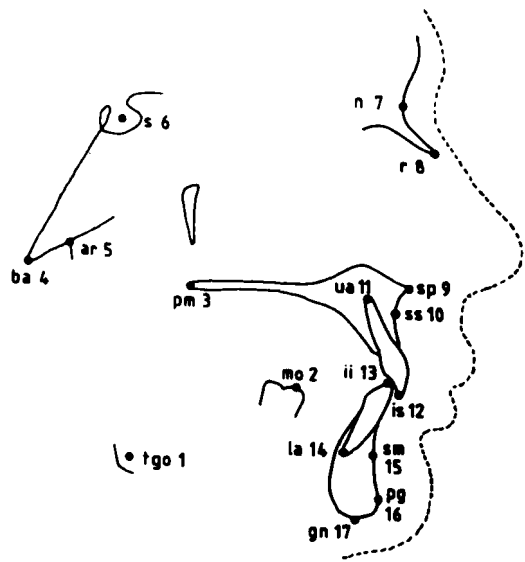


Fig. 3. Reference points.

plane. The children were instructed to use the mask 12 h per day and to change the elastics daily.

The treatment lasted until a positive horizontal overlapping was achieved (18 children treated for 3–12 months) or until the children had been under treatment for 12 months without achieving a positive overjet (4 children). All children were then observed for a period ranging from 6 to 48 months.

The data for this study were obtained from lateral cephalograms taken before treatment, at the end of active treatment, and at the end of the observation period. The reference points (Fig. 3) were digitized twice, and the mean of the coordinate values was used in the calculation of the variables used in the study (15).

The method error  $\tau$  was calculated from the formula  $\tau^2 = \Sigma d^2 / 2n$ , where  $d$  is the difference between corresponding values obtained from double tracings on all the 22 patients. The errors were generally small and comparable to those found in other cephalometric studies (11, 16–20).

The control group comprised 40 children (20 girls and 20 boys) with an age range of 4 to 9 years at the first observation. In this study the cephalograms were taken at the

first control visit and 12 and 24 months later. All had a positive overjet and a normal basal maxillomandibular relationship (ss-n-sm 0°-4°).

### Statistical methods

Standard statistics ( $\bar{x}$ , SD,  $x_{\min}$ ,  $x_{\max}$ ) were calculated to describe the treated group and the control group at the different observations, and the same statistics were used to describe the changes during the treatment and observation periods. The changes were examined by a paired *t* test. To compare the different groups, a two-sample *t* test was used when the variances of the groups were equal.

If not, a modified *t* test in which the variances of each population were estimated separately was used.

## Results

### Pretreatment face morphology

Table 1 shows that the mandible (s-n-sm, s-n-pg) was more prognathic in the treated group, the chin prominence somewhat more acute (pg·sm-gn·tgo), and the length of both the corpus of the mandible (pg-tgo) and the total mandible (pg-ar) was greater in the treated group.

Table 1. Pretreatment comparison of the dentofacial morphology of the treatment group ( $n = 22$ ) and the control group ( $n = 40$ )

Morphology	Treated group ( $n = 22$ )		Control group ( $n = 40$ )		<i>t</i>
	$\bar{x}$	SD	$\bar{x}$	SD	
Cranial base					
n-s-ba	130.2	3.84	131.2	4.57	-0.86
n-s (mm)	64.9	1.88	65.9	2.37	-1.81
Maxilla					
s-n-ss	79.8	3.84	81.1	3.02	-1.53
n-s-pm	68.3	3.38	67.5	3.13	0.97
sp·pm-n·s	5.9	2.90	5.5	3.02	0.48
Mandibula					
s-n-sm	79.6	3.09	77.4	2.79	2.79**
s-n-pg	79.4	3.21	77.1	2.62	3.01**
gn·tgo-s·n	34.9	4.71	34.1	3.98	0.67
n-s-tgo	100.6	3.58	99.0	3.76	0.74
n-s-ar	120.6	4.36	120.9	5.33	-0.23
pg·sm-gn·tgo	67.1	6.20	70.5	4.92	-2.20*
ar-tgo-gn	129.0	5.80	129.8	4.31	-0.60
pg-tgo (mm)	67.4	3.35	62.9	3.48	4.92**
pg-ar (mm)	94.0	4.62	90.0	3.52	3.75**
Intermaxillary					
ss-n-sm	0.2	2.01	3.7	2.04	-6.49**
n-ss-pg	179.2	4.90	171.8	4.55	6.01**
gn·tgo-sp·pm	29.0	4.73	28.6	3.74	0.36
Incisor position					
ua·is-n·ss	19.1	7.36	11.0	7.17	4.21**
n·ss-is (mm)	0.1	3.42	-0.4	1.89	0.65
la·ii-n·sm	18.7	5.69	16.9	5.58	1.17
n·sm-ii (mm)	2.3	2.24	1.1	1.57	2.32*
ua·is-la·ii	142.0	9.35	148.5	9.98	-2.51*
is-ii (hor) (mm)	-1.9	1.60	2.9	1.82	-10.45**
is-ii (ver) (mm)	-5.6	6.48	0.2	2.45	-4.06**

\*  $P < 0.05$ .

\*\*  $P < 0.01$ .

The ss-n-sm angle was significantly smaller in the treated group, and the profile (n-ss-pg) was straighter.

The position and inclination of the incisors were also different, but that is only natural, since this was the criterion for the selection of the material.

#### *Changes during active treatment and in the control group during the same time span*

Table 2 shows the changes of the variables during the active treatment period. The protrusion of the mandible (s-n-sm, s-n-pg) was reduced, and so was the chin prominence (pg·sm-gn·tgo). The length of the mandible increased (pg-tgo, pg-ar).

The ss-n-sm angle increased, and the concavity of the profile (n-ss-pg) was reduced.

The interbase angle increased (gn·tgo-sp·pm) and both the overjet (is-ii (hor.) mm) and overbite (is-ii (ver.) mm) increased. The mean changes are shown in Fig. 4.

Table 3 gives a comparison between the changes during active treatment and the changes during the corresponding year for the children in the control group. The anterior cranial base (n-s) increased more in the control group. The posterior part of the maxilla (n-s-pm) moved more backwards in the control group. In the mandible the protrusion was reduced in the treated group (s-n-sm, s-n-pg), and its inclination (gn·tgo-n·s) increased more than in the control group. The length of the mandible (pg-tgo, pg-ar) increased more in the control group.

The ss-n-sm angle increased more in the treated group, and the face convexity (n-ss-

Table 2. Changes in craniofacial morphology during the period with active anterior traction ( $n = 22$ )

Morphology	$\bar{d}$	SD	$d_{\min}$	$d_{\max}$	$t$
Cranial base					
n-s-ba	-0.2	1.32	-3.1	1.8	-0.73
n-s (mm)	0.4	0.88	-4.1	2.5	2.00
Maxilla					
s-n-ss	0.3	1.51	-3.1	3.0	0.93
n-s-pm	0.1	1.76	-2.4	3.7	0.21
s·pm-n·s	-0.1	1.24	-1.9	3.1	-0.26
Mandibula					
s-n-sm	-0.9	1.12	-3.5	1.0	-3.93**
s-n-pg	-0.6	1.35	-3.2	1.4	-2.24*
gn·tgo-n·s	0.9	1.58	-2.9	3.9	2.77*
n-s-tgo	1.2	1.99	-3.7	4.9	2.73*
n-s-ar	0.0	1.80	-3.1	4.2	-0.06
pg·sm-gn·tgo	-2.4	2.98	-8.2	2.3	-3.73**
ar-tgo-gn	-0.8	2.23	-5.1	3.8	-1.68
pg-tgo (mm)	1.1	1.44	-1.2	5.2	3.54**
pg-ar (mm)	0.7	1.13	-0.9	3.2	3.08**
Intermaxillary					
ss-n-sm	1.2	1.30	-1.2	3.8	4.47**
n-ss-pg	-1.9	2.84	-7.7	3.2	-3.08**
gn·tgo-sp·pm	1.0	1.86	-3.3	4.2	2.55*
Incisor position					
ua·is-n·ss	1.9	4.80	-8.4	8.3	1.85
n·ss-is (mm)	1.6	1.80	-2.1	4.9	4.11**
la·ii-n·sm	-2.0	4.97	-9.3	8.9	-1.90
n·sm-ii (mm)	-0.3	1.24	-2.3	1.8	-1.25
ua·is-la·ii	-1.2	6.62	-14.2	12.9	-0.82
is-ii (hor) (mm)	3.4	1.80	-1.1	6.1	8.87**
is-ii (ver) (mm)	3.9	4.58	-0.8	12.1	4.03**

\*  $P < 0.05$ .

\*\*  $P < 0.01$ .

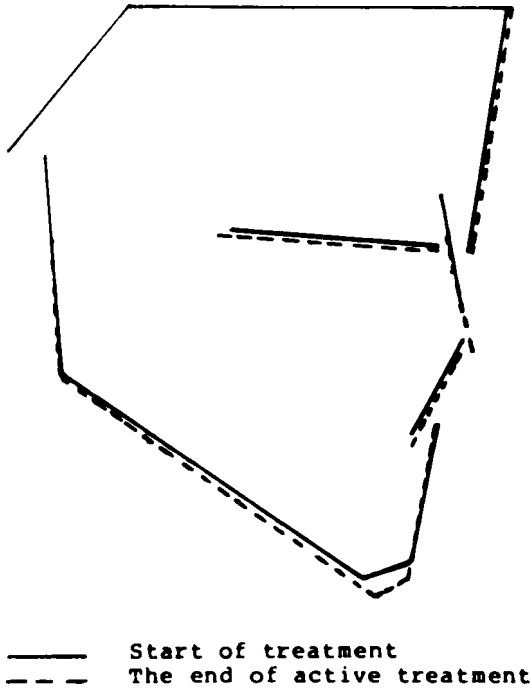


Fig. 4. Changes in morphology during the period with maxillary protraction.

pg) also increased more, as did the interbase angle (gn·tgo·sp·pm).

The lower incisors were retroclined (la·ii·n·sm, n·sm·ii) in the treated group. The interincisor angle (ua·is·la·ii) was less reduced in the treated group, and both the overjet (is·ii (hor)) and overbite (is·ii (ver)) increased more in that group.

*Changes during the observation period in the treated group and the control group*

The cranial base length (n·s) (Table 4) continued to increase during the observation period. The posterior part of the maxilla (n·s·pm) moved forward, and the inclination of the maxilla (sp·pm·n·s) increased. The prognathism of the mandible increased (s·n·sm, s·n·pg), whereas the chin prominence (pg·sm·gn·tgo) decreased. The length of the mandible (pg·tgo, pg·ar) increased.

The ss·n·sm angle was reduced, and the skeletal profile (n·ss·pg) was straightened. The interbase angle (gn·tgo·sp·pm) was reduced.

The protrusion of both the upper (ua·is·n·ss, n·ss·is) and lower incisors (la·ii·n·sm, n·sm·ii) increased, and consequently the interincisor angle was reduced. The overjet (is·ii (hor) mm) was insignificantly reduced, and the overbite (is·ii (ver) mm) was increased. Fig. 5 shows the mean changes during the observation period.

The changes in the treated group and the control group (Table 5) were very similar. The only significant differences were a greater anterior change of the posterior part of the maxilla in the treated group (n·s·pm) and a greater protrusion of the lower incisors (la·ii·n·sm) in the same group.

*Postobservation morphology*

The treated group and the control group (Table 6) showed only a few significant differences. The chin prominence (pg·sm·gn·tgo) was more acute in the treated group and the length of the mandibular corpus (pg·tgo) was greater.

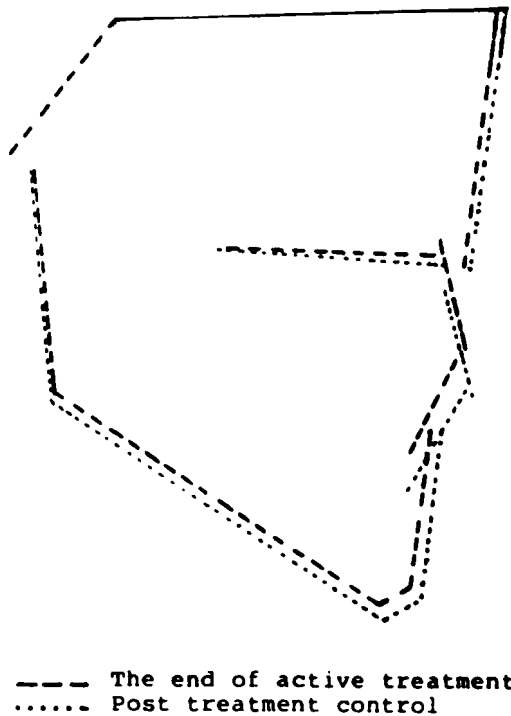


Fig. 5. Changes in morphology during the observation period.

The ss-n-sm angle was smaller in the treated group, and the skeletal profile (n-ss-pg) was straighter. The incisor position did not differ significantly in the two groups, but both the overjet (is-ii (hor)) and overbite (is-ii (ver)) were less in the treated group.

## Discussion

An evaluation of treatment results is directly related to the changes during treatment but should in children also be related to the normal growth and developmental changes in a comparable control group. The true effect of the treatment can only be seen if the control group is matched with the

experimental group with regard to age, sex, length of the observation period, and type of malocclusion.

In this study it was impossible (and unethical) to set up a control group with untreated malocclusions. Therefore a control group with normal maxillomandibular relationship but otherwise comparable to the treated group was used. This material was collected during the years 1964–1970, but it seems unlikely that this difference in time between the two materials should have influenced the results.

The pretreatment selection of the material was based on a clinical diagnosis only and included the criterion that both patients with a negative overjet caused by a retrognathic

Table 3. Changes in craniofacial morphology of the treated group ( $n = 22$ ) and the control group ( $n = 40$ ) during the period with active anterior traction

Morphology	Treated group ( $n = 22$ )		Control group ( $n = 40$ )		<i>t</i>
	$\bar{d}$	SD	$\bar{d}$	SD	
Cranial base					
n-s-ba	-0.2	1.32	0.0	1.53	-0.49
n-s (mm)	0.4	0.88	1.0	0.71	-2.97**
Maxilla					
s-n-ss	0.3	1.51	-0.1	1.11	1.30
n-s-pm	0.1	1.76	1.0	1.67	-2.00*
sp · pm · n · s	-0.1	1.24	0.3	1.38	-1.16
Mandibula					
s-n-sm	-0.9	1.12	-0.4	1.04	-2.02*
s-n-pg	-0.6	1.35	0.1	0.95	-2.16*
gn · tgo · n · s	0.9	1.58	0.0	1.21	2.48*
n-s-tgo	1.2	1.99	1.1	1.49	0.18
n-s-ar	0.0	1.80	1.1	2.36	-1.96
pg · sm · gn · tgo	-2.4	2.98	-2.9	3.31	0.61
ar-tgo-gn	-0.8	2.23	-0.4	2.47	-0.55
pg-tgo (mm)	1.1	1.44	2.4	1.33	-3.74**
pg-ar (mm)	0.7	1.13	2.6	1.65	-4.63**
Intermaxillary					
ss-n-sm	1.2	1.30	0.2	1.38	2.82*
n-ss-pg	-1.9	2.84	0.4	2.57	-3.04**
gn · tgo · sp · pm	1.0	1.86	-0.3	1.77	2.84**
Incisor position					
ua · is · n · ss	1.9	4.80	4.6	7.50	-1.51
n · ss-is (mm)	1.6	1.80	1.1	1.80	0.99
la · ii · n · sm	-2.0	4.97	2.6	5.82	-3.15**
n · sm-ii (mm)	-0.3	1.24	0.8	1.37	-3.19**
ua · is-la · ii	-1.2	6.62	-7.8	10.91	2.96**
is-ii (hor) (mm)	3.4	1.80	0.7	2.42	4.62**
is-ii (ver) (mm)	3.9	4.58	0.9	2.47	2.86**

\*  $P < 0.05$ .

\*\*  $P < 0.01$ .

position of the maxilla and patients with a prognathic position of the mandible were included in the material. This was natural, since the main aim of the work was to study the changes in dentofacial morphology caused by the mask treatment of negative overjet.

The pretreatment comparison with the control group (Table 1) showed differences in the position and size of the mandible, indicating that the main reason for the negative overjet was a prognathic position and an increased length of the mandible. The figures also indicate a somewhat retrognathic position of the maxilla, even though this was not significant. The resulting intermaxillary relationship was highly significantly different in the two groups. The mean ss-n-sm value was, however, positive also in the experimental group, and the standard deviation

showed that both patients with skeletal and patients with dentoalveolar deviations were included in the material. The incisor position reflected the transitional stage of occlusion in both groups with an increased interincisor angle compared with what is found in the permanent dentition (21). The upper incisors were, however, more protruded in the experimental group, thus indicating a compensation for the sagittal deviation even at this early age. This compensation is even more typical in older age groups (22).

It has been shown (23) that transversal expansion of the maxilla may result in an anterior movement of point ss and that the whole maxillary complex may be movable up to 7–8 years of age (14). Autopsy studies (24) have indicated that changes in the maxillary complex as a result of orthopedic forces will be localized in the palatomaxillary

Table 4. Changes in craniofacial and facial morphology after the removal of the appliance ( $n = 22$ )

Morphology	$\bar{d}$	SD	$d_{\min}$	$d_{\max}$	$t$
Cranial base					
n-s-ba	0.4	1.87	-3.0	4.6	0.92
n-s (mm)	1.1	1.02	-0.8	3.0	5.10**
Maxilla					
s-n-ss	-0.1	1.41	-1.9	2.2	-0.18
n-s-pm	1.8	1.94	-1.9	5.4	4.45**
sp · pm · n · s	0.6	1.34	-3.1	2.6	2.09*
Mandibula					
s-n-sm	0.6	1.32	-1.8	3.4	2.18*
s-n-pg	0.8	1.34	-1.1	3.7	2.77*
gn · tgo · n · s	-0.7	1.59	-3.6	2.1	-2.09*
n-s-tgo	-0.1	1.25	-2.5	1.9	-0.44
n-s-ar	0.2	1.73	-2.5	5.0	0.51
pg · sm · gn · tgo	-1.3	2.14	-5.3	3.0	-2.87**
ar-tgo-gn	-0.3	1.98	-4.8	4.4	-0.80
pg-tgo (mm)	2.0	1.99	-1.0	6.5	4.69**
pg-ar (mm)	2.8	2.82	-1.3	12.2	4.71**
Intermaxillary					
ss-n-sm	-0.7	0.91	-2.2	1.1	-3.38**
n-ss-pg	1.7	2.17	-2.7	5.7	3.64**
gn · tgo · sp · pm	-1.3	1.99	-5.0	2.4	-3.12**
Incisor position					
ua · is · n · ss	2.2	4.75	-4.2	11.4	2.13*
n · ss-is (mm)	1.3	1.63	-1.6	4.3	3.64**
la · ii · n · sm	4.7	6.66	-6.7	18.9	3.29**
n · sm-ii (mm)	0.9	1.26	-1.0	3.4	3.40**
ua · is-la · ii	-6.2	9.21	-22.0	11.4	-3.13**
is-ii (hor) (mm)	-0.4	1.85	-6.3	3.0	-1.02
is-ii (ver) (mm)	2.0	2.90	-1.0	8.4	3.27**

\*  $P < 0.05$ .

\*\*  $P < 0.01$ .

region. Experiments in monkeys with anterior forces of 500 g (9) showed that the zygomaticomaxillary suture displayed the greatest activity during forward displacement of the maxilla.

Other cephalometric studies have shown an increase in the prognathism of the maxilla during anterior traction treatment (11, 16–20). These findings were not statistically significant in this study, even though there was a slight increase in the s-n-ss angle. The reason may be that point n was moved anteriorly together with the maxillary complex and would conceal the anterior movement of the maxilla. However, the increase in the distance s-n was greater in the control group than in the treated group, and thus this hypothesis has to be rejected. A more likely

explanation is the difficulty in defining point ss accurately in this young age group. The unerupted permanent incisors tend to influence the position of point ss anteriorly. The change in the inclination of the maxilla which has been reported by anterior traction in cleft-palate patients (25) was not found in this material.

The changes in the mandible were greater than those in the maxilla and also differed significantly from the control group. The protrusion was reduced, and the increases in the linear dimensions were less than those in the control group. These findings correspond well with those of other workers (11, 16, 20).

The treatment resulted in a posterior rotation of the mandible and an increase of the angle between the basal parts of the

Table 5. Changes in craniofacial morphology of the treated group ( $n = 22$ ) and the control group ( $n = 40$ ) during the observation period

Morphology	Treated group ( $n = 22$ )		Control group ( $n = 40$ )		<i>t</i>
	$\bar{d}$	SD	$\bar{d}$	SD	
<b>Cranial base</b>					
n-s-ba	0.4	1.87	-0.4	1.67	1.71
n-s (mm)	1.1	1.02	0.7	1.17	1.45
<b>Maxilla</b>					
s-n-ss	-0.1	1.41	0.0	1.21	-0.03
n-s-pm	1.8	1.94	0.5	1.98	2.42*
sp·pm-n·s	0.6	1.34	0.3	1.97	0.65
<b>Mandibular</b>					
s-n-sm	0.6	1.32	0.4	1.14	0.58
s-n-pg	0.8	1.34	0.6	1.01	0.48
gn·tgo-n·s	-0.7	1.59	-0.9	1.28	0.47
n-s-tgo	-0.1	1.25	0.1	1.70	-0.59
n-s-ar	0.2	1.73	-0.3	2.13	0.92
pg·sm-gn·tgo	-1.3	2.14	-0.9	2.10	-0.64
ar-tgo-gn	-0.3	1.98	-1.3	2.33	1.63
pg-tgo (mm)	2.0	1.99	1.7	1.55	0.64
pg-ar (mm)	2.8	2.82	1.9	1.44	1.37
<b>Intermaxillar</b>					
ss-n-sm	-0.7	0.91	-0.4	1.10	-0.73
n-ss-pg	1.7	2.17	1.4	2.05	0.51
gn·tgo-sp·pm	-1.3	1.99	-1.1	1.84	-0.34
<b>Incisor position</b>					
ua·is-n·ss	2.2	4.75	4.1	6.35	-1.21
n·ss-is (mm)	1.3	1.63	1.8	1.46	-1.18
la·ii-n·sm	4.7	6.66	0.5	5.25	2.64*
n·sm-ii (mm)	0.9	1.26	0.4	1.43	1.34
ua·is-la·ii	-6.2	9.21	-4.1	9.22	-0.81
is-ii (hor) (mm)	-0.4	1.85	0.4	2.56	-1.24
is-ii (ver) (mm)	2.0	2.90	1.8	2.67	0.30

\*  $P < 0.05$ .

maxilla and the mandible, corresponding to the findings in other studies (14, 17, 20). This posterior rotation will also automatically reduce the prognathism of the mandible and contribute to the change of the position of the sm and pg points. The mean maxillary and mandibular changes were small. The outcome was, however, a significant change in the basal maxillomandibular relationship (the ss-n-sm angle increased), and an increase of the profile convexity.

The difference in incisor position between the treated and the control group is most likely due to the treatment. The result of the combined skeletal and dental changes was the establishment of a positive overjet and overbite in most of the patients. It would be interesting to know whether there was a

morphologic difference between those responding favorably to the treatment and those who did not, but the material was not suitable for such a comparison.

Animal studies have shown that the treatment effects on the maxilla remain stable (26), and the same is also reported in humans (17). Rune et al. (19), on the other hand, reported relapse in an 11-year-old boy with maxillonasal dysplasia treated with a face mask. Jackson et al. (7) found that the degree of relapse was negatively correlated to the length of stabilization. In our study no retention was used. During the observation period (Table 4) many variables changed significantly. Those indicating a relapse showed an increase of the mandibular prognathism and an anterior translation of the

Table 6. Posttreatment comparison of the dentofacial morphology of the treated group ( $n = 22$ ) and the control group ( $n = 40$ )

Morphology	Treated group ( $n = 22$ )		Control group ( $n = 40$ )		<i>t</i>
	$\bar{x}$	SD	$\bar{x}$	SD	
<b>Cranial base</b>					
n-s-ba	130.3	3.92	130.0	4.08	0.28
n-s (mm)	66.3	2.28	67.7	2.94	-1.78
<b>Maxilla</b>					
s-n-ss	80.0	4.27	81.3	3.30	-1.25
n-s-pm	70.2	3.82	68.6	3.43	1.59
sp · pm · n · s	6.5	2.98	5.8	3.32	0.73
<b>Mandibular</b>					
s-n-sm	79.2	3.27	77.7	2.68	1.88
s-n-pg	79.5	3.31	78.1	2.35	1.76
gn · tgo · n · s	35.1	4.91	32.8	4.15	1.87
n-s-tgo	101.7	3.29	100.7	3.61	0.95
n-s-ar	120.8	4.14	121.2	4.80	-0.37
pg · sm · gn · tgo	63.4	4.85	66.6	5.76	-2.16*
ar-tgo-gn	127.9	5.81	128.1	5.04	-0.14
pg-tgo (mm)	70.5	4.16	67.1	3.61	3.21**
pg-ar (mm)	97.5	6.05	94.6	3.65	2.04
<b>Intermaxillary</b>					
ss-n-sm	0.8	2.39	3.6	2.19	-4.47**
n-ss-pg	179.1	5.69	173.4	5.21	3.86**
gn · tgo · sp · pm	28.7	5.27	27.0	4.30	1.26
<b>Incisor position</b>					
ua · is · n · ss	23.2	7.09	19.8	6.32	1.89
n · ss · is (mm)	3.0	2.70	2.5	2.21	0.72
la · ii · n · sm	21.4	5.87	21.1	6.86	0.17
n · sm · ii (mm)	2.9	2.18	2.6	1.69	0.68
ua · is · la · ii	134.6	8.77	135.6	9.94	-0.36
is-ii (hor) (mm)	1.1	2.11	4.0	1.91	-5.32**
is-ii (ver) (mm)	0.3	2.47	2.8	2.80	-3.36**

\*  $P < 0.05$ .

\*\*  $P < 0.01$ .

mandible. However, when compared with the changes of the control group during the same period, they were insignificant and thus probably reflected normal development. The relapse changes in a group of children with the same age distribution and negative overjet treated with chin-cap and retractor were generally greater (27).

A change indicating a long-term effect of the treatment was the continuous increase in the protrusion of the posterior part of the maxilla (n-s-pm). This may be caused by an increased sutural activity with remodeling due to the protraction forces. Such a hypothesis is supported by autopsy studies (24) and animal experiments (9).

The only significant dental change between the groups was a greater protrusion of the lower incisors in the treated group. This indicates a relapse of the treatment, but still the overjet remained positive, even though it was somewhat reduced. Jackson et al. (7) stated that the dental relapse can be greatly reduced by a period of stabilization. It is likely therefore that the clinical results of our study would have been even better and more stable after a retention period.

An evaluation of the pretreatment and posttreatment morphology compared with that of the control group showed fewer significant differences after than before treatment. It therefore seems that the mask treatment had a normalizing effect not only on the negative overjet but also on the general face morphology during the period studied. Further studies are needed to show whether this positive effect will last throughout the rest of the growth period.

## References

1. Wieslander L. The effect of orthodontic treatment on the concurrent development of the craniofacial complex. *Am J Orthod* 1963;49:15-27.
2. Melsen B, Enemark H. Effect of cervical anchorage studied by the implant method. *Trans Eur Orthod Soc* 1969;435-47.
3. Wieslander L, Buck DL. Physiologic recovery after cervical traction therapy. *Am J Orthod* 1974;66:294-301.
4. Wieslander L. Early or late cervical traction therapy of class II malocclusion. *Am J Orthod* 1975;67:432-9.
5. Bernstein M, Rosol ML Jr, Gianelly AA. A Biometric study of orthopedically directed treatment of cl. II malocclusion. *Am J Orthod* 1976;70:683-9.
6. Dellinger EL. A preliminary study of anterior maxillary displacement. *Am J Orthod* 1973;63:509-16.
7. Jackson GW, Kokich VG, Shapiro PA. Experimental response to anteriorly directed extraoral force in young *Macaca nemestrina*. *Am J Orthod* 1979;75:319-33.
8. Kambara T. Dentofacial changes produced by extraoral forward force in the *Macaca irus*. *Am J Orthod* 1977;71:249-77.
9. Nanda R. Differential response of midfacial sutures and bones to anteriorly directed extraoral forces in monkeys [Abstract]. *J Dent Res* 1978;57A(spec iss):362.
10. Nelson FO. A new extraoral orthodontic appliance. *Int J Orthodont* 1968;6:24-7.
11. Irie M, Nakamura S. Orthopedic approach to severe skeletal class III malocclusion. *Am J Orthod* 1975;67:377-92.
12. Nanda R. Biomechanical and clinical considerations of a modified protraction headgear. *Am J Orthod* 1980;78:125-39.
13. Delaire J, Verdon P, Lumineau JP, et al. Quelques résultats des tractions extra-orales a appui fronto-mentonnier dans le traitement orthopédique des malformations maxillo-mandibulaires de classe III et des séquelles osseuses des fentes labio-maxillaires. *Rev Stomatol Chir Maxillofac* 1972;73:633-42.
14. Delaire J, Verdon P, Flour J. Ziele und Ergebnisse extraoraler Züge in postero-anteriorer Richtung in Anwendung einer orthopädischen Maske bei der Behandlung von Fallen der Klasse III. *Fortschr Kieferorthop* 1976;37:247-62.
15. Gjerdet NR. Kefalo. Datasystem for behandling av kefalometriske målinger. Bergen: Institutt for odontologisk teknologi, Universitetet i Bergen, 1983.
16. Van Put E. Les résultats téléradiographiques de la force extra-oral de Delaire. *Rev Stomatol Chir Maxillofac* 1976;77:192-4.
17. Subtelny JD. Oral respiration: facial maldevelopment and corrective dentofacial orthopedics. *Angle Orthodontist* 1980;50:147-64.
18. Cozzani G. Extraoral traction and class III treatment. *Am J Orthod* 1981;80:638-50.
19. Rune B, Sarnäs KV, Selvik G, et al. Posteroanterior traction in maxillonasal dysplasia (Binder syndrome). A roentgen stereometric study with the aid of metallic implants. *Am J Orthod* 1982;81:65-70.
20. Campbell PM. The dilemma of class III treatment. Early or late. *Angle Orthodontist* 1983;53:175-91.
21. Platou C, Zachrisson BU. Incisor position in Scandinavian children with ideal occlusion. A comparison with the Ricketts and Steiner standards. *Am J Orthod* 1983;83:341-52.
22. Wisth PJ. Pre- and postsurgical face morphology of patients with mandibular prognathism. Bergen:

Department of Orthodontics and Facial Orthopedics, University of Bergen, 1986.

23. Haas AJ. Palatal expansion: just the beginning of dentofacial orthopedics. *Am J Orthod* 1970;57:219-55.
24. Melsen B, Melsen F. The postnatal development of the palato-maxillary region studied on human autopsy material. *Am J Orthod* 1982;82:329-42.
25. Rygh P, Tindlund R. Orthopedic expansion and protraction of the maxilla in cleft palate patients. A new treatment rationale. *Cleft Palate J* 1982;19:104-12.
26. Cederquist R. Degree of stability following experimental alteration of midfacial growth with heavy intermittent force. *Proc Inst Med Chic* 1978;32:50-1.
27. Stensland A, Wisth PJ, Bøe OE. Dentofacial changes in children with negative overjet treated by a combined orthodontic and orthopedic approach. *Eur Orthod J* 1986 (in press).

---

Received for publication 1 February 1987