

Validation of DIAGNOdent for quantification of smooth-surface caries: an in vitro study

Xie-Qi Shi, Sofia Tranæus and Birgit Angmar-Månsson

Department of Cariology and Endodontology, Institute of Odontology, Karolinska Institutet, Huddinge, Sweden

Shi XQ, Tranæus S, Angmar-Månsson B. Validation of DIAGNOdent for quantification of smooth-surface caries: an in vitro study. *Acta Odontol Scand* 2001;59:74–78. Oslo. ISSN 0001-6357.

The aims were 1) to validate a laser-based device, KaVo DIAGNOdent, for quantification of caries lesions on smooth surfaces, using histopathologic and microradiographic analyses as the gold standard, and 2) to test inter- and intra-observer agreements. We also investigated the influence on DIAGNOdent readings of the storage medium used for extracted teeth. Two observers measured independently the tooth surfaces of 40 extracted premolars that had been stored in thymol-saturated saline. After subsequent storage in neutral-buffered formalin for 14 days they were re-measured. The teeth were then sectioned for histopathologic and microradiographic analysis. The Spearman rank correlation coefficients between lesion depth and DIAGNOdent readings were 0.78–0.83 and 0.85 for teeth stored in thymol-saturated saline and formalin, respectively. Inter- and intra-observer agreements were 0.94 and 0.95 when the teeth were stored in thymol-saturated saline. The DIAGNOdent reading was almost 1.5 times higher for teeth stored in formalin than for those stored in thymol saline. The Spearman rank correlation coefficient between mineral loss in enamel (ΔZ) and DIAGNOdent readings ranged from 0.64 to 0.68. It was concluded that DIAGNOdent may be helpful for assessing smooth-surface caries, but the cut-off points need to be assessed under clinical conditions. The increase in fluorescence associated with storage of teeth in formalin warrants further investigation. □ *Caries detection; laser fluorescence; microradiography; smooth-surface caries*

Birgit Angmar-Månsson, Department of Cariology and Endodontology, Institute of Odontology, Karolinska Institutet, Box 4064, SE-141 04 Huddinge, Sweden. Tel: +46-8-728 82 61, fax: +46-8-711 83 43, e-mail: Birgit.Angmar-Mansson@ofa.ki.se

Methods offering accurate detection and quantification of smooth-surface caries would have extensive application, not only as aids to correct clinical diagnosis. In evaluating the outcome of preventive and non-invasive treatment interventions, such methods could also be used to monitor changes in the mineral content of lesions on a longitudinal basis.

The conventional clinical approach to detection of smooth-surface caries comprises visual inspection. Only a few methods for quantification of smooth-surface caries have been introduced and investigated; these include quantitative laser/light induced fluorescence (QLF) (1–4) and digital imaging fiber-optic transillumination (DIFOTI) (5).

DIAGNOdent (DIAGNOdent, KaVo, Biberach, Germany) is a recently introduced laser fluorescence device for caries detection and quantification on both occlusal and smooth surfaces (6). The main unit generates laser light with a wavelength of 655 nm, which is absorbed by both organic and inorganic material in the tooth and re-emitted as fluorescence within the infrared region. In the presence of caries fluorescence increases, and the change is registered as an increased digital number. The mechanism underlying the enhanced fluorescence in the presence of caries has yet to be established but is presumed to result from the integration of bacterial metabolites rather than crystalline disintegration (7).

DIAGNOdent has been evaluated in several studies,

mostly for detection and quantification of occlusal caries (8–10). Good reproducibility is reported, and it is considered a feasible method.

The present in vitro study was designed to test the hypothesis that the correlation between DIAGNOdent registrations and lesion depth for smooth-surface caries is similar to that reported previously for occlusal caries. Since it was easier to collect a sufficient number of teeth with approximal lesions, those were studied rather than lesions on buccal/lingual surfaces.

The aims of the study were to test detection and quantification of smooth-surface caries by DIAGNOdent, using transverse microradiography and histopathology as standard references. In addition, the possible influence of storage medium on DIAGNOdent readings was investigated, and inter- and intra-observer agreements were assessed for quantification of smooth-surface caries by DIAGNOdent.

Materials and methods

Teeth

The material comprised 40 premolar teeth, extracted from young adolescents on orthodontic indications. Visual inspection of the 80 approximal surfaces showed that 11 were visually sound, 5 had cavities, and the other 64 had

caries without cavitation on the approximal surfaces. These lesions were used as a replacement for buccal and lingual surface lesions. The teeth were rinsed thoroughly under tap water and cleaned with a toothbrush. They were then stored in thymol-saturated saline under refrigeration.

Photographic documentation of study sites

Each of the approximal surfaces was photographed with a digital camera (Kodak DC210). For magnified images, a 5× magnifier was suspended about 10 cm from the tooth surface. The images of the teeth were saved on a PC to facilitate comparison of the measurements made by the two observers and the subsequent orientation of tooth slices for histopathology and transverse microradiography (TMR).

Teeth stored in thymol solution

Two observers measured the 80 surfaces independently, using DIAGNOdent (DIAGNOdent; KaVo, Biberach, Germany) under identical physical conditions. The teeth were retrieved from the thymol-saturated saline, wiped with tissue and dried with compressed air for about 8 sec. The areas of caries predilection on the approximal surfaces were then measured by means of DIAGNOdent, using the flat tip designated by the manufacturer for use on smooth surfaces. The measurements on each individual tooth were standardized by measuring a sound spot on the buccal surfaces. The highest values were registered. The first observer marked the sites with the highest readings on the hard-copy photographs of the teeth. The second observer then took her readings at the sites indicated on the photographs.

To test the intra-observer agreement of the method, the first observer repeated the same measurements 2 weeks later.

Teeth stored in formalin solution

To test whether DIAGNOdent readings were affected by choice of storage medium, the teeth were retrieved from the thymol saline and stored in neutral-buffered 10% formalin solution for 2 weeks. The first observer then repeated the above-described measurement procedures.

Histopathologic and microradiographic analyses

The teeth were then prepared for histopathologic examination and transverse microradiography. To isolate each approximal site on a separate specimen, each tooth was embedded in methylmethacrylate and hemi-sectioned with a diamond saw, perpendicular to the occlusal and buccal surfaces. Each half of the tooth crown was then re-embedded in methylmethacrylate, and a tooth slice, 300 µm thick, was sawn perpendicular to the enamel surface at the test sites. When the photographs indicated that the slice deviated from the test sites, two or more slices were

prepared. The tooth slices were examined under a microscope at 16× magnification. The lesions were defined by the extension of a whitish decalcified zone or a brown zone in the approximal surface-pulpal direction.

The following five-point scale was used for histopathologic stratification of the sites: 0 = sound; 1 = enamel caries limited to the outer half of enamel; 2 = caries extending into the inner half of the enamel but not to the dentinoenamel junction (DEJ); 3 = caries penetrating the DEJ but limited to the outer half of the dentin; and 4 = caries involving the inner half of the dentin.

The tooth slices were then manually ground to about 80–90 µm thickness. Six specimens were broken and lost during the tooth slice preparation. Microradiographs of each tooth slice, together with an aluminum step wedge for calibration, were recorded on holographic film (Kodak SO-253) exposed to Ni-filtered CuKα radiation at 20 kV and 55 mA with an exposure time of 20 sec. The film was developed in accordance with the manufacturer's instructions. The TMR equipment consisted of a PC connected to a microscope densitometer. Mineral content was assessed with specially designed software (Inspektor Research Systems BV, Amsterdam, The Netherlands), which uses densitometric values to calculate the mineral content in accordance with the formula of Angmar et al. (11). The tracings were expressed as integrated mineral loss (Δz), using the established parameter definition (12). For technical reasons, Δz was assessed only for enamel caries.

Data analysis

Intra-observer and inter-observer agreement. Observer agreement for DIAGNOdent readings for quantification of smooth-surface caries was assessed with one-way ANOVA. On the basis of these results, intra-observer agreement, expressed as an intra-class correlation coefficient, was calculated on the two sets of readings made by the first observer. Accordingly, inter-observer agreement was determined by calculating the inter-class correlation coefficient between the data from the two observers.

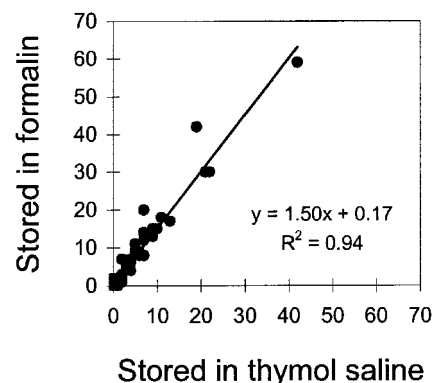


Fig. 1. Relationship between DIAGNOdent readings obtained from teeth stored in thymol saline and formalin, respectively.

Table 1. Histopathologic and microradiographic validations shown in a 4×4 cross-table. Seventy specimens of 74 showed agreement between the two methods

Histology	Microradiography				Total
	Sound	Enamel	Dentin	Pulp	
Sound	12	2	0	0	14
Enamel	1	40	1	0	42
Dentin	0	0	15	0	15
Pulp	0	0	0	3	3
Total	13	42	16	3	74

Table 2. Relationship between visual inspection and gold standard determined by histology and microradiography combined

Visual inspection	Gold standard		
	Sound	Caries	Total
Sound	10	2	12
Caries	1	61	62
Total	11	63	74

Effect of storage medium on DIAGNOdent readings. Linear regression analysis was used to study the relationship between the two sets of data: DIAGNOdent readings after the teeth had been stored in saturated thymol saline, and readings after storage in neutral-buffered formalin.

Validation study

a) Histopathologic analysis. The correlation between the DIAGNOdent readings and the lesion depths (determined

by histopathological examination and microradiography) was evaluated with the Spearman rank correlation coefficient. The cut-off points for caries detection at dentinal level (D3 level) were initially estimated on the basis of the median values of category 3. By adjusting cut-off values, a slight decrease in specificity/sensitivity can lead to a major increase in sensitivity/specificity. Minor adjustments were therefore made, to balance the values of sensitivity and specificity, which were calculated later on.

The sensitivity and specificity for caries detection at D3 level were calculated for two sets of measurements: after storage of the teeth in saturated thymol saline and after formalin storage.

b) Transverse microradiographic analysis. For enamel caries the correlation between the DIAGNOdent readings and TMR measurement of mineral loss (ΔZ) was expressed as the Spearman rank correlation coefficient. Linear correlation analysis was used to assess the relationship between lesion depth expressed in micrometers and ΔZ .

Results

Intra- and inter-observer agreement

The intra- and inter-observer agreements in terms of intra-class correlation coefficient were 0.95 and 0.94, respectively.

Effect of storage medium on DIAGNOdent

Fig. 1 shows the relationship between data obtained

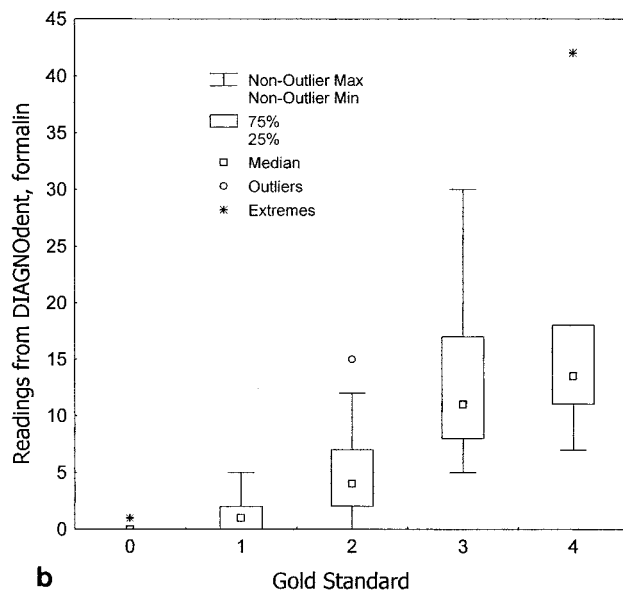
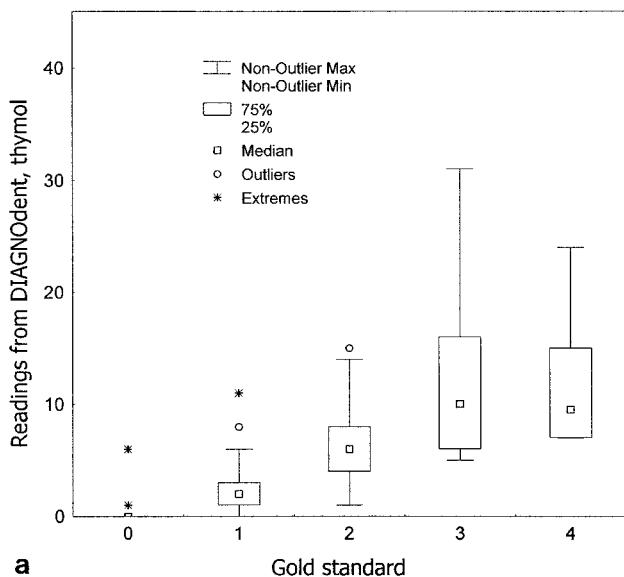


Fig. 2. DIAGNOdent readings classified into five categories in accordance with the 'gold standard': 0 = sound; 1 = enamel caries limited to the outer half of enamel; 2 = caries extending into the inner half of the enamel but not to the dentinoenamel junction (DEJ); 3 = caries penetrating the DEJ but limited to the outer half of the dentin; 4 = caries involving the inner half of the dentin. Fig. 2a shows readings for teeth stored in thymol, and 2b for those stored in formalin.

Table 3. Sensitivity and specificity of DIAGNOdent for smooth-surface caries detection at D3 level. Cut-off points were 9 and 7 for teeth stored in thymol and formalin, respectively

	Thymol		Formalin
	1st time	2nd time	
Sensitivity	0.75	0.63	0.75
Specificity	0.84	0.98	0.95

from teeth after storage in saturated thymol saline and after storage in formalin: higher values were recorded after storage in formalin.

Validity study

Table 1 is a 4 × 4 table showing the relationship of histopathologic and microradiographic analyses on the 74 specimens. The results based on the two validation methods are as follows: 12 were sound, 43 had enamel caries, 16 had dentinal caries, and 3 had pulp exposed. When visual inspection and gold standard, for detection of sound surfaces and caries, were compared, three surfaces were misdiagnosed by visual inspection (Table 2). The DIAGNOdent readings and lesion depths, stratified in accordance with the gold standard, are graphically illustrated in Fig. 2. The DIAGNOdent readings ranged mostly from 0 to 30. The cut-off points, sensitivity, and specificity for detection of dentinal caries were 7 and 9 for teeth stored in thymol and formalin, respectively (Table 3).

Spearman's rank correlation coefficients for DIAGNOdent readings and lesion depth and mineral loss, respectively, are presented in Table 4. Fig. 3 shows a strong correlation between mineral loss and lesion depth determined by TMR analysis ($r = 0.89$).

Discussion

In the present study the reliability of the KaVo DIAGNOdent was evaluated in terms of intra- and inter-observer agreement. The high intra- and inter-class correlation coefficients confirmed the high reproducibility reported in previous studies on occlusal caries (8, 10).

Several studies have reported KaVo DIAGNOdent to be valuable for detection and quantification of occlusal caries lesions (8, 10). Because of the much lower caries prevalence on buccal/lingual surfaces than on occlusal surfaces, the clinical impact of such a device for detection

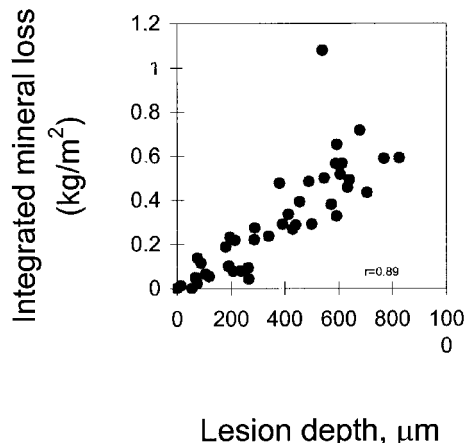


Fig. 3. Correlation between lesion depth in micrometers and mineral loss (ΔZ), using transverse microradiography. For enamel caries the lesion depth in micrometers was proportional to the loss of mineral content. Pearson's correlation coefficient was 0.89.

and quantification of caries on buccal/lingual surface would not be as prominent as that for occlusal caries. However, caries lesions on buccal surfaces are frequently found both among patients with high caries risk/activity and in orthodontic patients after removal of orthodontic brackets. It would have great impact on the motivation of these patients if a method could follow the progress of a lesion and monitor changes of a lesion rather than just give a dichotomous diagnosis, like visual inspection. Furthermore, a quantitative method may also be used in clinical trials to evaluate the outcome of preventive treatment.

According to the manufacturer, DIAGNOdent can be used for detection and quantification of caries lesions on smooth surfaces by application of a special flat-tipped probe. In this in vitro study we evaluated detection and quantification of smooth-surface caries with DIAGNOdent, in terms of validity and intra- and inter-observer agreement. We also investigated the possible effect on DIAGNOdent readings of the medium selected for storing the extracted teeth.

In this study the gold standard for lesion depth was determined by both histopathology and microradiography. In most cases the data from the two methods agreed. In cases of discrepancy the evidence indicating a deeper lesion was accepted. The following two possibilities arose: a) the microradiographic data were accepted instead of the histopathologic data. This occurred mainly in shallow lesions, such as subsurface lesions; these are not always

Table 4. Spearman's rank correlation coefficients between DIAGNOdent readings and lesion depth and integrated mineral loss (ΔZ), respectively

Spearman's rank correlation coefficient	Thymol (1)		Thymol (2) Observer 1	Formalin Observer 1
	Observer 1	Observer 2		
Lesion depth, μm	0.80	0.78	0.83	0.85
ΔZ	0.64	0.50	0.68	0.67

obvious on microscopic examination of a tooth slice but are clearly discernible as dark areas on a microradiograph. b) Histopathologic evidence was accepted in preference to the microradiographic data. This occurred when histopathologic examination showed the lesion to be deeper than disclosed by the microradiograph; after histopathologic examination the tooth slices were prepared for TMR by grinding from 300 µm to 80–90 µm, and the deepest points could have been ground away.

The Spearman rank correlation coefficient of around 0.8 between the gold standard for lesion depth and the DIAGNOdent readings indicates that DIAGNOdent could be a useful clinical diagnostic tool. However, it should be emphasized that most of the DIAGNOdent readings were less than 30, indicating that the full capacity (0–99) of the DIAGNOdent device was not used when measuring smooth-surface caries. This will subsequently result in lower accuracy of the measurement. Thus, for research purposes, minor carious changes of a smooth surface may not be monitored. The correlation between mineral loss in the enamel and DIAGNOdent readings was only about 0.65. The TMR analyses of lesion depth and mineral loss were closely correlated (0.89), suggesting that lesion depth has a greater influence than mineral loss on DIAGNOdent readings. This finding supports the proposal by Hibst & Paulus (7) that DIAGNOdent readings reflect changes in organic material rather than the inorganic content of tooth substance.

There was a dramatic increase in DIAGNOdent readings after storage of the teeth in 10% neutral-buffered formalin instead of saturated thymol saline (Fig. 1). This unexpected finding suggests that formalin denatured the proteins, changing the structure and quality of one or more organic components, resulting in increased fluorescence. The difference between the two readings was more pronounced for deeper than for shallow lesions; deeper lesions contain more protein because of bacterial deposits and would therefore be more affected by denaturing. This observation is in accordance with the hypothesis that increased fluorescence reflects an increased organic component in a lesion. As the storage medium was shown to influence DIAGNOdent readings, it is essential that the cut-off points be assessed under clinical conditions before general application.

Our data show that for in vitro detection and quantification of smooth-surface caries, DIAGNOdent provides high reproducibility, good correlation with lesion depth defined semi-quantitatively, and moderate sensitivity and specificity and may be a helpful clinical tool. However, for greater understanding and more efficient application of the method, further investigation of the underlying mechanisms is necessary.

References

1. Angmar-Månsson B, Al-Khateeb S, Tranæus S: Monitoring the caries process. Optical methods for clinical diagnosis and quantification of enamel caries. *Eur J Oral Sci* 1996;104:480–5.
2. Al-Khateeb S, Oliveby A, de Josselin de Jong E, Angmar-Månsson B. Laser fluorescence quantification of remineralisation in situ of incipient enamel lesions: influence of fluoride supplements. *Caries Res* 1997;31:132–40.
3. Al-Khateeb S, ten Cate JM, Angmar-Månsson B, de Josselin de Jong E, Sundström G, Exterkate RA, et al. Quantification of formation and remineralization of artificial enamel lesions with a new portable fluorescence device. *Adv Dent Res* 1997;11:502–6.
4. Al-Khateeb S, Forsberg C-M, de Josselin de Jong E, Angmar-Månsson B. A longitudinal laser fluorescence study of white spot lesions in orthodontic patients. *Am J Orthod Dentofacial Orthop* 1998;113:595–602.
5. Schneiderman A, Elbaum M, Shultz T, Keem S, Greenebaum M, Driller J. Assessment of dental caries with Digital Imaging Fiber-Optic Transillumination (DIFOTI): in vitro study. *Caries Res* 1997;31:103–10.
6. Hibst R, Gall R. Development of a diode laser-based fluorescence caries detector. *Caries Res* 1998;32:294.
7. Hibst R, Paulus R. Caries detection by red excited fluorescence investigations on fluorophores. *Caries Res* 1999;33:295.
8. Lussi A, Imwinkelried S, Pitts N, Longbottom C, Reich E. Performance and reproducibility of a laser fluorescence system for detection of occlusal caries in vitro. *Caries Res* 1999;33:261–6.
9. Longbottom C, Pitts NB, Lussi A, Reich E. Histological validation of in vivo measurements using the DIAGNOdent device: a three-centre study. *Caries Res* 1999;33:300.
10. Shi X-Q, Welander U, Angmar-Månsson B. Occlusal caries detection with KaVo DIAGNOdent and Radiographic examination: an in vitro comparison. *Caries Res* 2000;34:151–8.
11. Angmar B, Carlström D, Glas J-E. Studies on the ultrastructure of dental enamel. IV. The mineralisation of normal human enamel. *J Ultrastruct Res* 1963;8:12–23.
12. Arends J, ten Bosch JJ. Demineralization and remineralization evaluation techniques. *J Dent Res* 1992;71 (Spec Iss):924–8.