

# Contact dermatitis: clinics and pathology

Markus Streit and Lasse R. Braathen

Dermatological University Clinic, Inselspital, Berne, Switzerland

Streit M, Braathen LR. Contact dermatitis: clinics and pathology. *Acta Odontol Scand* 2001;59:309–314. Oslo. ISSN 0001-6357.

Contact dermatitis or eczema is a polymorphic inflammation of the skin. It occurs at the site of contact with irritating or antigenic substances. In the acute phase there is occurrence of itching erythema, papules, and vesicles, whereas in the chronic phase there is dryness, hyperkeratosis, and sometimes fissures. Contact dermatitis can be divided into irritant and allergic types. Allergic contact dermatitis is a type-IV T-cell-mediated reaction occurring in a sensitized individual after contact with the antigen/allergen. Such antigens are usually low molecular weight substances (MW ~500), called haptens; 3000 contact allergens are known. The diagnosis of contact allergy is made on the basis of the history, clinical findings, and a positive epicutaneous test result. Allergic, but not irritative, contact dermatitis can spread beyond the area of contact to other body parts. Eczematous lesions are characterized by a mononuclear infiltrate consisting mainly of T cells in the dermis and epidermis, together with an intercellular epidermal edema—that is, spongiosis. In allergic contact dermatitis, skin-applied antigen is taken up by epidermal Langerhans cells and transported with the afferent lymph to the regional lymph nodes. Here, naive T lymphocytes are sensitized to become antigen-specific effector T cells, which then leave the lymph node, enter the circulation, and are recruited to the skin by means of specific cell surface molecules, to form the infiltrates. Cytokines released by infiltrating T cells eventually cause keratinocyte apoptosis. □ *Allergy; contact dermatitis; immunology; irritant*

Lasse R. Braathen, *Dermatological University Clinic, Inselspital, CH-3010 Bern, Switzerland. Fax: +41 31 381 58 15, e-mail: lasse.r.braathen@insel.ch*

## Dermatitis and eczema

The terms ‘dermatitis’ and ‘eczema’ are normally used synonymously. They denote an epidermal intolerance reaction (1) showing a polymorphic inflammatory reaction pattern on the skin, which can be of endogenous or exogenous origin. ‘Eczema’ was defined by Miescher in 1962 as a non-contagious epidermodermatitis (that is, an inflammation of the epidermis and dermis) clinically characterized by erythema, vesicles, weeping, desquamation, lichenification, and, histologically, focal spongiosis, acanthosis, and parakeratosis (2). This definition shows that eczema is mainly a clinical diagnosis with typical clinical features.

These features are, in chronological order, as follows. The acute stage is characterized by exudative inflammatory processes that lead to erythema, swelling, and papules, mainly reflecting edema in the epidermis, histologically seen as spongiosis. The spongiosis and disruption of the intercellular bridges result in the formation of papulovesicles, vesicles, and blisters that may lead to weeping (Fig. 1). In the subacute and chronic stages the lesions become increasingly dry, scaly, and thicker, histologically reflected by hyperkeratosis and acanthosis (Fig. 2). Finally, lichenification and fissures can be observed. Itching is the dominant symptom in eczema.

Despite the synonymous use of the terms ‘dermatitis’ and ‘eczema’, some authors still point out differences: in the German literature dermatitis is used for acute forms; eczema is understood as the more chronic course with little spontaneous regression (1). Wilkinson, on the other hand, recommends the use of the term eczema for the condition

with an endogenous or constitutional origin and dermatitis for an eczema of external origin (3).

Here we use the term ‘contact dermatitis’ for eczematous reactions induced by contact with chemical substances causing either allergic or irritative skin reactions.

## Classification of contact dermatitis

Contact dermatitis accounts for up to 7% of all dermatological consultations (4). In Sweden a prevalence of 2% was found for hand eczema (5). On the basis of the etiology two types of contact dermatitis can be distinguished.

### *Irritant contact dermatitis*

Irritant contact dermatitis is the result of non-immunologic damage to the skin by an irritant—that is, a chemical or physical agent that produces cell damage if applied for a sufficiently long time in a sufficiently high concentration. Dermatitis arises when an inflammatory response is elicited. Strong irritants can induce a reaction in any individual: accidental exposure to, for example, acid or alkaline compounds leads to an acute toxic reaction that appears clinically as an inflammatory reaction that looks like a burn and is strictly limited to the site of application. Irritative contact dermatitis is induced by less potent irritants and develops only under more restricted circumstances: repeated exposure to a chemical or physical agent leading to cumulative damage is required. This cumulative

irritant contact dermatitis is characterized by a spectrum of reactions ranging from dryness and redness through all the above-mentioned stages of eczema. The stratum corneum is the most important barrier layer of the skin, so cumulative irritant contact dermatitis typically arises in areas with exposed thin skin. Examples of this are the dorsal parts of the fingers and hands in housewives or nurses with chronic irritation caused by frequent hand washing. Constitutional factors like the reduced stratum corneum barrier seen in atopic patients will increase the risk of cumulative irritant dermatitis. Irritant contact dermatitis is more common than allergic contact dermatitis.

#### *Allergic contact dermatitis*

In allergic contact dermatitis the inflammatory process is caused by a type-IV cell-mediated reaction occurring in a sensitized individual after renewed contact with the antigen. Clinically, an acute form can be distinguished from the chronic form. Acute allergic contact dermatitis shows the typical features of acute eczema with erythema, papules, vesicles, and weeping. Chronic allergic contact dermatitis is due either to a persisting antigen or to repeated exposure to the allergen. As in chronic irritant contact dermatitis, the skin becomes dry, scaly, thick, and fissured. Clinically, the main difference between irritant and allergic contact dermatitis is that in the latter the inflammatory lesions can spread beyond the area of contact to other parts of the body, often in a symmetrical pattern.

Sensitization was first shown in the experiments of Bloch & Steiner-Woerlich (6), who sensitized a man with primula some 70 years ago (6). Today, about 3000 antigens are known that act as contact allergens. Most of them are small substances with a molecular weight of less than 500 dalton, called haptens. They bind to a carrier protein via covalent bonds or, in the case of metals like nickel and cobalt, form a complex with protein. The configuration of the conjugate, the type of binding, and other, unknown factors determine the antigenicity (3). The sensitization process itself will be described below.

## Special types of contact dermatitis

#### *Typical and common allergens*

The ranking order of the most common allergens differs from country to country and from decade to decade. Common allergens are similar in Europe and the United States. Some examples follow:

*Nickel sulfate* is the allergen with the most tested positive reactions in the USA, appearing in almost 10% of epicutaneous tests and considered relevant in about 75% of cases (7). It is observed more often in women than in men, and in special groups like hairdressers the prevalence rises to 27% (3). Women are most often sensitized with objects worn close to the skin like cheap jewelry, especially earrings, or metal accessories on clothing such as studs on

jeans (Fig. 3). In men, watches are often the cause of nickel dermatitis.

*Chromate* sensitivity is another frequent cause of contact dermatitis, particularly of occupational dermatitis. Cement is its most important source, with bricklayers carrying the highest risk of sensitization (3). In these people the risk of sensitization is increased through chronic irritation by an alkali plus mechanical irritation. The course of the disease is often chronic. Cement dermatitis usually shows the dry, scaly, or even hyperkeratotic lesions that are typical of chronic disease.

*Medicaments* are the cause of allergic contact dermatitis in up to 30% of all cases (3). Some sites show a predilection for development of allergic contact dermatitis, such as the shin in patients with leg ulcers due to chronic venous stasis. The frequent application of a topical medicament, sometimes even under occlusion, may favor sensitization. Neomycin and lanolin are common sensitizers.

On the vermilion border of the lips, contact dermatitis caused by medicaments for the treatment of herpes simplex can be found, and in the acute phase this must be differentiated from herpetic lesions (Fig. 4).

*Cosmetics* like deodorant sprays are another source of contact dermatitis.

#### *Sites of contact dermatitis*

The *hands* are the body sites most often involved for both irritant and allergic contact dermatitis (3). Hand eczemas are often multifactorial and are very common in housewives with regular exposure of the hands to wet work. Most cases of occupational dermatitis are confined to the hands.

The *face* is another common site for contact dermatitis, with cosmetics and medicaments as important allergens. However, airborne allergens such as volatile chemicals, sprays, and dusts must also be considered. In the case of prior sunlight exposure, a phototoxic or photoallergic reaction should be considered as well.

Contact dermatitis of the *mucosa* is rare. Allergic reactions to flavors in toothpaste do not often have manifestations in the oral cavity but rather lead to a perioral allergic dermatitis. Allergic reactions to nickel, mercury, palladium, or gold in dental amalgams can present as systemic contact dermatitis with or even without localized stomatitis (8). When allergic reactions in the mouth occur, they show erythema and swelling in the acute phase and ulceration, atrophy, and leukoplakia in chronic cases. Lichen planus-like lesions may occur. Interestingly, the application of sensitizers like dinitrochlorobenzene to the oral mucosa leads to immunologic tolerance to later challenge (3). It is questionable whether the diluting effect of saliva can be held accountable for the paucity of intraoral allergic stomatitis, because allergic reactions are rarely seen in rectal mucosa as well. It is not fully understood whether the special anatomy of the oral epithelium, without a keratinized layer and lipid secretion, or other factors make its response different from that of the normal skin.

## Contact dermatitis: diagnostic measures

The diagnosis of contact dermatitis is made on the basis of the history, clinical findings, and, in the case of allergic dermatitis, positive epicutaneous test results.

In the *patient's history* the search for possible sources of a contact dermatitis, allergic as well as irritant, must include questions about occupation, use of cosmetics, clothing, personal objects, home environment, and previous and present medical treatment. Typically, dermatitis of occupational origin improves on weekends or during holidays.

In the *clinical findings* the pattern of the dermatitis is the key to diagnosis. A typical location of the dermatitis that corresponds with the history, together with lesions that are sharply limited to the site of contact, constitute suggestive findings (Fig. 5). The morphology of the lesions indicates acute or more chronic disease; spreading beyond the area of contact, and dissemination would be typical of allergic contact dermatitis.

*Epicutaneous testing* still remains the only reliable method of obtaining a correct diagnosis. Patch tests can be performed with any substance. Standard test series are commercially available for the most common allergens. Substances are applied to patches of filter paper, placed in aluminum cups (Finn-Chamber) and fixed on the skin with hypoallergenic adhesive tape. After 48 h the test material is removed, and a first test reading performed. Positive reactions show erythema and infiltration, often with papules or vesicles (Fig. 6). The reaction may spread beyond the margins of the patch. In contrast, irritant reactions show a sharp delineation and, typically, no infiltration. At the second reading, after 72 to 96 h, the reaction may show further increase and spreading, which would be another indication of an allergic reaction.

*Histopathology.* In the acute stage spongiosis and vesicle formation are dominant. In subacute eczema, acanthosis increases, with the formation of a parakeratotic cornified layer. In chronic eczema the epithelial ridges become elongated and broadened, and hyperkeratosis is observed. A dermal lymphocytic infiltrate and vascular dilatation can be found at all stages. Allergic and irritant contact dermatitis do not show significant histological differences.

## Immunological mechanisms in allergic contact dermatitis

The skin is an important and highly reactive immunological organ. Resident cells in the epidermis, as well as in the dermis, are immunocompetent and take part in immunological reactions of the skin. The epidermis is composed mainly of keratinocytes but also harbors melanocytes, which produce the skin pigment melanin, and the immunologically important dendritic epidermal Langerhans cells. The major antigen-presenting cell in the epidermis is the Langerhans cell, even though keratinocytes, on stimuli and damage, can produce proinflamma-

tory cytokines and acquire HLA class-II molecules, which enable them to present antigens to T-cells.

### *The dendritic epidermal Langerhans cell (Lc)*

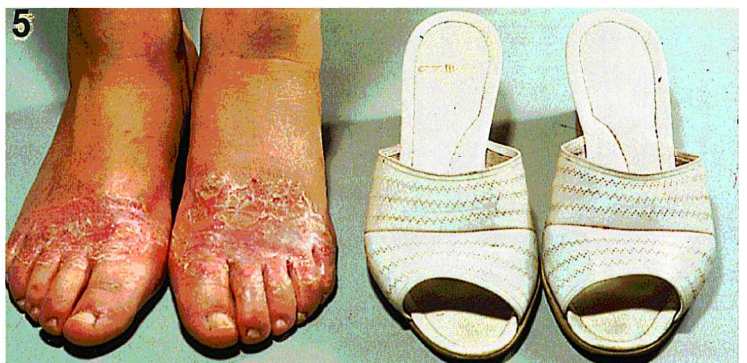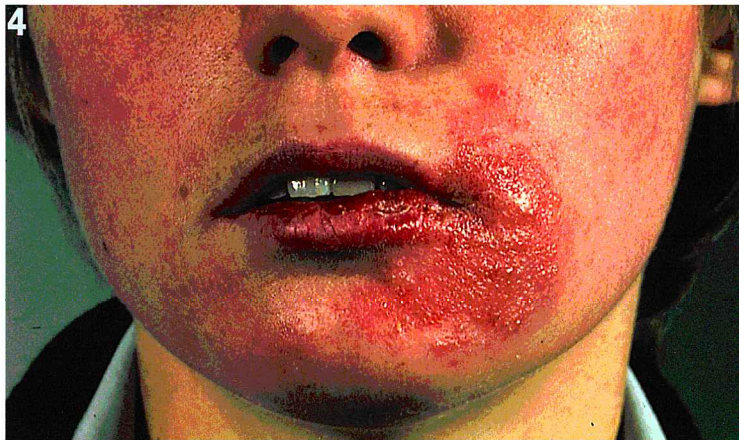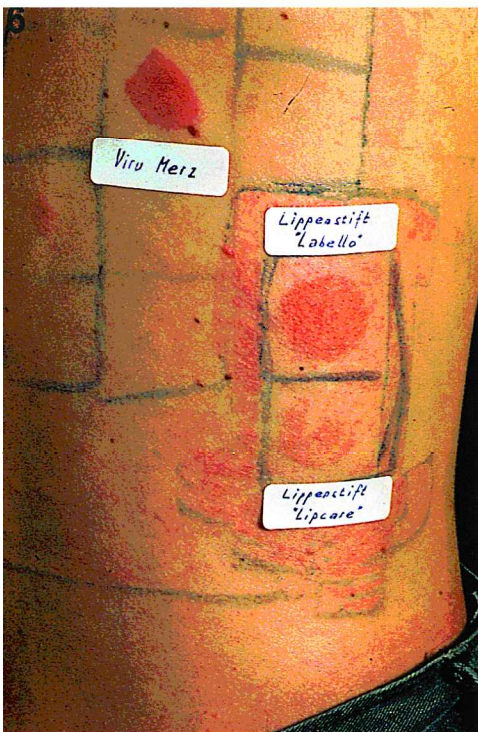
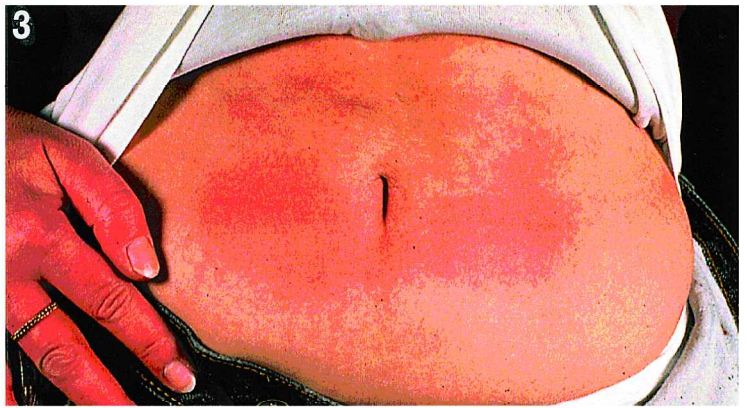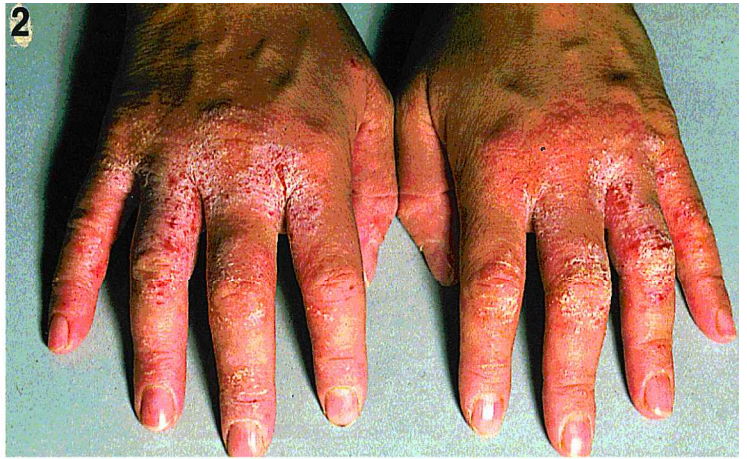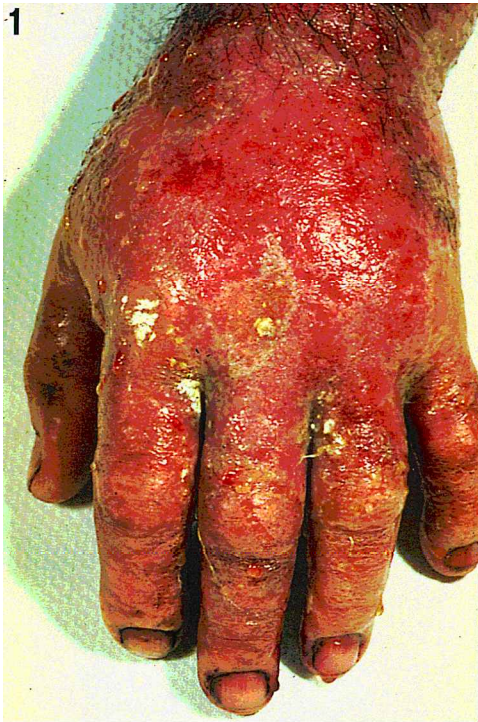The epidermal Langerhans cell derives from the bone marrow and is a temporary resident dendritic cell of the epidermis. It is situated over the basal cells in normal skin but can increase in number and migrate closer to the surface in inflammatory reactions, especially in allergic contact dermatitis. The Lc has an alloactivating and antigen-presenting capacity (9). It can present most, if not all, antigens to T cells (10–12) and seems to be highly specialized for this task (13, 14). It is also the primary cell to be infected in sexually transmitted HIV infection (15, 16) as a result of its presence in oral, vaginal, and cervical epithelium (17). Through their dendrites the Langerhans cells form a network that makes it impossible for an antigen to transverse the epidermis without getting caught. The antigen is then taken up by the Lc, and through this and other stimuli the Lc migrate out of the epidermis and enter the afferent lymph-vessels. On the way to the regional lymph node the Lc matures to become an antigen-processing and -presenting cell. It recruits and activates naive T cells to become T effector/memory cells in the paracortical areas of the lymph node. These cells then enter the blood stream and, through their homing receptors, migrate through small vessels into the tissue of the skin, where they can induce apoptosis of keratinocytes (18). The presence of T cells in the skin in atopic eczema, delayed-type hypersensitivity reactions, and lichen planus was shown more than 20 years ago (19–21). Evidence of the migration of Lc and other cells has been provided by collecting and analyzing afferent skin lymph (22).

### *Isolation of human skin lymph*

A lymph vessel that drains the skin of the lower medial part of the leg can be cannulated by microsurgery. Contact dermatitis reactions can be induced with irritants and obligate contact allergens on the skin of the lower leg, and then the lymph can be sampled for analysis of cytokines and cells. This gives valuable information about the processes in the skin and the traffic of cytokines and cells to the regional lymph node (23, 24). As compared with peripheral blood, lymph from normal skin contains an increased number of mainly memory/effector CD4-positive T cells expressing activation and co-stimulatory molecules (25).

### *Irritant contact dermatitis*

Sodium lauryl sulfate painted onto the skin as an irritant induces an increased lymph flow and output of cells in the course of the reaction (24). The HEC4-452 epitope was highly expressed, indicating that the cells had skin-homing receptors (26). Interleukin (IL)-2 receptors, granulocyte macrophage colony-stimulating factor (GM-CSF), and inflammatory cytokines such as IL-6, tumor necrosis factor



- Fig. 1. Acute contact dermatitis of the hands which resulted in weeping.  
 Fig. 2. Chronic allergic contact dermatitis with dry and scaly skin.  
 Fig. 3. Allergic contact dermatitis from nickel, elicited by a jeans stud.  
 Fig. 4. Acute allergic contact dermatitis with vesicles due to the treatment of herpes labialis.  
 Fig. 5. The pattern of dermatitis as the key to diagnosis: contact dermatitis from shoes.  
 Fig. 6. Positive epicutaneous test in the patient in Fig. 4.

(TNF)- $\alpha$ , IL-1 $\beta$ , and IL-2 were increased in a skin reaction dependent/associated manner (23). There was also a large increase in the number of Langerhans cells in the late phase of the contact dermatitis (27). Furthermore, it could be shown that these immunocompetent cells were activated (28) and that they had alloactivating and antigen-presenting capabilities (29). Rosettes of Langerhans cells and activated T cells could also be shown (30).

#### *Allergic contact dermatitis*

The Lc in afferent lymph from diphenylcyclopropenone-induced allergic contact dermatitis are similar to cultured Lc (31), with surface antigens such as HLA-DR, ICAM-1, and, in part, LFA-3 (30, 32). They also transport antigen to the regional lymph nodes. IL-12 is expressed on antigen-presenting cells and keratinocytes in allergic contact dermatitis (33).

Soluble ICAM, ELAM, and VCAM are constitutively present in the lymph and increased in allergic contact dermatitis (34). IL-1b protein in the lymph did not distinguish allergic from irritant contact dermatitis (35), but IL-10 was increased selectively in elicitation reactions (36). GM-CSF is constitutively expressed by cells in afferent lymph from skin (26). Afferent lymph from normal skin contains an increased number of mainly memory/effector CD4+T cells expressing activation, adhesion, and co-stimulatory molecules, as compared with the peripheral blood (25). The cytotoxic T cells generated in the lymph node travel to the skin and induce apoptosis of the keratinocytes (18).

#### Conclusion

The resident cells of the skin, and the cells that migrate to it, play important roles in irritant and allergic contact dermatitis reactions. The production of several cytokines and soluble factors results in a microenvironment that, in a kinetic fashion, determines the course of the dermatitis. Proinflammatory cytokines increase the skin reaction, and increased IL-10 production induces a downregulation. The transport of antigen by the Lc, their presentation of antigen to T cells in the lymph node, and the flow of cytokines like GM-CSF and others may influence the recruiting of T memory/effector cells from naive T cells in an enhancing or inhibitory manner. The final outcome of all these factors decides the clinical course of the dermatitis.

#### References

- Braun-Falco O. Dermatologie und Venerologie. Berlin: Springer; 1996. p. 405–36.
- Miescher G. Ekzem. Handbuch von Jadassohn. Vol. Erg.-Werk II; Berlin: Springer-Verlag; 1962. p. 1–211.
- Wilkinson J, Rycroft R. Contact dermatitis. In: Champion R, Burton J, Ebling F, editors. Rook/Wilkinson/Ebling: textbook of dermatology. Vol. 1. Oxford: Blackwell Scientific Publications; 1992. p. 622–715.
- Mendenhall RC, Ramsay DL, Girard RA, DeFlorio GP, Weary PE, Lloyd JS. A study of the practice of dermatology in the United States. Arch Dermatol 1978;114:1456–62.
- Agrup G. Hand eczema and other dermatoses in South Sweden. Acta Derm Venereol 1969;49 Suppl 61:44.
- Bloch B, Steiner-Woerlich A. Die willkürliche Erzeugung der Primelüberempfindlichkeit beim Menschen und ihre Bedeutung für das Idiosyncrasieproblem. Arch Dermatol Syphilol 1926;152: 283–303.
- Storrs FJ, Rosenthal LE, Adams RM, Clendenning W, Emmett EA, Fisher AA, et al. Prevalence and relevance of allergic reactions in patients patch tested in North America—1984 to 1985. J Am Acad Dermatol 1989;20:1038.
- Belsito D. Eczematous dermatitis: allergic contact dermatitis. In: Fitzpatrick T, Eisen A, Wolff K, Freedberg I, Austen K, editors. Dermatology in general medicine. Vol. 1. New York: McGraw-Hill; 1993. p. 1531–42.
- Braathén LR, Thorsby E. Studies on human epidermal Langerhans cells. I. Allo-activating and antigen-presenting capacity. Scand J Immunol 1980;11:401–8.
- Braathén LR, Berle E, Mobeck-Hanssen U, Thorsby E. Studies on human epidermal Langerhans cells. II. Activation of human T-lymphocytes to herpes simplex virus. Acta Derm Venereol 1980;60:381–7.
- Braathén LR. Studies on human epidermal Langerhans cells: III. Induction of T-lymphocyte response to nickel sulphate in sensitized individuals. Br J Dermatol 1980;103:517–26.
- Braathén LR, Bjercke S, Thorsby E. The antigen-presenting function of human Langerhans cells. Immunobiology 1984;168: 301–12.
- Braathén LR, Thorsby E. Human epidermal Langerhans cells are more potent than blood monocytes in inducing some antigen-specific T-cell responses. Br J Dermatol 1993;108:139–46.
- Bjercke S, Braathén L, Gaudermack G, Thorsby E. Relative efficiency of human Langerhans cells and blood derived dendritic cells as antigen-presenting cells. Acta Derm Venereol 1985;65: 374–8.
- Braathén LR, Ramirez G, Kunze ROF, Gelderblom H. Langerhans cells as primary target cells for HIV infection. Lancet 1987;2:1094.
- Braathén LR, Ramirez G, Kunze ROF, Mörk C, Gelderblom H. Langerhans cells in mucous membranes and skin may be the primary target cells for HIV. In: J. Thivolet D, editor. Schmitt, Colloque INSERM/John Libbey Eurotext Ltd. 1988; 172:441–8.
- Bjercke S, Scott H, Braathén LR, Thorsby E. HLA-DR-expressing Langerhans-like cells in vaginal and cervical epithelium. Acta Obstet Gynecol Scand 1983;62:585–9.
- Trautmann A, Akdis M, Kleemann D, Altnauer F, Simon HU, Graeve T, et al. T cell-mediated Fas-induced keratinocyte apoptosis plays a key pathogenetic role in eczematous dermatitis. J Clin Invest 2000;106:25–35.
- Braathén LR, Dal BL, Mellbye OJ. Immunological in situ identification of the lymphoid cells in the skin infiltrate of lichen planus. Clin Exp Dermatol 1979;4:175–85.
- Braathén LR, Førre Ø, Natvig JB. An anti-human T-lymphocyte antiserum: in situ identification of T cells in the skin of delayed-type hypersensitivity reactions, chronic photosensitivity dermatitis, and mycosis fungoides. Clin Immunol Immunopathol 1979; 13:211–9.

21. Braathen LR. Predominance of T lymphocytes in the dermal infiltrate of atopic dermatitis. *Br J Dermatol* 1979;100:511–9.
22. Brand CU, Hunziker T, Braathen LR. Studies on human skin lymph containing Langerhans cells from sodium lauryl sulphate contact dermatitis. *J Invest Dermatol* 1992;99:109s–110s.
23. Hunziker T, Brand CU, Kapp A, Waelti ER, Braathen LR. Increased levels of inflammatory cytokines in human skin lymph derived from sodium lauryl sulphate-induced contact dermatitis. *Br J Dermatol* 1992;127:254–7.
24. Brand CU, Hunziker T, Braathen LR. Isolation of human skin-derived lymph: flow and output of cells following sodium lauryl sulphate-induced contact dermatitis. *Arch Dermatol Res* 1992;284:123–6.
25. Yawalkar N, Hunger RE, Pichler WJ, Braathen LR, Brand CU. Human afferent lymph from normal skin contains an increased number of mainly memory/effector CD4+ T cells expressing activation, adhesion and co-stimulatory molecules. *Eur J Immunol* 2000;30:491–7.
26. Hunger RE, Yawalkar N, Braathen LR, Brand CU. The HECA-452 epitope is highly expressed on lymph cells derived from human skin. *Br J Dermatol* 1999;141:565–9.
27. Brand CU, Hunziker T, Limat A, Braathen LR. Large increase of Langerhans cells in human skin lymph derived from irritant contact dermatitis. *Br J Dermatol* 1993;128:184–8.
28. Brand CU, Hunziker T, Schaffner T, Limat A, Gerber HA, Braathen LR. Activated immunocompetent cells in human skin lymph derived from irritant contact dermatitis: an immunomorphological study. *Br J Dermatol* 1995;132:39–45.
29. Hunziker T, Brand CU, Limat A, Braathen LR. Alloactivating and antigen-presenting capacities of human skin lymph cells derived from sodium lauryl sulphate-induced contact dermatitis. *Eur J Dermatol* 1993;3:137–40.
30. Brand CU, Hunziker T, Gerber HA, Schaffner T, Limat A, Braathen LR. Studies on Langerhans cell phenotype in human afferent skin lymph from allergic contact dermatitis. *Adv Exp Med Biol* 1995;378:523–5.
31. Brand CU, Gerber HA, Hunziker T, Schaffner Th, Limat A, Braathen LR. Langerhans cells in human afferent skin lymph derived from allergic contact dermatitis are similar to cultured Langerhans cells. *Adv Exp Med Biol* 1995;378:523–5.
32. Brand CU, Gerber HA, Hunziker T, Schaffner T, Limat A, Braathen LR. Phenotype of Langerhans cells in human afferent skin lymph derived from allergic contact dermatitis. *Exp Dermatol* 1993;2:274–9.
33. Yawalkar N, Egli F, Brand CU, Pichler WJ, Braathen LR. Antigen-presenting cells and keratinocytes express interleukin-12 in allergic contact dermatitis. *Contact Dermatitis* 2000;42:18–22.
34. Ballmer-Weber BK, Braathen LR, Brand CU. sICAM, sELAM and sVCAM are constitutively present in human skin lymph and increased in allergic contact dermatitis. *Arch Dermatol Res* 1997;289:251–5.
35. Brand CU, Hunziker T, Yawalkar N, Braathen LR. IL-1 beta protein in human skin lymph does not discriminate allergic from irritant contact dermatitis. *Contact Dermatitis* 1996;35:152–6.
36. Brand CU, Yawalkar N, Hunziker T, Braathen LR. Human skin lymph derived from irritant and allergic contact dermatitis: Interleukin 10 is increased selectively in elicitation reactions. *Dermatology* 1997;194:221–8.