

- and leukocyte recruitment: Role of VEGF-receptor 2 and host VEGF-A. *Cancer Res* 2001;61:2404-8.
- [3] Yuan F, Chen Y, Dellian M, Safabakhsh N, Ferrara N, Jain RK. Time-dependent vascular regression and permeability changes in established human tumor xenografts induced by an anti-vascular endothelial growth factor/vascular permeability factor antibody. *Proc Natl Acad Sci USA* 1996;93:14765-70.
- [4] Tsuzuki Y, Fukumura D, Oosthuysen B, Koike C, Carmeliet P, Jain RK. Vascular endothelial growth factor (VEGF) modulation by targeting hypoxia-inducible factor-1 $\alpha$ --> hypoxia response element--> VEGF cascade differentially regulates vascular response and growth rate in tumors. *Cancer Res* 2000;60:6248-52.
- [5] Hansen-Algenstaedt N, Stoll BR, Padera TP, Dolmans DE, Hicklin DJ, Fukumura D, et al. Tumor oxygenation in hormone-dependent tumors during vascular endothelial growth factor receptor-2 blockade, hormone ablation, and chemotherapy. *Cancer Res* 2000;60:4556-60.
- [6] Lee CG, Heijn M, di TE, Griffon-Etienne G, Ancukiewicz M, Koike C, et al. Anti-Vascular endothelial growth factor treatment augments tumor radiation response under normoxic or hypoxic conditions. *Cancer Res* 2000;60:5565-70.
- [7] Dreves J, Siegert P, Medinger M, Mross K, Strecker R, Zirrgiebel U, et al. Phase I clinical study of AZD2171, an oral vascular endothelial growth factor signaling inhibitor, in patients with advanced solid tumors. *J Clin Oncol* 2007;25:3045-54.
- [8] Ananthnarayan S, Bahng J, Roring J, Nghiemphu P, Lai A, Cloughesy T, et al. Time course of imaging changes of GBM during extended bevacizumab treatment. *J Neurooncol* 2008;88:339-47.
- [9] Abrams TJ, Murray LJ, Pesenti E, Holway VW, Colombo T, Lee LB, et al. Preclinical evaluation of the tyrosine kinase inhibitor SU11248 as a single agent and in combination with "standard of care" therapeutic agents for the treatment of breast cancer. *Mol Cancer Ther* 2003;2:1011-21.
- [10] Ebos JM, Lee CR, Christensen JG, Mutsaers AJ, Kerbel RS. Multiple circulating proangiogenic factors induced by sunitinib malate are tumor-independent and correlate with antitumor efficacy. *Proc Natl Acad Sci USA* 2007;104:17069-74.
- [11] Mancuso MR, Davis R, Norberg SM, O'Brien S, Sennino B, Nakahara T, et al. Rapid vascular regrowth in tumors after reversal of VEGF inhibition. *J Clin Invest* 2006;116:2610-21.
- [12] Fiedler W, Serve H, Dohner H, Schwittay M, Ottmann OG, O'Farrell AM, et al. A phase 1 study of SU11248 in the treatment of patients with refractory or resistant acute myeloid leukemia (AML) or not amenable to conventional therapy for the disease. *Blood* 2005;105:986-93.

## Salvage therapy with sorafenib plus vinblastine and fluorouracil for metastatic renal cell carcinoma

CHENG-JENG TAI

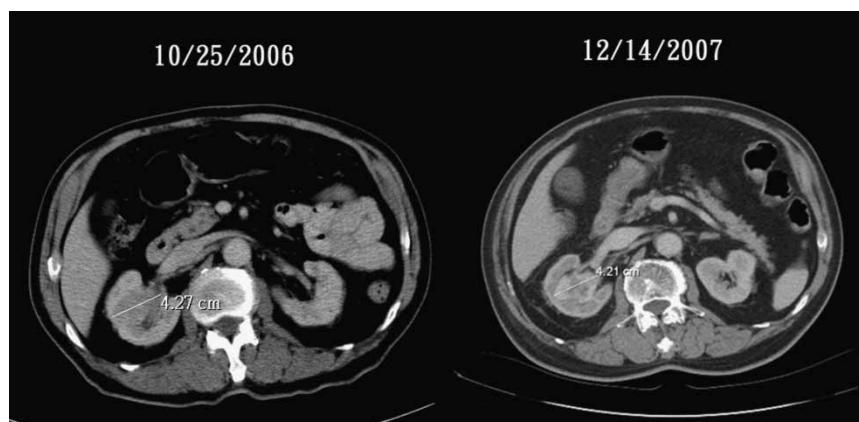
*Section of Hematology-Oncology, Taipei Medical University Hospital and Department of Medicine, Taipei Medical University, Taipei, Taiwan*

### To the Editor,

Sorafenib is a multi-kinase inhibitor and is effective in the treatment of metastatic renal cell carcinoma (RCC) [1,2]. However, the median treatment duration for RCC in published articles is around 24 weeks [2]. But for responsive patients, no published reports have discussed when sorafenib should be discontinued. We report a patient with metastatic RCC who responded to treatment with sorafenib plus chemotherapy, and the treatment was discontinued at his own insistence. Thirty months after the first dose of sorafenib plus chemotherapy and 15 months after discontinuing treatment, he was still alive without disease progression.

An 81-year-old man presented with severe pain in his right hip joint and underwent hip joint replace-

ment in October 2006. A specimen from the resected hip joint was sent for pathologic studies and was diagnosed as metastatic renal cell carcinoma with bony metastasis. A computed tomographic (CT) scan (Figure 1) revealed a right kidney tumor and enlarged calyx, so he was referred to our medical oncology department for treatment. Because of the patient's age, sorafenib was administered at a reduced dosage of 400 mg/day to avoid toxicity. One month later, vinblastine (8 mg/m<sup>2</sup>) plus fluorouracil (500 mg/cycle) were given as conjunct medication and repeated every two weeks. Bisphosphonate (pamidronate) was also given with 90 mg/month. The patient tolerated the treatment well and the disease remained stable without further metastasis for 15 months, when he



insisted on stopping the medication. Fifteen months later, we contacted him and he was healthy with an ECOG performance status of 0–1.

One of the main problems of using targeted therapy in metastatic cancer is whether the medication should be discontinued when the clinical status is stable or the patient is in remission. In most cases, patients are treated until disease progresses [3]. Therefore, it's difficult to determine when and whether to stop the medication. We also assumed that the addition of chemotherapy to these targeted medications might lead to better disease control and longer progression free intervals [4]. The cost of treatment is another problem. In metastatic RCC, the costs for sorafenib are around US\$30 000–40 000. This usually prevents a patient from taking these medications without limit. Based on this case, we are particularly interested in the cost-effectiveness of treatment, an aspect which interests insurance authorities the most.

Presently, the eradication of metastatic RCC by available medications is still a long way off. Lower costs and longer survivals with better control remain the main goals of treatment.

#### References

- [1] Ratain MJ, Eisen T, Stadler WM, Flaherty KT, Kaye SB, Rosner GL, et al. Phase II placebo-controlled randomized discontinuation trial of sorafenib in patients with metastatic renal cell carcinoma. *J Clin Oncol* 2006;24:2505–12.
- [2] Kane RC, Farrell AT, Saber H, Tang S, Williams G, Jee JM, et al. Sorafenib for the treatment of advanced renal cell carcinoma. *Clin Cancer Res* 2006;12:7271–8.
- [3] Bracarda S, Caserta C, Sordini L, Rossi M, Hamzay A, Crino L. Protein kinase inhibitors in the treatment of renal cell carcinoma: Sorafenib. *Ann Oncol* 2007;18(Suppl 6):22–5.
- [4] Gollob JA. Sorafenib: Scientific rationales for single-agent and combination therapy in clear-cell renal cell carcinoma. *Clin Genitourin Cancer* 2005;4:167–74.

## Persistent hiccups as an adverse event to FLAG-IDA regimen for leukemia

FABIO FORGHIERI<sup>1</sup>, MONICA MACCAFERRI<sup>1</sup>, MONICA MORSELLI<sup>1</sup>, LEONARDO POTENZA<sup>1</sup>, FRANCESCO VOLZONE<sup>1</sup>, ELENA BANDIERI<sup>2</sup>, GIUSEPPE TORELLI<sup>1</sup> & MARIO LUPPI<sup>1</sup>

<sup>1</sup>Department of Oncology, Hematology and Respiratory Diseases, University of Modena and Reggio Emilia, Azienda Ospedaliera Policlinico, Modena, Italy and <sup>2</sup>Centro Valutazione Efficacia Assistenza Sanitaria, AUSL Modena, Italy.