

4. Darby SC, McGale P, Taylor CW, et al. Long-term mortality from heart disease and lung cancer after radiotherapy for early breast cancer: prospective cohort study of about 300 000 women in US SEER cancer registries. *Lancet Oncol* 2005;6:557–65.
5. Harris EER, Correa C, Hwang W-T, et al. Late cardiac mortality and morbidity in early-stage breast cancer patients after breast-conservation treatment. *J Clin Oncol* 2006;24:4100–6.
6. Hoening MJ, Botma A, Aleman BMP, et al. Long-term risk of cardiovascular disease in 10-year survivors of breast cancer. *J Natl Cancer Inst* 2007;99:365–75.
7. Darby SC, Ewertz M, McGale P, et al. Risk of ischemic heart disease in women after radiotherapy for breast cancer. *N Engl J Med* 2013;368:987–98.
8. Van Nimwegen FA, Schaapveld M, Cutter DJ, et al. Radiation Dose-response relationship for risk of coronary heart disease in survivors of Hodgkin lymphoma. *J Clin Oncol* 2015;34:235–43.
9. Eriksson F, Gagliardi G, Liedberg A, et al. Long-term cardiac mortality following radiation therapy for Hodgkin's disease: analysis with the relative seriality model. *Radiother Oncol* 2000;55:153–62.
10. Gagliardi G, Lax I, Ottolenghi A, et al. Long-term cardiac mortality after radiotherapy of breast cancer: application of the relative seriality model. *Br J Radiol* 1996;69:839–46.
11. Kallman P, Agren A, Brahme A. Tumour and normal tissue responses to fractionated non-uniform dose delivery. *Int J Radiat Biol* 1992;62:249–62.
12. Nilsson G, Holmberg L, Garmo H, et al. Distribution of coronary artery stenosis after radiation for breast cancer. *J Clin Oncol* 2012;30:380–6.
13. Nissen HD, Appelt AL. Improved heart, lung and target dose with deep inspiration breath hold in a large clinical series of breast cancer patients. *Radiother Oncol* 2013;106:28–32.
14. Mulliez T, Veldeman L, Speleers B, et al. Heart dose reduction by prone deep inspiration breath hold in left-sided breast irradiation. *Radiother Oncol* 2015;114:79–84.

LETTER TO THE EDITOR

Abscopal effect of radiotherapy in a patient with metastatic diffuse-type giant cell tumor

Ingrid M. E. Desar^a, Pètra M. Braam^b, Suzanne E. J. Kaal^a, Winald R. Gerritsen^a, Wim J. G. Oyen^{c,d} and Winette T. A. van der Graaf^{a,d}

^aDepartment of Medical Oncology, Radboud University Medical Center, Nijmegen, The Netherlands; ^bDepartment of Radiotherapy, Radboud University Medical Center, Nijmegen, The Netherlands; ^cDepartment of Radiology and Nuclear Medicine, Radboud University Medical Center, Nijmegen, The Netherlands; ^dThe Institute of Cancer Research and The Royal Marsden NHS Foundation Trust, London, UK

ARTICLE HISTORY Received 29 August 2016; revised 21 September 2016; accepted 27 September 2016

To the Editor,



A 19-year-old male presented in 1999 with anemia, increased inflammatory parameters and knee complaints, based on diffuse-type giant cell tumor (DGCT). In 2010, a low femoral amputation was performed after several functional joint sparing surgeries and a short unsuccessful period of imatinib 400 mg once daily (OD) therapy [1]. Histopathology showed destructive DGCT with secondary changes due to imatinib treatment, but no signs of malignancy.

Four years later, he presented with fever, sweating, anorexia, weight loss, palpitations and anemia. FDG-positron emission tomography (PET)-computed tomography (CT) scan showed new pulmonary lesions and mediastinal lymphadenopathy. A cytological lymph node biopsy proved metastatic DGCT. Imatinib 400 mg OD and prednisolone 30 mg OD were started. No other immune-modulating therapy has been administered. Two months after start of imatinib and prednisolone, his clinical condition deteriorated with weight loss, fever and inflammation (Table 1). FDG-uptake showed

increased metabolic activity of metastases. To prevent atelectasis, the highly metabolically active right hilar metastasis was irradiated (30 Gy in 10 fractions; Figure 1(a)). During radiotherapy, his condition rapidly deteriorated with high fevers, profound anemia, hypoalbumenia, decreased sodium, hyperglycemia and pulmonary infection (Table 1). Unexpectedly, within two weeks after completing radiotherapy, he clinically improved and his inflammatory laboratory values decreased (Table 1). FDG-PET-CT showed response of the right irradiated hilar lesion, volumetric and metabolic response of left-sided non-irradiated pulmonary metastases and an increase of uptake in one mediastinal lymph node (Figure 1(b) and (c)). This phenomenon is called *abscopal effect*. It persisted for six months, after which he progressed and died from disease three months later.

Discussion

The abscopal effect induced by radiotherapy is rare and is mostly reported in tumor types considered *immunogenic* such

CONTACT Winette T. A. van der Graaf  winette.vandergraaf@icr.ac.uk  Department of Medical Oncology, Radboud University Medical Center, Nijmegen, The Netherlands; The Institute of Cancer Research and The Royal Marsden NHS Foundation Trust, London, UK

© 2016 The Author(s). Published by Informa UK Limited, trading as Taylor & Francis Group
This is an Open Access article distributed under the terms of the Creative Commons Attribution License (<http://creativecommons.org/licenses/by/4.0/>), which permits unrestricted use, distribution, and reproduction in any medium, provided the original work is properly cited.

Table 1. Laboratory results.

Parameter (normal range)	Before start of radiotherapy	Day 5 of radiotherapy (10 × 3 Gy)	Last day of radiotherapy	3 weeks after completing radiotherapy
Hemoglobin (8.4–10.8 mmol/l)	5.1	5.1 ^a	5.8	6.7
Leukocytes (4.0–11.0 × 10 ⁹ /l)	17.4	15.1	13.2	16.8
Platelets (150–400 × 10 ⁹ /l)	811	609	567	445
Neutrophils (2–7.5 × 10 ⁹ /l)	12.7	12.4	11.4	
Lymphocytes (1–3.5 × 10 ⁹ /l)	2.4	0.6	0.5	
Monocytes (0.3–1.0 × 10 ⁹ /l)	2.3	2.0	1.3	
Sodium (135–145 mmol/l)	134	129	127	135
Albumin (35–50 g/l)	13	10	10	17
CRP (<10 mg/ml)	200	225		82

^aErythrocyte transfusion was administered after this measurement. CRP: C-reactive protein.

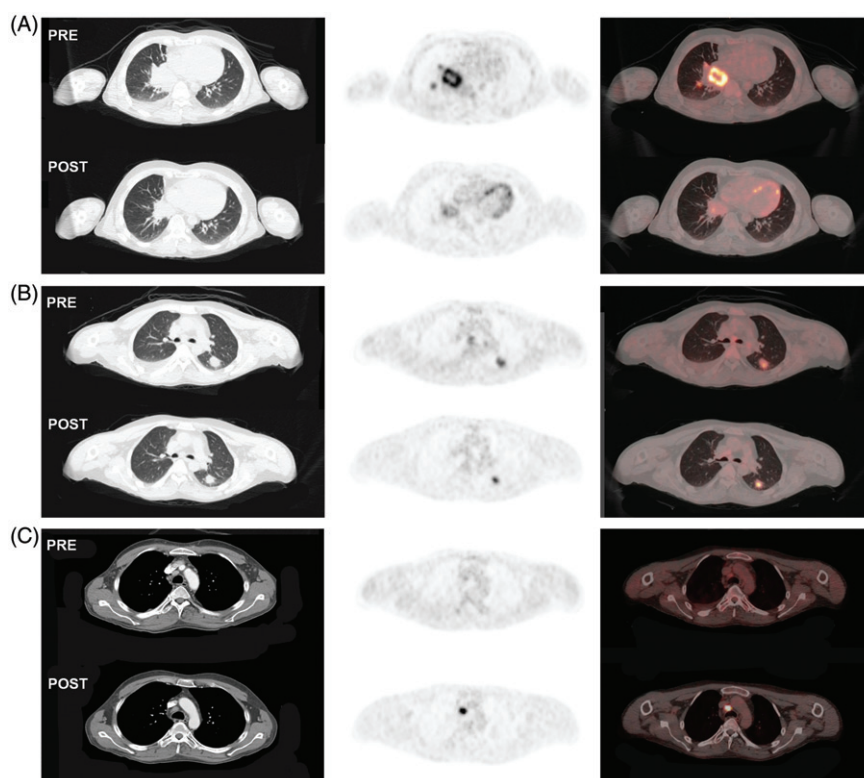


Figure 1. Computed tomography (CT) (left column), FDG-positron emission tomography (PET) (middle column) and combined FDG-PET-CT (right column) before the start (pre) and after completion (post) of radiotherapy. (a) showing high uptake of FDG in the right hilar diffuse-type giant cell tumor metastasis before the start of radiotherapy and impressive decrease in FDG-uptake, corresponding with metabolic response 3 weeks after completion of radiotherapy. Abscopal effect in the left pulmonary metastases (b) and mediastinal lymphadenopathy (c), showing a volume response on CT and metabolic response on FDG-PET-CT in the pulmonary lesions as well as increased uptake in a mediastinal lymph node on FDG-PET-CT, in keeping with an immunological reaction.

as melanoma, but has to our knowledge never been described in mesenchymal malignancies [2]. The immune system has been proposed as the key component of this abscopal effect [3]. Local radiotherapy induces cell death and release of immunogenic factors, leading to host immune responses. Damage-associated molecular patterns trigger dendritic cells, resulting in improved antigen presentation to T cells [2,4]. Pharmacological modification of the abscopal effect has been suggested for immune checkpoint inhibitors and granulocyte-macrophage colony-stimulating factor [4–7].

Here we report a patient with malignant DGCT with marked inflammatory symptoms and laboratory parameters, who demonstrated a systemic benefit from local radiotherapy by an abscopal effect. Tenosynovial giant cell tumors are rare mesenchymal lesions that arise from the synovial lining of articular spaces, bursal sacs, and tendon sheaths. The diffuse-

type is an aggressive multifocal proliferation of synovial-like mononuclear cells with inflammatory infiltrates. Metastases of DGCT are extremely rare. The current treatment strategies have recently been reviewed [8]. The inflammatory nature and the observed abscopal effect plea for considering immunotherapeutic approaches in this disease.

Disclosure statement

The authors report no conflict of interest. The authors alone are responsible for the content and writing of the paper.

References

1. Cassier PA, Gelderblom H, Stacchiotti S, et al. Efficacy of imatinib mesylate for the treatment of locally advanced and/or metastatic

- tenosynovial giant cell tumor/pigmented villonodular synovitis. *Cancer* 2012;118:1649–55.
2. Reynders K, Illidge T, Siva S, et al. The abscopal effect of local radiotherapy: using immunotherapy to make a rare event clinically relevant. *Cancer Treat Rev* 2015;41:503–10.
 3. Formenti SC, Demaria S. Systemic effects of local radiotherapy. *Lancet Oncol* 2009;10:718–26.
 4. Levy A, Chargari C, Marabelle A, et al. Can immunostimulatory agents enhance the abscopal effect of radiotherapy? *Eur J Cancer* 2016;62:36–45.
 5. Grimaldi AM, Simeone E, Giannarelli D, et al. Abscopal effects of radiotherapy on advanced melanoma patients who progressed after ipilimumab immunotherapy. *Oncoimmunology* 2014;3:e28780.
 6. Chandra RA, Wilhite TJ, Balboni TA, et al. A systematic evaluation of abscopal responses following radiotherapy in patients with metastatic melanoma treated with ipilimumab. *Oncoimmunology* 2015;4:e1046028.
 7. Golden EB, Chhabra A, Chachoua A, et al. Local radiotherapy and granulocyte-macrophage colony-stimulating factor to generate abscopal responses in patients with metastatic solid tumors: a proof-of-principle trial. *Lancet Oncol* 2015;16:795–803.
 8. Staals EL, Ferrari S, Donati DM, et al. Diffuse-type tenosynovial giant cell tumour: Current treatment concepts and future perspectives. *Eur J Cancer* 2016;63:34–40.

LETTER TO THE EDITOR

The relative biological effectiveness of carbon ion irradiations of the rat spinal cord increases linearly with LET up to 99 keV/μm

Maria Saager^{a,b,c}, Christin Glowa^{a,b,c}, Peter Peschke^{c,d}, Stephan Brons^{c,e}, Rebecca Grün^f, Michael Scholz^f, Peter E. Huber^{a,c,d}, Jürgen Debus^{a,c} and Christian P. Karger^{b,c}

^aDepartment of Radiation Oncology, University Hospital of Heidelberg, Heidelberg, Germany; ^bDepartment of Medical Physics in Radiation Oncology, German Cancer Research Center (DKFZ), Heidelberg, Germany; ^cNational Center for Radiation Research in Oncology (NCRO), Heidelberg Institute for Radiation Oncology (HIRO), Heidelberg, Germany; ^dClinical Cooperation Unit Molecular Radiooncology, German Cancer Research Center (DKFZ), Heidelberg, Germany; ^eHeidelberg Ion-Beam Therapy Center (HIT), Heidelberg, Germany; ^fDepartment of Biophysics, Helmholtz Center for Heavy Ion Research (GSI), Darmstadt, Germany

ARTICLE HISTORY Received 16 August 2016; revised 11 October 2016; accepted 15 October 2016

To the Editor,

Based on preliminary work at the Lawrence Berkley Laboratory [1], carbon ion beams developed to a mature technology in radiotherapy, which has now been applied successfully in patients for two decades [2–4]. As in proton radiotherapy, the depth-dose profile (Bragg peak) of carbon ions allows for highly conformal irradiations of the tumor. However, the rise of the relative biological effectiveness (RBE) with penetration depth towards the distal end of a spread-out Bragg peak (SOBP) is much more pronounced for carbon ions than for protons [5]. Quantitatively, the RBE is given by the ratio of a photon and an isoeffective carbon ion dose at a defined endpoint. However, the RBE is a complex quantity depending on particle type, linear energy transfer (LET), dose, and also on biological properties of the irradiated tissue. To consider the increased effectiveness of carbon ions, the RBE is calculated by bio-mathematical models. In Europe, clinical treatment planning is done using the local effect model (LEM), which is presently available in two versions (LEM I [6] and IV [7]). Although LEM I has been used for all patients so far, LEM IV was extended by including information on the

spatial DNA double stand break density. It is, however, an open question, which version is more accurate.

To validate the LEM *in vivo*, the RBE for radiation-induced myelopathy in the rat spinal cord has been determined in several studies [8–11] and comparisons with LEM predictions were made. In these studies RBEs were calculated for the tolerance doses at 50% complication probability (TD₅₀) determined from dose-response experiments. Although initial studies [8,9] demonstrated a strong dose-dependence of the RBE, the LET-dependence was not investigated in detail.

This was the starting point of a second series of experiments, where the rat spinal cord was irradiated with single and split doses at six different positions of a 6 cm SOBP covering a LET range from 16 to 99 keV/μm [10,11]. These data showed a linear increase of RBE with LET, where the slope of the curve increased with decreasing fractional dose [11]. For the single fraction experiment at 99 keV/μm, however, an inconsistently low RBE combined with a shallow dose-response curve was found. As this was only observed in the single but not in the split dose experiments, we repeated the 99 keV/μm single dose experiment and report here on the results.