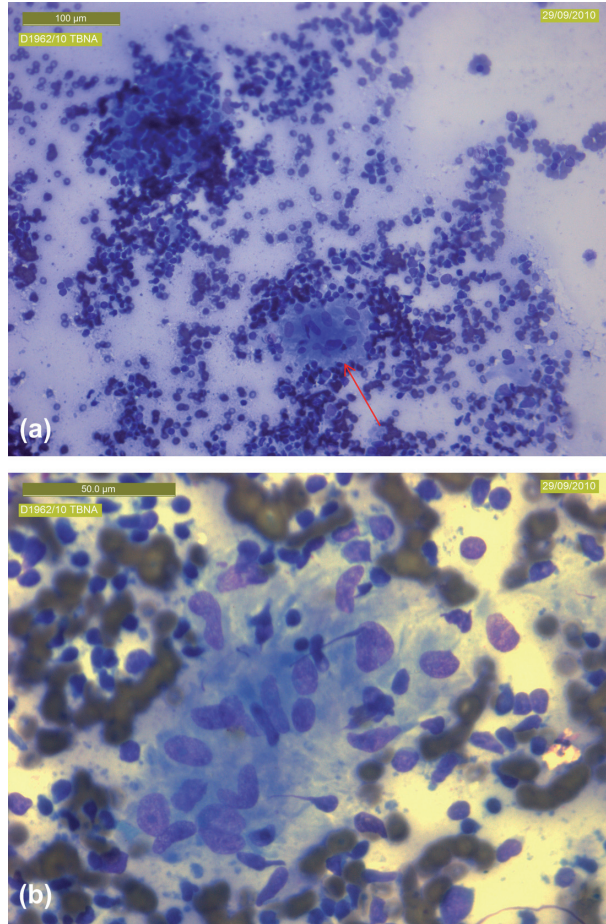


Supplementary material for Teo M, et al., A case of sarcoidosis in a patient with testicular cancer post stem cell transplant. *Acta Oncologica* 2013;52:869–871.



Supplementary Figure 1a and b. Low and high power cytologic examination showing non-caseating granuloma (supplemental: available in the online version of the journal. Please find this material within the direct link to the article: <http://www.informahealthcare.com/doi/abs/10.3109/0284186X.2012.689854>).