

STANDARDIZED PRECISION RADIOTHERAPY IN CHOROIDAL METASTASES

URBAN NYLÉN, ERIK KOCK, INGMAR LAX, GÖRAN LUNDELL, EVA AF TRAMPE and NILS WILKING

Metastases in the choroid of the eye are frequent in patients with disseminated malignancy. We here report the results using the precision radiotherapy technique described by Schipper et al. to treat 14 of 17 consecutive patients (21 eyes) with symptoms from such metastases. A beam defining collimator was used and a lateral field was given with the treated eye individually fixed. Varying fractionations and doses were used. The biologically effective dose for early effects (BED_3) was 47 to 90 Gy and for late effects (BED_{10}) 28 to 59 Gy. In 14 eyes (82%) the metastases regressed completely. The visual acuity was stabilized or improved in all patients and none needed local surgery. Three patients developed signs of radiation retinopathy, but only in one case the visual function was compromised. With this standardized technique no individualized dose planning was needed, the risk of radiation cataract was minimized and a dry eye avoided.

Metastatic intraocular tumour growth occurs in up to 10% of patients with disseminated breast cancer without symptoms from the eyes (1) and can also be found in most other types of malignancies (2–4). The choroid is the most frequent localization of such secondary tumours (5). Breast and pulmonary cancers are the most common primary sites (2, 3, 6–8). Growth of a secondary tumour in the eye is often subclinical but symptoms are distressing when present. Systemic therapy can affect choroidal tumour growth (1, 4, 9, 10), but when visual symptoms occur, most patients have advanced disease and the chance of effect from further systemic therapy is limited. Radiotherapy can be of value in this situation. We have, since 1985, used the retinoblastoma radiotherapy technique described by Schipper et al. (11, 12) for treatment of metastatic intraocular tumours. The present report summarizes our experience in patients with intraocular metastases.

Material and Methods

Between July 1985 and August 1992, 17 consecutive patients with symptoms from metastatic carcinoma of the choroid were given radiotherapy. Four of the patients received bilateral, simultaneous irradiation giving a total number of 21 irradiated eyes. None of the patients had signs of tumour growth in the orbit. The choroidal affection was diagnosed by ophthalmoscopy and in 8 patients also by an ultrasonography.

After completed radiotherapy, clinical examination, including ophthalmoscopy, was performed with intervals of 1 to 3 months. The results in terms of tumour response reported for each patient represent the best effect observed irrespective of time after radiotherapy.

Patient characteristics. The clinical characteristics are summarized in Table 1. For 3 patients (18%), with primaries in rectum, lung and breast, choroidal metastasis was the first sign of metastatic disease. Of the 14 patients who had metastasis from a breast carcinoma 12 had stage I–II disease at the time of primary diagnosis. Fourteen patients had metastases in 3 or more other organs at the time of the diagnosis of choroid metastasis and 5 patients (30%) had symptomatic tumour spread to the central nervous system verified by computerized tomography. Twelve of the 14 patients with breast cancer had been treated with 2 or more hormonal and/or chemotherapy regimens when the choroidal affection was diagnosed. The metastatic deposits

Received 9 June 1993.

Accepted 4 November 1993.

From the Departments of General Oncology (U. Nylén, G. Lundell, N. Wilking), Hospital Physics (I. Lax), Radiumhemmet, Karolinska Hospital, and St Erik Eye Hospital (E. Kock, E. af Trampe), Stockholm, Sweden.

Correspondence to: Dr Urban Nylén, Department of General Oncology, Radiumhemmet, Karolinska Hospital, S-104 01 Stockholm, Sweden.

Table 1
Patient characteristics

Characteristics	Median	Range	Female	Male	No.	(%)
Age at radiotherapy (years)	50	32-77				
Interval to first metastasis (months)	22	0-120				
Interval from first metastasis to intraocular metastasis (months)	13	0-43				
Primary tumour						
Breast cancer			14			
Medullary thyroid cancer			1			
Rectal cancer				1		
Pulmonary cancer				1		
Choroidal metastasis						
Single, unilateral					12	(70)
Single, bilateral					2	(12)
Multiple, unilateral					0	
Multiple, bilateral					3	(18)

involved the posterior pole of the eye. The anterior uveal tract was not affected in any patient. Decrease in visual acuity was the most common symptom. Flashes and a blurred vision field were also commonly reported.

Procedures. Sixteen of the 21 eyes were irradiated with a standardized, lateral 26×32 mm D-shaped field and a 4 MV photon beam (Philips linear accelerator SL 75-5). The field was shaped by a fixed 11 cm beam-defining collimator and included the eye dorsal from a plane tangent to the posterior pole of the lens. Ten millimeter of the anterior optic nerve was also included. The distance from cornea to the anterior optic nerve was also included. The distance from cornea to the anterior border of the field was 7 mm. A vacuum pillow was used for positioning and fixation of the patient's head during treatment. Prior to every irradiation a local anaesthetic and paraffin oil were instilled and the eye was isocentrically fixed to the collimator by a low-vacuum contact lens (Fig. 1). When the treatment was unilateral, two beam angles were used alternately and the contralateral eye was excluded from the field (a, b in Fig. 2). The dose was in this case specified at the depth of dose maximum in the beam, i.e. at 10 mm. At simultaneous bilateral treatment the fields were lateral and opposed (c in Fig. 2). For such cases the dose was specified at the midplane. The dose in the eye varied with about $\pm 5\%$ from the specification dose. However, in the penumbra region in the anterior part of the eye a lower dose was obtained (Fig. 3). The fractionation schedules used and the biologically effective doses for early (BED_3) and late (BED_{10}) effects (13) were as follows: Ten of the 21 eyes were irradiated with 3 Gy, 3 times per week to a total dose of 45 Gy (BED_3 90 Gy, BED_{10} 59 Gy). One eye got 4 Gy, 3 times weekly to 32 Gy (BED_3 75 Gy, BED_{10} 45 Gy). For 5 eyes schedules with one daily fraction 5 days a week were used: 1 eye 3.5 Gy per fraction to 35 Gy (BED_3 76 Gy,

BED_{10} 47 Gy), 2 eyes 3 Gy per fraction to 30 Gy (BED_3 60 Gy, BED_{10} 39 Gy) and 2 eyes 4 Gy per fraction to 20 Gy (BED_3 47 Gy, BED_{10} 28 Gy). In 5 of the 21 eyes (3 patients) no fixation of the eyes was applied but an individually manufactured face mask supported the head. A dose plan based on computerized tomography was made for each of these patients. Four of the eyes (2 patients) were treated with 2 Gy per fraction 5 days per week to 40 Gy (BED_3 67 Gy, BED_{10} 48 Gy) with lateral, opposed fields and one eye with 2.5 Gy per fraction 5 days per week to 35 Gy (BED_3 76 Gy, BED_{10} 47 Gy) with angulated unilateral fields.

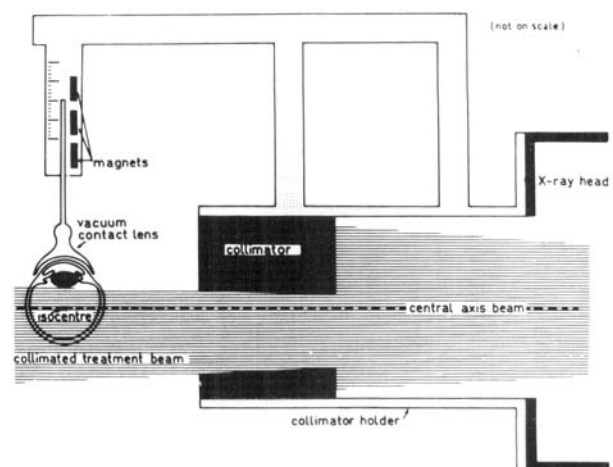


Fig. 1. Treatment technique. Schematic presentation of the treatment technique. Accurate alignment and positioning of the eye with respect to the radiation beam is achieved by indirect fixation of the eye to the beam defining collimator. A low-vacuum contact lens is fixed to the eye in central position. The soft iron pin jutting out from the contact lens is magnetically coupled to the millimeter scale on the collimator holder. (The figure is reproduced from ref. 15 with permission from Elsevier Science Publishers.)

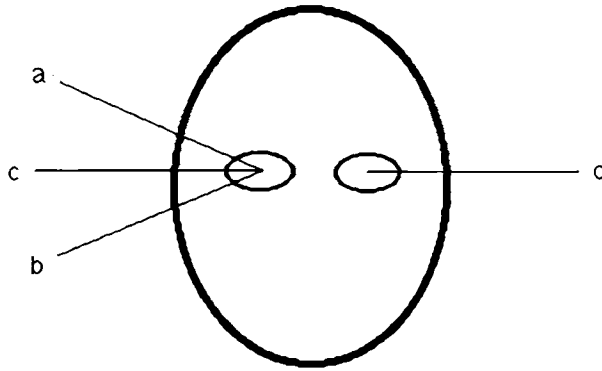


Fig. 2. Treatment angles. Schematic presentation of treatment beam directions. (a) and (b) represent alternated beam directions when the treatment was unilateral. For bilateral simultaneous treatment opposed fields (c) were used.

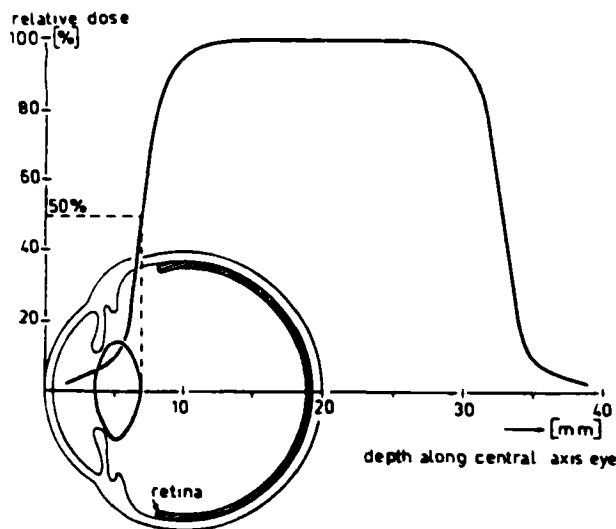


Fig. 3. Dose distribution. Dose profile of a lateral D-shaped field of 26×32 mm along the axial axis of an eye. The field is set up with the 50% dose point tangent to the posterior pole of the lens. The collimator system and the dose distribution were the same in the present study. (The figure is reproduced from ref. 15 with permission from Elsevier Science Publishers.)

Results

Seventeen of the 21 irradiated eyes were evaluated by ophthalmoscopy. In the remaining cases a bad performance status made further investigation of the eyes impossible. Fourteen of the eyes (82%) were found to have an inactive scar (complete response). Three (18%) had an unchanged state of the metastases or a partial regression (Table 2). Fundoscopic evidence of regression was visible within one month of completed radiotherapy in most patients. Sixteen eyes were evaluated for acuity of vision. Thirteen (81%) had improved or were unchanged. Three eyes (19%) had a slight reduction in acuity (Fig. 4). Time to best response in choroidal status and visual acuity was 6 months or less in 14 of the evaluable eyes. In one patient unilateral metastatic regrowth occurred 16 months after simulta-

Table 2

Result at ophthalmoscopy

	No. of eyes (17 eyes evaluated)
CR/inactive scar	14 (82%)
PR/NC	3 (18%)
PD	0

Abbreviations. CR = complete remission, PR = partial remission, NC = no change, PD = progressive disease

neous irradiation of bilateral, single metastases from breast cancer. Due to tumour progression also elsewhere the patient underwent chemotherapy. Signs of a second regression in the choroid could be seen. The patient was still alive 31 months after irradiation of the eyes. Two patients (3 eyes irradiated) were still alive at 6 and 31 months after irradiation. Fifteen patients had died from disseminated malignancy. Out of those, 4 died within 3 months of the ocular radiotherapy. The median survival after radiotherapy for choroidal metastases was 11 months (range 1–54).

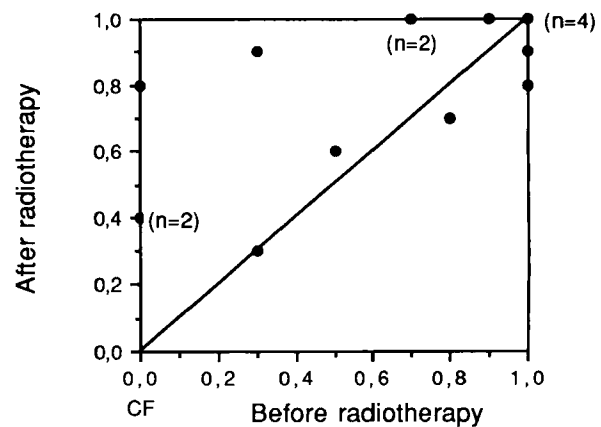


Fig. 4. Treatment effect on visual acuity. Visual acuity after radiotherapy as a function of pre-treatment value. x-axis: before, y-axis: after therapy. 16 of the 21 irradiated eyes were evaluated for visual acuity. (CF = counting fingers.)

Complications. Except for a mild contact lens-induced conjunctivitis during the treatment in some of the patients, no acute side-effects related to the therapy were seen. However, three female breast cancer patients, who all were irradiated with 3 fractions of 3 Gy per week to 45 Gy (BED_3 90 Gy, BED_{10} 59 Gy), experienced 2–20 months after completed radiotherapy minor choroidal bleeding or signs of retinal atrophy, that could be related to the radiotherapy given (14).

Discussion

Our study shows that irradiation of choroidal metastases in patients with disseminated malignancy of various origin gives an excellent palliation. The standardized tech-

nique, as described by Schipper (11), minimizes the need of individual dose planning, is easily tolerable for the patients and uncomplicated to handle at the radiotherapy department. None of our patients did suffer from ocular pain or was in need of surgery or other types of ophthalmic therapy due to the metastatic intraocular tumour growth. Useful visual function was restored or maintained in all patients. The standardized technique minimizes the risk of cataract for long-time survivors and the risk of symptoms from a dry eye can be avoided.

When we initiated palliative irradiation of eyes with the standardized method, we used the same fractionation schedule as used for treatment of retinoblastomas. In our experience this fractionation is effective also in the palliative setting. However, successful palliation was achieved with all schemes used. The technique should preferably be time saving and easily tolerable. Hypofractionated radiotherapy, in accordance with schedules used in other metastatic sites, is then of interest. The optimal fractionation with low risk for complications, such as retinopathy, remains to be established, but 3 Gy 5 times a week to 30 Gy or 4 Gy daily to 20 Gy may be schedules of choice.

A face mask for fixation of the head but no precise fixation of the irradiated eye is the commonly reported strategy (see 1, 5, 15). We have treated 3 patients (5 eyes) with such a method. Apart from the need of more demanding preparation procedures with such a fixation there is also an obvious risk of underdosage in the anterior part of the irradiated volume when the eye is not precisely fixed and the penumbra zone is wider in comparison with the standardized method. A portal arrangement with a frontal field (15, 16) diminishes the risk of underdosage in the bulb but invariably increases the risk of sequelae to the eyes and surrounding tissues.

In patients with ocular metastases the lesions have been reported to be bilateral in up to 40% of the cases (4). Four of our 17 patients (23%) had bilateral affection and had both eyes irradiated simultaneously. No patient had symptoms or signs of contralateral tumour growth during the follow-up period. With the present method there would have been no problem to add contralateral irradiation later if needed.

A variety of techniques with different portal arrangements and different fractionation schedules have been reported in the literature, such as 3 Gy daily to 21–30 Gy (1, 4, 7, 12, 15, 18), 2 Gy daily to 40–50 Gy (5, 17) and 3.33 Gy 3 times a week to 30 Gy (8). However, in some of these series also patients with orbital tumour growth have been included and the criteria for response differ. A straightforward comparison of results is hence not possible, but our results seem to be well in line with, or better than, the best results reported (5, 16, 18).

All but two of our patients received, due to their widespread disease, systemic therapy during the time of follow-up after radiotherapy.

However, fifteen patients died from progression of disseminated malignancy and out of these only one patient had signs of recurrence in an irradiated eye. Hence, with great probability the radiotherapy contributed to the locally successful result. Radiotherapy of intraocular metastasis can be delivered in a safe and tolerable way. The local result can be expected to be excellent and lasting. It is thus our impression, that patients with symptomatic metastases in the eyes should be offered radiotherapy. The method should be well elaborated from physical and clinical points of view.

REFERENCES

- Orenstein M, Anderson DP, Stein JJ. Choroid metastasis. *Cancer* 1972; 29: 1101–7.
- Ferry AP, Font RL. Carcinoma metastatic to the eye and orbit. *Arch Ophthalmol* 1974; 92: 276–86.
- von Hollwich F, Lemke L. Karzinommetastasen in der Aderhaut. *Dtsch Med Wochenschr* 1965; 8: 329–33.
- Mewis L, Young SE. Breast carcinoma metastatic to the choroid. *Ophthalmol* 1982; 89: 147–51.
- Dobrowsky W. Treatment of choroid metastases. *Br J Radiol* 1988; 61: 140–2.
- Freedman MI, Folk JC. Metastatic tumours to the eye and orbit. *Arch Ophthalmol* 1987; 105: 1215–9.
- Reddy S., Saxena VS, Hendrickson F, Deutsch W. Malignant metastatic disease of the eye. *Cancer* 1981; 47: 810–2.
- Sassmannshausen J, Bornfeldt N, Foerster MH, Sauerwein W, Schreiber T, Wessing A. Metastasen maligner extraokularen Tumoren in der Aderhaut. *Forschr Ophthalmol* 1990; 87: 69–73.
- Halpern J, Sofinski SJ, Forgach PW, Khilchenko S, Ambus JL. Choroidal metastasis arising from carcinoma of the breast. *J Med* 1986; 17: 1–11.
- Letson AD, Davidorf FH, Bruce Jr RA. Chemotherapy for treatment of choroidal metastasis from breast carcinoma. *Am J Ophthalmol* 1982; 93: 102–6.
- Schipper J. An accurate and simple method for megavoltage radiation therapy of retinoblastoma. *Radiother Oncol* 1983; 1: 31–41.
- Schipper J, Tan KEWP, van Peperzeel HA. Treatment of retinoblastoma by precision megavoltage radiation therapy. *Radiother Oncol* 1985; 3: 117–32.
- Fowler JF. The linear-quadratic formula and progress in fractionated radiotherapy. *Br J Radiol* 1989; 62: 679–94.
- Wara W, Irvine AR, Neger RE, Howes Jr EL, Phillips TL. Radiation retinopathy. *Int J Radiat Oncol Biol Phys* 1979; 5: 81–3.
- Hoogenhout J, Brink HMA, Verbeek AM, van Gasteren JJM, Beex LVAM. Radiotherapy of choroidal metastases. *Strahlenther Onkol* 1989; 165: 375–9.
- Ratanatharathorn V, Powers WE, Grimm J, et al. Eye metastasis from carcinoma of the breast: diagnosis, radiation treatment and results. *Cancer Treat Rev* 1991; 18: 261–76.
- Schweiger S, Breitbach GP, Bruch PM, Tkocz HP, Schmidt W. Aderhautmetastasen beim metastasierenden Mammakarzinom—Einen seltene Metastasenlokalisation. *Geburtshilfe Frauenheilkd* 1990; 50: 816–8.
- Burmeister BH, Benjamin CS, Childs WJ. The management of metastases to eye and orbit from carcinoma of the breast. *Aust NZJ Ophthalmol* 1990; 18: 187–90.